

World Journal of *Gastrointestinal Oncology*

World J Gastrointest Oncol 2020 November 15; 12(11): 1216-1380



ORIGINAL ARTICLE

Basic Study

- 1216** Pathological significance of abnormal receptor d'origine nantaïs and programmed death ligand 1 expression in colorectal cancer
Liu YZ, Han DT, Shi DR, Hong B, Qian Y, Wu ZG, Yao SH, Tang TM, Wang MH, Xu XM, Yao HP
- 1237** Decreased expression of the long non-coding RNA HOXD-AS2 promotes gastric cancer progression by targeting HOXD8 and activating PI3K/Akt signaling pathway
Yao L, Ye PC, Tan W, Luo YJ, Xiang WP, Liu ZL, Fu ZM, Lu F, Tang LH, Xiao JW
- 1255** Programmed death 1, ligand 1 and 2 correlated genes and their association with mutation, immune infiltration and clinical outcomes of hepatocellular carcinoma
Sheng QJ, Tian WY, Dou XG, Zhang C, Li YW, Han C, Fan YX, Lai PP, Ding Y

Case Control Study

- 1272** LncRNA C9orf139 can regulate the growth of pancreatic cancer by mediating the miR-663a/Sox12 axis
Ge JN, Yan D, Ge CL, Wei MJ

Retrospective Cohort Study

- 1288** Cancer-related microangiopathic hemolytic anemia in patients with advanced gastric cancer: A retrospective single-center analysis
Berger AK, Allgäuer M, Apostolidis L, Schulze-Schleithoff AE, Merle U, Jaeger D, Haag GM
- 1296** Influence of primary tumor location and resection on survival in metastatic colorectal cancer
Tharin Z, Blanc J, Charifi Alaoui I, Bertaut A, Ghiringhelli F

Retrospective Study

- 1311** Highly accurate colorectal cancer prediction model based on Raman spectroscopy using patient serum
Ito H, Urugami N, Miyazaki T, Yang W, Issha K, Matsuo K, Kimura S, Arai Y, Tokunaga H, Okada S, Kawamura M, Yokoyama N, Kushima M, Inoue H, Fukagai T, Kamijo Y
- 1325** Subtotal gastrectomy combined with chemotherapy: An effective therapy for patients with circumscribed Borrmann type IV gastric cancer
Huang HB, Gao ZM, Sun AQ, Liang WT, Li K

Randomized Controlled Trial

- 1336** Diagnostic value of novel retroflexion colonoscopy in the right colon: A randomized controlled trial
Li WK, Wang Y, Wang YD, Liu KL, Guo CM, Su H, Liu H, Wu J

META-ANALYSIS

- 1346** Efficacy and safety of anti-PD-1/anti-PD-L1 antibody therapy in treatment of advanced gastric cancer or gastroesophageal junction cancer: A meta-analysis

Yang L, Dong XZ, Xing XX, Cui XH, Li L, Zhang L

CASE REPORT

- 1364** Inferior mesenteric arteriovenous fistula during treatment with bevacizumab in colorectal cancer patient: A case report

Doi A, Takeda H, Umemoto K, Oumi R, Wada S, Hamaguchi S, Mimura H, Arai H, Horie Y, Mizukami T, Izawa N, Ogura T, Nakajima TE, Sunakawa Y

- 1372** Cutaneous metastases of pancreatic carcinoma to the labia majora: A case report and review of literature

Shi Y, Li SS, Liu DY, Yu Y

ABOUT COVER

Editorial Board Member of *World Journal of Gastrointestinal Oncology*, Tomohide Hori, PhD, MD, FACS, is an Attending Surgeon at the Affiliated Hospital with Kyoto University (Kyoto, Japan). Dr. Hori obtained his medical doctor license from Tokyo Medical University (Japan) in 1997 and his Doctor of Philosophy degree from Mie University Graduate School of Medicine (Japan) in 2007. Dr. Hori is certified and qualified by many international and domestic societies, including the American College of Surgeons and Japan Society of Endoscopic Surgery. From 2009 to 2011, he worked at Mayo Clinic (Jacksonville, FL, United States). Dr. Hori's research career has spanned the fields of gastroenterology, hepatology, transplant immunology, and gastrointestinal, colorectal, hepatobiliary, pancreatic, transplant and pediatric surgeries, yielding more than 200 medical publications in international journals. (L-Editor: Filipodia)

AIMS AND SCOPE

The primary aim of *World Journal of Gastrointestinal Oncology* (WJGO, *World J Gastrointest Oncol*) is to provide scholars and readers from various fields of gastrointestinal oncology with a platform to publish high-quality basic and clinical research articles and communicate their research findings online.

WJGO mainly publishes articles reporting research results and findings obtained in the field of gastrointestinal oncology and covering a wide range of topics including liver cell adenoma, gastric neoplasms, appendiceal neoplasms, biliary tract neoplasms, hepatocellular carcinoma, pancreatic carcinoma, cecal neoplasms, colonic neoplasms, colorectal neoplasms, duodenal neoplasms, esophageal neoplasms, gallbladder neoplasms, etc.

INDEXING/ABSTRACTING

The WJGO is now indexed in Science Citation Index Expanded (also known as SciSearch®), PubMed, and PubMed Central. The 2020 edition of Journal Citation Reports® cites the 2019 impact factor (IF) for WJGO as 2.898; IF without journal self cites: 2.880; 5-year IF: 3.316; Ranking: 143 among 244 journals in oncology; Quartile category: Q3; Ranking: 55 among 88 journals in gastroenterology and hepatology; and Quartile category: Q3.

RESPONSIBLE EDITORS FOR THIS ISSUE

Production Editor: Jia-Hui Li; Production Department Director: Xiang Li; Editorial Office Director: Jin-Lei Wang.

NAME OF JOURNAL

World Journal of Gastrointestinal Oncology

ISSN

ISSN 1948-5204 (online)

LAUNCH DATE

February 15, 2009

FREQUENCY

Monthly

EDITORS-IN-CHIEF

Rosa M Jimenez Rodriguez, Pashtoon Kasi, Monjur Ahmed

EDITORIAL BOARD MEMBERS

<https://www.wjgnet.com/1948-5204/editorialboard.htm>

PUBLICATION DATE

November 15, 2020

COPYRIGHT

© 2020 Baishideng Publishing Group Inc

INSTRUCTIONS TO AUTHORS

<https://www.wjgnet.com/bpg/gerinfo/204>

GUIDELINES FOR ETHICS DOCUMENTS

<https://www.wjgnet.com/bpg/GerInfo/287>

GUIDELINES FOR NON-NATIVE SPEAKERS OF ENGLISH

<https://www.wjgnet.com/bpg/gerinfo/240>

PUBLICATION ETHICS

<https://www.wjgnet.com/bpg/GerInfo/288>

PUBLICATION MISCONDUCT

<https://www.wjgnet.com/bpg/gerinfo/208>

ARTICLE PROCESSING CHARGE

<https://www.wjgnet.com/bpg/gerinfo/242>

STEPS FOR SUBMITTING MANUSCRIPTS

<https://www.wjgnet.com/bpg/GerInfo/239>

ONLINE SUBMISSION

<https://www.f6publishing.com>



Cutaneous metastases of pancreatic carcinoma to the labia majora: A case report and review of literature

Ying Shi, Shan-Shan Li, Dan-Yan Liu, Yan Yu

ORCID number: Ying Shi 0000-0002-3249-6632; Shan-Shan Li 0000-0001-5745-7835; Dan-Yan Liu 0000-0001-5631-6387; Yan Yu 0000-0003-1227-7448.

Author contributions: All authors contributed equally to this paper with the conception and design of the study, literature review and analysis, manuscript drafting, critical revision, and editing, and approval of the final version.

Informed consent statement:

Informed consent was obtained from the patient.

Conflict-of-interest statement: All the authors are aware of the content of the manuscript and have no conflict of interest to disclose.

CARE Checklist (2016) statement:

The authors have read the CARE Checklist (2016), and the manuscript was prepared and revised according to the CARE Checklist (2016).

Open-Access: This article is an open-access article that was selected by an in-house editor and fully peer-reviewed by external reviewers. It is distributed in accordance with the Creative Commons Attribution NonCommercial (CC BY-NC 4.0) license, which permits others to distribute, remix, adapt, build

Ying Shi, Yan Yu, Department of Dermatology, First Hospital of Jilin University, Changchun 130021, Jilin Province, China

Shan-Shan Li, Department of Dermatology and Venereology, First Hospital of Jilin University, Changchun 130021, Jilin Province, China

Dan-Yan Liu, Department of Radiology, First Hospital of Jilin University, Changchun 130021, Jilin Province, China

Corresponding author: Yan Yu, MD, Chief Doctor, Department of Dermatology, First Hospital of Jilin University, No. 71 Xinmin Street, Changchun 130021, Jilin Province, China. yuyan741206@126.com

Abstract

BACKGROUND

Cutaneous metastases originating from pancreatic cancer are relatively rare. The most common reported site of metastasis is the umbilicus, and this manifestation is known as the Sister Mary Joseph's nodule. Non-umbilical cutaneous metastases are far less common, with only a few cases reported in the literature. Our case is the first case report, to our knowledge, on metastasis involving the labia majora and flat papules.

CASE SUMMARY

A 49-year-old Chinese female patient presented with a number of red, swollen papules on the vulva for 2 mo. Histological examination of the labia majora lesion revealed metastatic adenocarcinoma. The serum levels of tumor biomarkers CA199, CA242, and CA125 were significantly elevated. B-mode ultrasound-guided needle biopsy of the pancreas demonstrated moderately and poorly differentiated adenocarcinoma. The patient finally declined treatment for financial reasons and died 3 mo later.

CONCLUSION

Metastatic cutaneous lesions could indicate pancreatic cancer. Serum levels of tumor biomarkers may aid in diagnosing metastatic pancreatic adenocarcinoma.

Key Words: Pancreatic cancer; Cutaneous; Metastasis; Non-umbilical; Biomarker; Case report

upon this work non-commercially, and license their derivative works on different terms, provided the original work is properly cited and the use is non-commercial. See: <http://creativecommons.org/licenses/by-nc/4.0/>

Manuscript source: Unsolicited manuscript

Specialty type: Oncology

Country/Territory of origin: China

Peer-review report's scientific quality classification

Grade A (Excellent): 0

Grade B (Very good): 0

Grade C (Good): 0

Grade D (Fair): 0

Grade E (Poor): 0

Received: August 12, 2020

Peer-review started: August 12, 2020

First decision: September 16, 2020

Revised: September 29, 2020

Accepted: October 19, 2020

Article in press: October 19, 2020

Published online: November 15, 2020

P-Reviewer: Buanes T

S-Editor: Gao CC

L-Editor: Wang TQ

P-Editor: Li JH



©The Author(s) 2020. Published by Baishideng Publishing Group Inc. All rights reserved.

Core Tip: Cutaneous metastasis from pancreatic cancer is uncommon. The most common site of the skin lesion is the umbilicus. The majority of skin lesions are singular, particularly in patients exhibiting the Sister Mary Joseph's nodule. We describe an unusual case of flat papules on the labia majora that metastasized from pancreatic cancer. The lesion was the first sign of metastatic disease, and serum levels of CA199, CA242, and CA125 were also elevated. We report this case to improve the understanding of cutaneous metastasis of pancreatic cancer and emphasize the importance of serum levels of CA199, CA242, and CA125 in diagnosing pancreatic cancer.

Citation: Shi Y, Li SS, Liu DY, Yu Y. Cutaneous metastases of pancreatic carcinoma to the labia majora: A case report and review of literature. *World J Gastrointest Oncol* 2020; 12(11): 1372-1380

URL: <https://www.wjgnet.com/1948-5204/full/v12/i11/1372.htm>

DOI: <https://dx.doi.org/10.4251/wjgo.v12.i11.1372>

INTRODUCTION

Pancreatic cancer is one of the most lethal human malignancies and is often diagnosed late in the course of the disease. Cutaneous metastases originating from pancreatic cancer are relatively rare. The most common reported site of metastasis is the umbilicus, and this manifestation is known as the Sister Mary Joseph's nodule. Non-umbilical cutaneous metastases are far less common, with only a few cases reported in the literature. To our knowledge, there are no previous reports on metastasis involving the labia majora and flat papules. This report describes a case of cutaneous pancreatic metastases on the labia majora in a Chinese woman, and a review of previously reported non-umbilical cutaneous pancreatic carcinoma metastases (by conducting a detailed PubMed search). Furthermore, an analysis of 34 reported cases of non-umbilical cutaneous metastasis from pancreatic cancer was conducted with regard to the clinical characteristics.

CASE PRESENTATION

Chief complaints

A 49-year-old female patient with a number of red, swollen papules on the vulva for 2 mo was referred to our department.

History of present illness

The patient had developed red, swollen papules on the vulva 3 mo previously. She attended a local hospital, where she was diagnosed with contact dermatitis and took regular anti-allergy treatment. There was no obvious improvement in her symptoms. Erythema gradually affected the abdomen and lower extremities. The patient had experienced intermittent shortness of breath and coughed up white sputum during this period.

History of past illness

The patient had experienced hypertension for 2 years and had a history of sulfonamide allergy.

Personal and family history

There was not a personal or family history of pancreatic cancer.

Physical examination

Physical examination revealed diffuse erythema and swelling on the chest, abdomen, and vulva; right leg edema; and a number of flat skin-colored or gray papules on the

labia majora (Figure 1).

Laboratory examinations

Routine laboratory testing revealed that the patient was human immunodeficiency virus (HIV) negative; the results of blood and urine tests and levels of renal and hepatic markers and antinuclear antibodies were within the normal ranges. There was a remarkable elevation in the serum concentrations of tumor markers, comprising cytokeratin 19 (8.98 g/L; normal: < 5 µg/L), CA242 (> 500 U/mL; normal: < 20 U/mL), CA125 (52.41 U/mL; normal: < 35 U/mL), and CA199 (726.54 U/mL; normal: < 37 U/mL).

Imaging examinations

An ultrasound scan showed bilateral mammary gland hyperplasia, no other gynecological abnormalities, and right leg lymphedema. A chest computerized tomography (CT) scan revealed inflammation, with patterns of interstitial change scattered across both lungs and a little pleural effusion in the left lung. An abdominal CT scan demonstrated many enlarged lymph nodes, associated with the abdominal aorta, bilateral iliac artery, and bilateral inguinal region, as well as changes in the pancreatic and peripancreatic morphology. A positron emission tomography (PET)-CT scan showed increased metabolic activity in the tail of the pancreas and multiple enlarged lymph nodes throughout the body, as well as subcutaneous tissue edema (Figure 2).

Further diagnostic work-up

A punch biopsy was performed on the abdomen and labia majora lesions. The abdominal epidermis was normal, and there were dilated small blood vessels and lymph vessels in the dermis, and small quantities of infiltrating lymphocytes. Histological examination of the labia majora papules showed nests of moderately differentiated atypical cells partly forming adenomatous structures in the collagen bundles of the dermis and lymphangiectasia (pathologic dilation of the lymph vessels) in the dermis (Figure 3). The immunohistochemical staining results (Figure 4) were as follows: CK7 (+), panCK (+), CK19 (+), CA19-9 (+), CDX-2 (+), CK20 (+), D2-40 (-), and P63 (-), which is consistent with a possible pancreatic source of the metastasis.

In addition, a large amount of milky fluid was drained from the skin biopsy sites. While the serum triglyceride level was normal, the level in the fluid was 1.55 mmol/L, indicating lymphocytosis. Neither bacteria (including *Mycobacterium tuberculosis*) nor fungi were found in the fluid. According to the laboratory and histopathologic findings, a diagnosis of chylous reflux fluid was made.

Thereafter, B-mode ultrasound-guided needle biopsy of the pancreas demonstrated moderately and poorly differentiated adenocarcinoma (Figure 5).

FINAL DIAGNOSIS

According to the clinical manifestations and histopathologic findings, a diagnosis of metastatic pancreatic carcinoma was established.

TREATMENT

The patient declined treatment for financial reasons.

OUTCOME AND FOLLOW-UP

The patient died 3 mo later.

DISCUSSION

Cutaneous metastases are rare, occurring in 0.7%-9.0% of all patients with cancer^[1]. Breast, lung, and colon cancer are the most frequent origins of cutaneous metastases.

Pancreatic cancer is one of the most lethal cancers, with a 5 year survival rate of 5%.

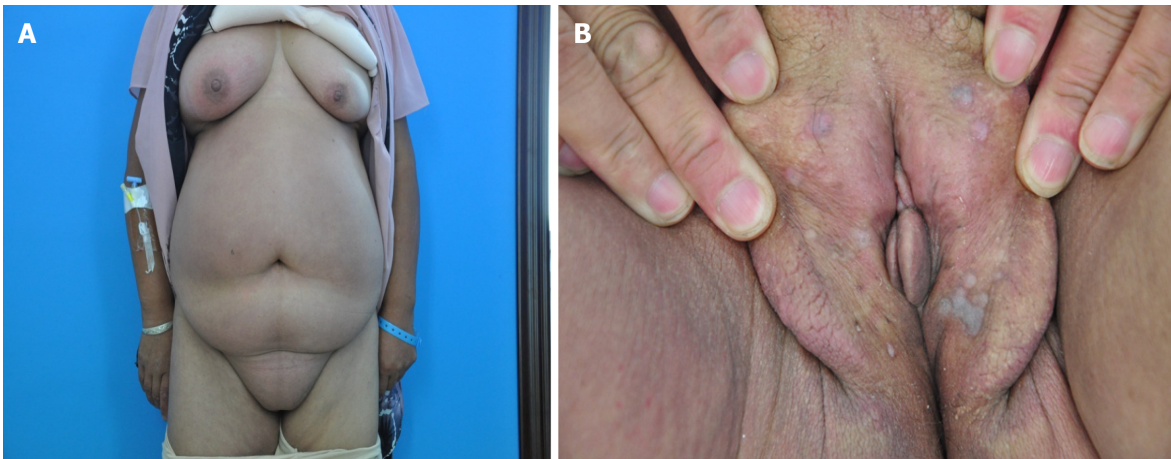


Figure 1 Photographs of our patient. A: Diffuse erythema and swelling on the chest, abdomen, and right leg; B: Edema and a number of flat skin-colored or gray papules on the labia majora.

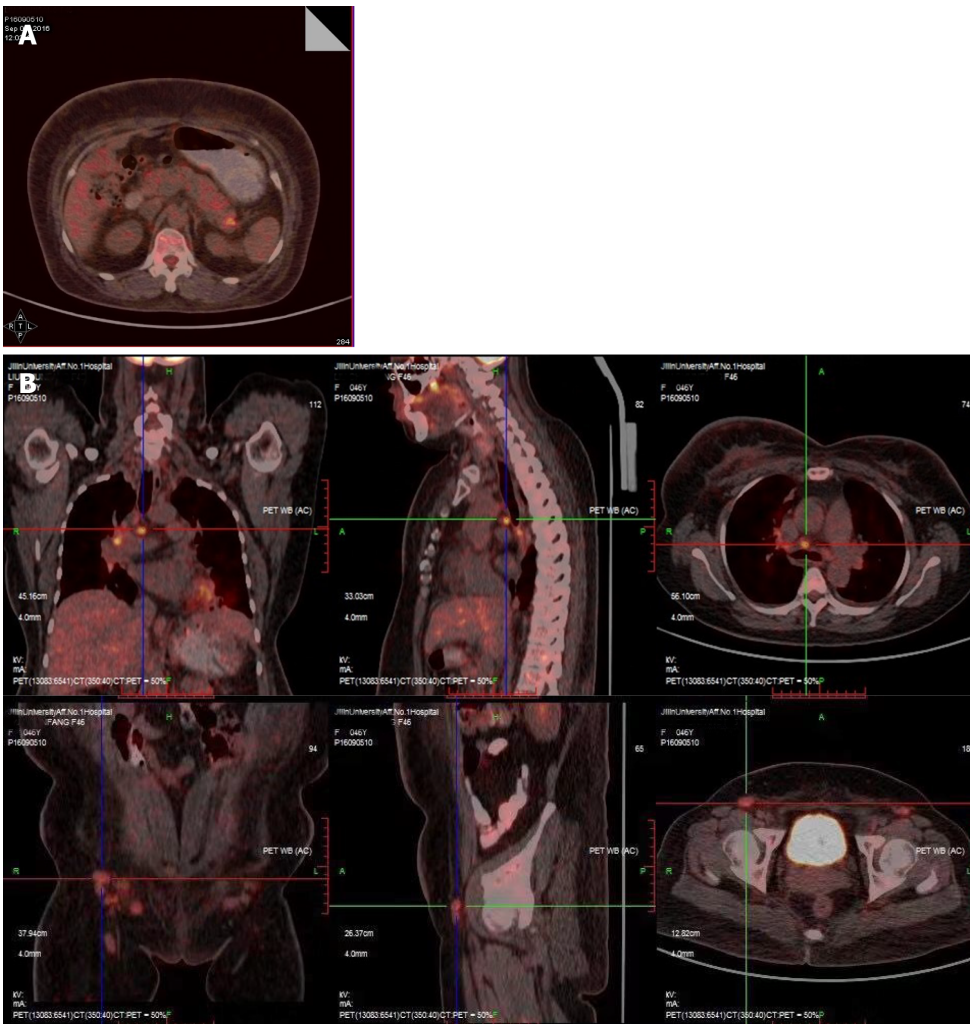


Figure 2 Positron emission tomography-computed tomography scan showing increased metabolic activity. A: The tail of the pancreas; B: Mediastinum, hilus of the lung, and postperitoneal lymph nodes.

Owing to a lack of early clinical features and the fulminant disease course, early diagnosis is difficult and the metastasis rate is high, with a median overall survival of 5 mo^[2]. Pancreatic cancer is often known to metastasize *via* the lymphatic system, with direct invasion at an early stage and hematogenous dissemination at a later stage. The incidence of cutaneous metastases is significantly more frequent for cancers of the

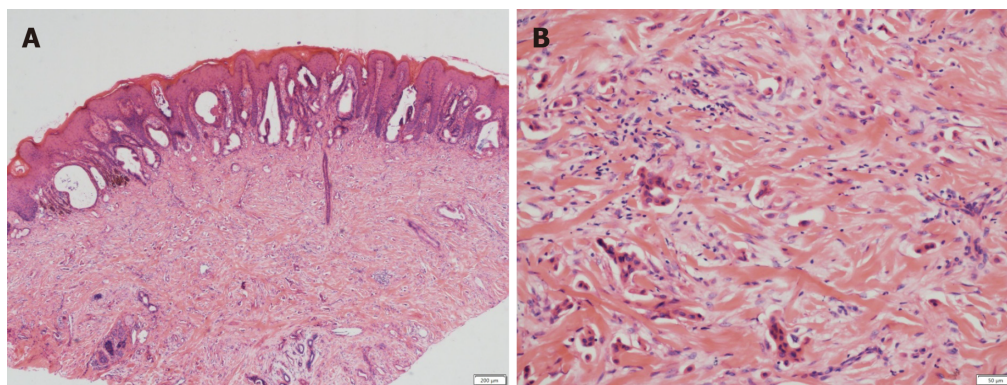


Figure 3 Pathology of cutaneous metastasis. A: Histological examination of the labia majora papule showing nests of moderately differentiated atypical cells partly forming adenomatous structures in the collagen bundle of the dermis and lymphangiectasis in the dermis [hematoxylin-eosin (HE) staining, $\times 40$]; B: Dermis occupied by mass of numerous tumor cells (HE staining, $\times 200$).

pancreatic body and tail than for pancreatic head cancer^[3].

The most frequent organs involved in the metastasis are the liver, peritoneum, lungs, bones, and brain^[2]. Indeed, only 2% of the first metastases from pancreatic cancer are cutaneous metastases, making cutaneous metastases relatively rare^[4]. The most common site of cutaneous metastasis from the pancreas is the umbilicus, and this manifestation is known as Sister Mary Joseph's nodule^[5]. Horino *et al*^[6] reviewed 42 reported cases of pancreatic metastasis from 1950 to 2011, and included only 14 cases of non-umbilical cutaneous metastasis, involving the head, neck, and truncal region. The patients with pancreatic metastasis had such symptoms as subcutaneous nodules (in 26 patients) and inflammatory erythema (in 3 patients).

We collected all case reports of non-umbilical metastatic skin cancer from 1950 to 2020 on the electronic PubMed database (www.ncbi.nlm.nih.gov/pubmed; up to July 2020) by searching using Medical Subject Headings (www.nlm.nih.gov/mesh) and keywords, and by limiting the search to human studies (Table 1)^[1-4,6-30]. The terms pancreatic cancer, pancreatic neoplasm, pancreatic carcinoma, cutaneous metastasis, and skin metastasis were used. The abstracts were reviewed, and articles that were associated with umbilical metastasis were excluded. Duplicate references as well as repeated publications were discarded. All of the studies that were considered to be eligible were retrieved and the final selection was based on the full article.

Our case is unique in that the cutaneous pancreatic cancer metastases were found on the labia majora. Our patient had papules on the labia majora, with diffuse swelling on the skin of the chest, abdomen, and vulva. In addition, there was oozing of chyle from the skin biopsy sites.

Chyle originates in the bowel lacteals (lymphatic capillaries that absorb dietary fats), is absorbed by the intestinal lymphatic vessels, passes through the collecting lymphatic vessels into the intestinal trunk (truncus intestinalis), and then passes through the cisterna chyli and thoracic duct to the bloodstream. If the reflux is obstructed, chylous reflux occurs; the chyle flows backward or leaks into the serosal cavity, external genitalia, lower limbs, *etc.* Chylous reflux is divided into primary and secondary types. Secondary chylous reflux is usually caused by neoplasia, trauma, inflammation, or surgery^[7]. According to the PET-CT scan, the metastatic cancer cells may have traveled to the labia majora *via* the lymphatic pathways. The abnormal lymphatic system, caused by tumor metastasis, may have been the underlying cause for the backflow of chyle to the skin. The patient was advised to undergo lymphangiography to confirm this, but declined for financial reasons.

The serum levels of tumor biomarkers CA199, CA242, and CA125 were significantly elevated in our case. It has been shown that the sensitivity and specificity of CA199 for diagnosing pancreatic cancer are 77% and 88%, respectively. Ozkan *et al*^[8] revealed that CA242 was significantly increased in 75% of pancreatic cancer patients. To sum up, Mao *et al*^[9] suggested that assessment of the combination of CA199, CA242, CEA, and CA125 levels is a simple, noninvasive, and effective method for early diagnosis of pancreatic cancer.

We present a case of pancreatic adenocarcinoma metastasizing to the vulva, with a number of flat papules. This condition is extremely rare and easy to misdiagnose.

Table 1 Review of case reports of nonumbilical cutaneous metastasis from pancreatic cancer

	Ref.	Age (yr)	Sex	Appearance	Metastatic site	Primary	Year
1	Edelstein <i>et al</i> ^[10]	60	M	Cellulitis	Face, neck	NA	1950
2	Sakai <i>et al</i>	47	M	Herpes zoster-like	No details	Head	1969
3	Sironi <i>et al</i> ^[12]	72	M	Nodule	Right thigh	Head	1991
4	Lookingbill <i>et al</i> ^[13]	No details	No details	Nodule	Abdomen	No details	1993
5	Taniguchi <i>et al</i> ^[4]	63	F	Erythematousplaques, nodule	Left axilla, chest	No details	1994
6	Ohashi <i>et al</i>	79	M	Nodule	Neck, chest, abdomen	No details	1995
7	Ohashi <i>et al</i>	65	M	Nodule	Back	No details	1995
8	Fukui <i>et al</i>	49	M	Nodule	Face, chest	No details	1995
9	Puri <i>et al</i> ^[14]	45	M	Nodule	Scalp, face, neck, back	No details	1995
10	Nakano <i>et al</i> ^[15]	80	M	Nodule	Occipital scalp	Tail	1996
11	Miyahara <i>et al</i> ^[16]	43	M	Nodule	Scalp	Uncus	1996
12	Miyahara <i>et al</i> ^[16]	65	M	Nodule	Mentum	Uncus	1996
13	Horino <i>et al</i> ^[17]	65	F	Nodule	Chest wall	Head	1999
14	Flórez <i>et al</i> ^[18]	48	M	Nodule	Buttock	Head	2000
15	Gawrieh <i>et al</i> ^[19]	45	F	Nodule	Temporal scalp	No details	2002
16	Takeuchi <i>et al</i> ^[3]	77	M	Nodule	Left axilla	Tail	2003
17	Otegbayo <i>et al</i> ^[20]	59	M	Nodule	Face, chest, abdomen, back	No details	2005
18	Jun <i>et al</i> ^[21]	68	M	Nodule	Right forearm, chest	Body, tail	2005
19	Ambro <i>et al</i> ^[22]	63	M	Nodule	Scalp	Ductal	2006
20	Takemura <i>et al</i> ^[23]	85	M	Nodule	Left temple	No details	2007
21	Hafez <i>et al</i> ^[24]	55	F	Nodule	Neck	Head	2008
22	Kimura <i>et al</i>	50	M	Nodule	Lateral abdomen	Body	2008
23	van Akkooi <i>et al</i> ^[25]	59	M	Nodule	Scalp	No details	2010
24	Bdeiri <i>et al</i> ^[1]	59	F	Nodule	Scalp	Tail	2010
25	Pontinen <i>et al</i> ^[26]	67	F	Nodule	Lower abdomen	Tail	2010
26	Saif <i>et al</i> ^[27]	46	F	Nodule	Chest, abdomen, right supraclavicular area	No details	2011
27	Horino <i>et al</i> ^[6]	58	F	Nodule	Lower abdomen	Body	2012
28	Horino <i>et al</i> ^[6]	65	F	Nodule	Lower abdomen	Tail	2012
29	Bdeiri <i>et al</i> ^[1]	70	F	Nodule	Scalp	Tail	2013
30	Kaoutzanis <i>et al</i> ^[28]	43	M	Nodule	Scalp	Head	2013
31	Zhou <i>et al</i> ^[2]	76	F	Nodule	Scalp, chest, abdomen	Tail	2014
32	Shin <i>et al</i> ^[29]	60	M	Mass	Left hip	Body	2015
33	Kotsantis <i>et al</i> ^[11]	62	M	Edema	Scrotum, trunk, chest wall	Head	2017
34	Ito <i>et al</i> ^[30]	71	F	Ulcer	Scalp	Tail	2020

NA: Not available; F: Female; M: Male.

CONCLUSION

Cutaneous metastasis from pancreatic carcinoma is a rare finding and mostly occurs around the umbilicus. Subcutaneous nodules are the most common clinical manifestation. To our knowledge, we describe the first case of cutaneous pancreatic metastasis to the vulva, with a number of flat papules. Clinicians should be aware of the possibility of metastatic cutaneous lesions in pancreatic adenocarcinoma and

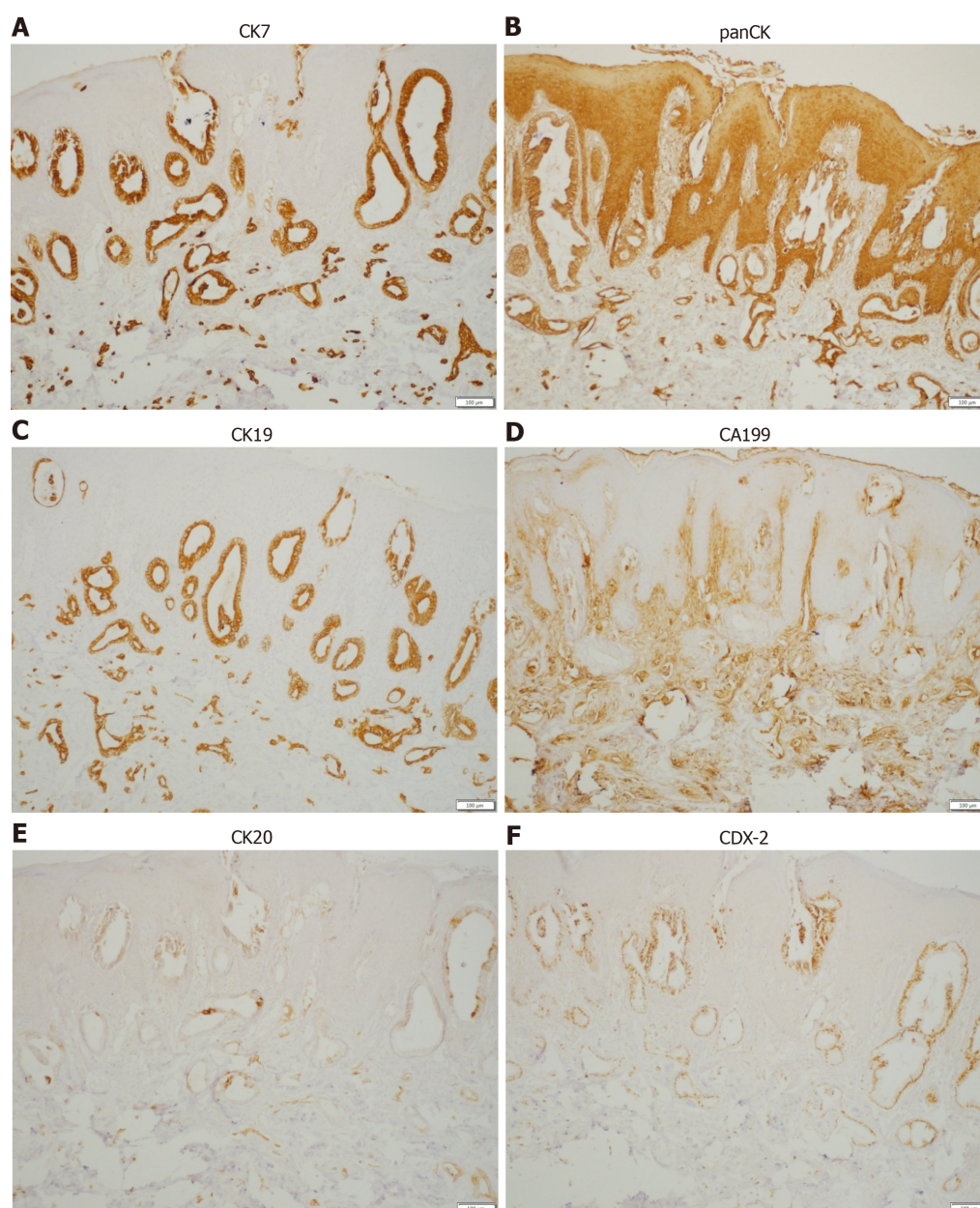


Figure 4 Neoplastic glands showing a positive reaction to immunohistochemical staining (100 \times). A: CK7 (+); B: panCK (+); C: CK19 (+); D: CA199 (+); E: CK20 (+); F: CDX-2 (+).

screen for tumor markers as promptly as possible.

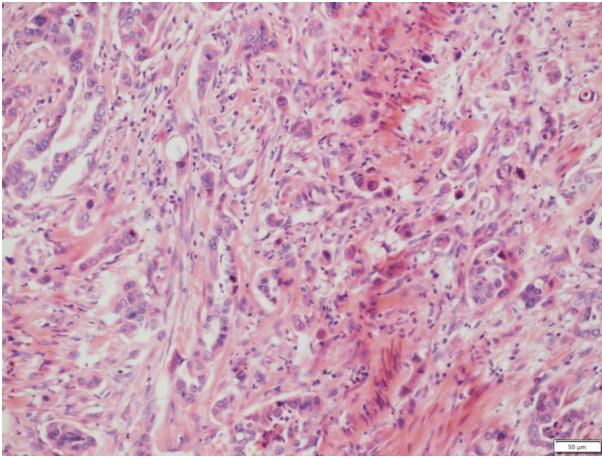


Figure 5 B-mode ultrasound-guided needle biopsy of the pancreas showing the moderately and poorly differentiated adenocarcinoma (hematoxylin-eosin staining, × 200).

REFERENCES

- 1 **Bdeiri K**, Kamar FG. Cutaneous metastasis of pancreatic adenocarcinoma as a first clinical manifestation: a case report and review of the literature. *Gastrointest Cancer Res* 2013; **6**: 61-63 [PMID: [23745161](#)]
- 2 **Zhou HY**, Wang XB, Gao F, Bu B, Zhang S, Wang Z. Cutaneous metastasis from pancreatic cancer: A case report and systematic review of the literature. *Oncol Lett* 2014; **8**: 2654-2660 [PMID: [25364444](#) DOI: [10.3892/ol.2014.2610](#)]
- 3 **Takeuchi H**, Kawano T, Toda T, Minamisono Y, Nagasaki S, Yao T, Sugimachi K. Cutaneous metastasis from pancreatic adenocarcinoma: a case report and a review of the literature. *Hepatogastroenterology* 2003; **50**: 275-277 [PMID: [12630040](#) DOI: [10.1016/j.fct.2008.12.023](#)]
- 4 **Taniguchi S**, Hisa T, Hamada T. Cutaneous metastases of pancreatic carcinoma with unusual clinical features. *J Am Acad Dermatol* 1994; **31**: 877-880 [PMID: [7525667](#) DOI: [10.1016/s0190-9622\(94\)70250-0](#)]
- 5 **Gabriele R**, Conte M, Egidi F, Borghese M. Umbilical metastases: current viewpoint. *World J Surg Oncol* 2005; **3**: 13 [PMID: [15723695](#) DOI: [10.1186/1477-7819-3-13](#)]
- 6 **Horino K**, Takamori H, Ikuta Y, Nakahara O, Chikamoto A, Ishiko T, Beppu T, Baba H. Cutaneous metastases secondary to pancreatic cancer. *World J Gastrointest Oncol* 2012; **4**: 176-180 [PMID: [22844548](#) DOI: [10.4251/wjgo.v4.i7.176](#)]
- 7 **Huang HY**, Chiu WT. Primary chylous reflux presenting with vulvar vesicles. *Arch Dermatol* 2010; **146**: 683-684 [PMID: [20566942](#) DOI: [10.1001/archdermatol.2010.122](#)]
- 8 **Ozkan H**, Kaya M, Cengiz A. Comparison of tumor marker CA 242 with CA 19-9 and carcinoembryonic antigen (CEA) in pancreatic cancer. *Hepatogastroenterology* 2003; **50**: 1669-1674 [PMID: [14571813](#) DOI: [10.1002/jcb.20532](#)]
- 9 **Mao QQ**, Yan WL, Sun X, Hu Y, Zhong L. The value of serum CA199, CA242 and CA125 in the diagnosis and prognosis of pancreatic cancer. *Biaoji Mianyi Fenxi Yu Linchunag Zazhi* 2009; **16**: 79-82 [DOI: [10.3969/j.issn.1006-1703.2009.02.006](#)]
- 10 **EDELSTEIN JM**. Pancreatic carcinoma with unusual metastasis to the skin and subcutaneous tissue simulating cellulitis. *N Engl J Med* 1950; **242**: 779-781 [PMID: [15416899](#) DOI: [10.1056/NEJM195005182422003](#)]
- 11 **Kotsantis I**, Economopoulou P, Dritsakos K, Oikonomopoulos N, Bakogeorgos M, Rapti C, Kentepozidis N. Extensive cutaneous metastases of pancreatic adenocarcinoma: a case report and review of the literature. *Clin Case Rep* 2017; **5**: 51-56 [PMID: [28096990](#) DOI: [10.1002/ccr.3.737](#)]
- 12 **Sironi M**, Radice F, Taccagni GL, Braga M, Zerbi M. Fine needle aspiration of a pancreatic oxyphilic carcinoma with pulmonary and subcutaneous metastases. *Cytopathology* 1991; **2**: 303-309 [PMID: [1724921](#) DOI: [10.1111/j.1365-2303.1991.tb00505.x](#)]
- 13 **Lookingbill DP**, Spangler N, Helm KF. Cutaneous metastases in patients with metastatic carcinoma: a retrospective study of 4020 patients. *J Am Acad Dermatol* 1993; **29**: 228-236 [PMID: [8335743](#) DOI: [10.1016/0190-9622\(93\)70173-q](#)]
- 14 **Puri AS**, Saraswat VA, Krishnani N, Salunke PN. Cutaneous metastases in pancreatic adenocarcinoma. *Indian J Pathol Microbiol* 1995; **38**: 99-101 [PMID: [8919476](#)]
- 15 **Nakano S**, Narita R, Yamamoto M, Ogami Y, Osuki M. Two cases of pancreatic cancer associated with skin metastases. *Am J Gastroenterol* 1996; **91**: 410-411 [PMID: [8607535](#) DOI: [10.2958/suizo.24.521](#)]
- 16 **Miyahara M**, Hamanaka Y, Kawabata A, Sato Y, Tanaka A, Yamamoto A, Ueno T, Nishihara K, Suzuki T. Cutaneous metastases from pancreatic cancer. *Int J Pancreatol* 1996; **20**: 127-130 [PMID: [8968868](#)]
- 17 **Horino K**, Hiraoka T, Kanemitsu K, Tsuji T, Inoue K, Tanabe D, Takamori H, Matsuoka M, Kitamura N. Subcutaneous metastases after curative resection for pancreatic carcinoma: a case report and review of the literature. *Pancreas* 1999; **19**: 406-408 [PMID: [10547202](#) DOI: [10.1097/00006676-199911000-00013](#)]
- 18 **Flórez A**, Rosón E, Sánchez-Aguilar D, Peteiro C, Toribio J. Solitary cutaneous metastasis on the buttock: a disclosing sign of pancreatic adenocarcinoma. *Clin Exp Dermatol* 2000; **25**: 201-203 [PMID: [10844494](#) DOI: [10.1046/j.1365-2230.2000.00614.x](#)]
- 19 **Gawrich S**, Massey BT, Komorowski RA. Scalp metastases as the first manifestation of pancreatic cancer.

- Dig Dis Sci* 2002; **47**: 1469-1471 [PMID: [12141802](#) DOI: [10.1023/a:1015842413562](#)]
- 20 **Otegbayo JA**, Oluwasola OA, Akere A, Yakubu A, Daramola OO, Ogun GO. Pancreatic carcinoma presenting as cutaneous nodules in a diabetic Nigerian male. *West Afr J Med* 2005; **24**: 180 [PMID: [16092324](#)]
- 21 **Jun DW**, Lee OY, Park CK, Choi HS, Yoon BC, Lee MH, Lee DH. Cutaneous metastases of pancreatic carcinoma as a first clinical manifestation. *Korean J Intern Med* 2005; **20**: 260-263 [PMID: [16295788](#) DOI: [10.3904/kjim.2005.20.3.260](#)]
- 22 **Ambro CM**, Humphreys TR, Lee JB. Epidermotropically metastatic pancreatic adenocarcinoma. *Am J Dermatopathol* 2006; **28**: 60-62 [PMID: [16456328](#) DOI: [10.1097/01.dad.0000157460.72334.fa](#)]
- 23 **Takemura N**, Fujii N, Tanaka T. Cutaneous metastasis as the first clinical manifestation of pancreatic adenocarcinoma: a case treated with gemcitabine. *J Dermatol* 2007; **34**: 662-664 [PMID: [17727372](#) DOI: [10.1111/j.1346-8138.2007.00353.x](#)]
- 24 **Hafez HZ**. Cutaneous pancreatic metastasis: a case report and review of literature. *Indian J Dermatol* 2008; **53**: 206-209 [PMID: [19882039](#) DOI: [10.4103/0019-5154.44806](#)]
- 25 **van Akkooi AC**, Dokter J, Boxma H. Unusual first presentation of metastatic pancreatic cancer as skin metastases in a burn patient. *Burns* 2010; **36**: e111-e114 [PMID: [20392566](#) DOI: [10.1016/j.burns.2009.12.004](#)]
- 26 **Pontinen T**, Melin A, Varadi G, Khanmoradi K, Chewaproug D, Kung SC, Zaki R, Ortiz J. Cutaneous metastasis of pancreatic adenocarcinoma after kidney transplant: a case report and review of the literature. *Exp Clin Transplant* 2010; **8**: 273-276 [PMID: [21143091](#)]
- 27 **Saif MW**, Brennan M, Penney R, Hotchkiss S, Kaley K. Cutaneous metastasis in a patient with pancreatic cancer. *JOP* 2011; **12**: 306-308 [PMID: [21546714](#)]
- 28 **Kaoutzanis C**, Chang MC, Abdul Khalek FJ, Kreske E. Non-umbilical cutaneous metastasis of a pancreatic adenocarcinoma. *BMJ Case Rep* 2013; **2013** [PMID: [23307465](#) DOI: [10.1136/bcr-2012-007931](#)]
- 29 **Shin WY**, Lee KY, Ahn SI, Park SY, Park KM. Cutaneous metastasis as an initial presentation of a non-functioning pancreatic neuroendocrine tumor. *World J Gastroenterol* 2015; **21**: 9822-9826 [PMID: [26361431](#) DOI: [10.3748/wjg.v21.i33.9822](#)]
- 30 **Ito H**, Tajiri T, Hiraiwa SI, Sugiyama T, Ito A, Shinma Y, Kaneko M, Anzai K, Tsuda S, Ichikawa H, Nagata J, Kojima S, Watanabe N. A Case of Rare Cutaneous Metastasis from Advanced Pancreatic Cancer. *Case Rep Oncol* 2020; **13**: 49-54 [PMID: [32110219](#) DOI: [10.1159/000505322](#)]



Published by **Baishideng Publishing Group Inc**
7041 Koll Center Parkway, Suite 160, Pleasanton, CA 94566, USA

Telephone: +1-925-3991568

E-mail: bpgoffice@wjgnet.com

Help Desk: <https://www.f6publishing.com/helpdesk>

<https://www.wjgnet.com>

