

# World Journal of *Clinical Cases*

*World J Clin Cases* 2020 December 26; 8(24): 6213-6545



## MINIREVIEWS

- 6213 Role of gut microbiome in regulating the effectiveness of metformin in reducing colorectal cancer in type 2 diabetes

*Huang QY, Yao F, Zhou CR, Huang XY, Wang Q, Long H, Wu QM*

## ORIGINAL ARTICLE

## Retrospective Cohort Study

- 6229 Impact factors of lymph node retrieval on survival in locally advanced rectal cancer with neoadjuvant therapy

*Mei SW, Liu Z, Wang Z, Pei W, Wei FZ, Chen JN, Wang ZJ, Shen HY, Li J, Zhao FQ, Wang XS, Liu Q*

## Retrospective Study

- 6243 Three-year follow-up of Coats disease treated with conbercept and 532-nm laser photocoagulation

*Jiang L, Qin B, Luo XL, Cao H, Deng TM, Yang MM, Meng T, Yang HQ*

- 6252 Virus load and virus shedding of SARS-CoV-2 and their impact on patient outcomes

*Chen PF, Yu XX, Liu YP, Ren D, Shen M, Huang BS, Gao JL, Huang ZY, Wu M, Wang WY, Chen L, Shi X, Wang ZQ, Liu YX, Liu L, Liu Y*

- 6264 Risk factors for *de novo* hepatitis B during solid cancer treatment

*Sugimoto R, Furukawa M, Senju T, Aratake Y, Shimokawa M, Tanaka Y, Inada H, Noguchi T, Lee L, Miki M, Maruyama Y, Hashimoto R, Hisano T*

- 6274 Cause analysis and reoperation effect of failure and recurrence after epiblepharon correction in children

*Wang Y, Zhang Y, Tian N*

## Clinical Trials Study

- 6282 Effects of different acupuncture methods combined with routine rehabilitation on gait of stroke patients

*Lou YT, Yang JJ, Ma YF, Zhen XC*

## Observational Study

- 6296 Application of endoscopic submucosal dissection in duodenal space-occupying lesions

*Li XY, Ji KY, Qu YH, Zheng JJ, Guo YJ, Zhang CP, Zhang KP*

- 6306 Early renal injury indicators can help evaluate renal injury in patients with chronic hepatitis B with long-term nucleos(t)ide therapy

*Ji TT, Tan N, Lu HY, Xu XY, Yu YY*

**Prospective Study**

- 6315** Neoadjuvant chemoradiotherapy plus surgery in the treatment of potentially resectable thoracic esophageal squamous cell carcinoma  
*Yan MH, Hou XB, Cai BN, Qu BL, Dai XK, Liu F*

**CASE REPORT**

- 6322** Uterine rupture in patients with a history of multiple curettages: Two case reports  
*Deng MF, Zhang XD, Zhang QF, Liu J*
- 6330** Pleural effusion and ascites in extrarenal lymphangiectasia caused by post-biopsy hematoma: A case report  
*Lin QZ, Wang HE, Wei D, Bao YF, Li H, Wang T*
- 6337** Eighty-year-old man with rare chronic neutrophilic leukemia caused by CSF3R T618I mutation: A case report and review of literature  
*Li YP, Chen N, Ye XM, Xia YS*
- 6346** Sigmoid colon duplication with ectopic immature renal tissue in an adult: A case report  
*Namgung H*
- 6353** Paraplegia from spinal intramedullary tuberculosis: A case report  
*Qu LM, Wu D, Guo L, Yu JL*
- 6358** Confocal laser endomicroscopy distinguishing benign and malignant gallbladder polyps during choledochoscopic gallbladder-preserving polypectomy: A case report  
*Tang BF, Dang T, Wang QH, Chang ZH, Han WJ*
- 6364** Sclerosing stromal tumor of the ovary with masculinization, Meig's syndrome and CA125 elevation in an adolescent girl: A case report  
*Chen Q, Chen YH, Tang HY, Shen YM, Tan X*
- 6373** Primary pulmonary malignant melanoma diagnosed with percutaneous biopsy tissue: A case report  
*Xi JM, Wen H, Yan XB, Huang J*
- 6380** SRY-negative 45,X/46,XY adult male with complete masculinization and infertility: A case report and review of literature  
*Wu YH, Sun KN, Bao H, Chen YJ*
- 6389** Refractory case of ulcerative colitis with idiopathic thrombocytopenic purpura successfully treated by Janus kinase inhibitor tofacitinib: A case report  
*Komeda Y, Sakurai T, Sakai K, Morita Y, Hashimoto A, Nagai T, Hagiwara S, Matsumura I, Nishio K, Kudo M*
- 6396** Immunotherapies application in active stage of systemic lupus erythematosus in pregnancy: A case report and review of literature  
*Xiong ZH, Cao XS, Guan HL, Zheng HL*

- 6408** Minimally invasive maxillary sinus augmentation with simultaneous implantation on an elderly patient: A case report  
*Yang S, Yu W, Zhang J, Zhou Z, Meng F, Wang J, Shi R, Zhou YM, Zhao J*
- 6418** Congenital nephrogenic diabetes insipidus due to the mutation in *AVPR2* (c.541C>T) in a neonate: A case report  
*Lin FT, Li J, Xu BL, Yang XX, Wang F*
- 6425** Primary gastric melanoma in a young woman: A case report  
*Long GJ, Ou WT, Lin L, Zhou CJ*
- 6432** Extreme venous letting and cupping resulting in life-threatening anemia and acute myocardial infarction: A case report  
*Jang AY, Suh SY*
- 6437** Novel conservative treatment for peritoneal dialysis-related hydrothorax: Two case reports  
*Dai BB, Lin BD, Yang LY, Wan JX, Pan YB*
- 6444** Clinical characteristics of pulmonary cryptococcosis coexisting with lung adenocarcinoma: Three case reports  
*Zheng GX, Tang HJ, Huang ZP, Pan HL, Wei HY, Bai J*
- 6450** Fracture of the scapular neck combined with rotator cuff tear: A case report  
*Chen L, Liu CL, Wu P*
- 6456** Synchronous colonic mucosa-associated lymphoid tissue lymphoma found after surgery for adenocarcinoma: A case report and review of literature  
*Li JJ, Chen BC, Dong J, Chen Y, Chen YW*
- 6465** Novel mutation in the *ASXL3* gene in a Chinese boy with microcephaly and speech impairment: A case report  
*Li JR, Huang Z, Lu Y, Ji QY, Jiang MY, Yang F*
- 6473** Recurrent thrombosis in the lower extremities after thrombectomy in a patient with polycythemia vera: A case report  
*Jiang BP, Cheng GB, Hu Q, Wu JW, Li XY, Liao S, Wu SY, Lu W*
- 6480** Status epilepticus as an initial manifestation of hepatic encephalopathy: A case report  
*Cui B, Wei L, Sun LY, Qu W, Zeng ZG, Liu Y, Zhu ZJ*
- 6487** Delayed diagnosis of prosopagnosia following a hemorrhagic stroke in an elderly man: A case report  
*Yuan Y, Huang F, Gao ZH, Cai WC, Xiao JX, Yang YE, Zhu PL*
- 6499** Oral myiasis after cerebral infarction in an elderly male patient from southern China: A case report  
*Zhang TZ, Jiang Y, Luo XT, Ling R, Wang JW*
- 6504** Rare case of drain-site hernia after laparoscopic surgery and a novel strategy of prevention: A case report  
*Gao X, Chen Q, Wang C, Yu YY, Yang L, Zhou ZG*

- 6511** Extracorporeal shock wave therapy treatment of painful hematoma in the calf: A case report  
*Jung JW, Kim HS, Yang JH, Lee KH, Park SB*
- 6517** Takotsubo cardiomyopathy associated with bronchoscopic operation: A case report  
*Wu BF, Shi JR, Zheng LR*
- 6524** Idiopathic adulthood ductopenia with elevated transaminase only: A case report  
*Zhang XC, Wang D, Li X, Hu YL, Wang C*
- 6529** Successful endovascular treatment with long-term antibiotic therapy for infectious pseudoaneurysm due to *Klebsiella pneumoniae*: A case report  
*Wang TH, Zhao JC, Huang B, Wang JR, Yuan D*
- 6537** Primary duodenal tuberculosis misdiagnosed as tumor by imaging examination: A case report  
*Zhang Y, Shi XJ, Zhang XC, Zhao XJ, Li JX, Wang LH, Xie CE, Liu YY, Wang YL*

**ABOUT COVER**

Peer-Reviewer of *World Journal of Clinical Cases*, Dr. Adonis Protopapas is a gastroenterology Resident at the first Propaedeutic Department of Internal Medicine of the Aristotle University of Thessaloniki (Greece), located at the A.H.E.P.A Hospital. He earned his Bachelor's degree in 2015 from the Democritus University of Thrace, followed by three Master's of Science degrees, with specializations in clinic pharmacology, medical research methodology, and healthcare management. His research interests are mainly focused on the area of hepatology, although he also participates in various projects related to endoscopy and inflammatory bowel disease. He is particularly fascinated by research on cirrhosis and its complications. (L-Editor: Filipodia)

**AIMS AND SCOPE**

The primary aim of *World Journal of Clinical Cases* (*WJCC*, *World J Clin Cases*) is to provide scholars and readers from various fields of clinical medicine with a platform to publish high-quality clinical research articles and communicate their research findings online.

*WJCC* mainly publishes articles reporting research results and findings obtained in the field of clinical medicine and covering a wide range of topics, including case control studies, retrospective cohort studies, retrospective studies, clinical trials studies, observational studies, prospective studies, randomized controlled trials, randomized clinical trials, systematic reviews, meta-analysis, and case reports.

**INDEXING/ABSTRACTING**

The *WJCC* is now indexed in Science Citation Index Expanded (also known as SciSearch®), Journal Citation Reports/Science Edition, PubMed, and PubMed Central. The 2020 Edition of Journal Citation Reports® cites the 2019 impact factor (IF) for *WJCC* as 1.013; IF without journal self cites: 0.991; Ranking: 120 among 165 journals in medicine, general and internal; and Quartile category: Q3.

**RESPONSIBLE EDITORS FOR THIS ISSUE**

Production Editor: Ji-Hong Liu; Production Department Director: Xiang Li; Editorial Office Director: Jin-Lai Wang.

**NAME OF JOURNAL**

*World Journal of Clinical Cases*

**ISSN**

ISSN 2307-8960 (online)

**LAUNCH DATE**

April 16, 2013

**FREQUENCY**

Semimonthly

**EDITORS-IN-CHIEF**

Dennis A Bloomfield, Sandro Vento, Bao-gan Peng

**EDITORIAL BOARD MEMBERS**

<https://www.wjgnet.com/2307-8960/editorialboard.htm>

**PUBLICATION DATE**

December 26, 2020

**COPYRIGHT**

© 2020 Baishideng Publishing Group Inc

**INSTRUCTIONS TO AUTHORS**

<https://www.wjgnet.com/bpg/gerinfo/204>

**GUIDELINES FOR ETHICS DOCUMENTS**

<https://www.wjgnet.com/bpg/GerInfo/287>

**GUIDELINES FOR NON-NATIVE SPEAKERS OF ENGLISH**

<https://www.wjgnet.com/bpg/gerinfo/240>

**PUBLICATION ETHICS**

<https://www.wjgnet.com/bpg/GerInfo/288>

**PUBLICATION MISCONDUCT**

<https://www.wjgnet.com/bpg/gerinfo/208>

**ARTICLE PROCESSING CHARGE**

<https://www.wjgnet.com/bpg/gerinfo/242>

**STEPS FOR SUBMITTING MANUSCRIPTS**

<https://www.wjgnet.com/bpg/GerInfo/239>

**ONLINE SUBMISSION**

<https://www.f6publishing.com>

## Retrospective Study

## Three-year follow-up of Coats disease treated with conbercept and 532-nm laser photocoagulation

Li Jiang, Bo Qin, Xiao-Ling Luo, He Cao, Ting-Ming Deng, Ming-Ming Yang, Ting Meng, Hui-Qin Yang

**ORCID number:** Li Jiang 0000-0002-2478-620X; Bo Qin 0000-0002-7653-272X; Xiao-Ling Luo 0000-0001-7599-9822; He Cao 0000-0002-7540-0661; Ting-Ming Deng 0000-0001-8032-8281; Ming-Ming Yang 0000-0002-5550-729; Ting Meng 0000-0002-3390-5178; Hui-Qin Yang 0000-0001-9210-4648.

**Author contributions:** Jiang L was responsible for the conception of the article, case analysis, statistics and article writing and was the main contributor to the writing of the manuscript; Qin B and Luo XL were responsible for the guidance and revision of the article; Cao H was responsible for assisting with the query of literature and analysis of statistical results; Deng TM collected and reviewed follow-up records of major cases; Yang MM, Meng T and Yang HQ were responsible for the collection of case data and assisting with document search; All authors have read and approved the manuscript.

**Supported by** the Shenzhen Municipal Health and Family Planning System Research Project, No. SZFZ2017085.

**Institutional review board**

**statement:** The study was approved by the ethics committee of Shenzhen People's Hospital (No. LL-KY-2020238).

**Li Jiang, Xiao-Ling Luo, He Cao, Ting-Ming Deng, Ming-Ming Yang, Ting Meng, Hui-Qin Yang,** Department of Ophthalmology, Shenzhen People's Hospital, Second Clinical Medical College of Jinan University, Shenzhen 518020, Guangdong Province, China

**Bo Qin,** Department of Ophthalmology, Shenzhen Aier Eye Hospital Affiliated to Jinan University, Shenzhen 518032, Guangdong Province, China

**Corresponding author:** Bo Qin, MD, Doctor, Shenzhen Aier Eye Hospital Affiliated to Jinan University, No. 1017 Dongmen North Road, Luohu District, Shenzhen 518020, Guangdong Province, China. [jiang.li@szhospital.com](mailto:jiang.li@szhospital.com)

## Abstract

**BACKGROUND**

Coats disease is an idiopathic exudative outer retinopathy caused by abnormal retinal vascular development.

**AIM**

To evaluate the long-term outcomes of intravitreal conbercept injection with laser photocoagulation as a treatment for Coats disease in adults.

**METHODS**

This retrospective case series study included patients diagnosed with Coats disease and treated with intravitreal conbercept injection and 532-nm laser photocoagulation at the Ophthalmology Department of Shenzhen People's Hospital between January 2016 and January 2017. Best-corrected visual acuity (BCVA) measurements, noncontact tonometry, ophthalmoscopy, fundus photography, fundus fluorescein angiography and optical coherence tomography were performed before treatment and at 1 wk, 1 mo, 3 mo, 6 mo, 9 mo, 12 mo, 24 mo and 36 mo after therapy. Best-corrected visual acuity was measured using the early treatment of diabetic retinopathy study chart.

**RESULTS**

The study included eight eyes of 8 patients (7 men) aged  $36.10 \pm 6.65$  years. The average BCVA of the affected eye before treatment was  $51.17 \pm 15.15$  letters (range, 28–70 letters), and the average central macular thickness was  $303.30 \pm 107.87 \mu\text{m}$  (range, 221–673  $\mu\text{m}$ ). Four eyes were injected once, three were injected twice, and one was injected three times. Average follow-up duration was  $37.33 \pm 2.26$  mo. Average BCVA of the affected eye was  $51.17 \pm 15.15$  letters before



# **Informed consent statement:**

Patients were not required to give informed consent to the study because the analysis used anonymous clinical data that were obtained after each patient agreed to treatment by written consent.

# **Conflict-of-interest statement:**

The authors declare that they have no competing interests.

# **Data sharing statement:**

Not applicable.

# **Open-Access:**

This article is an open-access article that was selected by an in-house editor and fully peer-reviewed by external reviewers. It is distributed in accordance with the Creative Commons Attribution NonCommercial (CC BY-NC 4.0) license, which permits others to distribute, remix, adapt, build upon this work non-commercially, and license their derivative works on different terms, provided the original work is properly cited and the use is non-commercial. See: <http://creativecommons.org/licenses/by-nc/4.0/>

# **Manuscript source:**

Unsolicited manuscript

# **Specialty type:**

Medicine, research and experimental

# **Country/Territory of origin:**

China

# **Peer-review report's scientific quality classification**

Grade A (Excellent): 0  
Grade B (Very good): B  
Grade C (Good): C  
Grade D (Fair): 0  
Grade E (Poor): 0

# **Received:**

August 4, 2020

# **Peer-review started:**

August 4, 2020

# **First decision:**

August 21, 2020

# **Revised:**

September 22, 2020

# **Accepted:**

November 2, 2020

# **Article in press:**

November 2, 2020

# **Published online:**

December 26, 2020

# **P-Reviewer:**

Buchaim RL,  
Mehdipour P

# **S-Editor:**

Zhang H

# **L-Editor:**

Filipodia

treatment and was increased by  $13.50 \pm 3.20$ ,  $16.25 \pm 7.73$ ,  $18.25 \pm 8.96$ ,  $18.03 \pm 5.27$ ,  $18.63 \pm 3.35$ ,  $19.75 \pm 6.96$ ,  $18.05 \pm 5.36$  and  $17.88 \pm 3.45$  letters at 1 wk, 1 mo, 3 mo, 6 mo, 9 mo, 12 mo, 24 mo and 36 mo after treatment, respectively ( $P < 0.01$ ). The patients showed varying degrees of subretinal fluid resorption after treatment. None of the patients had serious complications such as increased intraocular pressure, development/progression of cataracts, endophthalmitis or retinal detachment.

# **CONCLUSION**

Intravitreal injection of conbercept combined with 532-nm laser photocoagulation may be a feasible treatment for Coats disease in adult patients.

**Key Words:** Coats disease; Adults; Retinal telangiectasis; Conbercept; Laser therapy; Retrospective study

©The Author(s) 2020. Published by Baishideng Publishing Group Inc. All rights reserved.

**Core Tip:** Coats disease is an idiopathic exudative outer retinopathy caused by abnormal retinal vascular development. Intravitreal injection of conbercept combined with 532-nm laser photocoagulation may be a feasible treatment for Coats disease in adult patients.

**Citation:** Jiang L, Qin B, Luo XL, Cao H, Deng TM, Yang MM, Meng T, Yang HQ. Three-year follow-up of Coats disease treated with conbercept and 532-nm laser photocoagulation. *World J Clin Cases* 2020; 8(24): 6243-6251

**URL:** <https://www.wjgnet.com/2307-8960/full/v8/i24/6243.htm>

**DOI:** <https://dx.doi.org/10.12998/wjcc.v8.i24.6243>

# **INTRODUCTION**

Coats disease is an idiopathic exudative outer retinopathy caused by abnormal retinal vascular development<sup>[1,2]</sup>. The main clinical features of Coats disease are dilated retinal capillaries, miliary or small aneurysms and retinal and subretinal exudation<sup>[1,2]</sup>. The estimated incidence of Coats disease in the population is 0.09 per 100000 persons, and males are more commonly affected than females<sup>[3]</sup>. The disorder usually affects adolescents with a mean age at presentation of around 12 years<sup>[3]</sup>. However, a recent study reported that 7% of cases occur in adults (mainly males) with an onset age of 43–50 years, and the incidence of monocularly was 93.3%-100.0%<sup>[4]</sup>. Standard treatments for Coats disease include laser therapy, cryotherapy and surgical techniques such as subretinal fluid drainage and vitrectomy<sup>[5]</sup>.

Recent studies have shown that patients with Coats disease have elevated levels of vascular endothelial growth factor (VEGF) in the aqueous humor, vitreous and subretinal fluid, suggesting that a disorder of VEGF-mediated vascular regeneration may be involved in the pathogenesis of Coats disease<sup>[6-9]</sup>. It has been suggested that ischemia around a region of unperfused retinal capillaries may lead to VEGF upregulation that increases the permeability of dilated capillaries and causes exudation of lipoproteins below the retina, resulting in edema and exudative retinal detachment<sup>[6-9]</sup>. There has been increasing interest in the use of anti-VEGF agents as an adjunct treatment for Coats disease<sup>[1,2,10]</sup>. Several clinical studies have reported that the intravitreal injection of a VEGF-binding antibody (such as bevacizumab or ranibizumab) or aptamer (pegaptanib) exerts beneficial effects in patients with Coats disease, including a reduction in exudation and edema and an improvement in visual acuity<sup>[11-15]</sup>.

Conbercept is a recombinant fusion protein comprising extracellular domain 2 of VEGF receptor-1, extracellular domains 3 and 4 of VEGF receptor-2 and the Fc region of human IgG1<sup>[16]</sup>. This fusion protein binds VEGF with high affinity, has a long half-life in the vitreous and blocks all isoforms of VEGF-A, VEGF-B, VEGF-C and placental growth factor<sup>[16]</sup>. Conbercept has been shown to be an effective treatment for retinal diseases such as diabetic retinopathy-induced macular edema<sup>[17,18]</sup> and age-related



P-Editor: Liu JH



macular degeneration<sup>[19-22]</sup>. However, to the best of our knowledge, only one previous study has investigated the use of conbercept as an adjunct treatment to laser therapy in the management of Coats disease<sup>[23]</sup>.

The aim of this retrospective case series study was to summarize the clinical outcomes of adult patients who were diagnosed with Coats disease at our ophthalmology department and treated with intravitreal injection of conbercept in combination with laser photocoagulation.

## MATERIALS AND METHODS

### Patients

This retrospective case series study included patients diagnosed with Coats disease and treated with intravitreal injection of conbercept and laser photocoagulation at the Department of Ophthalmology of Shenzhen People's Hospital between January 2016 and January 2017. The inclusion criteria were: (1) Age > 18 years; (2) Newly diagnosed with Coats disease; and (3) Treated with intravitreal injection of conbercept and laser photocoagulation. Coats disease was diagnosed according to the results of the fundus examination (the presence of abnormal dilated retinal blood vessels and retinal interstitial or subretinal exudation with or without retinal detachment), fluorescein fundus angiography (FFA; typical dilatation of retinal capillaries and small blood vessels) and optical coherence tomography (OCT; characteristic features such as retinal thickening, exudation and subretinal fluid)<sup>[24]</sup>. The exclusion criteria were: (1) Other eye diseases such as age-related macular degeneration; and (2) Complications such as severe refractive interstitial opacity or vitreous hemorrhage that impaired observation of the fundus.

The severity of Coats disease in each patient was classified as stage 1 (retinal capillary dilation only), stage 2A (retinal capillary dilation and subretinal exudation outside the central fovea), stage 2B (retinal capillary dilation and exudation inside the central fovea), stage 3A (incomplete retinal detachment), stage 3B (complete retinal detachment), stage 4 (total retinal detachment with secondary glaucoma) or stage 5 (the terminal stage of eyeball atrophy)<sup>[24]</sup>.

The study was approved by the ethics committee of Shenzhen People's Hospital, No. LL-KY-2020238.

### Treatment

Written consent was obtained from each patient after they and their families had been fully informed about the treatment strategy (intravitreal injection of conbercept combined with laser photocoagulation) and potential adverse effects. A standard method was used for intravitreal injection of conbercept into the affected eye. Before treatment, 0.5% levofloxacin eye drops were administered as a local anti-inflammatory therapy. The same doctor, who had a third-level surgery qualification, performed all the procedures. The patient was placed in a supine position in the operating room. Tropicamide was used for mydriasis, and oxybuprocaine hydrochloride was applied for surface anesthesia. Disinfection and surgical draping were performed routinely according to the requirements of internal eye surgery. A protective film was pasted, an eyelid opener was used to open the eyelids, and the conjunctival sac was washed with diluted povidone iodine. A 30-gauge needle was inserted into the flat part of the ciliary body at a distance of 3.5–4 mm from the limbus. The intravitreal cavity was injected with 0.5 mg conbercept (trade name, Langmu; Chengdu Kanghong Biological Co., Ltd, China) administered as 0.05 mL of a 10 mg/mL solution. Gentle pressure was applied with a cotton swab for 10 s to prevent reflux. At the end of the procedure, light sensation was checked, tobramycin-dexamethasone eye ointment was applied, and the eye was covered with a blindfold. Postoperatively, 0.5% levofloxacin eye drops were given for 3 d as prophylaxis against bacterial infection. Subsequently, the anterior segment of the eye was examined for signs of an inflammatory reaction, intraocular pressure was measured, and fundus examination and FFA were performed. Based on the FFA results, 532-nm laser photocoagulation was carried out after conbercept injection to block retinal aneurysms, abnormally dilated capillaries or capillaries without perfusion. The laser equipment used in this study was Lumenis Vision One. Retinal laser photocoagulation was operated routinely with a 532-nm light. The size of the spot was 200  $\mu$ m, the energy was 150 MW, and the duration was 200 ms.

### Follow-up

Periodic reviews were conducted postoperatively at 1 wk, 1 mo, 3 mo, 6 mo, 9 mo, 12 mo and annually thereafter. Changes in the condition of the eye were used to determine whether the treatment needed to be repeated.

### Data collection

Clinical data were extracted from the medical records. Best-corrected visual acuity (BCVA) was measured using the early treatment of diabetic retinopathy study chart. Intraocular pressure was measured with a noncontact tonometer (NT-530; Nidek Co., Ltd, Japan). Fundus color photography and FFA examinations were performed using a TRC-50DX retinal camera (Topcon Medical Systems Inc., Japan). Spectral-domain OCT was carried out with a Spectralis system (Heidelberg Engineering GmbH, Germany). The central macular thickness was measured in high-definition scanning mode. The change in vision at each follow-up was evaluated as follows: an increase of  $\geq 15$  in the number of letters in the chart was considered a substantial improvement in vision; an increase of 5–14 was considered an improvement in vision; an increase or decrease of  $< 5$  was considered stable vision; a decrease of 5–14 was considered a worsening of vision; and a decrease of  $\geq 15$  was considered a substantial worsening of vision<sup>[25]</sup>.

### Statistical analysis

SPSS 23.0 (IBM Corp., Armonk, NY, United States) was used for the statistical analyses. Measurement data are expressed as mean  $\pm$  standard deviation values. BCVA was compared between time points using repeated-measures analysis of variance and Fisher's LSD post-hoc test.  $P < 0.05$  was considered statistically significant.

## RESULTS

### Clinical characteristics of the study participants

The study included eight eyes of 8 patients (7 men, 87.5%) aged  $36.10 \pm 6.65$  years (range, 27–51 years). The clinical characteristics of the study participants are summarized in Table 1. The average BCVA of the affected eye before treatment was  $51.17 \pm 15.15$  letters (range, 28–70 letters), and the average central macular thickness was  $303.30 \pm 107.87$   $\mu\text{m}$  (range, 221–673  $\mu\text{m}$ ). Intraocular pressure was normal in all affected eyes. The average number of injections in the affected eyes was  $1.37 \pm 0.92$ : four eyes were injected once, three eyes were injected twice, and one eye was injected thrice. The average follow-up duration was  $37.33 \pm 2.26$  mo (range, 34–39 mo).

### Comparison of BCVA before and after treatment

There was a substantial improvement in vision in four eyes (50.0%), an improvement in vision in three eyes (37.5%) and stable vision in one eye (12.5%). Table 2 presents the BCVA before treatment and at 1 wk, 1 mo, 3 mo, 6 mo, 9 mo, 1 year, 2 years and 3 years after treatment. There was a significant upward trend in the BCVA ( $P\text{-trend}_{\text{linear}} < 0.001$ ). Compared to the pretreatment value, the average BCVA at 1 wk, 1 mo, 3 mo, 6 mo, 9 mo, 1 year, 2 years and 3 years after treatment increased by  $13.50 \pm 3.20$ ,  $16.25 \pm 7.73$ ,  $18.25 \pm 8.96$ ,  $18.03 \pm 5.27$ ,  $18.63 \pm 3.35$ ,  $19.75 \pm 6.96$ ,  $18.05 \pm 5.36$  and  $17.88 \pm 3.45$  letters, respectively ( $P < 0.01$  for all pairwise comparisons; Figure 1). The number of letters by which the average BCVA increased at 1 mo after the treatment showed no significant difference compared to that at 3 mo, 12 mo and 24 mo post-treatment and at the final follow-up ( $P > 0.05$ ), suggesting that 1 mo after treatment was the critical period for recovery of visual acuity.

### Comparison of subretinal edema before and after treatment

Only one of the patients in this study had macular lesions and developed macular edema. The central macular thickness in this patient was 673  $\mu\text{m}$  before treatment but decreased to 587  $\mu\text{m}$ , 372  $\mu\text{m}$ , 322  $\mu\text{m}$ , 267  $\mu\text{m}$ , 221  $\mu\text{m}$  and 208  $\mu\text{m}$  at 1 wk, 1 mo, 3 mo, 1 year, 2 years and 3 years after treatment, respectively. Macular edema was substantially improved at the final follow-up. In the other patients, treatment led to varying degrees of subretinal fluid resorption and a decrease in retinal thickness (a representative case is shown in Figure 2).

Table 1 Clinical characteristics of the study participants

Case no.	Sex/age in yr/eye	Stage	Comorbidity	Alcohol/smoking status	Quadrants of telangiectasia	No. of injections	No. of laser therapies	BCVA baseline	BCVA 1 wk	BCVA 1 mo	BCVA 3 mo	BCVA 6 mo	BCVA 9 mo	BCVA 12 mo	BCVA 24 mo	BCVA 36 mo	Termination
1	M/31/os	2A	None	Smoker	3	2	1	60	70	68	75	75	74	72	66	65	65
2	M/35/os	2A	None	Drinker	2	1	1	55	70	75	70	70	70	75	80	76	76
3	M/45/od	2A	HTN.	Drinker	2	1	1	28	40	45	50	53	55	55	53	55	55
4	M/29/os	2A	None	None	3	1	2	39	55	65	60	58	60	60	58	62	62
5	M/33/od	2B	None	None	3	2	1	55	70	70	75	75	75	77	75	75	75
6	F/32/od	2B	None	None	3	2	2	70	78	75	78	78	80	80	77	75	75
7	M/35/os	2B	None	Drinker	3	3	2	56	70	75	78	75	75	78	75	75	75
8	M/37/od	2A	Cervical spondylosis	Smoker	2	1	1	54	72	74	77	77	77	77	78	77	77

BCVA: Best-corrected visual acuity; HTN.: Hypertension; os: Oculus sinister; od: Oculus dexter.

### Complications

No patients had serious complications such as increased intraocular pressure, development/progression of cataracts, endophthalmitis or retinal detachment.

## DISCUSSION

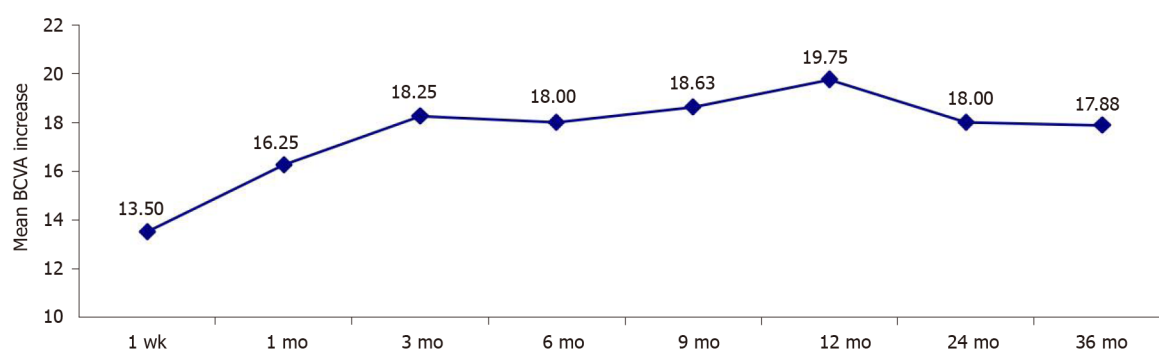
An important finding of this study was that adult patients with Coats disease exhibited significant improvements in BCVA that were maintained for at least 3 years after treatment with intravitreal injection of conbercept and laser photocoagulation. Furthermore, the treatment resulted in the resorption of subretinal fluid. Notably, no patients had serious complications such as increased intraocular pressure, development/progression of cataracts, endophthalmitis or retinal detachment. Our findings suggest that intravitreal injection of conbercept combined with 532-nm laser photocoagulation may be a feasible treatment for Coats disease in adult patients.

Coats disease is more common in men and is usually monocular. The average age of onset is 8-16 years<sup>[26]</sup>; hence, Coats disease is rarely diagnosed in adults. It can be challenging to distinguish Coats disease from other ocular diseases such as exudative age-related macular degeneration, diabetic retinopathy and retinal vasculitis. We observed that Coats disease in adulthood has similar fundal manifestations to Coats disease of childhood onset, although FFA showed that the abnormal expansion of the

**Table 2** Best-corrected visual acuity

Time of measurement	Best-corrected visual acuity	<i>P</i> (vs pretreatment value)
Pretreatment	52.12 ± 12.93	
1 wk after treatment	65.63 ± 12.19	< 0.001
1 mo after treatment	68.38 ± 10.17	< 0.001
3 mo after treatment	70.38 ± 10.18	< 0.001
6 mo after treatment	70.13 ± 9.42	< 0.001
9 mo after treatment	70.75 ± 8.75	< 0.001
12 mo after treatment	71.88 ± 9.28	< 0.001
24 mo after treatment	70.13 ± 9.98	< 0.001
36 mo after treatment	70.01 ± 8.23	< 0.001
	<i>P</i> -trend <sub>linear</sub> < 0.001	

Data are presented as mean ± standard deviation.

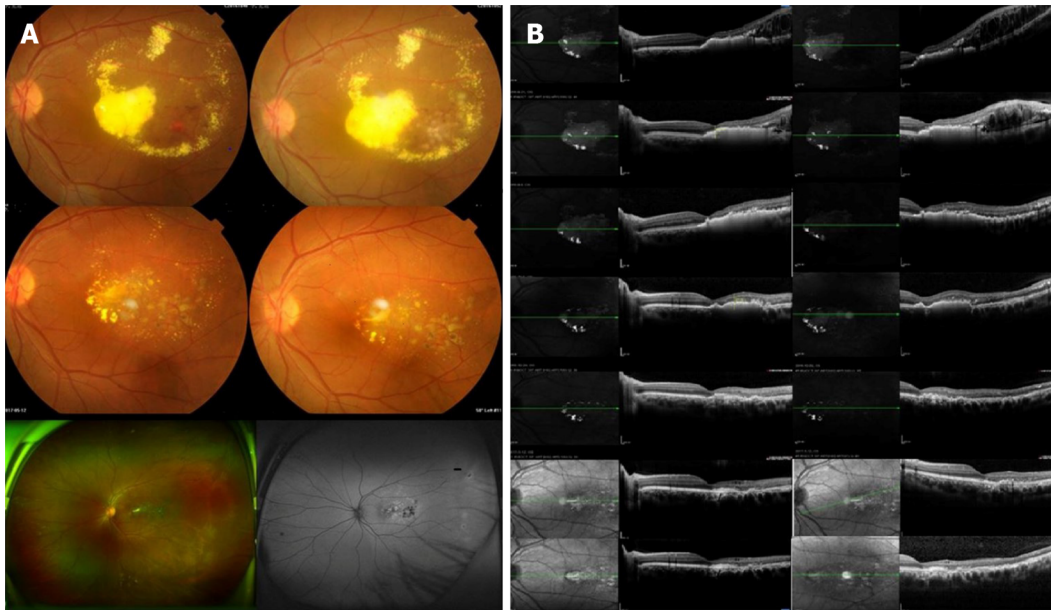


**Figure 1** Mean increase in the best-corrected visual acuity from the pretreatment value. BCVA: Best-corrected visual acuity.

retinal capillaries was limited and mostly confined to the temporal retina. Only one patient in this study had an affected macula, which resulted in local superficial retinal detachment. Our observations are similar to those reported previously<sup>[27]</sup>, suggesting that adult patients with Coats disease have a limited disease type with slow progression, mild macular damage and a good visual prognosis. Otani *et al*<sup>[28]</sup> followed two adult patients with Coats disease for more than 10 years: 1 patient showed a reduction in subretinal exudation within 1 year after retinal laser photocoagulation and an improvement in vision that was maintained for 11 years; the other patient exhibited increased exudation at 1 mo after photocoagulation and retinal detachment at 2 mo, but these subsequently resolved to result in visual improvement that was maintained for 10 years.

There are various management strategies for Coats disease, and the decision whether to use a single therapy or combination of treatments is made according to the disease stage. The pathogenesis of Coats disease involves abnormal dilatation and enhanced permeability of retinal vessels leading to vascular leakage. It is thought that VEGF may play an important role in these pathogenetic mechanisms, and several studies have reported that VEGF concentration is significantly increased in the affected eyes of patients with Coats disease<sup>[6-9]</sup>. Intravitreal injection of anti-VEGF drugs can reduce VEGF concentration, stabilize abnormal blood vessels and promote the resorption of subretinal effusion and exudation. Numerous clinical investigations have found that the intravitreal injection of a VEGF-binding agent (such as bevacizumab, ranibizumab or pegaptanib) can reduce exudation and edema and improve visual acuity in patients with Coats disease<sup>[29-31]</sup>. However, there is no current consensus on the choice, dosage and timing of anti-VEGF drug in the treatment of Coats disease, and research in this area is still in the exploratory stage.

Only one previous study has described the use of conbercept in the management of Coats disease<sup>[23]</sup>. The combination of intravitreal injection of conbercept with laser



**Figure 2** Coats disease of the left eye treated with conbercept combined with 532-laser photocoagulation. A: Fundus photographs of the patient's eye before treatment and at 1 mo, 1 yr and 2 yrs after treatment as well as at the last follow-up; B: Changes in central retinal thickness and subretinal fluid before treatment and at 1 wk, 1 mo, 3 mo, 1 yr and 2 yrs after treatment as well as at the final follow-up. The retinal interstitial layer and subretinal regions showed gradual reductions in edema and exudation.

therapy resulted in a significant improvement in BCVA after 2 years with no serious adverse effects. The above observations are consistent with our findings, which showed a reduction in subretinal fluid and an improvement in BCVA that was sustained for 3 years without any major adverse effects.

This study has some limitations. First, the results may be prone to information bias or selection bias due to the retrospective study design. Second, the generalizability of the findings is not known because this was a single center study with a small sample size. Third, a comparator group was not included. Prospective randomized clinical trials are needed to confirm our findings and establish whether conbercept is a useful adjunct therapy for Coats disease.

## CONCLUSION

In conclusion, intravitreal injection of conbercept combined with 532-nm laser photocoagulation may be a feasible treatment for Coats disease in adult patients.

## ARTICLE HIGHLIGHTS

### Research background

Coats disease is an idiopathic exudative outer retinopathy caused by abnormal retinal vascular development

### Research motivation

The disorder usually affects adolescents. However, a recent study reported that 7% of cases occur in adults.

### Research objectives

We investigated the long-term outcomes of intravitreal conbercept injection with laser photocoagulation to treat Coats disease in adults.

### Research methods

This is a retrospective case series on 8 adult patients (eight eyes) diagnosed with Coats disease. Patients were treated with intravitreal conbercept injection and 532-nm laser photocoagulation.



## Research results

There was a significant upward trend in the best-corrected visual acuity after treatment, which was maintained for at least 3 years.

## Research conclusions

Intravitreal conbercept injection plus 532-nm laser photocoagulation may be a feasible treatment for Coats disease in adult patients.

## Research perspectives

Prospective randomized clinical trials are needed to confirm our findings and establish whether conbercept is a useful adjunct therapy for Coats disease.

## REFERENCES

- 1 Sen M, Shields CL, Honavar SG, Shields JA. Coats disease: An overview of classification, management and outcomes. *Indian J Ophthalmol* 2019; **67**: 763-771 [PMID: [31124484](#) DOI: [10.4103/ijo.IJO\\_841\\_19](#)]
- 2 Yang X, Wang C, Su G. Recent advances in the diagnosis and treatment of Coats' disease. *Int Ophthalmol* 2019; **39**: 957-970 [PMID: [30895419](#) DOI: [10.1007/s10792-019-01095-8](#)]
- 3 Morris B, Foot B, Mulvihill A. A population-based study of Coats disease in the United Kingdom I: epidemiology and clinical features at diagnosis. *Eye (Lond)* 2010; **24**: 1797-1801 [PMID: [20865031](#) DOI: [10.1038/eye.2010.126](#)]
- 4 Rishi E, Rishi P, Appukuttan B, Uparkar M, Sharma T, Gopal L. Coats' disease of adult-onset in 48 eyes. *Indian J Ophthalmol* 2016; **64**: 518-523 [PMID: [27609165](#) DOI: [10.4103/0301-4738.190141](#)]
- 5 Kusaka S. Surgical Management of Coats Disease. *Asia Pac J Ophthalmol (Phila)* 2018; **7**: 156-159 [PMID: [29664241](#) DOI: [10.22608/APO.201867](#)]
- 6 Kase S, Rao NA, Yoshikawa H, Fukuhara J, Noda K, Kanda A, Ishida S. Expression of vascular endothelial growth factor in eyes with Coats' disease. *Invest Ophthalmol Vis Sci* 2013; **54**: 57-62 [PMID: [23221067](#) DOI: [10.1167/iov.12-10613](#)]
- 7 He YG, Wang H, Zhao B, Lee J, Bahl D, McCluskey J. Elevated vascular endothelial growth factor level in Coats' disease and possible therapeutic role of bevacizumab. *Graefes Arch Clin Exp Ophthalmol* 2010; **248**: 1519-1521 [PMID: [20379736](#) DOI: [10.1007/s00417-010-1366-1](#)]
- 8 Sun Y, Jain A, Moshfeghi DM. Elevated vascular endothelial growth factor levels in Coats disease: rapid response to pegaptanib sodium. *Graefes Arch Clin Exp Ophthalmol* 2007; **245**: 1387-1388 [PMID: [17342503](#) DOI: [10.1007/s00417-007-0559-8](#)]
- 9 Zhao Q, Peng XY, Chen FH, Zhang YP, Wang L, You QS, Jonas JB. Vascular endothelial growth factor in Coats' disease. *Acta Ophthalmol* 2014; **92**: e225-e228 [PMID: [23764089](#) DOI: [10.1111/aos.12158](#)]
- 10 Shields CL, Udyavar S, Dalvin LA, Lim LS, Atalay HT, L Khoo CT, Mazloumi M, Shields JA. Coats disease in 351 eyes: Analysis of features and outcomes over 45 years (by decade) at a single center. *Indian J Ophthalmol* 2019; **67**: 772-783 [PMID: [31124485](#) DOI: [10.4103/ijo.IJO\\_449\\_19](#)]
- 11 Zheng XX, Jiang YR. The effect of intravitreal bevacizumab injection as the initial treatment for Coats' disease. *Graefes Arch Clin Exp Ophthalmol* 2014; **252**: 35-42 [PMID: [23873253](#) DOI: [10.1007/s00417-013-2409-1](#)]
- 12 Li S, Deng G, Liu J, Ma Y, Lu H. The effects of a treatment combination of anti-VEGF injections, laser coagulation and cryotherapy on patients with type 3 Coats' disease. *BMC Ophthalmol* 2017; **17**: 76 [PMID: [28532448](#) DOI: [10.1186/s12886-017-0469-4](#)]
- 13 Gaillard MC, Mataftsi A, Balmer A, Houghton S, Munier FL. ranibizumab in the management of advanced Coats disease Stages 3B and 4: long-term outcomes. *Retina* 2014; **34**: 2275-2281 [PMID: [25075562](#) DOI: [10.1097/IAE.0000000000000248](#)]
- 14 Raoof N, Quhill F. Successful use of intravitreal bevacizumab and pascal laser photocoagulation in the management of adult Coats' disease. *Middle East Afr J Ophthalmol* 2013; **20**: 256-258 [PMID: [24014992](#) DOI: [10.4103/0974-9233.114805](#)]
- 15 Villegas VM, Gold AS, Berrocal AM, Murray TG. Advanced Coats' disease treated with intravitreal bevacizumab combined with laser vascular ablation. *Clin Ophthalmol* 2014; **8**: 973-976 [PMID: [24876764](#) DOI: [10.2147/OPTH.S62816](#)]
- 16 de Oliveira Dias JR, de Andrade GC, Novais EA, Farah ME, Rodrigues EB. Fusion proteins for treatment of retinal diseases: aflibercept, ziv-aflibercept, and conbercept. *Int J Retina Vitreous* 2016; **2**: 3 [PMID: [27847621](#) DOI: [10.1186/s40942-016-0026-y](#)]
- 17 Zhou Q, Guo C, You A, Wang D, Wang W, Zhang X. One-year outcomes of novel VEGF decoy receptor therapy with intravitreal conbercept in diabetic retinopathy-induced macular edema. *Mol Vis* 2019; **25**: 636-644 [PMID: [31700228](#)]
- 18 Li F, Zhang L, Wang Y, Xu W, Jiao W, Ma A, Zhao B. One-Year Outcome of Conbercept Therapy for Diabetic Macular Edema. *Curr Eye Res* 2018; **43**: 218-223 [PMID: [29265939](#) DOI: [10.1080/02713683.2017.1379542](#)]
- 19 Wu BH, Wang B, Wu HQ, Chang Q, Lu HQ. Intravitreal conbercept injection for neovascular age-

- related macular degeneration. *Int J Ophthalmol* 2019; **12**: 252-257 [PMID: 30809481 DOI: 10.18240/ijo.2019.02.11]
- 20 **Liu K**, Song Y, Xu G, Ye J, Wu Z, Liu X, Dong X, Zhang M, Xing Y, Zhu S, Chen X, Shen Y, Huang H, Yu L, Ke Z, Rosenfeld PJ, Kaiser PK, Ying G, Sun X, Xu X; PHOENIX Study Group. Conbercept for Treatment of Neovascular Age-related Macular Degeneration: Results of the Randomized Phase 3 PHOENIX Study. *Am J Ophthalmol* 2019; **197**: 156-167 [PMID: 30148987 DOI: 10.1016/j.ajo.2018.08.026]
  - 21 **Cui C**, Lu H. Clinical observations on the use of new anti-VEGF drug, conbercept, in age-related macular degeneration therapy: a meta-analysis. *Clin Interv Aging* 2018; **13**: 51-62 [PMID: 29343949 DOI: 10.2147/CIA.S151225]
  - 22 **Cui J**, Sun D, Lu H, Dai R, Xing L, Dong H, Wang L, Wei D, Jiang B, Jiao Y, Jablonski MM, Charles S, Gu W, Chen H. Comparison of effectiveness and safety between conbercept and ranibizumab for treatment of neovascular age-related macular degeneration. A retrospective case-controlled non-inferiority multiple center study. *Eye (Lond)* 2018; **32**: 391-399 [PMID: 28937147 DOI: 10.1038/eye.2017.187]
  - 23 **Zhang L**, Ke Y, Wang W, Shi X, Hei K, Li X. The efficacy of conbercept or ranibizumab intravitreal injection combined with laser therapy for Coats' disease. *Graefes Arch Clin Exp Ophthalmol* 2018; **256**: 1339-1346 [PMID: 29549425 DOI: 10.1007/s00417-018-3949-1]
  - 24 **Shields JA**, Shields CL, Honavar SG, Demirci H. Clinical variations and complications of Coats disease in 150 cases: the 2000 Sanford Gifford Memorial Lecture. *Am J Ophthalmol* 2001; **131**: 561-571 [PMID: 11336930 DOI: 10.1016/s0002-9394(00)00883-7]
  - 25 **Holz FG**, Amoaku W, Donate J, Guymer RH, Kellner U, Schlingemann RO, Weichselberger A, Staurengi G; SUSTAIN Study Group. Safety and efficacy of a flexible dosing regimen of ranibizumab in neovascular age-related macular degeneration: the SUSTAIN study. *Ophthalmology* 2011; **118**: 663-671 [PMID: 21459217 DOI: 10.1016/j.ophtha.2010.12.019]
  - 26 **Wang KY**, Cheng CK. A combination of intravitreal bevacizumab injection with tunable argon yellow laser photocoagulation as a treatment for adult-onset Coats' disease. *J Ocul Pharmacol Ther* 2011; **27**: 525-530 [PMID: 21951171 DOI: 10.1089/jop.2011.0088]
  - 27 **Zhang C**, Dong F, Wang R. Clinical characteristics and diagnosis and treatment of Coats disease in adults. *Zhonghua Yandibing Zazhi* 2008; **24**: 279-282
  - 28 **Otani T**, Yasuda K, Aizawa N, Sakai F, Nakazawa T, Shimura M. Over 10 years follow-up of Coats' disease in adulthood. *Clin Ophthalmol* 2011; **5**: 1729-1732 [PMID: 22205832 DOI: 10.2147/OPHTH.S27938]
  - 29 **Sigler EJ**, Randolph JC, Calzada JI, Wilson MW, Haik BG. Current management of Coats disease. *Surv Ophthalmol* 2014; **59**: 30-46 [PMID: 24138893 DOI: 10.1016/j.survophthal.2013.03.007]
  - 30 **Kaul S**, Uparkar M, Mody K, Walinjar J, Kothari M, Natarajan S. Intravitreal anti-vascular endothelial growth factor agents as an adjunct in the management of Coats' disease in children. *Indian J Ophthalmol* 2010; **58**: 76-78 [PMID: 20029154 DOI: 10.4103/0301-4738.58480]
  - 31 **Lin CJ**, Hwang JF, Chen YT, Chen SN. The effect of intravitreal bevacizumab in the treatment of Coats disease in children. *Retina* 2010; **30**: 617-622 [PMID: 19996822 DOI: 10.1097/IAE.0b013e3181c2e0b7]





Published by **Baishideng Publishing Group Inc**  
7041 Koll Center Parkway, Suite 160, Pleasanton, CA 94566, USA

**Telephone:** +1-925-3991568

**E-mail:** [bpgoffice@wjgnet.com](mailto:bpgoffice@wjgnet.com)

**Help Desk:** <https://www.f6publishing.com/helpdesk>

<https://www.wjgnet.com>

