

国内版 国际版

Rare case of esophageal superficial adenosquamous carcinoma re



ALL IMAGES VIDEOS

59,000 Results

Any time ▾

[\[A case of superficial esophageal basaloid squamous cell ...](#)

<https://www.ncbi.nlm.nih.gov/pubmed/24898489>

In addition, the basaloid **squamous cell carcinoma** had two different components in terms of malignancy and differentiation. Here we report a **rare case of esophageal basaloid squamous cell carcinoma resected by endoscopic submucosal dissection**. PMID: 24898489 [Indexed for MEDLINE] Publication Types: **Case Reports**; MeSH terms. Aged

Author: Takuto Nosaka, Hiroyuki Suto, Hidetaka... **Publish Year:** 2014

[Endoscopic submucosal dissection of coexisting early ...](#)

<https://journals.sagepub.com/doi/full/10.1177/0300060520961246>

Endoscopic biopsy revealed **esophageal squamous cell carcinoma**. Both lesions were successfully treated by **endoscopic submucosal dissection**. The patient was followed up for 6 months without recurrence. **Endoscopic submucosal dissection** was a successful initial treatment method for **esophageal carcinoma coexisting with esophageal leiomyoma** in this case.

Author: Ma Liang, Ding Fei, Song Jianguo, Wu C... **Publish Year:** 2020

[Superficial Esophageal Neoplasms Overlying Leiomyomas ...](#)

<https://www.ncbi.nlm.nih.gov/pmc/articles/PMC4522425>

Several cases of coexisting squamous cell **carcinoma (SCC)** and leiomyoma in the **esophagus** have been reported, and most were treated surgically.^{5,6,7} In the present **report**, three cases of **superficial esophageal neoplasms (SENs)** that overlaid leiomyoma and were successfully removed by **endoscopic submucosal dissection (ESD)** are reported. The ...

Cited by: 3 **Author:** Myeongsook Seo, Do Hoon Kim, Young Wh...
Publish Year: 2015

[Repeated Endoscopic Submucosal Dissection for Esophageal ...](#)

<https://journals.lww.com/ctg/fulltext/2020/08000/...>

Endoscopic submucosal dissection (ESD) has been accepted in eastern countries with higher en bloc and complete resection rates for **superficial esophageal neoplasia** compared with those of **endoscopic mucosal resection (EMR)**, regardless of the tumor's size or of presence of ulceration .

国内版

国际版

A rare case of esophageal superficial adenosquamous carcinoma r



ALL

IMAGES

VIDEOS

59,400 Results

Any time ▾

A superficial esophageal cancer in an epiphrenic ...

<https://pubmed.ncbi.nlm.nih.gov/28784105>

Background: We **report** a unique **case** of a **superficial esophageal** cancer arising in a single diverticulum, diagnosed with magnifying image-enhanced endoscopy and then successfully treated **by endoscopic submucosal dissection** (ESD). **Case** presentation: A 66-year-old man with alcohol-related liver injury visited our hospital for endoscopy for investigation of varix.

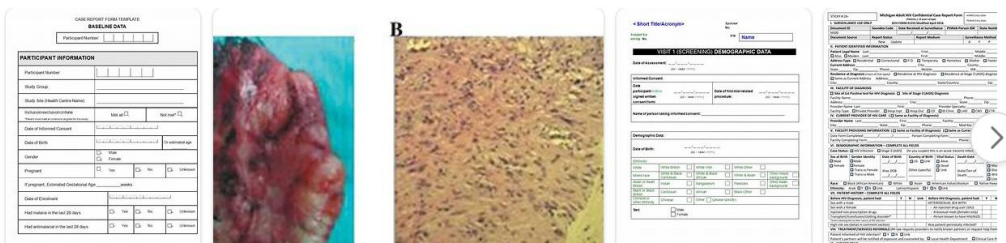
[A case of superficial esophageal basaloid squamous cell ...

<https://www.ncbi.nlm.nih.gov/pubmed/24898489>

[A case of superficial esophageal basaloid squamous cell carcinoma resected by endoscopic submucosal dissection]. [Article in Japanese] Nosaka T(1), Suto H, Matsuda H, Takahashi K, Ohtani M, Hiramatsu K, Nemoto T, Imamura Y, Nakamoto Y. Author information: (1)Department of Gastroenterology, University of Fukui Hospital.

Author: Takuto Nosaka, Hiroyuki Suto, Hidetaka... **Publish Year:** 2014

Images of a Rare Case of Esophageal Superficial Adenosquamous...

<bing.com/images>

Name of Journal: *World Journal of Clinical Cases*

Manuscript NO: 58677

Manuscript Type: CASE REPORT

A rare case of esophageal superficial adenosquamous carcinoma resected by endoscopic submucosal dissection: a case report

esophageal superficial adenosquamous carcinoma

Abstract

BACKGROUND

Adenosquamous carcinoma (ASC), comprising squamous cell carcinoma (SCC) and adenocarcinoma (AC) elements, is a rare histological type of esophageal carcinoma. Few reports have focused on the endoscopic findings and the effectiveness of the endoscopic treatment of early ASC.

CASE SUMMARY

Match Overview

1	Internet 43 words crawled on 05-Aug-2020 content.sciendo.com	2%
2	Internet 37 words www.ncbi.nlm.nih.gov	2%
3	Crossref 30 words Hiroyuki Endo, Tomoyuki Koike, Waku Hatta, Kiyotaka Asanuma et al. "Endoscopic Findings of Esophageal Adenosquamous Carcinoma"	1%
4	Crossref 13 words Kuangji Fu, Peng Jin, Yuqi He, Masanori Suzuki, Jianqiu Sheng. "A superficial esophageal cancer in an epiphrenic diverticulum"	1%
5	Internet 13 words crawled on 23-Dec-2020 koreascience.or.kr	1%
6	Internet 12 words crawled on 16-Oct-2020 www.wjgnet.com	1%

国内版

国际版

Esophageal superficial adenosquamous carcinoma resected by er



ALL

IMAGES

VIDEOS

59,500 Results

Any time ▾

[A case of superficial esophageal basaloid squamous cell ...

<https://www.ncbi.nlm.nih.gov/pubmed/24898489>

In addition, the **basaloid squamous cell carcinoma** had two different components in terms of malignancy and differentiation. Here we report a **rare** case of **esophageal basaloid squamous cell carcinoma resected by endoscopic submucosal dissection**. PMID: 24898489 [Indexed for MEDLINE] Publication Types: Case Reports; MeSH terms. Aged

Author: Takuto Nosaka, Hiroyuki Suto, Hidet... **Publish Year:** 2014

Endoscopic resection for early esophageal carcinoma ...

jtd.amegroups.com/article/view/27787/html ▾

Endoscopic resection of mucosal (T1m1-3) and **superficial submucosal** (T1sm1) adenocarcinoma can be curative as well as for **superficial** mucosal (T1m1-m2) squamous cell **carcinoma**. In Paris type I lesions in Barrett's **esophagus** and for early squamous cell **carcinoma endoscopic submucosal dissection** (ESD) is the preferred option.

Cited by: 8

Author: Irma C. Noordzij, Wouter L. Curvers, Eri...

Publish Year: 2019

Superficial Esophageal Cancer in a Fanconi Anemia Patient ...

<https://www.ncbi.nlm.nih.gov/pmc/articles/PMC6421153>

Feb 15, 2019 · We herein report a case of FA in an adult patient who developed tongue and **superficial esophageal cancers** following hematopoietic stem cell transplantation. This case is presented due to its significance as the first reported case of **esophageal cancer** in an FA patient in whom the **cancer** was detected as a **superficial cancer** and treated **successfully by endoscopic submucosal dissection** (ESD).

Author: Sachiyo Onishi, Masahiro Tajika, Tsu... **Publish Year:** 2019

[PDF] A superficial esophageal cancer in an epiphrenic ...

<https://bmcgastroenterol.biomedcentral.com/track/pdf/10.1186/s12876-017-0649-y>

Background: We **report** a unique **case** of a **superficial esophageal cancer** arising in a single