

World Journal of *Clinical Cases*

World J Clin Cases 2020 November 26; 8(22): 5496-5834



Contents

Semimonthly Volume 8 Number 22 November 26, 2020

EDITORIAL

- 5496** Is Dynesys dynamic stabilization system superior to posterior lumbar fusion in the treatment of lumbar degenerative diseases?

Peng BG, Gao CH

MINIREVIEWS

- 5501** COVID-19: A review of what radiologists need to know
Tang L, Wang Y, Zhang Y, Zhang XY, Zeng XC, Song B
- 5513** Holistic care model of time-sharing management for severe and critical COVID-19 patients
Yang B, Gao Y, Kang K, Li J, Wang L, Wang H, Bi Y, Dai QQ, Zhao MY, Yu KJ

ORIGINAL ARTICLE

Case Control Study

- 5518** Bioequivalence of two esomeprazole magnesium enteric-coated formulations in healthy Chinese subjects
Liu ZZ, Ren Q, Zhou YN, Yang HM
- 5529** Osteoprotegerin, interleukin and hepatocyte growth factor for prediction of diabetes and hypertension in the third trimester of pregnancy
Huang SJ, Wang HW, Wu HF, Wei QY, Luo S, Xu L, Guan HQ

Retrospective Study

- 5535** High serum lactate dehydrogenase and dyspnea: Positive predictors of adverse outcome in critical COVID-19 patients in Yichang
Ly XT, Zhu YP, Cheng AG, Jin YX, Ding HB, Wang CY, Zhang SY, Chen GP, Chen QQ, Liu QC
- 5547** Risk factors analysis of prognosis of adult acute severe myocarditis
Zhang Q, Zhao R
- 5555** Sonographic features of umbilical vein recanalization for a Rex shunt on cavernous transformation of portal vein in children
Zhang YQ, Wang Q, Wu M, Li Y, Wei XL, Zhang FX, Li Y, Shao GR, Xiao J

Clinical Trials Study

- 5564** Gemcitabine plus concurrent irreversible electroporation vs gemcitabine alone for locally advanced pancreatic cancer
Ma YY, Leng Y, Xing YL, Li HM, Chen JB, Niu LZ

Observational Study

- 5576** No significant association between dipeptidyl peptidase-4 inhibitors and adverse outcomes of COVID-19
Zhou JH, Wu B, Wang WX, Lei F, Cheng X, Qin JJ, Cai JJ, Zhang X, Zhou F, Liu YM, Li HM, Zhu LH, She Z, Zhang X, Yang J, Li HL

META-ANALYSIS

- 5589** Interobserver agreement for contrast-enhanced ultrasound of liver imaging reporting and data system: A systematic review and meta-analysis
Li J, Chen M, Wang ZJ, Li SG, Jiang M, Shi L, Cao CL, Sang T, Cui XW, Dietrich CF

CASE REPORT

- 5603** CLAG-M chemotherapy followed by umbilical cord blood stem cell transplantation for primary refractory acute myeloid leukaemia in a child: A case report
Huang J, Yang XY, Rong LC, Xue Y, Zhu J, Fang YJ
- 5611** Multiple schwannomas with pseudoglandular element synchronously occurring under the tongue: A case report
Chen YL, He DQ, Yang HX, Dou Y
- 5618** Primary myelofibrosis with concurrent *CALR* and *MPL* mutations: A case report
Zhou FP, Wang CC, Du HP, Cao SB, Zhang J
- 5625** Endometrial stromal sarcoma extending to the pulmonary artery: A rare case report
Fan JK, Tang GC, Yang H
- 5632** Malignant acanthosis nigricans with Leser-Trélat sign and tripe palms: A case report
Wang N, Yu PJ, Liu ZL, Zhu SM, Zhang CW
- 5639** Gastric plexiform fibromyxoma: A case report
Pei JY, Tan B, Liu P, Cao GH, Wang ZS, Qu LL
- 5645** Rectoseminal vesicle fistula after radical surgery for rectal cancer: Four case reports and a literature review
Xia ZX, Cong JC, Zhang H
- 5657** Azacitidine decreases reactive oxygen species production in peripheral white blood cells: A case report
Hasunuma H, Shimizu N, Yokota H, Tatsuno I
- 5663** Oral granuloma in a pediatric patient with chronic graft-versus-host disease: A case report
Uesugi A, Tsushima F, Kodama M, Kuroshima T, Sakurai J, Harada H
- 5670** Intrahepatic biliary cystadenoma: A case report
Xu RM, Li XR, Liu LH, Zheng WQ, Zhou H, Wang XC
- 5678** Gene diagnosis of infantile neurofibromatosis type I: A case report
Li MZ, Yuan L, Zhuo ZQ

- 5684** Localized amyloidosis affecting the lacrimal sac managed by endoscopic surgery: A case report
Song X, Yang J, Lai Y, Zhou J, Wang J, Sun X, Wang D
- 5690** Endoscopic resection of benign esophageal schwannoma: Three case reports and review of literature
Li B, Wang X, Zou WL, Yu SX, Chen Y, Xu HW
- 5701** Bouveret syndrome masquerading as a gastric mass-unmasked with endoscopic luminal laser lithotripsy: A case report
Parvataneni S, Khara HS, Diehl DL
- 5707** Nonhypertensive male with multiple paragangliomas of the heart and neck: A case report
Wang Q, Huang ZY, Ge JB, Shu XH
- 5715** Completed atrioventricular block induced by atrial septal defect occluder unfolding: A case report
He C, Zhou Y, Tang SS, Luo LH, Feng K
- 5722** Clinical characteristics of adult-type annular pancreas: A case report
Yi D, Ding XB, Dong SS, Shao C, Zhao LJ
- 5729** Port-site metastasis of unsuspected gallbladder carcinoma with ossification after laparoscopic cholecystectomy: A case report
Gao KJ, Yan ZL, Yu Y, Guo LQ, Hang C, Yang JB, Zhang MC
- 5737** Gonadal dysgenesis in Turner syndrome with Y-chromosome mosaicism: Two case reports
Leng XF, Lei K, Li Y, Tian F, Yao Q, Zheng QM, Chen ZH
- 5744** Gastric mixed adenoma-neuroendocrine tumor: A case report
Kohno S, Aoki H, Kato M, Ogawa M, Yoshida K
- 5751** Sebaceous lymphadenocarcinoma of the parotid gland: A case report
Hao FY, Wang YL, Li SM, Xue LF
- 5758** Misdiagnosis of ligamentoid fibromatosis of the small mesenteric: A case report
Xu K, Zhao Q, Liu J, Zhou D, Chen YL, Zhu X, Su M, Huang K, Du W, Zhao H
- 5765** Intraoperative care of elderly patients with COVID-19 undergoing double lung transplantation: Two case reports
Wu Q, Wang Y, Chen HQ, Pan H
- 5773** Amelioration of cognitive impairment following growth hormone replacement therapy: A case report and review of literature
Liu JT, Su PH
- 5781** Early colon cancer with enteropathy-associated T-cell lymphoma involving the whole gastrointestinal tract: A case report
Zhang MY, Min CC, Fu WW, Liu H, Yin XY, Zhang CP, Tian ZB, Li XY

- 5790** Bleeding of two lumbar arteries caused by one puncture following percutaneous nephrolithotomy: A case report
Liu Q, Yang C, Lin K, Yang D
- 5795** Hemorrhagic fever with renal syndrome complicated with aortic dissection: A case report
Qiu FQ, Li CC, Zhou JY
- 5802** Robot-assisted laparoscopic pyeloureterostomy for ureteropelvic junction rupture sustained in a traffic accident: A case report
Kim SH, Kim WB, Kim JH, Lee SW
- 5809** Large leiomyoma of lower esophagus diagnosed by endoscopic ultrasonography-fine needle aspiration: A case report
Rao M, Meng QQ, Gao PJ
- 5816** Endoscopic reduction of colocolonic intussusception due to metastatic malignant melanoma: A case report
Kasuga K, Sakamoto T, Takamaru H, Sekiguchi M, Yamada M, Yamazaki N, Hashimoto T, Uraoka T, Saito Y
- 5821** Usefulness of ultrasonography to assess the response to steroidal therapy for the rare case of type 2b immunoglobulin G4-related sclerosing cholangitis without pancreatitis: A case report
Tanaka Y, Kamimura K, Nakamura R, Ohkoshi-Yamada M, Koseki Y, Mizusawa T, Ikarashi S, Hayashi K, Sato H, Sakamaki A, Yokoyama J, Terai S

LETTER TO THE EDITOR

- 5831** Is positivity for hepatitis C virus antibody predictive of lower risk of death in COVID-19 patients with cirrhosis?
Mangia A, Cenderello G, Verucchi G, Ciancio A, Fontana A, Piazzolla V, Minerva N, Squillante MM, Copetti M

ABOUT COVER

Peer-reviewer of *World Journal of Clinical Cases*, Dr. Galiatsatos Aristidis is an Associate Professor, Department of Biomedical Sciences, Division of Dental Technology, University of West Attica. After graduating from the Faculty of Dentistry of University of Thessaloniki in 1988, he completed his PhD in the Dental Prosthodontics Department of Athens University in 1996. From 1988 to 2005, he continued his professional training in the University of Athens as a Research Fellow in Prosthodontics. During the 1998-1999 academic year, he was hired as a paid research scientist in the same subject area. In 2009, he rose to Assistant and then Associate Professor in the University of West Attica. From September 2019, he has served as Director of the Division of Dental Technology. (L-Editor: Filipodia)

AIMS AND SCOPE

The primary aim of *World Journal of Clinical Cases* (*WJCC*, *World J Clin Cases*) is to provide scholars and readers from various fields of clinical medicine with a platform to publish high-quality clinical research articles and communicate their research findings online.

WJCC mainly publishes articles reporting research results and findings obtained in the field of clinical medicine and covering a wide range of topics, including case control studies, retrospective cohort studies, retrospective studies, clinical trials studies, observational studies, prospective studies, randomized controlled trials, randomized clinical trials, systematic reviews, meta-analysis, and case reports.

INDEXING/ABSTRACTING

The *WJCC* is now indexed in Science Citation Index Expanded (also known as SciSearch®), Journal Citation Reports/Science Edition, PubMed, and PubMed Central. The 2020 Edition of Journal Citation Reports® cites the 2019 impact factor (IF) for *WJCC* as 1.013; IF without journal self cites: 0.991; Ranking: 120 among 165 journals in medicine, general and internal; and Quartile category: Q3.

RESPONSIBLE EDITORS FOR THIS ISSUE

Production Editor: Ji-Hong Liu; Production Department Director: Xiang Li; Editorial Office Director: Jin-Lai Wang.

NAME OF JOURNAL

World Journal of Clinical Cases

ISSN

ISSN 2307-8960 (online)

LAUNCH DATE

April 16, 2013

FREQUENCY

Semimonthly

EDITORS-IN-CHIEF

Dennis A Bloomfield, Sandro Vento, Bao-Gan Peng

EDITORIAL BOARD MEMBERS

<https://www.wjgnet.com/2307-8960/editorialboard.htm>

PUBLICATION DATE

November 26, 2020

COPYRIGHT

© 2020 Baishideng Publishing Group Inc

INSTRUCTIONS TO AUTHORS

<https://www.wjgnet.com/bpg/gerinfo/204>

GUIDELINES FOR ETHICS DOCUMENTS

<https://www.wjgnet.com/bpg/GerInfo/287>

GUIDELINES FOR NON-NATIVE SPEAKERS OF ENGLISH

<https://www.wjgnet.com/bpg/gerinfo/240>

PUBLICATION ETHICS

<https://www.wjgnet.com/bpg/GerInfo/288>

PUBLICATION MISCONDUCT

<https://www.wjgnet.com/bpg/gerinfo/208>

ARTICLE PROCESSING CHARGE

<https://www.wjgnet.com/bpg/gerinfo/242>

STEPS FOR SUBMITTING MANUSCRIPTS

<https://www.wjgnet.com/bpg/GerInfo/239>

ONLINE SUBMISSION

<https://www.f6publishing.com>

Large leiomyoma of lower esophagus diagnosed by endoscopic ultrasonography–fine needle aspiration: A case report

Min Rao, Qing-Qing Meng, Pu-Jun Gao

ORCID number: Min Rao 0000-0001-8330-260X; Qing-Qing Meng 0000-0003-1057-1643; Pu-Jun Gao 0000-0002-8306-7694.

Author contributions: Rao M wrote the original manuscript with comprehensive review of the literature on the topic; Gao PJ edited the initial report and contributed to literature review; Meng QQ also contributed to editing the report.

Supported by the Natural Science Foundation of Science and Technology Department of Jilin Province, China. No. 20200201496JC.

Informed consent statement: All study participants, or their legal guardian, provided informed written consent prior to study enrollment.

Conflict-of-interest statement: There are no conflicts of interest by any other the authors of this manuscript including Drs. Min Rao, Qing-Qing Meng, and Pu-Jun Gao.

CARE Checklist (2016) statement: The authors have read the CARE Checklist (2016), and the manuscript was prepared and revised according to the CARE Checklist (2016).

Min Rao, Qing-Qing Meng, Department of Hepatology and Gastroenterology, The Second Part of First Hospital of Jilin University, Changchun 130021, Jilin Province, China

Pu-Jun Gao, Department of Hepatology, The First Hospital of Jilin University, Changchun 130021, Jilin Province, China

Corresponding author: Pu-Jun Gao, PhD, Chief Doctor, Full Professor, Department of Hepatology, The First Hospital of Jilin University, No. 71 Xinmin Street, Changchun 130021, Jilin Province, China. gpj@jlu.edu.cn

Abstract

BACKGROUND

Benign esophageal tumors are rare accounting for < 1% of esophageal tumors; two-thirds of which are leiomyomas. Esophageal leiomyoma is a benign tumor derived from mesenchymal tissue that is completely muscularly differentiated. Most esophageal leiomyomas are < 5 cm. Esophageal leiomyomas > 5 cm are rare. We describe a case of a large esophageal leiomyoma involving the cardia and diaphragm.

CASE SUMMARY

A 35-year-old woman presented to the doctor because of a choking sensation after eating. Physical examination showed no positive signs. Gastroscopy indicated an uplifted change in the cardia. Enhanced computed tomography revealed space-occupying lesions in the lower part of the esophagus and cardia, which were likely to be malignant. Positron emission tomography-computed tomography showed increased metabolism of soft tissue masses in the lower esophagus and near the cardia. Malignant lesions were considered, and mesenchymal tumors were not excluded. Endoscopic ultrasonography was performed to examine a hypoechoic mass in the lower esophagus, which was unclear from the esophageal wall. Clinical evaluation suggested diagnosis of esophageal and cardiac stromal tumors. Finally, histological specimens obtained by endoscopic ultrasonography–fine needle aspiration suggested leiomyoma. The patient underwent laparoscopic local resection of the tumor. The postoperative pathological diagnosis was leiomyoma.

CONCLUSION

Endoscopic ultrasonography–fine needle aspiration is necessary for the diagnosis of gastrointestinal leiomyomas. It provides a strong basis for diagnosis of gastrointestinal tumors of unknown nature and origin.

Open-Access: This article is an open-access article that was selected by an in-house editor and fully peer-reviewed by external reviewers. It is distributed in accordance with the Creative Commons Attribution NonCommercial (CC BY-NC 4.0) license, which permits others to distribute, remix, adapt, build upon this work non-commercially, and license their derivative works on different terms, provided the original work is properly cited and the use is non-commercial. See: <http://creativecommons.org/licenses/by-nc/4.0/>

Manuscript source: Unsolicited manuscript

Specialty type: Medicine, research and experimental

Country/Territory of origin: China

Peer-review report's scientific quality classification

Grade A (Excellent): 0
Grade B (Very good): B
Grade C (Good): C
Grade D (Fair): 0
Grade E (Poor): 0

Received: September 1, 2020

Peer-review started: September 1, 2020

First decision: September 12, 2020

Revised: September 17, 2020

Accepted: September 29, 2020

Article in press: September 29, 2020

Published online: November 26, 2020

P-Reviewer: Bello BL, Yoshio S

S-Editor: Zhang L

L-Editor: Filipodia

P-Editor: Xing YX



Key Words: Esophageal tumor; Leiomyoma; Endoscopic ultrasonography; Fine needle aspiration; Endoscopic ultrasonography-fine needle aspiration; Case report

©The Author(s) 2020. Published by Baishideng Publishing Group Inc. All rights reserved.

Core Tip: Endoscopic ultrasonography-fine needle aspiration is necessary for the diagnosis of gastrointestinal leiomyomas. It provides a strong basis for diagnosis of gastrointestinal tumors of unknown nature and origin.

Citation: Rao M, Meng QQ, Gao PJ. Large leiomyoma of lower esophagus diagnosed by endoscopic ultrasonography-fine needle aspiration: A case report. *World J Clin Cases* 2020; 8(22): 5809-5815

URL: <https://www.wjgnet.com/2307-8960/full/v8/i22/5809.htm>

DOI: <https://dx.doi.org/10.12998/wjcc.v8.i22.5809>

INTRODUCTION

Benign esophageal tumors are rare accounting for < 1% of esophageal tumors; two-thirds of which are leiomyomas^[1-3]. Leiomyomas are the most common benign esophageal tumors. Leiomyoma is common in middle-aged patients with a male to female ratio of 2:1. Leiomyomas < 5 cm are mostly asymptomatic and discovered accidentally. The larger the leiomyoma, the more likely it is to show symptoms, such as dysphagia and chest pain. Most leiomyomas do not need treatment, but regular follow-up observation; if large leiomyomas cause symptoms, resection is required.

The pathology of leiomyoma is characterized by intersecting spindle cells with rich cytoplasm, and the malignant potential is low. In immunohistochemical examination, the specific signs of leiomyoma are diffuse positivity for desmin and smooth muscle actin (SMA) and negativity for CD34 and CD117. Abdominal computed tomography (CT) and endoscopic ultrasound (EUS) can diagnose most upper gastrointestinal leiomyomas, but there are still some difficulties in the diagnosis of atypical lesions, which can easily be misdiagnosed as stromal tumors and other malignant lesions. Tumor histological specimens can be obtained through EUS-fine needle aspiration (FNA), which provide a strong basis for the diagnosis of gastrointestinal tumors of unknown nature and origin.

Here we report a case of large esophageal leiomyoma. The CT and endoscopic findings of this case were close to those of stromal tumors. However, through EUS-FNA examination, the final diagnosis was leiomyoma.

CASE PRESENTATION

Chief complaints

A 35-year-old woman with hiccups and belching for > 30 years presented at the hospital because of choking and foreign body sensation during eating over the past 10 d. Abdominal CT and gastroscopy had not previously been performed.

History of present illness

The patient has experienced choking and foreign body sensation during eating over the past 10 d.

History of past illness

Patient has no relevant past medical history.

Personal and family history

Patient has no relevant family history.

Physical examination

There were no positive signs.

Laboratory examinations

No abnormalities were found by blood biochemical examination.

Imaging examinations

Gastroscopy showed uplifted changes in the cardia. Contrast-enhanced CT of the stomach (Figure 1) indicated space-occupying lesions in the lower esophagus and cardia, which were likely to be malignant. Positron emission tomography-CT (Figure 2) showed increased metabolism of soft tissue masses in the lower esophagus and near the cardia. Malignant lesions were considered, and mesenchymal malignant tumors were not excluded. EUS (Figure 3) examined the lower part of the esophagus near the cardia, and a hypoechoic mass was seen close to the esophageal wall growing outward. The internal echo was uneven, and there was no echo in some parts. Blood flow signals were seen inside. The mass was close to the liver and diaphragm, and the longest diameter of the section was approximately 4.9 cm. EUS diagnosed a hypoechoic mass in the lower esophagus with an unclear boundary with the esophageal wall. Combined with the above examinations, preoperative assessment was a probable stromal tumor. The tumor was large and involved the diaphragm and liver, thus making surgery difficult. Preoperative FNA examination was recommended to determine the treatment plan.

FINAL DIAGNOSIS

Postoperative pathological diagnosis was leiomyoma.

TREATMENT

The patient agreed to undergo EUS-FNA examination. Under EUS, a puncture needle was placed in the lower part of the esophagus near the cardia and pierced the center of the tumor. A strip of tissue was obtained and sent for pathological examination (Figure 4A). Pathological examination showed a large amount of mucus-like tissue that included a small amount of smooth muscle tissue (Figure 4B). Immunohistochemistry showed: SMA (+), desmin (+), H-caldesmon (+), CD117 (-), Dog-1 (-), S-100 (-), CD34 (-), CKpan (-), SDHB (+) and Ki-67 (+ < 1%) (Figure 4C). Histological and immunohistochemical results suggested that the tumor was leiomyoma. Laparoscopic local resection of the mass was performed (Figure 5A). The postoperative pathological diagnosis was leiomyoma (tumor volume 8.0 cm × 6.0 cm × 3.5 cm) (Figure 5B). Immunohistochemistry showed: CD34 (-), desmin (+), H-caldesmon (+), Ki-67 (+1%), SDHB (+), SMA (+), CD117 (-), Dog-1 (-) and S-100 (-) (Figure 5C). These findings were consistent with the results of EUS-FNA before surgery.

OUTCOME AND FOLLOW-UP

The patient recovered well after the operation, and there is no information for review at present.

DISCUSSION

Benign esophageal tumors are rare accounting for < 1% of esophageal tumors; two-thirds of which are leiomyomas^[1-3]. The rest are mostly cysts (20%), polyps (5%), gastrointestinal stromal tumors (< 5%) and lipomas (< 1%)^[4,5]. Leiomyoma is the most common benign tumor of the esophagus. Esophageal leiomyomas are common in middle-aged patients, and the male to female ratio is 2:1^[2,6]. Leiomyomas < 5 cm are mostly asymptomatic and discovered accidentally. The larger the leiomyoma, the more likely it is to show symptoms, such as dysphagia and chest pain^[7-10]. The pathology of leiomyoma is characterized by intersecting spindle cells with rich cytoplasm, and the malignant potential is low. In immunohistochemical examination,

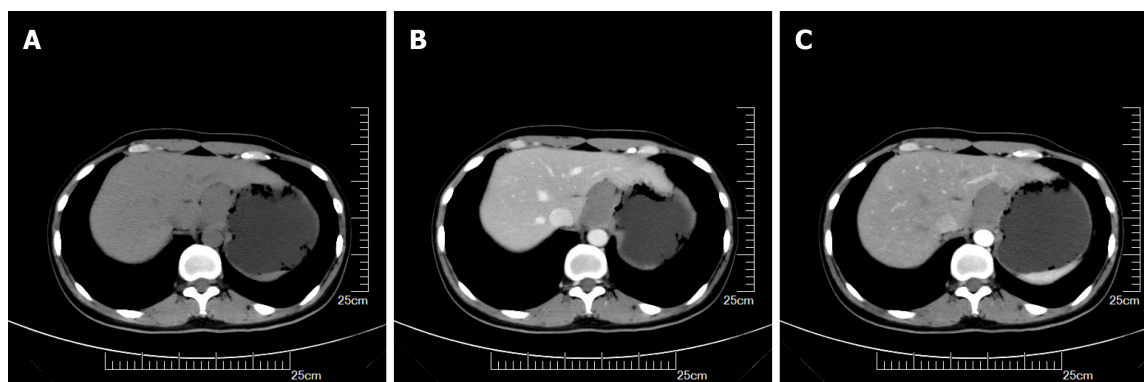


Figure 1 Stomach computed tomography images. A: Plain scan; B: Arterial phase; C: Venous phase.

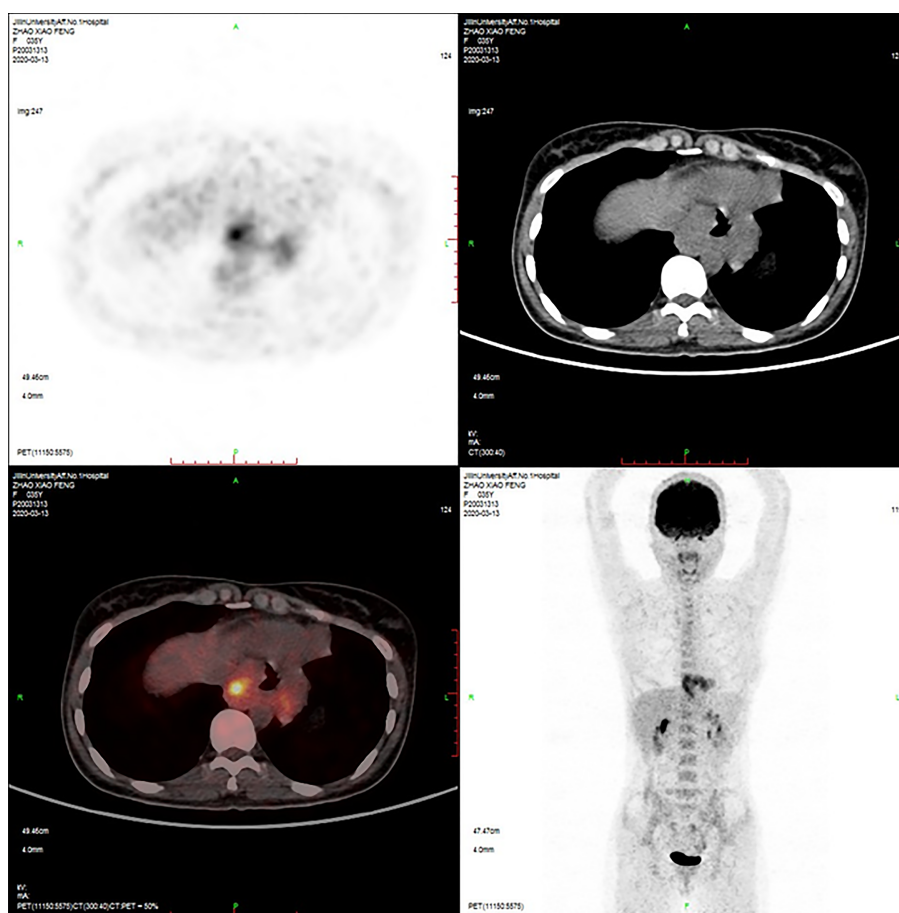


Figure 2 Positron emission tomography–computed tomography image.

the specific signs of leiomyoma are diffuse positivity for desmin and SMA and negativity for CD34 and CD117^[11,12].

For most esophageal leiomyomas, the most common imaging test is upper gastrointestinal barium meal or esophagography because it is the least invasive, simplest and most common examination method^[13-15]. As a noninvasive investigation method, CT examination has high diagnostic accuracy for space-occupying lesions of the digestive system and can make an accurate assessment of the exact location, size, range and distribution of blood vessels of the lesion. The CT findings of leiomyomas are soft tissue masses with clear boundaries. The tumors are of various shapes. The common growth patterns are intracavitary and transmural inside and outside the cavity. The mass density is uniform on CT scan, and enhanced scanning shows mild to moderate uniform enhancement. Compared with stromal tumors, leiomyomas have fewer ulcers^[12].

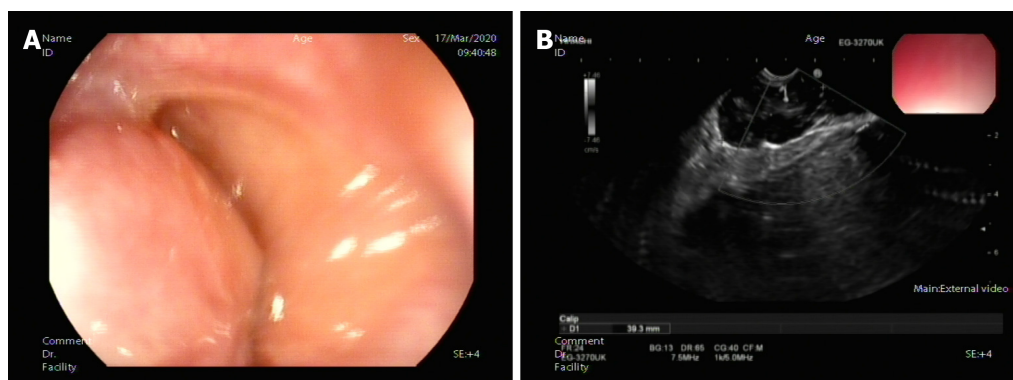


Figure 3 Endoscopic ultrasound examined the lower part of the esophagus near the cardia, and a hypoechoic mass was seen close to the esophageal wall growing outward. A: Large uplift of the cardia under endoscopy; B: Endoscopic ultrasonography image.

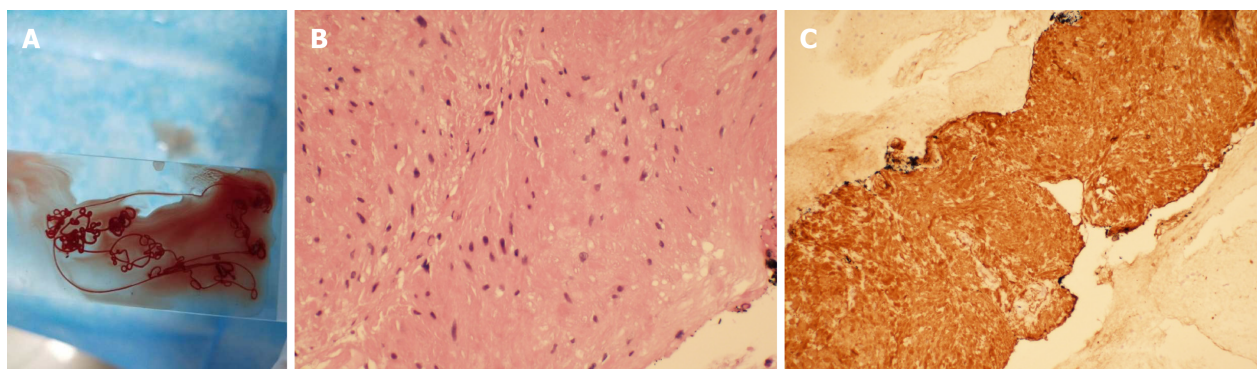


Figure 4 Pathological examination. A: Tissue specimen aspirated by endoscopic ultrasonography-fine needle aspiration (FNA); B: Cytological examination of FNA biopsy of tumor (hematoxylin and eosin staining, 400 ×); C: Immunohistochemical staining of FNA biopsy of tumor.

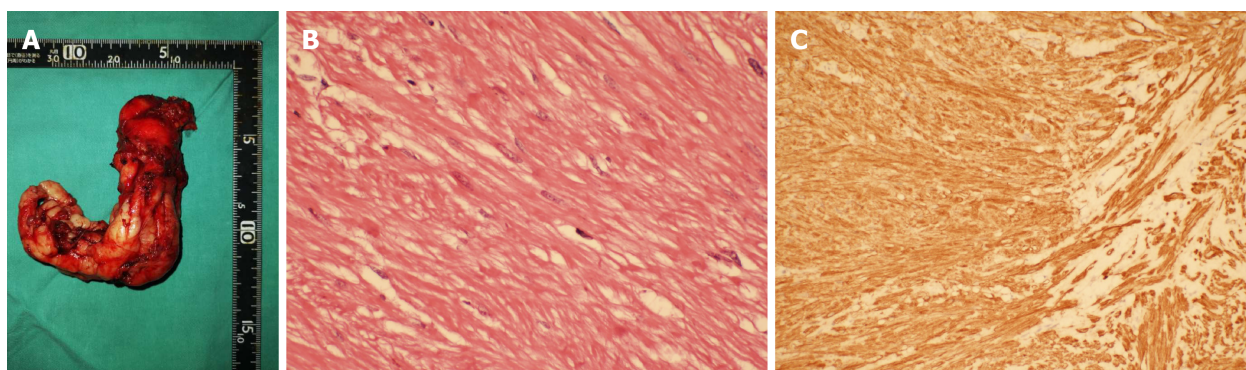


Figure 5 Laparoscopic local resection of the mass was performed and pathological examination. A: Postoperative whole tumor tissue specimen; B: Cytological examination of the whole tumor (hematoxylin and eosin staining, 400 ×); C: Immunohistochemical staining of the tumor.

EUS is currently an important diagnostic method for esophageal leiomyoma. Under EUS, leiomyomas mostly originate in the muscularis mucosa with smooth surface mucosa and mostly show uniform hypoechoic lesions. EUS is more accurate for diagnosis of lesions derived from the muscularis mucosa and muscularis propria. Previous studies have suggested that EUS makes a diagnosis based on factors such as the location, level of origin, size, echo intensity, uniformity, boundary and relationship with surrounding organs of the submucosal mass, and its specificity is 80%-88%^[16,17]. Esophageal lesions from the muscularis mucosa or the muscularis propria are mainly leiomyomas, and only a few lesions derived from the muscularis propria are stromal tumors. The proportion of esophageal stromal tumors is < 7%^[18]. Although EUS provides important information for identifying submucosal masses in the upper gastrointestinal tract, it still has some limitations. The main problem is that judgment

of the origin level of the tumor does not match the actual situation. This may be related to incorrect operation and subjective misjudgment of the operator.

For atypical upper gastrointestinal tumors, pathological diagnosis is still the gold standard when CT and EUS imaging findings are uncertain. EUS-FNA examination not only finds submucosal lesions and accurately determines their origin, size and echogenicity, but also directly punctures larger lesions to obtain materials for histological and cytological examination and immunohistochemical staining. It is reported in the literature that the diagnostic accuracy of EUS-FNA for upper gastrointestinal submucosal masses is 95.6%, and its accuracy, sensitivity and specificity in distinguishing benign from potentially malignant lesions are 94.2%, 92.4% and 100.0%, respectively. Combined with immunohistochemical staining, the diagnostic accuracy rate can reach 98%^[19-21]. This shows that EUS-FNA is an effective means to accurately diagnose this type of tumor.

For most upper gastrointestinal leiomyomas, diagnosis is not difficult by barium meal imaging, CT, EUS and other methods. However, the leiomyoma in the present case had the following characteristics. The tumor was large, wide, started from the lower esophagus, involved the cardia and reached the abdominal cavity next to the diaphragm and liver. The boundary with the diaphragm was unclear and the tumor grew outward. Enhanced scanning showed different degrees of enhancement; the echo was not uniform with an abundant blood flow signal within the tumor. These clinical features are more likely to be the characteristics of stromal tumors and other malignant lesions and are less common in leiomyomas. If EUS-FNA is not performed, histological specimens cannot be obtained, which may cause misdiagnosis and miss the opportunity for surgical treatment. Through this case, we have gained more understanding of large leiomyoma of the upper digestive tract and have provided more clinical indicators for diagnosis and treatment of the disease.

CONCLUSION

Abdominal computed tomography and EUS have high diagnostic accuracy for most upper gastrointestinal leiomyomas, but there are still difficulties in the diagnosis of atypical lesions, which can be misdiagnosed as stromal tumors and other malignant lesions. For the diagnosis of such lesions, EUS-FNA is necessary. EUS-FNA examination provides a strong basis for the diagnosis of gastrointestinal tumors of unknown nature and origin. The results are consistent with surgical pathological examination and provide good clinical indicators for final diagnosis and treatment.

REFERENCES

- 1 **Jiang W**, Rice TW, Goldblum JR. Esophageal leiomyoma: experience from a single institution. *Dis Esophagus* 2013; **26**: 167-174 [PMID: 22458777 DOI: 10.1111/j.1442-2050.2012.01345.x]
- 2 **De Giacomo T**, Bruschini P, Arcieri S, Ruberto F, Venuta F, Diso D, Francioni F. Partial oesophagectomy for giant leiomyoma of the oesophagus: report of 7 cases. *Eur J Cardiothorac Surg* 2015; **47**: 143-145 [PMID: 24711507 DOI: 10.1093/ejcts/ezu146]
- 3 **Shin S**, Choi YS, Shim YM, Kim HK, Kim K, Kim J. Enucleation of esophageal submucosal tumors: a single institution's experience. *Ann Thorac Surg* 2014; **97**: 454-459 [PMID: 24360088 DOI: 10.1016/j.athoracsur.2013.10.030]
- 4 **Yekeler E**, Yazicioglu A, Subasi M, Boztepe H. Giant Esophageal Lipoma as an Uncommon Cause of Diverticula. *Case Rep Gastroenterol* 2016; **10**: 446-451 [PMID: 2721731 DOI: 10.1159/000447487]
- 5 **Neoral C**, Aujesky R, Skarda J, Vrba R, Chudáček J, Bohanes T, Vomáček K. Thoracoscopic treatment of benign esophageal tumors. *Wideochir Inne Tech Maloinwazyjne* 2012; **7**: 294-298 [PMID: 23362430 DOI: 10.5114/wiitm.2011.30817]
- 6 **Lee LS**, Singhal S, Brinster CJ, Marshall B, Kochman ML, Kaiser LR, Kucharczuk JC. Current management of esophageal leiomyoma. *J Am Coll Surg* 2004; **198**: 136-146 [PMID: 14698321 DOI: 10.1016/j.jamcollsurg.2003.08.015]
- 7 **Cheng BC**, Chang S, Mao ZF, Li MJ, Huang J, Wang ZW, Wang TS. Surgical treatment of giant esophageal leiomyoma. *World J Gastroenterol* 2005; **11**: 4258-4260 [PMID: 16015702 DOI: 10.3748/wjg.v11.i27.4258]
- 8 **Peters JH**, DeMeester TR. Esophagus and diaphragmatic hernia. In: Brunicaudi FC, Andersen KD, Billiar RT. Schwartz's Principles of Surgery. New York, NY, USA: McGraw-Hill; 2005: 906. Available from: <http://www.docin.com/p-734249480.html>
- 9 **Guo J**, Liu Z, Sun S, Liu X, Wang S, Ge N. Ligation-assisted endoscopic enucleation for treatment of esophageal subepithelial lesions originating from the muscularis propria: a preliminary study. *Dis Esophagus* 2015; **28**: 312-317 [PMID: 24592944 DOI: 10.1111/dote.12192]
- 10 **Sun X**, Wang J, Yang G. Surgical treatment of esophageal leiomyoma larger than 5 cm in diameter: A case report and review of the literature. *J Thorac Dis* 2012; **4**: 323-326 [PMID: 22754674 DOI: 10.3978/j.issn.2072-1439.2011.11.02]

- 11 **Deshpande A**, Nelson D, Corless CL, Deshpande V, O'Brien MJ. Leiomyoma of the gastrointestinal tract with interstitial cells of Cajal: a mimic of gastrointestinal stromal tumor. *Am J Surg Pathol* 2014; **38**: 72-77 [PMID: 24145645 DOI: 10.1097/PAS.0b013e3182a0d134]
- 12 **Yang HK**, Kim YH, Lee YJ, Park JH, Kim JY, Lee KH, Lee HS. Leiomyomas in the gastric cardia: CT findings and differentiation from gastrointestinal stromal tumors. *Eur J Radiol* 2015; **84**: 1694-1700 [PMID: 26051977 DOI: 10.1016/j.ejrad.2015.05.022]
- 13 **Perwaiz A**, Shaw VK, Singh A, Chaudhary A. Extra-mucosal enucleation is still a safe and feasible treatment option of giant esophageal leiomyomas. *Indian J Gastroenterol* 2018; **37**: 63-66 [PMID: 29464545 DOI: 10.1007/s12664-018-0835-z]
- 14 **Kohli DR**, Faigel DO. Esophageal leiomyomas: Making mole hills out of mole hills? *Gastrointest Endosc* 2018; **87**: 378-379 [PMID: 29406926 DOI: 10.1016/j.gie.2017.08.028]
- 15 **Lipnickas V**, Beiša A, Makūnaitė G, Strupas K. Laparoscopic approach in the treatment of large leiomyoma of the lower third of the esophagus. *Wideochir Inne Tech Maloinwazyjne* 2017; **12**: 437-442 [PMID: 29362660 DOI: 10.5114/wiitm.2017.72327]
- 16 **Rösch T**, Kapfer B, Will U, Baronius W, Strobel M, Lorenz R, Ulm K; German EUS Club. Endoscopic ultrasonography. Accuracy of endoscopic ultrasonography in upper gastrointestinal submucosal lesions: a prospective multicenter study. *Scand J Gastroenterol* 2002; **37**: 856-862 [PMID: 12190103 DOI: 10.1080/gas.37.7.856.862]
- 17 **Will U**, Fuedner F, Mueller AK, Meyer F. A prospective study on endoscopic ultrasonography criteria to guide management in upper GI submucosal tumors. *Pol Przegl Chir* 2011; **83**: 63-69 [PMID: 22166282 DOI: 10.2478/v10035-011-0010-z]
- 18 **Franco MC**, Schulz RT, Maluf-Filho F. Opinion: How to manage subepithelial lesions of the upper gastrointestinal tract? *World J Gastrointest Endosc* 2015; **7**: 1262-1267 [PMID: 26675266 DOI: 10.4253/wjge.v7.i18.1262]
- 19 **Moon JS**. Endoscopic ultrasound-guided fine needle aspiration in submucosal lesion. *Clin Endosc* 2012; **45**: 117-123 [PMID: 22866250 DOI: 10.5946/ce.2012.45.2.117]
- 20 **Mekky MA**, Yamao K, Sawaki A, Mizuno N, Hara K, Nafeh MA, Osman AM, Koshikawa T, Yatabe Y, Bhatia V. Diagnostic utility of EUS-guided FNA in patients with gastric submucosal tumors. *Gastrointest Endosc* 2010; **71**: 913-919 [PMID: 20226456 DOI: 10.1016/j.gie.2009.11.044]
- 21 **Akahoshi K**, Oya M, Koga T, Koga H, Motomura Y, Kubokawa M, Gibo J, Nakamura K. Clinical usefulness of endoscopic ultrasound-guided fine needle aspiration for gastric subepithelial lesions smaller than 2 cm. *J Gastrointest Liver Dis* 2014; **23**: 405-412 [PMID: 25531999 DOI: 10.15403/jgld.2014.1121.234.eug]



Published by **Baishideng Publishing Group Inc**
7041 Koll Center Parkway, Suite 160, Pleasanton, CA 94566, USA

Telephone: +1-925-3991568

E-mail: bpgoffice@wjgnet.com

Help Desk: <https://www.f6publishing.com/helpdesk>

<https://www.wjgnet.com>

