

**Name of Journal:** *World Journal of Clinical Cases*

**Manuscript NO:** 59431

**Manuscript Type:** CASE REPORT

**Recurrent Takotsubo cardiomyopathy triggered by emotionally stressful events: A case report**

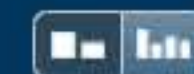Hao-Yu Wu, Gong Cheng, Lei Liang, Yi-Wei Cao

## Abstract

### BACKGROUND

Takotsubo cardiomyopathy (TCM) is characterized by reversible left ventricular dysfunction triggered by emotional or physical stress. Only 1%-2% of patients with acute coronary syndrome are diagnosed with TCM. Although obstructive coronary artery disease is frequently considered to be the cause of chest pain, TCM should be

## Match Overview



There are no matching sources for this report.



国内版

国际版

Recurrent Takotsubo cardiomyopathy triggered by emotionally stre



网页

图片

视频

学术

词典

地图

检测到您输入了英文，试试切换到国际版？ 搜英文结果更丰富更准确



12,300 条结果 时间不限 ▼

## [Takotsubo cardiomyopathy triggered by ... - BMJ Case ...](#) 翻译此页

Cited by: 2

Author: Savvy Nandal, Anastasia Castles, Muham...

Publish Year: 2019

2020-11-3 · **Takotsubo cardiomyopathy** (TC) is acute stress-induced **cardiomyopathy** with characteristic transient wall motion abnormalities. TC has a clinical presentation similar to an acute coronary syndrome, including chest pain or dyspnoea, ECG changes and elevated cardiac enzymes. TC often occurs after emotional stress. There are approximately 50 TC cases reported related to seizure activity, and our ...

<https://casereports.bmj.com/content/12/1/e225924> ▼

## [Takotsubo cardiomyopathy triggered by ... - BMJ Case ...](#)

Cited by: 2

Author: Savvy Nandal, Anastasia Castles, Muham...

Publish Year: 2019

15 Stöllberger C, Fischer H, Pratter A, et al. Seizure-induced **Takotsubo cardiomyopathy** and thrombocytopenia. Eur J Neurol 2011;18:e68–e69. 16 Falconer B, Rajs J. Post-mortem findings of cardiac lesions in epileptics: a preliminary **report**. Forensic Sci 1976;8:63–71. 17 Sakuragi S, Tokunaga N, Okawa K, et al. **A case of takotsubo cardiomyopathy**

<https://casereports.bmj.com/content/bmjcr/12/1/e225924.full.pdf>

## [Takotsubo cardiomyopathy triggered by delirium ...](#) 翻译此页

Author: Abdellah Hedjoudje, Jean-Paul Cervon...

Publish Year: 2020

2020-6-1 · **Takotsubo cardiomyopathy** (TCM) is a reversible **cardiomyopathy** frequently precipitated by acute emotional or physical stressors through excessive catecholamine release . Both alcohol withdrawal (and subsequent development of delirium tremens ) and liver failure are associated with a hyperadrenergic state predisposing to cardiovascular complications.

<https://www.sciencedirect.com/science/article/pii/S2210740119302621>



Recurrent Takotsubo cardiomyopathy triggered by emotionally stres



ALL

IMAGES

VIDEOS

47,400 Results

Any time ▾

## A Case of Recurrent Takotsubo Cardiomyopathy: Not a Benign ...

<https://www.journalmc.org/index.php/JMC/article/view/3011/2342> ▾

Mar 03, 2018 · **Takotsubo cardiomyopathy** is a relatively uncommon **condition triggered** by **severe physical** and/or **emotional stress**. It is characterized by transient ventricular wall dysfunction in the absence of coronary artery disease (CAD). Herein, we **report** a **case** of a 59-year-old female who had three **episodes of recurrent Takotsubo cardiomyopathy**.

**Author:** Anthony H. Kashou, Adam Custer, Nabil... **Publish Year:** 2018

## [PDF] CASE REPORT Open Access Emotional stress as a trigger of ...

<https://jmedicalcasereports.biomedcentral.com/...>

tion change, **emotional** or physical **stress** (e.g., surgery, psychological trauma); and in one-third of patients, no clear precipitant is identified [3]. We present a **case** of **takotsubo cardiomyopathy** (TC) that appears to have been related to a **stressful** life **event** that was believed to have **triggered** a concomitant MG crisis. TC is a

## Recurrent takotsubo with prolonged QT and torsade de ...

<https://www.ncbi.nlm.nih.gov/pmc/articles/PMC5247304>

At present, there have been very few **reports** of **recurrent takotsubo cardiomyopathy**. In this **case report**, we present a patient with multiple **recurrences** of **takotsubo syndrome triggered** by **severe emotional stress** that presented with **recurrent loss** of consciousness, QT prolongation, and polymorphic ventricular tachycardia ( torsade de pointes ) and left ventricular apical **thrombus**.

**Cited by:** 4 **Author:** Alaa Eldin K. Ahmed, Abdulhalim Serafi, Na...

**Publish Year:** 2017

## Lifelong recurrent takotsubo cardiomyopathy: a case report ...

<https://academic.oup.com/ehjcr/article/3/4/1/5606743> ▾

Oct 24, 2019 · Introduction. **Takotsubo cardiomyopathy** mimics acute myocardial infarction in its presentation and has a recognized recurrence rate. 1, 2 So far, the literature focused on the re-occurrence of the syndrome in populations without particular attention to the number of recurrences in a certain individual. We, hereby, present a **case** of a patient having three confirmed recorded recurrences at the ...

**Cited by:** 1 **Author:** Shekinah Chandy, Dana K Dawson

**Publish Year:** 2019

## Takotsubo Cardiomyopathy

Medical Condition

A type of non-ischemic cardiomyopathy in which there is a sudden temporary enlargement of the heart muscles.

Rare (Fewer than 200,000 cases per year in US)

Requires lab test or imaging

Treatment from medical professional advised

Can last several weeks or months

Occurs following extreme emotional stress. Symptom is sudden chest pain. Treatment is medications.

### Symptoms

- Sudden onset of chest pain
- Shortness of breath
- Palpitations
- Nausea/vomiting

### Treatments

Treatment is dependent on the symptoms. The patient is monitored for a minimum of 24 hours.

#### Medication

- ACE inhibitors: Used to reduce blood pressure.  
[Enalapril](#)
- Beta blockers: Used to manage abnormal heart rhythm.  
[Propranolol](#)
- Anticoagulants: May be given for a short period of time to prevent stroke.  
[Warfarin](#)

### Causes



47,100 Results    Any time ▾

### [Lifelong recurrent takotsubo cardiomyopathy: a case report ...](#)

<https://academic.oup.com/ehjcr/article/3/4/1/5606743> ▾

Oct 24, 2019 · Introduction. **Takotsubo cardiomyopathy** mimics acute myocardial infarction in its presentation and has a recognized recurrence rate. 1, 2 So far, the literature focused on the re-occurenc...

Cited by: 1

Author: Shekinah Chandy, Dana K Dawson

Publish Year: 2019

### [PDF] [Takotsubo cardiomyopathy triggered by ... - BMJ Case Reports](#)

<https://casereports.bmj.com/content/bmjcr/12/1/e225924.full.pdf>

**Takotsubo cardiomyopathy** (TC) is acute **stress**-induced **cardiomyopathy** with characteristic transient wall motion abnormalities. TC has a clinical presentation similar to an acute coronary syndrome,...

Cited by: 2

Author: Savvy Nandal, Anastasia Castles, Muham...

Publish Year: 2019

### [Takotsubo cardiomyopathy and pituitary apoplexy: a case report](#)

<https://bmccardiovascdisord.biomedcentral.com/...> ▾

May 19, 2020 · **TTC** is **triggered** by physical or **emotional stressors** and is characterized by a **reduction** in the left ventricular ejection fraction (LVEF) associated with a balloon-like wall motion abnormality, typica...

Author: Chun Yang, Xiu Han, Yuan Du, Ai-qun Ma

Publish Year: 2020

### [A Case of Recurrent Takotsubo Cardiomyopathy: Not a Benign ...](#)

<https://www.journalmc.org/index.php/JMC/article/view/3011/2342> ▾

Mar 03, 2018 · **Takotsubo cardiomyopathy** is a relatively uncommon **condition triggered** by **severe physical** and/or **emotional stress**. It is characterized by transient ventricular wall dysfunction in the...

Author: Anthony H. Kashou, Adam Custer, Nabil...

Publish Year: 2018

### [Reverse Takotsubo Cardiomyopathy in a Patient With Prior ...](#)

<https://www.ncbi.nlm.nih.gov/pmc/articles/PMC6735595>

**Takotsubo cardiomyopathy** is characterized by transient reversible regional hypokinesia of the ventricular myocardium usually extending beyond the territory perfused by a single coronary artery. 2 **Takotsubo...**

Author: Ahmed Rashed, Mohamed Shokr, Ahme


Publish Year: 2019

## Takotsubo Cardiomyopathy

Medical Condition

A type of non-ischemic cardiomyopathy in which there is a sudden temporary enlargement of the heart muscles.

 Rare (Fewer than 200,000 cases per year in US)

 Requires lab test or imaging

 Treatment from medical professional advised

 Can last several weeks or months

Occurs following extreme emotional stress. Symptom is sudden chest pain. Treatment is medications.

### Symptoms

- Sudden onset of chest pain
- Shortness of breath
- Palpitations
- Nausea/vomiting

### Treatments

Treatment is dependent on the symptoms. The patient is monitored for a minimum of 24 hours.

#### Medication

- ACE inhibitors: Used to reduce blood pressure.  
[Enalapril](#)
- Beta blockers: Used to manage abnormal heart rhythm.  
[Propranolol](#)
- Anticoagulants: May be given for a short period of time to prevent stroke.  
[Warfarin](#)