



59450-Manuscript-File-revision.docx

Quotes Included
Bibliography Included8%
SIMILAR

1

Case report: Endoscopic salvage treatment of add-on histoacryl (n-butyl-2-cyanoacrylate) sealing after fully covered metal stent application on the anastomotic leak after proximal gastrectomy

Hee-Sung Kim*, Yook Kim*, Joung-Ho Han

Hee-Sung Kim and Yook Kim have contributed equally to this study.

Match Overview

- | Match Number | Source | Words | Similarity |
|--------------|----------|---|------------|
| 1 | Crossref | 40 words
"27th International Congress of the European Association 1...
Endoscopic Surgery (EAES) Sevilla, Spain, 12-15 June 201 | 4% |
| 2 | Crossref | 23 words
Yu Jin Kim, Sung Kwan Shin, Hyun Jung Lee, Hyun Soo Ch
ung et al. "Endoscopic management of anastomotic leakag... | 2% |
| 3 | Internet | 12 words
crawled on 04-May-2020
www.arjonline.org | 1% |
| 4 | Crossref | 7 words
Neil Jones, Wolfgang Sperl, Johannes Koch, Heidemarie Ho
lzmann, Wolfgang Radauer. "TICK-BORNE ENCEPHALITIS | 1% |
| 5 | Crossref | 7 words
"ESOPHAGUS", The American Journal of Gastroenterology,
9/2007 | 1% |

激活 Windows

转到“设置”以激活 Windows

Text-Only Report



ALL

IMAGES

VIDEOS

157 Results

Any time ▾

[Endoscopic devices and techniques for the management of ...](#)

<https://www.sciencedirect.com/science/article/pii/S0016510720341432>

Sep 01, 2020 · Fully or partially covered esophageal SEMSs can be used in the treatment of stenosis after sleeve gastrectomy or management of acute or early postoperative leaks to allow for diversion of gastric contents. 99, 100 The stent should span from the distal esophagus to beyond the incisura or site of downstream stenosis to seal the leak site and ...

Author: Allison R. Schulman, Rabindra R. Wa... Publish Year: 2020

[Endoscopic management of postoperative fistulas and leaks ...](#)

<https://www.e-sciencecentral.org/articles/SC000024064> ▾

Mar 31, 2017 · Postoperative leaks after esophagectomy occur in up to 35% of cases¹⁷ and 4% to 27% after gastrectomy, carrying a mortality as high as 65%.^{18,19} Intrathoracic leak following esophagectomy carries higher mortality compared to cervical leak²⁰ and if there is a delay in treatment for over 24 hours, mortality approaches as high as 50%.²¹ Endoscopic ...

Cited by: 2

Author: Prathab Devaraj, Hemanth Gavini

Publish Year: 2017

[Endoscopic management of gastrointestinal perforations ...](#)

europepmc.org/articles/PMC4588076

Oct 01, 2015 · INTRODUCTION. Gastrointestinal perforations may result from endoscopic or laparoscopic procedures, or they can be spontaneous (e.g., Boerhaave syndrome). Although the majority of perforations during endoscopic procedures are adverse events, the increasing use of advanced endoscopic techniques, including natural orifice transluminal endoscopic surgery (NOTES), or the ...

Cited by: 33

Author: Pawel Rogalski, Jaroslaw Daniluk, Andr...

Publish Year: 2015

[Endoscopic management of postsurgical leaks - ScienceCentral](#)

<https://www.e-sciencecentral.org/articles/SC000014440> ▾

Mar 31, 2016 · Clips were applied in 12 patients (55%); 5 simultaneously with stents and 7 after stent removal. An average of 1.4 stents and 2.8 endoscopic procedures were required per patient. Primary success after 1 endoscopic procedure occurred in 59% while long-term success was achieved in ...

Cited by: 1

Author: Hany Shehab

Publish Year: 2016



ALL

IMAGES

VIDEOS



Add the Give with Bing extension >

83 Results

Any time ▼

Endoscopic devices and techniques for the management of ...

<https://www.sciencedirect.com/science/article/pii/S0016510720341432>

Sep 01, 2020 · **Fully** or partially **covered** esophageal SEMSs can be used in the **treatment** of stenosis **after** sleeve **gastrectomy** or management of acute or early postoperative leaks to allow for diversion of gastric contents. 99, 100 The **stent** should span from the distal esophagus to beyond the incisura or site of downstream stenosis to seal the **leak** site and ...

Author: Allison R. Schulman, Rabindra R. Watso... **Publish Year:** 2020

E-Poster Presentations - C) Endoscopy - 2017 - Journal of ...

<https://onlinelibrary.wiley.com/doi/10.1111/jgh.13881>

Discussion and Conclusion : **Endoscopic treatment** outcomes for PFCs were satisfactory in CP, S, and PC. The AP **treatment** outcome, particularly in ANC/WON, was insufficient. Improvement of techniques and devices (e.g., lumen apposing **metal stent** usage) is desired. # P-0347

Endoscopic management of postoperative fistulas and leaks ...

<https://www.e-sciencecentral.org/articles/SC000024064> ▼

Mar 31, 2017 · Postoperative leaks **after** esophagectomy occur in up to 35% of cases¹⁷ and 4% to 27% **after gastrectomy**, carrying a mortality as high as 65%.^{18,19} Intrathoracic **leak** following esophagectomy

Search Tools

[Turn on Hover Translation \(开启取词\)](#)

激活 Windows

转到“设置”以激活 Windows

[Feedback](#)

75,100 Results Any time ▾

Prevalence of Nonalcoholic Fatty Liver Disease in Patients ...

<https://academic.oup.com/ibdjournal/advance...>

Aug 11, 2020 · Both **diseases** involve a complex relationship between environment and polygenic **factors**, with immune dysregulation also playing a central role. 9 **Nonalcoholic fatty liver disease** is associated with diabetes, obesity, and the metabolic syndrome; however, there are a subset of **patients** who have "lean NAFLD". 10 Although the incidence of ...

Nonalcoholic Fatty Liver Disease in Inflammatory Bowel ...

<https://pubmed.ncbi.nlm.nih.gov/29688336>

Background: **Nonalcoholic fatty liver disease** (NAFLD) is common in **inflammatory bowel diseases** (IBD). Herein, NAFLD **prevalence and risk factors** in a large IBD cohort were evaluated and compared to that of a non-IBD sample. Methods: Crohn's **disease**/ulcerative colitis outpatients referred to IBD service of our Gastroenterology Unit were enrolled.

Cited by: 12 **Author:** Mariabeatrice Principi, Andrea Iannone, Giu...

Publish Year: 2018

Prevalence of and risk factors for nonalcoholic fatty ...

<https://aasldpubs.onlinelibrary.wiley.com/doi/full/10.1002/hep.20734>

May 13, 2005 · The **prevalence** of and the **risk factors** for **fatty liver** have not undergone a formal evaluation in a representative sample of the general population. We therefore performed a **cross-sectional** study in the town of Campogalliano (Modena, Italy), within the ...

Cited by: 1592 **Author:** Giorgio Bedogni, Lucia Miglioli, Flora Masut...

Publish Year: 2005

Prevalence of Nonalcoholic Fatty Liver Disease in Patients ...

<https://www.researchgate.net/publication/343597805...>

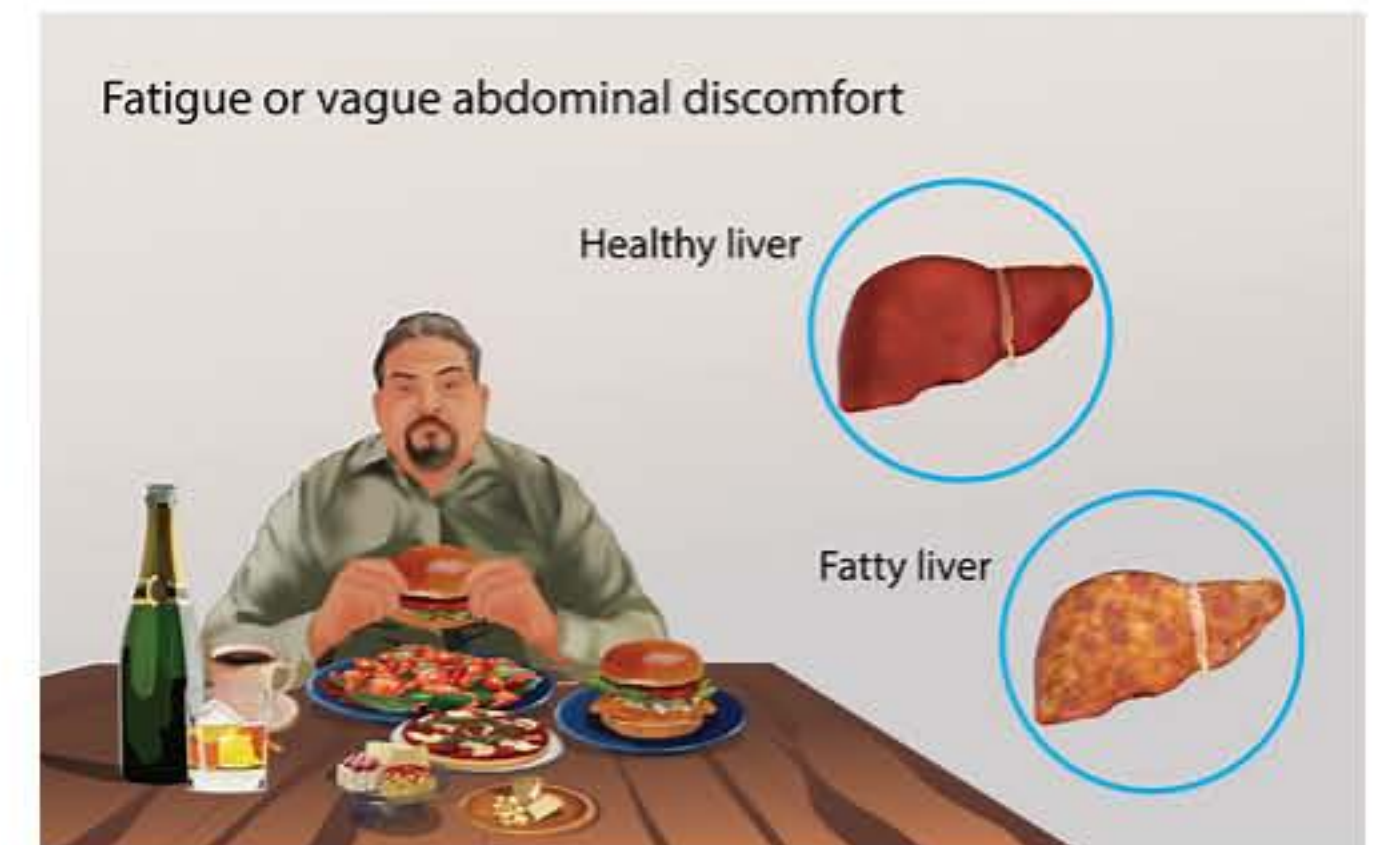
Non-alcoholic fatty liver disease (NAFLD) can be detected in up to 33.6% of **inflammatory bowel disease** (IBD) **patients**, often in absence of metabolic **risk factors**.

Prevalence and factors associated with nonalcoholic fatty ...

<https://www.ncbi.nlm.nih.gov/pmc/articles/PMC6039627>

Fatty Liver

Medical Condition



Excessive build-up of fat in the liver.

- Very common (More than 3 million cases per year in US)
- No vaccine available
- Requires lab test or imaging
- Treatment from medical professional advised
- Can last several weeks or months

The causes are alcoholism, obesity, diabetes and infections. Symptoms are weakness, weightloss and abdominal discomfort. Treatment includes attending the underlying cause.

Symptoms

Fatty liver could be symptomless for many years or decades. Notable symptoms include: