



59495_Auto_Edited.docx

Quotes Excluded
Bibliography Excluded3%
SIMILAR**Name of Journal:** *World Journal of Clinical Cases***Manuscript NO:** 59495**Manuscript Type:** CASE REPORT**Gastroesophageal varices in a patient presenting with essential thrombocythemia: A case report**

A case report of Gastroesophageal varices

Jian-Bo Wang, Yang Gao, Junwei Liu, Mugen Dai, Shangwen Yang, Bin Ye

Match Overview

1

Internet 28 words
crawled on 26-Aug-2020
www.wjgnet.com

2%

2

Crossref 16 words
Nath, Shriram V., David Westerman, Lynda J. Campbell, and John F. Seymour. "Clonal "devolution" in a case of essential

1%



Gastroesophageal varices in a patient presenting with essential thro



ALL

IMAGES

VIDEOS

110,000 Results

Any time ▾

[Isolated gastric varices in a patient with essential ...](#)

<https://pubmed.ncbi.nlm.nih.gov/30359570>

Isolated gastric **varices** in a patient with **essential thrombocythemia**. Isolated gastric **varices** in a patient with **essential thrombocythemia** Gastrointest Endosc. 2019 Feb;89(2):435-436. doi: 10.1016/j.gie.2018.10.016. ... **Esophageal** and Gastric **Varices** / diagnostic imaging

Author: Alex M. Kesler, Omar Y. Mousa, Bea... **Publish Year:** 2019

[Isolated gastric varices in a patient with essential ...](#)

<https://www.ncbi.nlm.nih.gov/pubmed/30359570>

1. Gastrointest Endosc. 2019 Feb;89(2):435-436. doi: 10.1016/j.gie.2018.10.016. Epub 2018 Oct 22. Isolated gastric **varices** in a patient with **essential thrombocythemia**.

Author: Alex M. Kesler, Omar Y. Mousa, Bea... **Publish Year:** 2019

[Isolated Gastric Varices due to Essential Thrombocytosis ...](#)

<https://www.ncbi.nlm.nih.gov/pmc/articles/PMC6890150>

We present a case of a patient with essential thrombocytosis and obscure-overt GI bleeding, who was diagnosed with gastric varices only after multiple presentations. Essential thrombocytosis is associated with **gastro-intestinal vascular thrombosis** . Multiple Doppler studies of the splenic vein also failed to reveal any splenic vein thrombosis to explain the etiology of the isolated gastric varices.

Cited by: 1 **Author:** Harish Patel, Peter Bhandari, Kishore K...

Publish Year: 2019

[Essential Thrombocytosis Treated with Percutaneous ...](#)

<https://www.mountsinai.org/about/patient-stories/...> ▾

Essential Thrombocytosis Treated with Percutaneous Mesocaval Shunt ... **esophageal varices**, fluid in my lungs, and the need for over 20 transfusions. I had major clots but also major bleeds at the same time. They were finally able to perform a TIPS procedure where they were able to re-establish



ALL

IMAGES

VIDEOS



Add the Give with Bing extension >

56,500 Results

Any time ▾

Isolated Gastric Varices due to Essential Thrombocytosis ...

<https://www.cureus.com/articles/23850-isolated...> ▾

We present a case of a patient with essential thrombocytosis and obscure-overt **GI bleeding**, who was diagnosed with gastric varices only after multiple presentations. Essential thrombocytosis is associated with gastro-intestinal vascular thrombosis . Multiple Doppler studies of the splenic vein also failed to reveal any splenic vein thrombosis to explain the etiology of the isolated gastric varices.

Cited by: 1

Author: Harish Patel, Peter Bhandari, Kishore Kuma...

Publish Year: 2019

Essential Thrombocythemia Complicated with Portal Vein ...

<https://abstracts.isth.org/abstract/essential...> ▾

Background: **Essential thrombocythemia** (ET) is a myeloproliferative neoplasm characterized by excessive, clonal platelet production and increased risk of thrombotic complications. Aims: **Case report** of a **patient** with ET complicated with chronic portal vein thrombosis (PVT) with liver cirrhosis, and treatment approach. Methods: A 27-year-old man was admitted in the clinic for diagnostic work-up ...

Successful Treatment of Bleeding Gastric Varices with ...

<https://www.hindawi.com/journals/cris/2013/273531/citations> ▾

Search Tools

Turn on Hover Translation (开启取词)

ALL

IMAGES

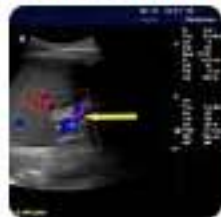
VIDEOS

53,400 Results

Any time ▾

Isolated Gastric Varices due to Essential Thrombocytosis ...

<https://www.cureus.com/articles/23850-isolated...> ▾



We present a case of a patient with essential thrombocytosis and obscure-overt GI bleeding, who was diagnosed with gastric varices only after multiple presentations. ...

Cited by: 1

Author: Harish Patel, Peter Bhandari, Kis...

Publish Year: 2019

Search Tools

Turn off Hover Translation (关闭取词)

Successful Treatment of Bleeding Gastric Varices with ...

<https://www.hindawi.com/journals/cris/2013/273531/citations> ▾

We present a case of gastric variceal bleeding caused by prehepatic venous thrombosis from essential thrombocythemia that was successfully treated with therapeutic splenectomy. 2. Case Report. A 59-year-old female with a history of essential thrombocythemia and heterozygous prothrombin gene mutation was hospitalized for abdominal pain.

Cited by: 2

Author: Lior Menasherian-Yaccobe, Nathan T. Jaq...

Publish Year: 2013

Essential Thrombocythemia Complicated with Portal Vein ...

<https://abstracts.isth.org/abstract/essential...> ▾

Background: Essential thrombocythemia (ET) is a myeloproliferative neoplasm characterized by excessive, clonal platelet production and increased risk of thrombotic complications. Aims: Case report of a patient with ET complicated with chronic portal vein thrombosis (PVT) with liver cirrhosis, and treatment approach. Methods: A 27-year-old man was admitted in the clinic for diagnostic work-up ...

[PDF] Case Report Successful Treatment of Bleeding Gastric ...

<downloads.hindawi.com/journals/cris/2013/273531.pdf>

Gastric varices are less common than esophageal varices in patients with portal hypertension, occurring in up to % of patients []. ... We present a case of ... bosis from essential thrombocythemia that was successfully treated with therapeutic splenectomy. 2. Case Report

Anticoagulation in Gastroesophageal Varices and JAK2 ...

<https://www.clinicaltrials.gov/ct2/show/NCT04527666> ▾

Myeloproliferative neoplasms (MPNs), including polycythemia vera, essential thrombocythemia, and primary myelofibrosis, may lead to gastroesophageal varices. The quality of life, morbidity, and mortality of MPN patients mainly depend on disease-related symptoms, thromboembolic and ...

1. Introduction

<https://downloads.hindawi.com/journals/cris/2013/273531.xml>