

# World Journal of *Clinical Urology*

*World J Clin Urol* 2021 April 24; 10(1): 1-6



**CASE REPORT**

- 1 Perinephric urinoma, an unusual upper tract presentation of a lower tract injury following retroperitoneoscopy: A case report

*Kumaran A, Yeung PM, Tiwari R*

**ABOUT COVER**

Editorial Board Member of *World Journal of Clinical Urology*, Bedeir Ali-El-Dein, PhD, Professor, Department of Urology, Urology and Nephrology Center, Mansoura University, Mansoura 35516, Egypt. balieldein@yahoo.com

**AIMS AND SCOPE**

The primary aim of *World Journal of Clinical Urology* (WJCU, *World J Clin Urol*) is to provide scholars and readers from various fields of urology with a platform to publish high-quality basic and clinical research articles and communicate their research findings online.

WJCU mainly publishes articles reporting research results and findings obtained in the field of urology and covering a wide range of topics including andrology, benign prostatic hyperplasia, diagnostic imaging, endoscopy, genital diseases, incontinence, minimally invasive therapy, pharmacology, renal transplantation, urinary reconstruction, urinary tract stones, urodynamics and urinary dysfunction, urogenital abnormalities, urogenital neoplasms, urogenital surgical procedures, and urologic diseases.

**INDEXING/ABSTRACTING**

*World Journal of Clinical Urology* is now indexed in China National Knowledge Infrastructure (CNKI), China Science and Technology Journal Database (CSTJ), and Superstar Journals Database.

**RESPONSIBLE EDITORS FOR THIS ISSUE**

Production Editor: Li-Li Wang, Production Department Director: Yun-Xiaoqian Wu, Editorial Office Director: Ya-Juan Ma.

**NAME OF JOURNAL**

*World Journal of Clinical Urology*

**ISSN**

ISSN 2219-2816 (online)

**LAUNCH DATE**

December 28, 2011

**FREQUENCY**

Continuous Publication

**EDITORS-IN-CHIEF**

Olivier Abbo, Jian Lu

**EDITORIAL BOARD MEMBERS**

<https://www.wjgnet.com/2219-2816/editorialboard.htm>

**PUBLICATION DATE**

April 24, 2021

**COPYRIGHT**

© 2021 Baishideng Publishing Group Inc

**INSTRUCTIONS TO AUTHORS**

<https://www.wjgnet.com/bpg/gerinfo/204>

**GUIDELINES FOR ETHICS DOCUMENTS**

<https://www.wjgnet.com/bpg/GerInfo/287>

**GUIDELINES FOR NON-NATIVE SPEAKERS OF ENGLISH**

<https://www.wjgnet.com/bpg/gerinfo/240>

**PUBLICATION ETHICS**

<https://www.wjgnet.com/bpg/GerInfo/288>

**PUBLICATION MISCONDUCT**

<https://www.wjgnet.com/bpg/gerinfo/208>

**ARTICLE PROCESSING CHARGE**

<https://www.wjgnet.com/bpg/gerinfo/242>

**STEPS FOR SUBMITTING MANUSCRIPTS**

<https://www.wjgnet.com/bpg/GerInfo/239>

**ONLINE SUBMISSION**

<https://www.f6publishing.com>



## Perinephric urinoma, an unusual upper tract presentation of a lower tract injury following retroperitoneoscopy: A case report

Arjunan Kumaran, Po Man Yeung, Raj Tiwari

**ORCID number:** Arjunan Kumaran 0000-0002-3746-4787; Po Man Yeung 0000-0002-0656-2181; Raj Tiwari 0000-0003-3893-5859.

**Author contributions:** Kumaran A drafted the manuscript under the guidance of Tiwari R and Yeung PM; all authors have read and approved the final manuscript.

**Informed consent statement:** Only de-identified patient specific information was used in this manuscript. Written informed consent is waived by our institutional review board.

**Conflict-of-interest statement:** The authors have no conflicts of interest to declare.

**CARE Checklist (2016) statement:** The authors have read the CARE Checklist (2016), and the manuscript was prepared and revised according to the CARE Checklist (2016).

**Open-Access:** This article is an open-access article that was selected by an in-house editor and fully peer-reviewed by external reviewers. It is distributed in accordance with the Creative Commons Attribution NonCommercial (CC BY-NC 4.0) license, which permits others to distribute, remix, adapt, build upon this work non-commercially,

**Arjunan Kumaran, Raj Tiwari,** Department of Urology, Sengkang General Hospital, Singapore 544886, Singapore

**Po Man Yeung,** Department of Surgery, Sengkang General Hospital, Singapore 544886, Singapore

**Corresponding author:** Raj Tiwari, FRCS, Consultant, Department of Urology, Sengkang General Hospital, 110 Sengkang E Way, Singapore 544886, Singapore.  
[raj.vikesh.p.k.t@singhealth.com.sg](mailto:raj.vikesh.p.k.t@singhealth.com.sg)

### Abstract

#### BACKGROUND

A 66-year-old lady was referred to urology for a suspected urinoma after retroperitoneoscopy done for debridement of a retroperitoneal abscess that developed following a duodenal perforation.

#### CASE SUMMARY

Serous contents of the drain sent for fluid creatinine were elevated confirming this and computed tomography urography findings suggested an upper tract injury with urinoma around the kidney. However, the antegrade nephrostogram suggested otherwise and on flexible cystoscopy and cystogram, an extraperitoneal bladder perforation was instead identified, with tip of retroperitoneal drain sitting inside the bladder.

#### CONCLUSION

This case identifies a limitation in the usual diagnostic approach for such injuries and emphasizes the need to exercise caution when managing them especially when they occur after several surgical procedures and in the presence of multiple surgical drains.

**Key Words:** Urinoma; Urinary tract injury; Retroperitoneoscopy; Complication; Diagnosis; Radiology; Case report

©The Author(s) 2021. Published by Baishideng Publishing Group Inc. All rights reserved.

**Core Tip:** This study reports a 66-year-old lady who was referred to urology for a

and license their derivative works on different terms, provided the original work is properly cited and the use is non-commercial. See: <http://creativecommons.org/licenses/by-nc/4.0/>

**Manuscript source:** Unsolicited manuscript

**Specialty type:** Urology and nephrology

**Country/Territory of origin:** Singapore

**Peer-review report's scientific quality classification**

Grade A (Excellent): 0  
Grade B (Very good): B, B  
Grade C (Good): C  
Grade D (Fair): 0  
Grade E (Poor): 0

**Received:** September 23, 2020

**Peer-review started:** September 23, 2020

**First decision:** December 11, 2020

**Revised:** December 12, 2020

**Accepted:** April 7, 2021

**Article in press:** April 7, 2021

**Published online:** April 24, 2021

**P-Reviewer:** Balzarro M, Esposito C

**S-Editor:** Gao CC

**L-Editor:** A

**P-Editor:** Wang LL



suspected urine leak after retroperitoneoscopy. This case identifies a limitation in the usual diagnostic approach for such injuries and emphasizes the need to exercise caution when managing them especially when they occur after several surgical procedures and in the presence of multiple surgical drains.

**Citation:** Kumaran A, Yeung PM, Tiwari R. Perinephric urinoma, an unusual upper tract presentation of a lower tract injury following retroperitoneoscopy: A case report. *World J Clin Urol* 2021; 10(1): 1-6

**URL:** <https://www.wjgnet.com/2219-2816/full/v10/i1/1.htm>

**DOI:** <https://dx.doi.org/10.5410/wjcu.v10.i1.1>

## INTRODUCTION

Bowel perforation is an uncommon complication of endoscopy but can be associated with significant morbidity. This is especially so in the duodenum after procedures such as endoscopic retrograde cholangiopancreatography<sup>[1]</sup> and endoscopic submucosal dissection (ESD)<sup>[2]</sup>. When recognised early, primary repair can be performed but these perforations may recur and progress to form retroperitoneal collections and abscesses<sup>[3]</sup>.

As these abscesses can be complicated (multiple, loculated and contain gas forming micro-organisms) as well as difficult to access, a step-up approach is employed to manage them<sup>[4]</sup>. Retroperitoneoscopy is one option that offers a minimally invasive approach through which debridement can be performed<sup>[5]</sup>.

Urinary tract injury can occur during retroperitoneal surgery but is fortunately rare<sup>[6]</sup>. Drain fluid analysis for creatinine confirms the diagnosis while contrast extravasation seen on computed tomography (CT) urography localizes the site of injury. This is crucial as the prognosis and subsequent management of upper tract injuries differ greatly from lower tract ones.

## CASE PRESENTATION

### Chief complaints

A 66-year-old lady who was referred to urology for a suspected urine leak after retroperitoneoscopy.

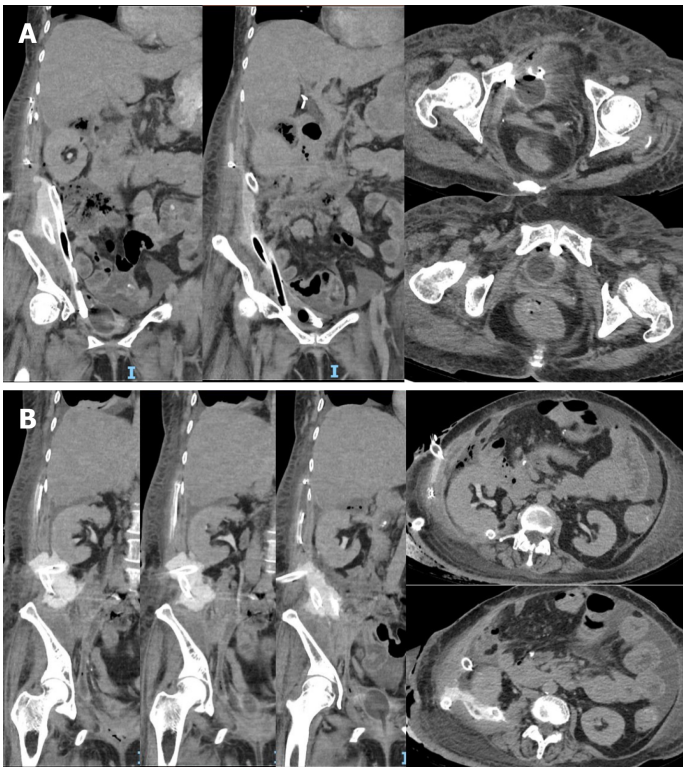
### History of present illness

Three days following her last debridement, serous and straw-coloured fluid was observed from a 32Fr drain that was placed through her right flank directed posterior to the right kidney. Drain fluid creatinine was elevated at 650 µmol/L and a CT urography revealed a perinephric urinoma with no pooling of contrast seen around the bladder. There were two other 32Fr drains directed towards the pelvis through the right upper quadrant and flank respectively. Figures 1A and B demonstrate the location of the perinephric urinoma and surgical drains.

### History of past illness

She underwent ESD of a duodenal polyp by general surgery 2 months prior for which the histology was a tubular adenoma with low grade dysplasia. Intra-operatively, a perforation was noted and closed with clips but unfortunately, this recurred post-operatively and a retroperitoneal abscess developed. She underwent a laparotomy, duodenojejunostomy with Roux-en-Y reconstruction and feeding jejunostomy creation.

Her post-operative recovery was stormy, requiring a 3 day stay in the intensive care unit for mechanical ventilation and inotropic support as well as percutaneous drainage by interventional radiology and further surgical debridement thrice, two of which were done endoscopically.



**Figure 1** Coronal and axial views of computed tomography urography. A: Drains through right upper quadrant and flank directed inferiorly into the pelvis; B: The perinephric urinoma and right flank drain directed posterior to the right kidney.

### ***Personal and family history***

She has a past medical history of hypertension, hyperlipidemia, type 2 diabetes mellitus, treated pulmonary tuberculosis and lumbar spondylosis with radiculopathy. Her past surgical history includes a L5/S1 laminectomy and fusion with posterior instrumentation, cholecystectomy and hysterectomy. She neither smokes nor drinks, is independent in her activities of daily living, works as a porter in the hospital and stays with her daughter who offers good social support.

### ***Physical examination***

An indwelling urinary catheter (IDC) and percutaneous nephrostomy (PCN) were inserted for urinary diversion. The antegrade nephrostogram (Figure 2) performed during PCN insertion demonstrated good flow of contrast down an intact ureter into the bladder without any leakage around the kidney. In addition, contrast was seen within the lumen of one of the surgical drains in the pelvis.

### ***Laboratory examinations***

Fluid from all drains were analyzed found to have raised levels of creatinine ranging from 280  $\mu\text{mol/L}$  to 621  $\mu\text{mol/L}$ . Serum creatinine was not elevated at 43  $\mu\text{mol/L}$ .

### ***Imaging examinations***

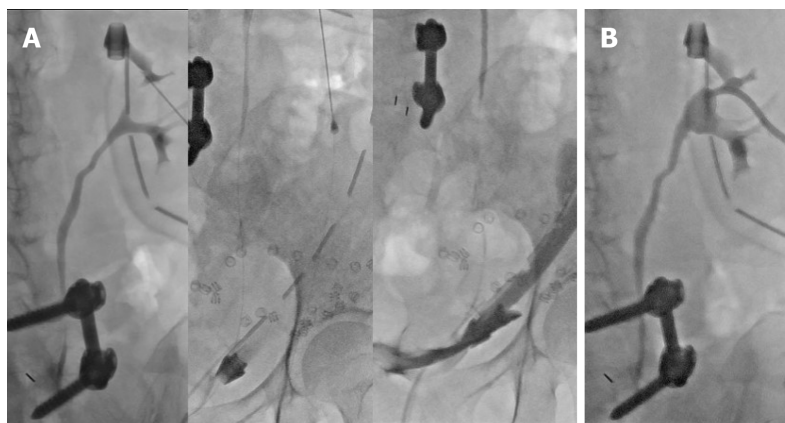
A flexible cystoscopy (Figure 3) was performed which visualized the tip of the right flank surgical drain within the bladder.

A cystogram (Figure 4A) performed in the same sitting demonstrated contrast instilled through the IDC travelled up the surgical drain.

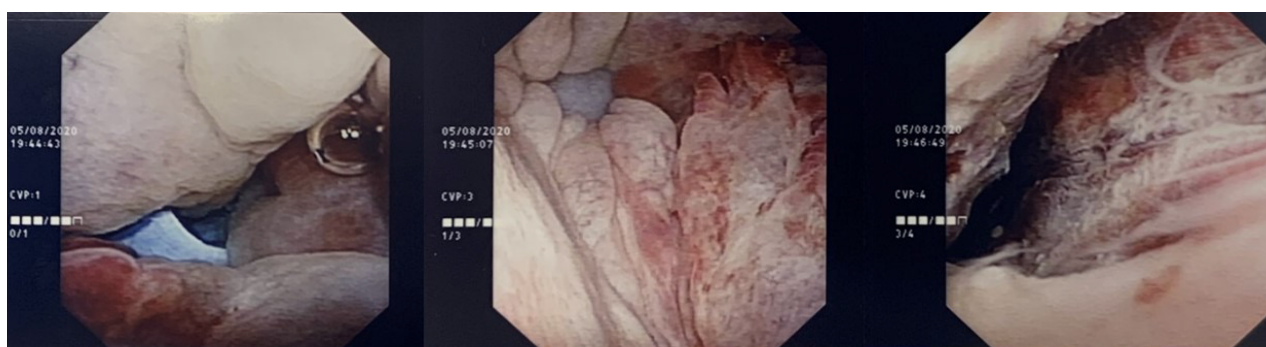## **FINAL DIAGNOSIS**

The patient unfortunately suffered an extraperitoneal bladder perforation after retroperitoneoscopy.





**Figure 2 Antegrade nephrostogram via an upper pole puncture.** A: Smooth flow of contrast down an intact ureter into the bladder and up a surgical drain; B: Satisfactory percutaneous nephrostomy position post-procedure.



**Figure 3 Intra-operative photographs demonstrating the surgical drain within the bladder (left most), surrounding cystitis (middle) and the site of perforation tracking upwards toward the retroperitoneum (right most).**

## TREATMENT

Under direct vision, the right flank drain was withdrawn and the site of injury inspected. With the flexible cystoscope directed away from the site of perforation, a guide wire was passed and a new IDC inserted over it using a Seldinger technique. A repeat cystogram (Figure 4B) demonstrated contrast within the bladder which did not enter the right flank surgical drain.

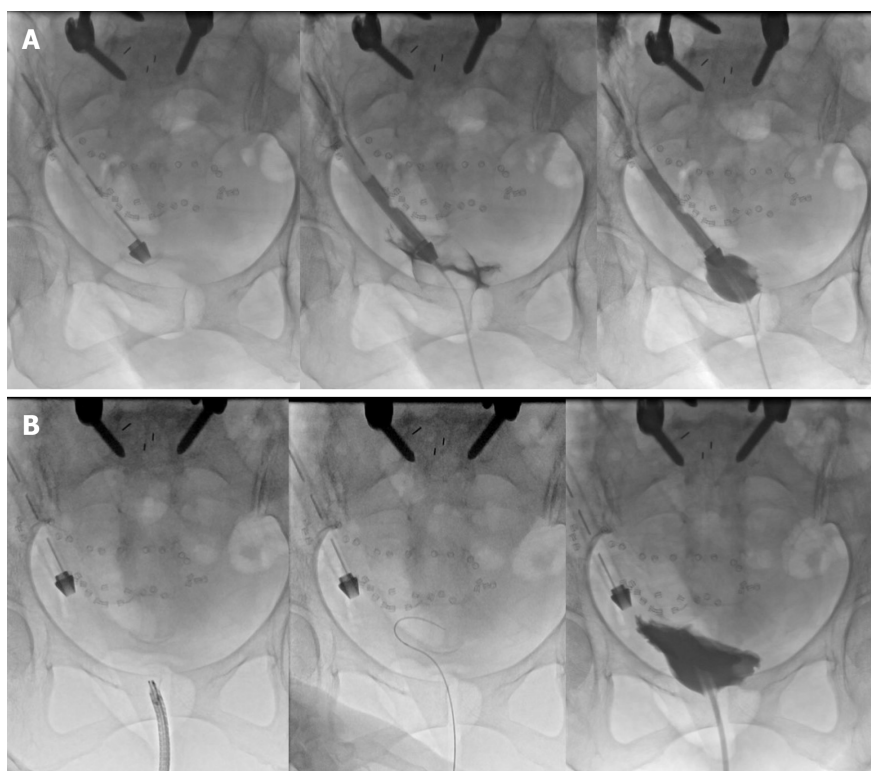
## OUTCOME AND FOLLOW-UP

The patient's extraperitoneal bladder perforation was managed conservatively with a large 20Fr indwelling catheter left in the bladder. The retroperitoneal drain within the bladder was withdrawn cranially out of the bladder to sit cranially in the retroperitoneum. Drain outputs decreased subsequently with increased urine output in the catheter. An interval check cystogram was arranged 4 weeks after.

## DISCUSSION

The patient's initial investigations, namely, the elevated perinephric drain creatinine and urinoma suggested an upper urinary tract injury (*i.e.*, pelvicalyceal or ureteric). This was in keeping with the lack of pooling of contrast seen within the pelvis.

However, there was no perinephric leak of contrast seen on the antegrade nephrostogram which prompted the authors to re-evaluate our provisional diagnosis. Contrast flowed freely down an intact ureter and was seen within the lumen of one of the pelvic drains, which suggested a lower urinary tract injury (*i.e.*, bladder). This was later confirmed on flexible cystoscopy and cystogram.



**Figure 4 Cystogram images.** A: Contrast instilled through the indwelling urinary catheter travelled up the surgical drain; B: Contrast within the bladder which did not enter the right flank surgical drain.

Even though drain fluid from the other surgical drains did not appear like urine, samples taken showed elevated creatinine. This suggested that the leak was fairly large such that urine was being drained by all the surgical drains. Serum creatinine was also checked and not found to be elevated, which can occur in intra-peritoneal urine leaks due to peritoneal reabsorption.

The authors postulate that most of the contrast administered during CT urography travelled down the collecting system and out the surgical drain that had perforated the bladder. A small amount likely leaked around this drain and settled in the right perinephric space as it was dependent and not directly drained by another surgical drain, giving rise to the perinephric urinoma.

## CONCLUSION

Creatine levels in serum and drain fluid (from all drains, even if they do not appear like urine) should be checked. When serum levels are not elevated, an intra-peritoneal urine leak is less likely. When multiple drain fluid samples have elevated creatinine, the possibility of a large leak or multiple leaks should be considered. CT urography is useful in localizing the site of urine leak but interpretation may be difficult in cases of altered anatomy and in the presence of multiple large bore surgical drains. Prior to CT scanning, all surgical drains (including IDC) should be clamped so as not to confound the results. Antegrade nephrostograms and (retrograde) cystograms are valuable in confirming the site of urine leak and can help assess the extent of injury. A flexible cystoscopy can afford direct visualization of bladder injuries and is a simple procedure under local anaesthesia that can be performed in the same setting as a cystogram.

## REFERENCES

- 1 **Guerra F**, Giuliani G, Coletta D, Bonapasta SA, Levi Sandri GB. Clinical outcomes of ERCP-related retroperitoneal perforations. *Hepatobiliary Pancreat Dis Int* 2017; **16**: 160-163 [PMID: [28381379](#) DOI: [10.1016/s1499-3872\(16\)60106-6](#)]
- 2 **Andromanakos N**, Filippou D, Skandalakis P, Kouraklis G, Kostakis A. An extended retroperitoneal abscess caused by duodenal diverticulum perforation: report of a case and short review of the literature.



- Am Surg* 2007; **73**: 85-88 [PMID: [17249465](#) DOI: [10.1177/000313480707300120](#)]
- 3 **Ohara Y**, Takimoto K, Toyonaga T, Yamaguchi T, Sakaguchi H, Kawara F, Tanaka S, Ishida T, Morita Y, Umegaki E. Enormous postoperative perforation after endoscopic submucosal dissection for duodenal cancer successfully treated with filling and shielding by polyglycolic acid sheets with fibrin glue and computed tomography-guided abscess puncture. *Clin J Gastroenterol* 2017; **10**: 524-529 [PMID: [29094323](#) DOI: [10.1007/s12328-017-0791-7](#)]
  - 4 **Eid AI**, Mueller P, Thabet A, Castillo CF, Fagenholz P. A Step-Up Approach to Infected Abdominal Fluid Collections: Not Just for Pancreatitis. *Surg Infect (Larchmt)* 2020; **21**: 54-61 [PMID: [31429662](#) DOI: [10.1089/sur.2019.056](#)]
  - 5 **Tu Y**, Jiao H, Tan X, Wang D, Du J, Sun L, Zhang W. Retroperitoneal laparoscopic debridement and drainage of infected retroperitoneal necrosis in severe acute pancreatitis. *Asian J Surg* 2013; **36**: 159-164 [PMID: [23786806](#) DOI: [10.1016/j.asjsur.2013.04.003](#)]
  - 6 **Lombardo R**, Martos R, Ribal MJ, Alcaraz A, Tubaro A, De Nunzio C. Retroperitoneoscopy in urology: a systematic review. *Minerva Urol Nefrol* 2019; **71**: 9-16 [PMID: [30607927](#) DOI: [10.23736/S0393-2249.18.03235-6](#)]



Published by **Baishideng Publishing Group Inc**  
7041 Koll Center Parkway, Suite 160, Pleasanton, CA 94566, USA

**Telephone:** +1-925-3991568

**E-mail:** [bpgoffice@wjgnet.com](mailto:bpgoffice@wjgnet.com)

**Help Desk:** <https://www.f6publishing.com/helpdesk>

<https://www.wjgnet.com>

