

World Journal of *Clinical Cases*

World J Clin Cases 2020 December 26; 8(24): 6213-6545



MINIREVIEWS

- 6213 Role of gut microbiome in regulating the effectiveness of metformin in reducing colorectal cancer in type 2 diabetes

Huang QY, Yao F, Zhou CR, Huang XY, Wang Q, Long H, Wu QM

ORIGINAL ARTICLE

Retrospective Cohort Study

- 6229 Impact factors of lymph node retrieval on survival in locally advanced rectal cancer with neoadjuvant therapy

Mei SW, Liu Z, Wang Z, Pei W, Wei FZ, Chen JN, Wang ZJ, Shen HY, Li J, Zhao FQ, Wang XS, Liu Q

Retrospective Study

- 6243 Three-year follow-up of Coats disease treated with conbercept and 532-nm laser photocoagulation

Jiang L, Qin B, Luo XL, Cao H, Deng TM, Yang MM, Meng T, Yang HQ

- 6252 Virus load and virus shedding of SARS-CoV-2 and their impact on patient outcomes

Chen PF, Yu XX, Liu YP, Ren D, Shen M, Huang BS, Gao JL, Huang ZY, Wu M, Wang WY, Chen L, Shi X, Wang ZQ, Liu YX, Liu L, Liu Y

- 6264 Risk factors for *de novo* hepatitis B during solid cancer treatment

Sugimoto R, Furukawa M, Senju T, Aratake Y, Shimokawa M, Tanaka Y, Inada H, Noguchi T, Lee L, Miki M, Maruyama Y, Hashimoto R, Hisano T

- 6274 Cause analysis and reoperation effect of failure and recurrence after epiblepharon correction in children

Wang Y, Zhang Y, Tian N

Clinical Trials Study

- 6282 Effects of different acupuncture methods combined with routine rehabilitation on gait of stroke patients

Lou YT, Yang JJ, Ma YF, Zhen XC

Observational Study

- 6296 Application of endoscopic submucosal dissection in duodenal space-occupying lesions

Li XY, Ji KY, Qu YH, Zheng JJ, Guo YJ, Zhang CP, Zhang KP

- 6306 Early renal injury indicators can help evaluate renal injury in patients with chronic hepatitis B with long-term nucleos(t)ide therapy

Ji TT, Tan N, Lu HY, Xu XY, Yu YY

Prospective Study

- 6315** Neoadjuvant chemoradiotherapy plus surgery in the treatment of potentially resectable thoracic esophageal squamous cell carcinoma
Yan MH, Hou XB, Cai BN, Qu BL, Dai XK, Liu F

CASE REPORT

- 6322** Uterine rupture in patients with a history of multiple curettages: Two case reports
Deng MF, Zhang XD, Zhang QF, Liu J
- 6330** Pleural effusion and ascites in extrarenal lymphangiectasia caused by post-biopsy hematoma: A case report
Lin QZ, Wang HE, Wei D, Bao YF, Li H, Wang T
- 6337** Eighty-year-old man with rare chronic neutrophilic leukemia caused by CSF3R T618I mutation: A case report and review of literature
Li YP, Chen N, Ye XM, Xia YS
- 6346** Sigmoid colon duplication with ectopic immature renal tissue in an adult: A case report
Namgung H
- 6353** Paraplegia from spinal intramedullary tuberculosis: A case report
Qu LM, Wu D, Guo L, Yu JL
- 6358** Confocal laser endomicroscopy distinguishing benign and malignant gallbladder polyps during choledochoscopic gallbladder-preserving polypectomy: A case report
Tang BF, Dang T, Wang QH, Chang ZH, Han WJ
- 6364** Sclerosing stromal tumor of the ovary with masculinization, Meig's syndrome and CA125 elevation in an adolescent girl: A case report
Chen Q, Chen YH, Tang HY, Shen YM, Tan X
- 6373** Primary pulmonary malignant melanoma diagnosed with percutaneous biopsy tissue: A case report
Xi JM, Wen H, Yan XB, Huang J
- 6380** SRY-negative 45,X/46,XY adult male with complete masculinization and infertility: A case report and review of literature
Wu YH, Sun KN, Bao H, Chen YJ
- 6389** Refractory case of ulcerative colitis with idiopathic thrombocytopenic purpura successfully treated by Janus kinase inhibitor tofacitinib: A case report
Komeda Y, Sakurai T, Sakai K, Morita Y, Hashimoto A, Nagai T, Hagiwara S, Matsumura I, Nishio K, Kudo M
- 6396** Immunotherapies application in active stage of systemic lupus erythematosus in pregnancy: A case report and review of literature
Xiong ZH, Cao XS, Guan HL, Zheng HL

- 6408** Minimally invasive maxillary sinus augmentation with simultaneous implantation on an elderly patient: A case report
Yang S, Yu W, Zhang J, Zhou Z, Meng F, Wang J, Shi R, Zhou YM, Zhao J
- 6418** Congenital nephrogenic diabetes insipidus due to the mutation in *AVPR2* (c.541C>T) in a neonate: A case report
Lin FT, Li J, Xu BL, Yang XX, Wang F
- 6425** Primary gastric melanoma in a young woman: A case report
Long GJ, Ou WT, Lin L, Zhou CJ
- 6432** Extreme venous letting and cupping resulting in life-threatening anemia and acute myocardial infarction: A case report
Jang AY, Suh SY
- 6437** Novel conservative treatment for peritoneal dialysis-related hydrothorax: Two case reports
Dai BB, Lin BD, Yang LY, Wan JX, Pan YB
- 6444** Clinical characteristics of pulmonary cryptococcosis coexisting with lung adenocarcinoma: Three case reports
Zheng GX, Tang HJ, Huang ZP, Pan HL, Wei HY, Bai J
- 6450** Fracture of the scapular neck combined with rotator cuff tear: A case report
Chen L, Liu CL, Wu P
- 6456** Synchronous colonic mucosa-associated lymphoid tissue lymphoma found after surgery for adenocarcinoma: A case report and review of literature
Li JJ, Chen BC, Dong J, Chen Y, Chen YW
- 6465** Novel mutation in the *ASXL3* gene in a Chinese boy with microcephaly and speech impairment: A case report
Li JR, Huang Z, Lu Y, Ji QY, Jiang MY, Yang F
- 6473** Recurrent thrombosis in the lower extremities after thrombectomy in a patient with polycythemia vera: A case report
Jiang BP, Cheng GB, Hu Q, Wu JW, Li XY, Liao S, Wu SY, Lu W
- 6480** Status epilepticus as an initial manifestation of hepatic encephalopathy: A case report
Cui B, Wei L, Sun LY, Qu W, Zeng ZG, Liu Y, Zhu ZJ
- 6487** Delayed diagnosis of prosopagnosia following a hemorrhagic stroke in an elderly man: A case report
Yuan Y, Huang F, Gao ZH, Cai WC, Xiao JX, Yang YE, Zhu PL
- 6499** Oral myiasis after cerebral infarction in an elderly male patient from southern China: A case report
Zhang TZ, Jiang Y, Luo XT, Ling R, Wang JW
- 6504** Rare case of drain-site hernia after laparoscopic surgery and a novel strategy of prevention: A case report
Gao X, Chen Q, Wang C, Yu YY, Yang L, Zhou ZG

- 6511** Extracorporeal shock wave therapy treatment of painful hematoma in the calf: A case report
Jung JW, Kim HS, Yang JH, Lee KH, Park SB
- 6517** Takotsubo cardiomyopathy associated with bronchoscopic operation: A case report
Wu BF, Shi JR, Zheng LR
- 6524** Idiopathic adulthood ductopenia with elevated transaminase only: A case report
Zhang XC, Wang D, Li X, Hu YL, Wang C
- 6529** Successful endovascular treatment with long-term antibiotic therapy for infectious pseudoaneurysm due to *Klebsiella pneumoniae*: A case report
Wang TH, Zhao JC, Huang B, Wang JR, Yuan D
- 6537** Primary duodenal tuberculosis misdiagnosed as tumor by imaging examination: A case report
Zhang Y, Shi XJ, Zhang XC, Zhao XJ, Li JX, Wang LH, Xie CE, Liu YY, Wang YL

ABOUT COVER

Peer-Reviewer of *World Journal of Clinical Cases*, Dr. Adonis Protopapas is a gastroenterology Resident at the first Propaedeutic Department of Internal Medicine of the Aristotle University of Thessaloniki (Greece), located at the A.H.E.P.A Hospital. He earned his Bachelor's degree in 2015 from the Democritus University of Thrace, followed by three Master's of Science degrees, with specializations in clinic pharmacology, medical research methodology, and healthcare management. His research interests are mainly focused on the area of hepatology, although he also participates in various projects related to endoscopy and inflammatory bowel disease. He is particularly fascinated by research on cirrhosis and its complications. (L-Editor: Filipodia)

AIMS AND SCOPE

The primary aim of *World Journal of Clinical Cases* (*WJCC*, *World J Clin Cases*) is to provide scholars and readers from various fields of clinical medicine with a platform to publish high-quality clinical research articles and communicate their research findings online.

WJCC mainly publishes articles reporting research results and findings obtained in the field of clinical medicine and covering a wide range of topics, including case control studies, retrospective cohort studies, retrospective studies, clinical trials studies, observational studies, prospective studies, randomized controlled trials, randomized clinical trials, systematic reviews, meta-analysis, and case reports.

INDEXING/ABSTRACTING

The *WJCC* is now indexed in Science Citation Index Expanded (also known as SciSearch®), Journal Citation Reports/Science Edition, PubMed, and PubMed Central. The 2020 Edition of Journal Citation Reports® cites the 2019 impact factor (IF) for *WJCC* as 1.013; IF without journal self cites: 0.991; Ranking: 120 among 165 journals in medicine, general and internal; and Quartile category: Q3.

RESPONSIBLE EDITORS FOR THIS ISSUE

Production Editor: Ji-Hong Liu; Production Department Director: Xiang Li; Editorial Office Director: Jin-Lai Wang.

NAME OF JOURNAL

World Journal of Clinical Cases

ISSN

ISSN 2307-8960 (online)

LAUNCH DATE

April 16, 2013

FREQUENCY

Semimonthly

EDITORS-IN-CHIEF

Dennis A Bloomfield, Sandro Vento, Bao-gan Peng

EDITORIAL BOARD MEMBERS

<https://www.wjgnet.com/2307-8960/editorialboard.htm>

PUBLICATION DATE

December 26, 2020

COPYRIGHT

© 2020 Baishideng Publishing Group Inc

INSTRUCTIONS TO AUTHORS

<https://www.wjgnet.com/bpg/gerinfo/204>

GUIDELINES FOR ETHICS DOCUMENTS

<https://www.wjgnet.com/bpg/GerInfo/287>

GUIDELINES FOR NON-NATIVE SPEAKERS OF ENGLISH

<https://www.wjgnet.com/bpg/gerinfo/240>

PUBLICATION ETHICS

<https://www.wjgnet.com/bpg/GerInfo/288>

PUBLICATION MISCONDUCT

<https://www.wjgnet.com/bpg/gerinfo/208>

ARTICLE PROCESSING CHARGE

<https://www.wjgnet.com/bpg/gerinfo/242>

STEPS FOR SUBMITTING MANUSCRIPTS

<https://www.wjgnet.com/bpg/GerInfo/239>

ONLINE SUBMISSION

<https://www.f6publishing.com>



Successful endovascular treatment with long-term antibiotic therapy for infectious pseudoaneurysm due to *Klebsiella pneumoniae*: A case report

Tie-Hao Wang, Ji-Chun Zhao, Bin Huang, Jia-Rong Wang, Ding Yuan

ORCID number: Tie-Hao Wang 0000-0002-8901-9765; Ji-Chun Zhao 0000-0002-1799-9514; Bin Huang 0000-0002-0128-520X; Jia-Rong Wang 0000-0002-9393-259X; Ding Yuan 0000-0002-9538-6959.

Author contributions: Wang TH, Zhao JC and Huang B performed the surgery and wrote the paper; Wang JR and Yuan D collected the information and followed the patient; Wang TH and Yuan D revised the paper; All authors read and approved the final manuscript.

Supported by Sichuan Foundation of Science and Technology, No. 2019YJ0066.

Informed consent statement: Informed written consent was obtained from the patient for publication of this report and any accompanying images.

Conflict-of-interest statement: The authors declare that they have no conflict of interest.

CARE Checklist (2016) statement: The authors have read the CARE Checklist (2016), and the manuscript was prepared and revised according to the CARE Checklist (2016).

Open-Access: This article is an

Tie-Hao Wang, Ji-Chun Zhao, Bin Huang, Jia-Rong Wang, Ding Yuan, Department of Vascular Surgery, West China Hospital, Sichuan University, Chengdu 610000, Sichuan Province, China

Corresponding author: Ding Yuan, MD, Assistant Professor, Department of Vascular Surgery, West China Hospital, Sichuan University, No. 37 Guoxue Xiang, Chengdu 610000, Sichuan Province, China. yuandingdoc09@163.com

Abstract

BACKGROUND

Infectious common femoral artery pseudoaneurysm caused by *Klebsiella pneumoniae* pulmonary infection is a relatively infrequent entity but is potentially life and limb threatening. The management of infectious pseudoaneurysm remains controversial.

CASE SUMMARY

We reported a 79-year-old man with previous *Klebsiella pneumoniae* pulmonary infection and multiple comorbidities who presented with a progressive pulsate mass at the right groin and with right lower limb pain. Computed tomography angiography showed a 6 cm × 6 cm × 9 cm pseudoaneurysm of the right common femoral artery accompanied by occlusion of the right superficial femoral artery and deep femoral artery. He underwent endovascular treatment (EVT) with stent-graft, and etiology of infectious pseudoaneurysm was confirmed. Then, 3-mo antibiotic therapy was given. One-year follow-up showed the stent-graft was patent and complete removal of surrounding hematoma.

CONCLUSION

The femoral artery pseudoaneurysm can be caused by *Klebsiella pneumoniae* deriving from the pulmonary infection. Moreover, this unusual case highlights the use of EVT and prolonged antibiotic therapy for infectious pseudoaneurysm.

Key Words: Infectious pseudoaneurysm; Common femoral artery; *Klebsiella pneumoniae*; Antibiotic therapy; Endovascular treatment; Case report

©The Author(s) 2020. Published by Baishideng Publishing Group Inc. All rights reserved.

open-access article that was selected by an in-house editor and fully peer-reviewed by external reviewers. It is distributed in accordance with the Creative Commons Attribution NonCommercial (CC BY-NC 4.0) license, which permits others to distribute, remix, adapt, build upon this work non-commercially, and license their derivative works on different terms, provided the original work is properly cited and the use is non-commercial. See: <http://creativecommons.org/licenses/by-nc/4.0/>

Manuscript source: Unsolicited manuscript

Specialty type: Peripheral vascular disease

Country/Territory of origin: China

Peer-review report's scientific quality classification

Grade A (Excellent): 0
Grade B (Very good): 2
Grade C (Good): 0
Grade D (Fair): 0
Grade E (Poor): 0

Received: September 27, 2020

Peer-review started: September 25, 2020

First decision: October 18, 2020

Revised: October 22, 2020

Accepted: November 2, 2020

Article in press: November 2, 2020

Published online: December 26, 2020

P-Reviewer: Tanabe H

S-Editor: Liu M

L-Editor: Filipodia

P-Editor: Li JH



Core Tip: Infectious pseudoaneurysm of the femoral artery is a rare entity that is potentially life and limb threatening. Common femoral artery (CFA) pseudoaneurysm caused by *Klebsiella pneumoniae* has not been reported. We reported a rare infectious CFA pseudoaneurysm, which was caused by previous pulmonary infection of *Klebsiella pneumoniae*. After endovascular treatment (EVT) and long-term antibiotic therapy, the patient had a good result at the 1-year follow-up. This case demonstrates common femoral artery pseudoaneurysm can be caused by *Klebsiella pneumoniae* deriving from the pulmonary infection. Moreover, it highlights the use of EVT and prolonged antibiotic therapy for infectious pseudoaneurysm.

Citation: Wang TH, Zhao JC, Huang B, Wang JR, Yuan D. Successful endovascular treatment with long-term antibiotic therapy for infectious pseudoaneurysm due to *Klebsiella pneumoniae*: A case report. *World J Clin Cases* 2020; 8(24): 6529-6536

URL: <https://www.wjgnet.com/2307-8960/full/v8/i24/6529.htm>

DOI: <https://dx.doi.org/10.12998/wjcc.v8.i24.6529>

INTRODUCTION

Infectious pseudoaneurysm of the femoral artery, accounting for merely 0.8% of all mycotic aneurysms, is rare and potentially life threatening^[1,2]. It may be caused either by direct invasion or less commonly by the hematogenous spread of infectious organisms to the vessel wall^[3]. *Staphylococcus aureus* and *Streptococcus* species are the most common causative pathogens^[4]. Excision, debridement, and surgical reconstruction of the blood vessels are considered the standard strategy in these cases^[5]. However, the clinical conditions of these patients are often critical due to both acute illness and severe infective comorbidities. The management of infectious femoral artery pseudoaneurysm remains a challenge^[1-3,6]. Here, we reported a rare case of common femoral artery (CFA) pseudoaneurysm due to *Klebsiella pneumoniae* (*K. pneumoniae*) pulmonary infection, presenting with acute limb ischemia. The patient was successfully treated with endovascular treatment (EVT) and long-term antibiotic therapy.

CASE PRESENTATION

Chief complaints

A 79-year-old man presented to our emergency department with a sudden progressive mass that occurred at the right groin and with progressive right lower limb pain.

History of present illness

The patient, initially presenting with fever, chills, and dyspnea, was admitted to a local hospital about 1 mo ago. A chest computed tomography showed pulmonary infection (Figure 1A), and *K. pneumoniae* was isolated from the blood and sputum culture, which was most sensitive to ceftriaxone. No pulsate mass was noted in either groin region, and all his lower limb pulses were present. After intravenous ceftriaxone (2 g every 12 h) was administered for 7 d, his symptoms rapidly alleviated, and he was discharged. Two weeks after discharging from the local hospital, without any history of trauma, a progressive mass suddenly occurred at his right groin accompanied by right lower limb pain. Ultrasound in a local hospital showed femoral artery pseudoaneurysm, and he was transferred to our institution immediately.

History of past illness

This patient had a history of alcoholism, was a heavy smoker, and had poorly controlled diabetes mellitus (DM) and hypertension.

Personal and family history

Unremarkable.

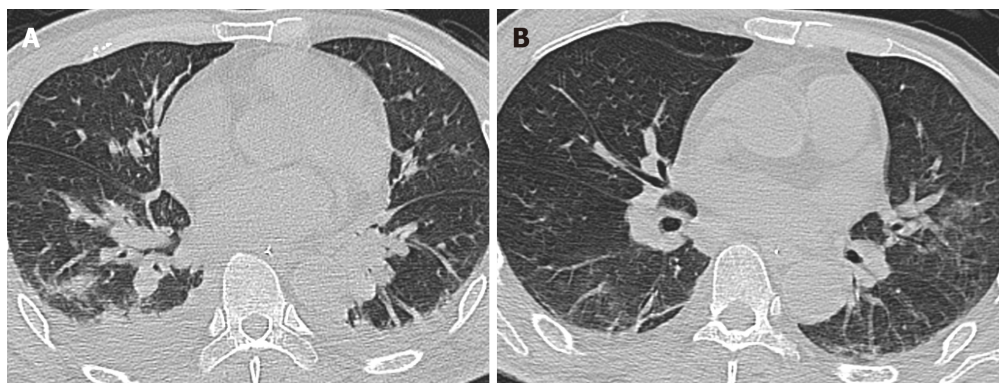


Figure 1 Findings of chest computed tomography. A: Three weeks before the patient was transferred to our hospital, chest computed tomography showed pulmonary consolidation and pleural effusion; B: Upon admission to our hospital, chest computed tomography showed that pulmonary infection had alleviated, but some inflammatory infiltrations were present.

Physical examination

Upon admission, he had a temperature of 39.0 °C, heart rate of 117/min, blood pressure of 165/95 mmHg, and respiratory rate of 27/min. Physical examination showed a pulsate mass at his right groin accompanied by cyanosis of the right lower limb. All pulses of the right lower limb disappeared, and tenderness of the right calf was detected.

Laboratory examinations

The laboratory test yielded a blood leukocyte count of $18.7 \times 10^9/L$, C-reactive protein of 186 mg/L, procalcitonin of 0.62 ng/mL, myoglobin of 2300 ng/mL, blood glucose of 16.5 mmol/L, glycated hemoglobin of 9.2%, blood PO_2 of 55 mmHg, and blood PCO_2 of 50 mmHg. Repeat blood and sputum cultures were noncontributory. During EVT, partial hematoma within the pseudoaneurysm was extracted through a catheter for microbial culture, and *K. pneumoniae* was isolated, which was most sensitive to ceftazidime and levofloxacin (Table 1).

Imaging examinations

The chest computed tomography showed that the pulmonary infection had significantly improved; however, inflammatory infiltration of both lungs was still present (Figure 1B). Computed tomography angiography (CTA) showed a 6 cm × 6 cm × 9 cm pseudoaneurysm of the right CFA accompanied by occlusion of the right superficial femoral artery (SFA) and deep femoral artery (DFA) (Figure 2). The echocardiogram was unremarkable.

FINAL DIAGNOSIS

The final diagnosis of the presented case is spontaneous CFA pseudoaneurysm due to *K. pneumoniae* accompanied by multiple comorbidities.

TREATMENT

Considering the multiple cardiorespiratory comorbidities of this patient, an open surgical repair (OSR) was not suitable. Because the CFA pseudoaneurysm was accompanied by severe lower limb ischemia, an emergency EVT with local anesthesia was performed. Left femoral access was achieved using a pre-close technique (ProGlide; Abbott Vascular, United States). Intraoperative angiography showed pseudoaneurysm of the CFA and occlusion of the SFA and DFA (Figure 3A). A little hematoma within the pseudoaneurysm was extracted through a catheter for microbial culture. Unfortunately, the compression caused by the pseudoaneurysm prevented the guidewires from passing through the occlusion lesion. Thus, retrograde access was achieved at the distal part of the SFA, and a V-18 control guidewire (Boston Scientific) was passed through the occlusion lesion into the proximal CFA. Then, this guidewire was manipulated into the antegrade catheter (Figure 3B and 3C). After the pathway

Table 1 Antimicrobial susceptibility test result of hematoma within the pseudoaneurysm

Antibiotics	Result	Sensitivity	Method	Breakpoint	
				S	R
Ampicillin	≥ 32	R	MIC	≤ 8	≥ 32
Ampicillin/sulbactam	≥ 32	R	MIC	≤ 8	≥ 32
Ticarcillin	≥ 128	R	MIC	≤ 16	≥ 128
Ticarcillin/clavulanic acid	≥ 128	R	MIC	≤ 16	≥ 128
Piperacillin	≥ 128	R	MIC	≤ 16	≥ 128
Piperacillin/tazobactam	≥ 128	R	MIC	≤ 16	≥ 128
Cefuroxime	≥ 64	R	MIC	≤ 8	≥ 32
Cefazolin	≥ 64	R	MIC	≤ 2	≥ 8
Cefalotin	≥ 64	R	MIC	≤ 8	≥ 32
Ceftazidime	1	S	MIC	≤ 4	≥ 16
Ceftazidime/avibatan	21	S	K-B	≥ 21	≤ 20
Cefotaxime	≥ 64	R	MIC	≤ 1	≥ 4
Ceftriaxone	≥ 64	R	MIC	≤ 1	≥ 4
Cefepime	≥ 64	R	MIC	≤ 2	≥ 16
Cefpodoxime	≥ 8	R	MIC	≤ 2	≥ 8
Aztreonam	≥ 64	R	MIC	≤ 4	≥ 16
Meropenem	≥ 16	R	MIC	≤ 1	≥ 4
Imipenem	≥ 16	R	MIC	≤ 1	≥ 4
Gentamicin	≥ 16	R	MIC	≤ 4	≥ 16
Amikacin	≥ 64	R	MIC	≤ 16	≥ 64
Ciprofloxacin	≥ 2	R	MIC	≤ 0.25	≥ 1
Levofloxacin	0.25	S	MIC	≤ 0.5	≥ 2
Moxifloxacin	1	S	MIC	≤ 1	≥ 4
Cotrimoxazole	≥ 16	R	MIC	≤ 2	≥ 4
Polymyxin B	1	S	MIC	≤ 1	≥ 4
Tetracycline	4	S	MIC	≤ 4	≥ 16
Tigecycline	2	S	MIC	≤ 2	≥ 8

K-B: Kirby-Bauer technique; MIC: Minimal inhibitory concentration; R: Resistant; S: Sensitive.

was established, two Viabahn (Gore, Flagstaff, United States) stent-grafts (8 mm × 100 mm and 8 mm × 50 mm) were deployed. Final angiography showed that the stent-grafts and distal SFA were patent without any endoleaks (Figure 3D).

When the patient was transferred to our hospital, empirical antibiotic therapy with intravenous ceftriaxone (2 g every 12 h) was given for suspicious infectious pseudoaneurysm. Then, the antibiotic was switched to intravenous ceftazidime (2 g every 8 h) according to the microbial culture of the hematoma in the pseudoaneurysm. After 14 d of antibiotic therapy with intravenous ceftazidime, this patient was discharged, and antibiotics were switched to oral levofloxacin (0.5 g/d) for 3 mo.

OUTCOME AND FOLLOW-UP

The postoperative course was uneventful. Bilateral dorsalis pedis could be palpated. Repeat blood cultures were negative, and no complications occurred. One month after hospital discharge, the inguinal mass disappeared. CTA at the 1-year follow-up

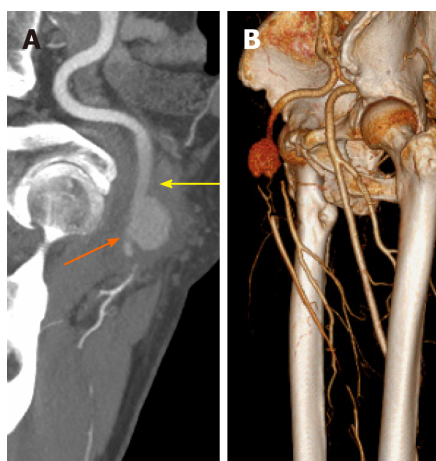


Figure 2 Preoperative computed tomography angiography. A: A pseudoaneurysm of the common femoral artery compressed its distal outflow tract (orange arrow); B: Occlusion of the superficial femoral artery and deep femoral artery.

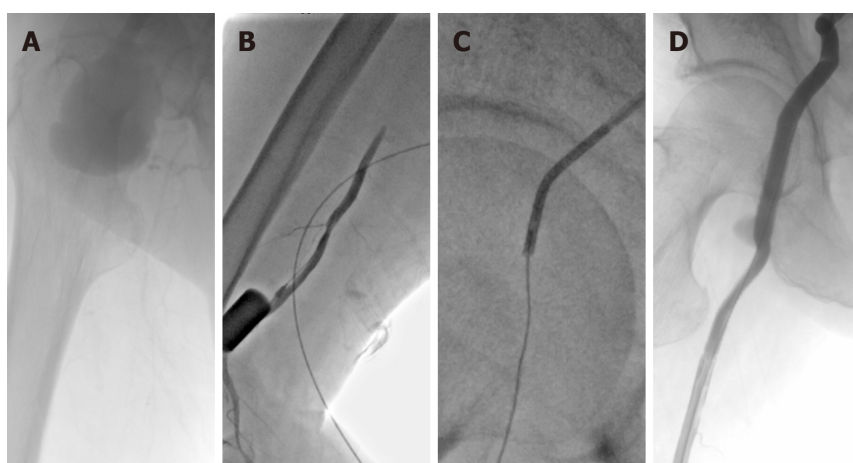


Figure 3 Intraoperative digital subtraction angiography. A: Guidewires cannot pass through the occlusion lesion; B: Retrograde access was achieved at the superficial femoral artery; C: Pathway was established via the "SAFARI" technique; D: After stent-grafts were deployed, the stent-grafts and distal outflow tract were patent without any endoleaks.

showed that the previous hematoma was absorbed; the stent-graft and outflow tract were patent without any endoleaks (Figure 4). The timeline of the patient's treatment is outlined in Figure 5.

DISCUSSION

Infectious pseudoaneurysms are characterized by the destruction of the artery wall *via* an infectious process and are associated with significant morbidity and mortality^[1,2]. The etiology of infectious pseudoaneurysm has been changing with septic emboli of endocarditis being the most common cause of arterial trauma in the post-antibiotic period. The less common cause is circulating organisms directly infecting the arterial walls as in cases of bacteremia. The risk factors for infectious pseudoaneurysm include underlying arterial pathologies, such as atherosclerotic disease and endothelial cell dysfunction^[3,7,8]. These factors can disrupt the integrity of the vessel wall; moreover, they will hasten the destruction of the intima and media layers by infectious organisms^[4]. Potential predisposing conditions include malignancy, DM, an immune-compromised state, and severe comorbidities^[3]. Although infectious pseudoaneurysm caused by bacteremia is a rare entity, a few authors had reported aortic pseudoaneurysm caused by pulmonary infection^[9]. The infected sites varied considerably. Because of hemodynamics, the arterial bifurcation may be invaded by circulating organisms^[8]. Therefore, CFA can be affected by circulating organisms during bacteremia in certain cases.

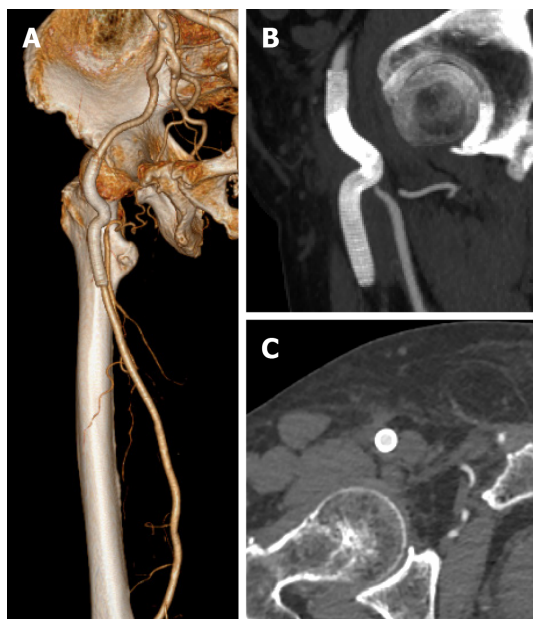


Figure 4 Computed tomography angiography at the 1-year follow-up. A: Stent-grafts were patent without any endoleaks; B and C: The previous surrounding hematoma was completely absorbed.

Numerous organisms, including *Staphylococcus aureus* (30% of all cases), other *Streptococcus* species (14%), and *Salmonella* (10%), may cause infectious pseudoaneurysms^[8]. *K. pneumoniae* is a normal flora of the human mouth and intestine. The various clinical manifestations of *K. pneumoniae* include pneumonia, intra-abdominal infection, bacteremia, and soft tissue infection^[9,10]. However, pseudoaneurysm caused by *K. pneumoniae* is rare. DM is the most common risk factor in *K. pneumoniae* pseudoaneurysm, which exists in most reported cases^[3]. Some authors reported *K. pneumoniae*-associated thoracic or abdominal aortic pseudoaneurysm but not *K. pneumoniae*-associated femoral artery pseudoaneurysm^[9,11]. In our case, the patient had a history of bacteremia caused by *K. pneumoniae* pneumonia accompanied by DM, atherosclerosis, and multiple severe comorbidities. Moreover, *K. pneumoniae* was isolated from the hematoma within the pseudoaneurysm. All evidence demonstrated that this CFA pseudoaneurysm was caused by *K. pneumoniae* derived from the pulmonary infection.

Treatment of infectious pseudoaneurysm is a perpetual challenge^[2]. OSR requires radical debridement with excision of all the infected arterial segments and surrounding tissues, followed by ligation of the affected artery or revascularization with synthetic or autologous graft^[12]. Given the possibility of severe limb ischemia with ligation alone, revascularization is universally accepted as the foundation of treatment^[5]. However, in situ reconstruction with synthetic or autologous graft leaves the patient susceptible to infection of the new graft, while the extra-anatomic reconstruction requires complex operations to restore the natural direction of blood flow^[2]. Moreover, hemorrhage-associated complications caused by OSR and the invasive approach may increase the likelihood of mortality. Compared with OSR, exclusion with covered stent-graft is a minimally invasive procedure^[1,6]. Obviously, a case for EVT for a high-risk surgical candidate with a CFA pseudoaneurysm could be made^[8]. Our patient had multiple severe comorbidities and was in a poor general condition. Therefore, EVT was a reasonable choice for this patient.

Endovascular exclusion of the infectious CFA pseudoaneurysm has been described, especially in patients not fit for a risky OSR or as a bridge therapy until definitive surgery^[4,5,12]. However, placement of a stent-graft into an infected environment is not appropriate. EVT of infectious pseudoaneurysm has shown complications of 20.0% and early mortality of 5.5%, which are higher than the incidence of complications and early mortality associated with OSR^[2]. The management of the DFA is also a challenge for CFA pseudoaneurysm in bifurcated lesions as it may cause persistent bleeding for retrograde perfusion from the DFA. Some authors described coil embolization of the DFA, and although technically feasible, it increases the possibility of subsequent abscess formation^[2]. Fortunately, the original part of the DFA of this patient had already occluded, which did not require additional dispose for the DFA. Moreover, the compression of the pseudoaneurysm may cause distal outflow tract distortion and

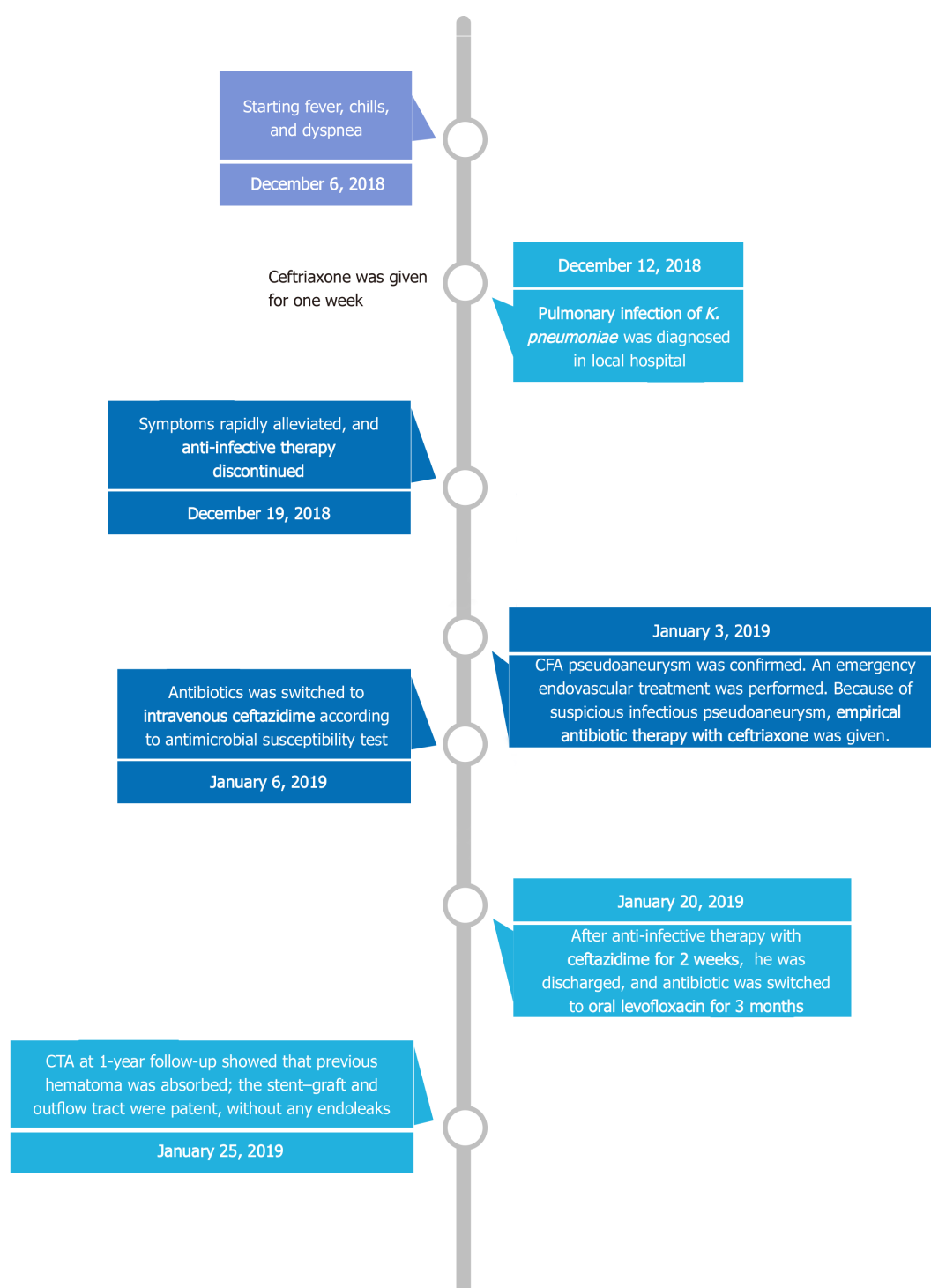


Figure 5 Timeline of the treatment. CFA: Common femoral artery; CTA: Computed tomography angiography.

occlusion, which make EVT challenging. The retrograde access can assist in establishing the pathway of EVT. This technique has been widely used in peripheral artery diseases and can also be a reasonable choice for EVT in CFA pseudoaneurysm with distal artery occlusion^[12,13].

Empirical antibiotics should be initiated immediately after the diagnosis of infectious pseudoaneurysm. Subsequently, the antibiotics should be changed according to the results of susceptibility testing^[3,6]. Microbiological diagnosis is crucial as a guide in the management of the condition. The specimen of a pseudoaneurysm is difficult to obtain during EVT, which may make the etiology diagnosis difficult^[4]. In our case, we extracted the blood from the pseudoaneurysm for microbial culture. This method is feasible for determining the specific organism involved in infectious pseudoaneurysm.

The period of antibiotic therapy is controversial^[9]. A 2-wk treatment course for primary *K. pneumoniae* bacteremia would be optimal. The antibiotic course of our patient was inadequate in his first pulmonary infection, which resulted in infectious CFA pseudoaneurysm. During the second episode of *K. pneumoniae* infection, a longer antibiotic course was recommended. Moreover, the persistence of an organism after EVT of infectious pseudoaneurysm requires prolonged antibiotic therapy as a stent-graft is used. Some reports indicated that at least 2 wk of intravenous antimicrobial therapy was needed, followed by administration of oral antibiotics for 6 wk or longer for patients undergoing EVT for infectious pseudoaneurysm^[3,5,6]. Our patient had a good long-term result with subsequent prolonged and continued antibiotic therapy after EVT.

CONCLUSION

Infectious CFA pseudoaneurysm caused by *K. pneumoniae* pulmonary infection is a rare clinical entity and is usually associated with multiple comorbidities. Our case demonstrates an endovascular solution to this challenging and lethal disease process as a suitable alternative to traditional OSR. Prompt pathogen diagnosis and continued antibiotic therapy are also crucial in patients with infectious pseudoaneurysm undergoing EVT.

REFERENCES

- 1 Xu J, Zheng Z, Yang Y, Zhang W, Zhao H, E B, Zheng M. Clinical evaluation of covered stents in the treatment of superficial femoral artery pseudoaneurysm in drug abusers. *Mol Med Rep* 2018; **17**: 4460-4466 [PMID: 29344667 DOI: 10.3892/mmr.2018.8431]
- 2 Inaraja-Pérez GC, Adoración RC, Jose-Antonio LS, Maria-Isabel LG, Irene SV. A Bail Out Solution for an Urgent Situation: Endovascular Exclusion and Embolization of an Infected Femoral Pseudoaneurysm. *Ann Vasc Surg* 2020; **69**: 454.e1-454.e5 [PMID: 32768535 DOI: 10.1016/j.avsg.2020.07.018]
- 3 Hussain M, Roche-Nagle G. Infected pseudoaneurysm of the superficial femoral artery in a patient with Salmonella enteritidis bacteremia. *Can J Infect Dis Med Microbiol* 2013; **24**: e24-e25 [PMID: 24421797 DOI: 10.1155/2013/715609]
- 4 Gooneratne TD, Sriskantha S, Wijeyaratne M. A case of a mycotic aneurysm of the superficial femoral artery infected by mixed bacterial species. *Ann Vasc Dis* 2011; **4**: 325-327 [PMID: 23555472 DOI: 10.3400/avd.cr.11.00018]
- 5 Li K, Beckerman WE, Luo X, Peng HW, Chen KQ, He CG. Graft Infection after Prosthetic Bypass Surgery for Infectious Femoral Artery Pseudoaneurysm in Intravenous Drug Users: Manifestation, Management, and Prognosis. *Ann Vasc Surg* 2020 epub ahead of print [PMID: 32634568 DOI: 10.1016/j.avsg.2020.06.058]
- 6 Wooster MD, Shames ML. Mycotic pseudoaneurysm of a superficial femoral artery stent. *Vasc Endovascular Surg* 2013; **47**: 470-473 [PMID: 23709271 DOI: 10.1177/1538574413490838]
- 7 Kocovski L, Butany J, Nair V. Femoral artery pseudoaneurysm due to *Candida albicans* in an injection drug user. *Cardiovasc Pathol* 2014; **23**: 50-53 [PMID: 24012013 DOI: 10.1016/j.carpath.2013.07.003]
- 8 Bowden DJ, Hayes PD, Sadat U, Choon See T. Mycotic pseudoaneurysm of the superficial femoral artery in a patient with Cushing disease: case report and literature review. *Vascular* 2009; **17**: 163-167 [PMID: 19476750 DOI: 10.2310/6670.2008.00060]
- 9 Chuang YC, Lee MF, Yu WL. Mycotic aneurysm caused by hypermucoviscous *Klebsiella pneumoniae* serotype K54 with sequence type 29: an emerging threat. *Infection* 2013; **41**: 1041-1044 [PMID: 23508461 DOI: 10.1007/s15010-013-0447-6]
- 10 Chao CM, Lee KK, Wang CS, Chen PJ, Yeh TC. A Fatal Case of *Klebsiella pneumoniae* Mycotic Aneurysm. *Case Rep Emerg Med* 2011; **2011**: 498545 [PMID: 23326694 DOI: 10.1155/2011/498545]
- 11 Chen X, Yuan D, Zhao J, Huang B, Yang Y. Hybrid repair for a complex infection aortic pseudoaneurysm with continued antibiotic therapy: A case report and literature review. *Medicine (Baltimore)* 2019; **98**: e14330 [PMID: 30732155 DOI: 10.1097/MD.00000000000014330]
- 12 Mehta T, Dey R, Chaudhuri A. Iliopofunda Endobypass Can Successfully Treat a Post-Operative Femoral Pseudo-Aneurysm. *EJVES Short Rep* 2017; **34**: 9-12 [PMID: 28856325 DOI: 10.1016/j.ejvssr.2016.11.001]
- 13 Zhuang KD, Tan SG, Tay KH. The "SAFARI" technique using retrograde access via peroneal artery access. *Cardiovasc Intervent Radiol* 2012; **35**: 927-931 [PMID: 22131120 DOI: 10.1007/s00270-011-0297-5]



Published by **Baishideng Publishing Group Inc**
7041 Koll Center Parkway, Suite 160, Pleasanton, CA 94566, USA

Telephone: +1-925-3991568

E-mail: bpgoffice@wjgnet.com

Help Desk: <https://www.f6publishing.com/helpdesk>

<https://www.wjgnet.com>

