

# World Journal of *Clinical Cases*

*World J Clin Cases* 2021 January 26; 9(3): 521-763



## Contents

Thrice Monthly Volume 9 Number 3 January 26, 2021

## MINIREVIEWS

- 521 Role of argon plasma coagulation in treatment of esophageal varices  
*Song Y, Feng Y, Sun LH, Zhang BJ, Yao HJ, Qiao JG, Zhang SF, Zhang P, Liu B*
- 528 Clinical features and potential mechanism of coronavirus disease 2019-associated liver injury  
*Han MW, Wang M, Xu MY, Qi WP, Wang P, Xi D*

## ORIGINAL ARTICLE

## Retrospective Study

- 540 Circulating immune parameters-based nomogram for predicting malignancy in laryngeal neoplasm  
*Chen M, Fang Y, Yang Y, He PJ, Cheng L, Wu HT*
- 552 Role of ammonia in predicting the outcome of patients with acute-on-chronic liver failure  
*Chiriac S, Stanciu C, Cojocariu C, Singeap AM, Sfarti C, Cuciureanu T, Girleanu I, Igna RA, Trifan A*
- 565 Impact of different stereoisomers of inositol on insulin sensitivity of gestational diabetes mellitus patients  
*He J, Zhang YL, Wang LP, Liu XC*

## Observational Study

- 573 Fascial space odontogenic infections: Ultrasonography as an alternative to magnetic resonance imaging  
*Ghali S, Katti G, Shahbaz S, Chitroda PK, V Anukriti, Divakar DD, Khan AA, Naik S, Al-Kheraif AA, Jhugroo C*

## SYSTEMATIC REVIEWS

- 581 Clinical benefit of COX-2 inhibitors in the adjuvant chemotherapy of advanced non-small cell lung cancer: A systematic review and meta-analysis  
*Xu YQ, Long X, Han M, Huang MQ, Lu JF, Sun XD, Han W*

## CASE REPORT

- 602 Delayed cardiac tamponade diagnosed by point-of-care ultrasound in a neonate after peripherally inserted central catheter placement: A case report  
*Cui Y, Liu K, Luan L, Liang P*
- 607 Facial microcystic adnexal carcinoma — treatment with a “jigsaw puzzle” advancement flap and immediate esthetic reconstruction: A case report  
*Xiao YD, Zhang MZ, Zeng A*
- 614 Nephrotic syndrome in syngeneic hematopoietic stem cell transplantation recipients: A case report  
*Bai MC, Wu JJ, Miao KR, Zhu JF, Mao HJ*

- 623** Compound heterozygous mutations in the neuraminidase 1 gene in type 1 sialidosis: A case report and review of literature  
*Cao LX, Liu Y, Song ZJ, Zhang BR, Long WY, Zhao GH*
- 632** Dynamic biomechanical effect of lower body positive pressure treadmill training for hemiplegic gait rehabilitation after stroke: A case report  
*Tang HF, Yang B, Lin Q, Liang JJ, Mou ZW*
- 639** Right-heart contrast echocardiography reveals missed patent ductus arteriosus in a postpartum woman with pulmonary embolism: A case report  
*Chen JL, Mei DE, Yu CG, Zhao ZY*
- 644** Treatment of cervical spine metastasis with minimally invasive cervical spondylectomy: A case report and literature review  
*He LM, Ma X, Chen C, Zhang HY*
- 651** Successful treatment of pyogenic ventriculitis caused by extensively drug-resistant *Acinetobacter baumannii* with multi-route tigecycline: A case report  
*Li W, Li DD, Yin B, Lin DD, Sheng HS, Zhang N*
- 659** Radical resection of hepatic polycystic echinococcosis complicated with hepatocellular carcinoma: A case report  
*Kalifu B, Meng Y, Maimaitinijati Y, Ma ZG, Tian GL, Wang JG, Chen X*
- 666** Pleural lump after paragonimiasis treated by thoracoscopy: A case report  
*Xie Y, Luo YR, Chen M, Xie YM, Sun CY, Chen Q*
- 672** Deep vein thrombosis in patient with left-sided inferior vena cava draining into the hemiazygos vein: A case report  
*Zhang L, Guan WK*
- 677** Recurrent Takotsubo cardiomyopathy triggered by emotionally stressful events: A case report  
*Wu HY, Cheng G, Liang L, Cao YW*
- 685** Oral and perioral herpes simplex virus infection type I in a five-month-old infant: A case report  
*Aloyouny AY, Albagieh HN, Al-Serwi RH*
- 690** Nasal septal foreign body as a complication of dental root canal therapy: A case report  
*Du XW, Zhang JB, Xiao SF*
- 697** Coinheritance of *OLFM2* and *SIX6* variants in a Chinese family with juvenile-onset primary open-angle glaucoma: A case report  
*Yang X, Sun NN, Zhao ZN, He SX, Zhang M, Zhang DD, Yu XW, Zhang JM, Fan ZG*
- 707** Systemic lupus erythematosus and antineutrophil cytoplasmic antibody-associated vasculitis overlap syndrome in a 77-year-old man: A case report  
*Xu ZG, Li WL, Wang X, Zhang SY, Zhang YW, Wei X, Li CD, Zeng P, Luan SD*

- 714** Clinical cure and liver fibrosis reversal after postoperative antiviral combination therapy in hepatitis B-associated non-cirrhotic hepatocellular carcinoma: A case report  
*Yu XP, Lin Q, Huang ZP, Chen WS, Zheng MH, Zheng YJ, Li JL, Su ZJ*
- 722** Severe skeletal bimaxillary protrusion treated with micro-implants and a self-made four-curvature torquing auxiliary: A case report  
*Liu R, Hou WB, Yang PZ, Zhu L, Zhou YQ, Yu X, Wen XJ*
- 736** Cystic duct dilation through endoscopic retrograde cholangiopancreatography for treatment of gallstones and choledocholithiasis: Six case reports and review of literature  
*He YG, Gao MF, Li J, Peng XH, Tang YC, Huang XB, Li YM*
- 748** Infectious complications during immunochemotherapy of post-transplantation lymphoproliferative disease—can we decrease the risk? Two case reports and review of literature  
*Gładys A, Kozak S, Wdowiak K, Winder M, Chudek J*
- 758** Restenosis of a drug eluting stent on the previous bioresorbable vascular scaffold successfully treated with a drug-coated balloon: A case report  
*Jang HG, Kim K, Park HW, Koh JS, Jeong YH, Park JR, Kang MG*



**ABOUT COVER**

Editorial Board Member of *World Journal of Clinical Cases*, Dr. Marcelo A F Ribeiro Jr. is Full Professor of Surgery at Pontifical Catholic University – PUC Sorocaba – General and Trauma Surgery, and Professor of the Post-Graduation Program in Surgery, IAMSPE São Paulo (Brazil). He serves as Member and Fellow of the Brazilian College of Surgeons, Brazilian College of Digestive Surgery, Brazilian Trauma Society (General Secretary), American College of Surgeons, American Association for the Surgery of Trauma, Eastern Association for the Surgery of Trauma, and Pan-American Trauma Society (being Chairman of the Education Committee and Member of the Board). (L-Editor: Filipodia)

**AIMS AND SCOPE**

The primary aim of *World Journal of Clinical Cases* (WJCC, *World J Clin Cases*) is to provide scholars and readers from various fields of clinical medicine with a platform to publish high-quality clinical research articles and communicate their research findings online.

WJCC mainly publishes articles reporting research results and findings obtained in the field of clinical medicine and covering a wide range of topics, including case control studies, retrospective cohort studies, retrospective studies, clinical trials studies, observational studies, prospective studies, randomized controlled trials, randomized clinical trials, systematic reviews, meta-analysis, and case reports.

**INDEXING/ABSTRACTING**

The WJCC is now indexed in Science Citation Index Expanded (also known as SciSearch®), Journal Citation Reports/Science Edition, Scopus, PubMed, and PubMed Central. The 2020 Edition of Journal Citation Reports® cites the 2019 impact factor (IF) for WJCC as 1.013; IF without journal self cites: 0.991; Ranking: 120 among 165 journals in medicine, general and internal; and Quartile category: Q3. The WJCC's CiteScore for 2019 is 0.3 and Scopus CiteScore rank 2019: General Medicine is 394/529.

**RESPONSIBLE EDITORS FOR THIS ISSUE**

Production Editor: Ji-Hong Liu; Production Department Director: Xiang Li; Editorial Office Director: Jin-Lai Wang.

**NAME OF JOURNAL**

*World Journal of Clinical Cases*

**ISSN**

ISSN 2307-8960 (online)

**LAUNCH DATE**

April 16, 2013

**FREQUENCY**

Thrice Monthly

**EDITORS-IN-CHIEF**

Dennis A Bloomfield, Sandro Vento, Bao-gan Peng

**EDITORIAL BOARD MEMBERS**

<https://www.wjgnet.com/2307-8960/editorialboard.htm>

**PUBLICATION DATE**

January 26, 2021

**COPYRIGHT**

© 2021 Baishideng Publishing Group Inc

**INSTRUCTIONS TO AUTHORS**

<https://www.wjgnet.com/bpg/gerinfo/204>

**GUIDELINES FOR ETHICS DOCUMENTS**

<https://www.wjgnet.com/bpg/GerInfo/287>

**GUIDELINES FOR NON-NATIVE SPEAKERS OF ENGLISH**

<https://www.wjgnet.com/bpg/gerinfo/240>

**PUBLICATION ETHICS**

<https://www.wjgnet.com/bpg/GerInfo/288>

**PUBLICATION MISCONDUCT**

<https://www.wjgnet.com/bpg/gerinfo/208>

**ARTICLE PROCESSING CHARGE**

<https://www.wjgnet.com/bpg/gerinfo/242>

**STEPS FOR SUBMITTING MANUSCRIPTS**

<https://www.wjgnet.com/bpg/GerInfo/239>

**ONLINE SUBMISSION**

<https://www.f6publishing.com>



## Clinical cure and liver fibrosis reversal after postoperative antiviral combination therapy in hepatitis B-associated non-cirrhotic hepatocellular carcinoma: A case report

Xue-Ping Yu, Qi Lin, Zhi-Peng Huang, Wei-Shan Chen, Ming-Hui Zheng, Yi-Juan Zheng, Ju-Lan Li, Zhi-Jun Su

**ORCID number:** Xue-Ping Yu 0000-0002-1157-2501; Qi Lin 0000-0002-2829-6224; Zhi-Peng Huang 0000-0002-1217-0192; Wei-Shan Chen 0000-0003-1762-3792; Ming-Hui Zheng 0000-0003-0577-370X; Yi-Juan Zheng 0000-0002-3659-2998; Ju-Lan Li 0000-0003-4222-2966; Zhi-Jun Su 0000-0003-2849-480X.

**Author contributions:** Yu XP, Lin Q, and Su ZJ performed the postoperative evaluation and diagnosis; Huang ZP and Chen WS pathologically diagnosed the tissue; Zheng MH, Zheng YJ, and Li JL collected the medical data; Yu XP and Su ZJ reviewed the literature and contributed to manuscript drafting; Yu XP and Huang ZP contributed equally to this article; and all authors issued final approval for the submitted version.

**Supported by** Natural Science Foundation of Fujian Province, No. 2019J01593; High-Level Talent Innovation Project of Quanzhou, No. 2018C067R; Science and Technology Innovation Joint Project of Fujian Province, No. 2019Y9048; Youth Research Project of Fujian Provincial Health Commission, No. 2018-1-94 and No. 2018-1-95; Science and Technology Project of Quanzhou, No. 2018Z074 and No. 2018Z069.

**Xue-Ping Yu, Qi Lin, Ming-Hui Zheng, Yi-Juan Zheng, Ju-Lan Li, Zhi-Jun Su,** Department of Infection Diseases, First Hospital of Quanzhou Affiliated to Fujian Medical University, Quanzhou 362000, Fujian Province, China

**Zhi-Peng Huang,** Department of Gastroenterology, First Hospital of Quanzhou Affiliated to Fujian Medical University, Quanzhou 362000, Fujian Province, China

**Wei-Shan Chen,** Department of Pathology, First Hospital of Quanzhou Affiliated to Fujian Medical University, Quanzhou 362000, Fujian Province, China

**Corresponding author:** Zhi-Jun Su, Chief Doctor, Department of Infection Disease, First Hospital of Quanzhou Affiliated to Fujian Medical University, No. 250 East Street, Licheng District, Quanzhou 362000, Fujian Province, China. [su2366@sina.com](mailto:su2366@sina.com)

### Abstract

#### BACKGROUND

The incidence of hepatocellular carcinoma (HCC) is high in China, and approximately 15%-20% of HCC cases occur in the absence of cirrhosis. Compared with patients with cirrhotic HCC, those with non-cirrhotic HCC have longer postoperative tumor-free survival. However, the overall survival time is not significantly increased, and the risk of postoperative recurrence remains. Strategies to improve the postoperative survival rate in these patients are currently required.

#### CASE SUMMARY

A 47-year-old man with a family history of HCC was found to have hepatitis B virus (HBV) infection 25 years ago. In 2000, he was administered lamivudine for 2 years, and entecavir (ETV 0.5 mg) was administered in 2006. In October 2016, magnetic resonance imaging revealed a tumor in the liver (5.3 cm × 5 cm × 5 cm); no intraoperative hepatic and portal vein and bile duct tumor thrombi were found; and postoperative pathological examination confirmed a grade II HCC with no nodular cirrhosis (G1S3). ETV was continued, and no significant changes were observed on imaging. After receiving pegylated interferon alfa-2b (PEG IFNα-2b) (180 μg) + ETV in February 2019, the HBsAg titer decreased significantly within 12 wk. After receiving hepatitis B vaccine (60 μg) in 12 wk, HBsAg serological conversion was realized at 48 wk. During the treatment, no obvious

**Informed consent statement:**

Informed written consent was obtained from the patient for publication of this report and any accompanying images.

**Conflict-of-interest statement:** The authors declare that they have no conflicts of interest related to this manuscript.

**CARE Checklist (2016) statement:**

The authors have read the CARE Checklist (2016), and the manuscript was prepared and revised according to the CARE Checklist (2016).

**Open-Access:** This article is an open-access article that was selected by an in-house editor and fully peer-reviewed by external reviewers. It is distributed in accordance with the Creative Commons Attribution NonCommercial (CC BY-NC 4.0) license, which permits others to distribute, remix, adapt, build upon this work non-commercially, and license their derivative works on different terms, provided the original work is properly cited and the use is non-commercial. See: <http://creativecommons.org/licenses/by-nc/4.0/>

**Manuscript source:** Unsolicited manuscript

**Specialty type:** Medicine, research and experimental

**Country/Territory of origin:** China

**Peer-review report's scientific quality classification**

Grade A (Excellent): 0  
Grade B (Very good): 0  
Grade C (Good): C, C  
Grade D (Fair): D  
Grade E (Poor): 0

**Received:** September 28, 2020

**Peer-review started:** September 28, 2020

**First decision:** November 3, 2020

**Revised:** November 20, 2020

**Accepted:** December 11, 2020

**Article in press:** November 11, 2020

**Published online:** January 26, 2021

**P-Reviewer:** Macias Rodriguez RU,

adverse reactions were observed, except for early alanine aminotransferase flares. The reexamination results of liver pathology were G2S1, and reversal of liver fibrosis was achieved.

**CONCLUSION**

The therapeutic regimen of ETV+ PEG IFN $\alpha$ -2b + hepatitis B vaccine for patients with HBV-associated non-cirrhotic HCC following hepatectomy can achieve an HBV clinical cure and prolong the recurrence-free survival.

**Key Words:** Hepatocellular carcinoma; Hepatitis B virus; Entecavir; Pegylated interferon alfa-2b; Clinical cure; Case report

©The Author(s) 2021. Published by Baishideng Publishing Group Inc. All rights reserved.

**Core Tip:** Patients with hepatitis B virus infection can progress to liver failure, cirrhosis, and hepatocellular carcinoma (HCC); however, not all HCCs originate from cirrhosis, and approximately 15%-20% of HCC cases still occur without cirrhosis. Most importantly, the treatment of non-cirrhotic HCC after surgery and whether the risk of recurrence can be reduced by combining immunomodulators are the urgent problems that need to be solved at present. Therefore, we report a case in which HCC still occurred after 16 years of antiviral therapy, and the combination of immunoregulator therapy after HCC resection achieved a clinical cure and liver fibrosis reversal.

**Citation:** Yu XP, Lin Q, Huang ZP, Chen WS, Zheng MH, Zheng YJ, Li JL, Su ZJ. Clinical cure and liver fibrosis reversal after postoperative antiviral combination therapy in hepatitis B-associated non-cirrhotic hepatocellular carcinoma: A case report. *World J Clin Cases* 2021; 9(3): 714-721

**URL:** <https://www.wjgnet.com/2307-8960/full/v9/i3/714.htm>

**DOI:** <https://dx.doi.org/10.12998/wjcc.v9.i3.714>

**INTRODUCTION**

Hepatocellular carcinoma (HCC) is the fifth most common tumor and the second leading cause of cancer mortality in China<sup>[1]</sup>, with 92.05% of HCC cases being caused by hepatitis B virus (HBV) infection<sup>[2]</sup>. The Chinese population generally follow the trilogy of "chronic hepatitis B-liver cirrhosis-HCC"<sup>[3]</sup>. In this population, 75%-80% of HCC cases progressively originate from the regenerative or dysplastic nodules of liver cirrhosis, whereas 15%-20% occur without cirrhosis<sup>[4]</sup>. Compared with patients with cirrhotic HCC, those with non-cirrhotic HCC have the following characteristics: Usually single and large tumors; less deletion and mutation of tumor suppressor genes such as *p53*; stronger DNA mismatch repair; milder liver injury; better liver compensatory function; and, generally, no significant interferon contraindications<sup>[4,5]</sup>. Moreover, patients with non-cirrhotic HCC have a longer postoperative tumor-free survival, although the overall survival time does not significantly increase<sup>[5,6]</sup> and there is still a risk of postoperative recurrence. Currently, it is unclear whether clinical cure can reduce the risk of postoperative recurrence and improve survival rate in these patients. Therefore, we report the case of a patient with HBV-associated non-cirrhotic HCC who achieved a clinical cure and liver fibrosis reversal following treatment with entecavir (ETV) in combination with pegylated interferon alfa-2b (PEG IFN $\alpha$ -2b) and hepatitis B vaccine after hepatectomy for HCC.

**CASE PRESENTATION****Chief complaints**

A 47-year-old male patient who had HBV infection for 25 years and underwent hepatectomy for HCC 4 years ago was admitted to our institution.

Manautou JE, Ozaki I

**S-Editor:** Huang P**L-Editor:** Wang TQ**P-Editor:** Xing YX

### History of present illness

The patient was found to have HBV infection 25 years ago with normal liver function during follow-up. In 2000, he developed abnormal liver function and was diagnosed with HBeAg-positive chronic hepatitis B, for which he was administered lamivudine (LAM) antiviral therapy; however, he discontinued the antiviral therapy after 2 years. In 2006, he was administered ETV antiviral therapy. In 2009, HBeAg seroconversion was achieved, and HBV DNA (Cobas) was maintained at < 20 IU/mL. In October 2016, color Doppler ultrasonography showed a space-occupying hepatic lesion, and it was confirmed to be an HCC (5.3 cm × 5 cm × 5 cm) by enhanced magnetic resonance imaging (MRI) of the liver at Zhongshan Hospital Affiliated to Fudan University (Figure 1). Subsequently, special segmental hepatectomy was performed. Intraoperatively, a tumor was found in segment V, with a complete capsule, clear boundary, and soft texture; moreover, no tumor thrombus was found in the hepatic and portal veins or bile ducts. Postoperative pathological examination confirmed a grade II HCC with no nodular cirrhosis (G1S3, Figure 2A). Postoperatively, the patient continued taking ETV, regular follow-ups revealed normal liver function, and MRI findings did not change significantly.

### History of past illness

The patient had no previous noteworthy medical history.

### Personal and family history

The patient did not smoke tobacco or consume alcohol. His father died of HCC in 1974.

### Physical examination

The patient's height and weight were 176 cm and 76 kg, respectively. The patient had a body temperature of 36.2 °C, blood pressure of 145/78 mmHg, and pulse rate of 76 beats/min. The abdomen was soft and flat, with no pain or tenderness. No edema of the lower extremities was observed.

### Laboratory examinations

The results of the analyses performed on February 27, 2019 before the initial treatment, were as follows: For serology (Abbott), HBsAg, 572.03 IU/mL; HBeAb, 0.79 S/CO; HBcAb, 1.13 S/CO; and alpha-fetoprotein (AFP), 3.06 ng/mL; for biochemistry, alanine aminotransferase (ALT), 22 U/L; and aspartate aminotransferase (AST), 25 U/L; for virology, HBV DNA (cobas), < 20 IU/mL; and for the blood routine test, white blood cell count,  $6.38 \times 10^9/L$ ; neutrophil count,  $2.21 \times 10^9/L$ ; and platelet count,  $156 \times 10^9/L$ . The results of the thyroid function tests (TSH, FT3, and FT4) were normal; autoimmune liver disease-related antibodies were all negative.

### Imaging examinations

Electrocardiography was normal, and abdominal color Doppler ultrasonography and liver ultrasound scans showed slightly coarse images, with no nodules or space-occupying lesions.

## FINAL DIAGNOSIS

HBeAg negative chronic hepatitis B; non-cirrhotic HCC after hepatectomy.

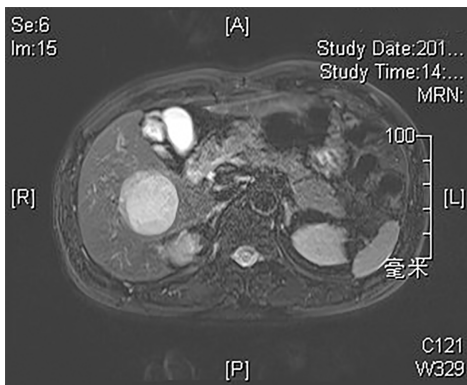
## TREATMENT

The treatment regimen was PEG IFN $\alpha$ -2b (180  $\mu$ g qw, Amoytop Biotech Co., LTD., Xiamen, China) + ETV (0.5 mg qd, Bristol Myers Squibb Co., NY, United States). After 12 wk, hepatitis B vaccine (60  $\mu$ g qm, Shenzhen Kangtai Biological Products Co., Ltd., Shenzhen, China) was added.

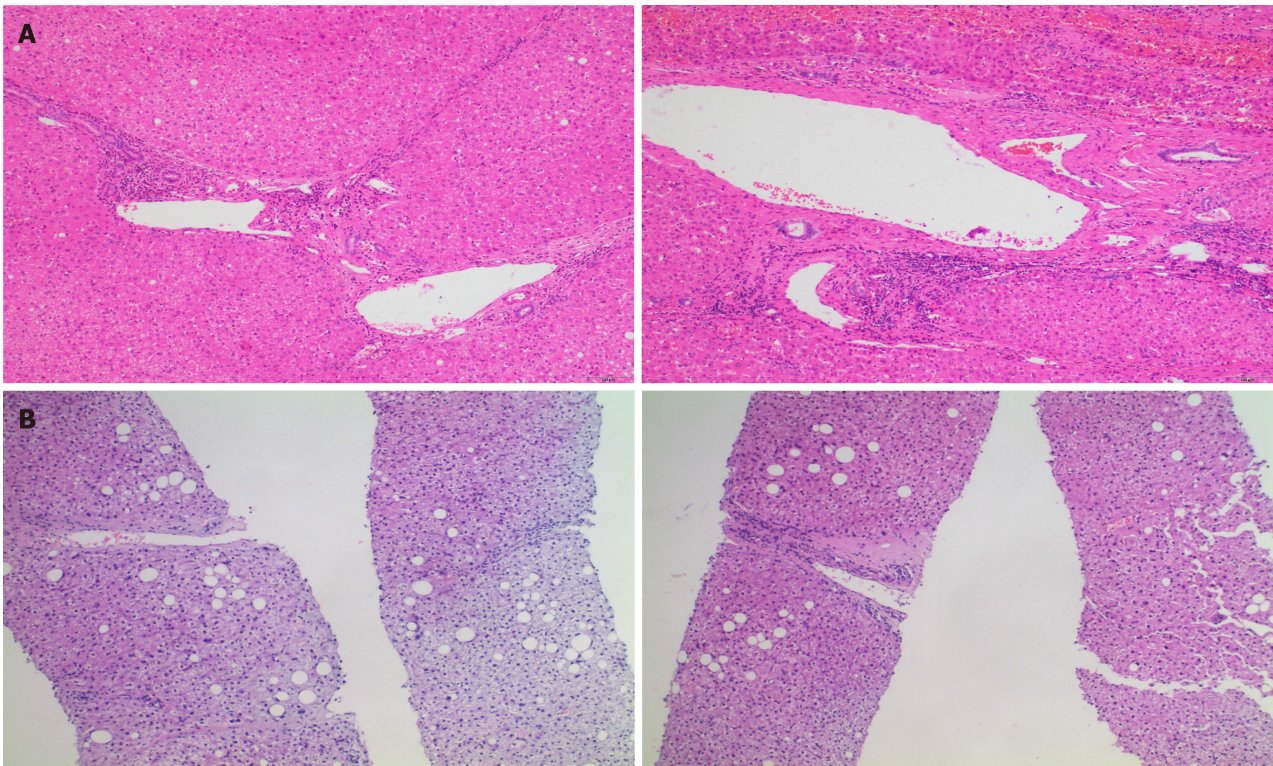
## OUTCOME AND FOLLOW-UP

Before the combined treatment, the scores of the FIB-4<sup>[7]</sup> and APRI<sup>[8]</sup>, two recognized





**Figure 1** Location map of the liver tumor.

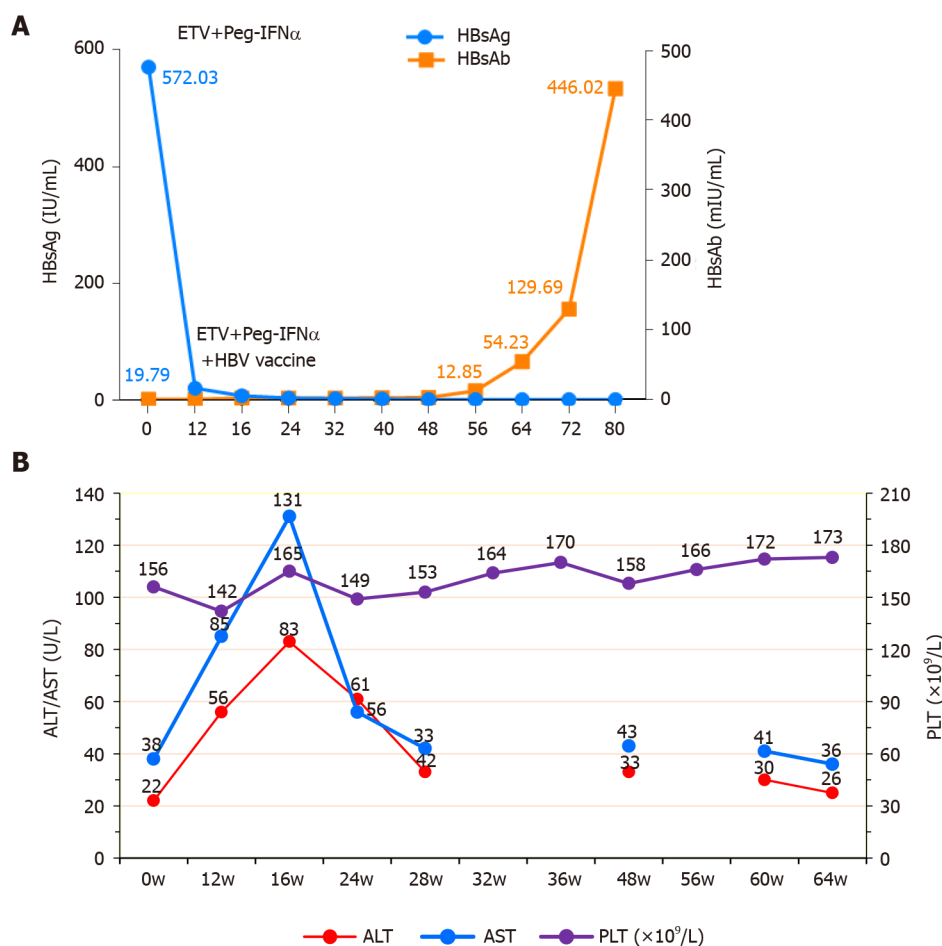


**Figure 2 Histology.** A: Pathological staining of the resected liver cancer tissue at Zhongshan Hospital, Shanghai in October 2016 (G1S3); B: Liver puncture biopsy (G2S1) performed at Quanzhou First Hospital in July 2020.

indices for noninvasive liver fibrosis, were 2.39 and 24.36, respectively. No significant adverse reactions were found during the combined treatment, and the routine blood and biochemistry indices varied within the normal range. After 12 wk of treatment, HBsAg decreased (572.0 to 19.79 IU/mL), ALT and AST levels increased (ALT/AST, 56/85 U/L), and hepatitis B vaccine was added as monthly treatment. After 16 wk of treatment, HBsAg further decreased, HBsAb increased, and ALT and AST levels peaked (ALT/AST, 83/131 U/L). After 28 wk of treatment, HBsAg and HBsAb further increased (2.38 mIU/mL), whereas ALT and AST levels decreased to normal levels. After 48 wk of treatment, HBsAb further increased (12.85 mIU/mL), and ALT and AST levels normalized. After 60 wk of treatment, HBsAg disappeared with seroconversion, whereas HBsAb further increased (129.69 mIU/mL). After 64 wk of treatment, the scores of the FIB-4 and APRI were significantly reduced (1.13 and 14.45, respectively), and HBsAb further increased to 446.02 mIU/mL, reaching the level of clinical cure (Figure 3).

#### **Pathological findings**

On July 12, 2020 (60 wk), a liver puncture biopsy was performed and assessed,



**Figure 3** Changes in the laboratory examination results during treatment. A: Changes in the hepatitis B virology indices HBsAg and HBsAb; B: Changes in alanine aminotransferase and aspartate aminotransferase levels, and platelet count. ETV: Entecavir; Peg-IFN $\alpha$ : Pegylated interferon alpha-2b; HBV: Hepatitis B virus; AST: Alanine aminotransferase; ALT: Aspartate aminotransferase; PLT: Platelet count.

showing slightly disordered arrangement of hepatic plates, swollen hepatocytes with some showing balloon-like changes, focal and narrow strip-like necrosis, a small amount of lymphocyte infiltration in the portal area, and mild interfacial inflammation, findings consistent with chronic hepatitis (G2S1, **Figure 2B**). Immunohistochemistry showed negative HBsAg and HBcAg results. Compared with the pathological results of HCC resection in October 2016 (Zhongshan Hospital, Shanghai, G1S3), the degree of fibrosis was significantly reversed.

## DISCUSSION

This paper reports a patient with HBeAg-negative chronic hepatitis B who had been treated with long-term oral ETV antiviral therapy and was regularly followed in the outpatient clinic. The AFP level was consistently normal. When HCC was found on color Doppler ultrasonography, there were no signs of clinical discomfort or metastasis, such as portal vein and bile duct tumor thrombi. After timely surgical treatment, survival was prolonged. Therefore, reexamination by AFP analysis and color Doppler ultrasonography or enhanced CT/MRI regularly every 3-6 mo to detect HCC at an early stage is particularly important for reducing HCC mortality.

This patient had no discomfort, and his liver function was normal, with a single large tumor on imaging. Postoperative pathological analyses confirmed no cirrhosis or nodules; therefore, he was classified as a patient with non-cirrhotic HCC. Such patients have been shown to have a good prognosis after early surgical resection; however, the risk of postoperative HCC recurrence persists<sup>[9]</sup>. Several factors can affect postoperative HCC recurrence, among which HBsAg is the main virus factor<sup>[10,11]</sup>. The higher the HBsAg level, the higher the long-term postoperative recurrence rate<sup>[12]</sup>. During the seroconversion or disappearance of HBsAg, the long-term recurrence rate

of HCC decreases significantly<sup>[13]</sup>. Interferon not only has antiviral, anti-fibrosis, and antitumor effects (or prevents HCC recurrence) but also inhibits HBsAg production and even eliminates HBsAg<sup>[14]</sup>. In 2019, a study showed that when the HBsAg titers of patients treated with nucleos(t)ide analogs (NAs) were  $\leq 1500$  IU/mL, NA sequential/combination therapy with PEG IFN $\alpha$ -2b is conducive to reducing or even eliminating HBsAg and achieving a clinical cure<sup>[15]</sup>. However, there are still a small number of reports on PEG IFN $\alpha$ -2b combination therapy for postoperative treatment of patients with HCC, especially those without liver cirrhosis. The current patient was treated with a combination therapy of ETV + PEG IFN $\alpha$ -2b + hepatitis B vaccine. Currently, HBsAg seroconversion has been achieved, suggesting a clinical cure for HBV infection. Severe liver fibrosis is a risk factor for postoperative HCC recurrence<sup>[16]</sup>; moreover, the higher the degree of liver fibrosis, the higher the postoperative recurrence risk<sup>[16,17]</sup>. Previous studies have shown that the resolution of fibrosis occurred in HBV-infected patients after NAs or IFN $\alpha$  treatment<sup>[18,19]</sup>. After 60 wk of a combination therapy of ETV + PEG IFN $\alpha$ -2b, the pathological reexamination results of the liver tissue showed that liver fibrosis was significantly reversed (S3 to S1). The noninvasive liver fibrosis indices also decreased significantly (FIB-4, 2.39 to 1.13; APRI, 24.36 to 14.45). Thus, the resolution of fibrosis indicated that the possibility of HCC recurrence was significantly reduced. However, due to the short follow-up period, further studies are required to clarify the risk of long-term HCC recurrence.

Hepatitis B vaccine can activate host immune cells and induce the expression of dendritic cells and specific cytotoxic T lymphocytes, thereby improving the response rate to PEG IFN $\alpha$ -2b, reducing the HBsAg level, and promoting the secretion of anti-HBs<sup>[20,21]</sup>. For immunocompromised or unresponsive adults, the vaccination dose (60  $\mu$ g) or administration frequency should be increased<sup>[3]</sup>; hence, it is safe and effective to apply combination therapy with 60  $\mu$ g of hepatitis B vaccine for this patient.

An acute elevation of ALT is mainly immune-mediated, which may mark the transition to inactive disease or infection clearance<sup>[22]</sup>. Patients, more commonly, experience an acute elevation of ALT during PEG IFN $\alpha$ -2b treatment, and such patients achieve better treatment outcomes. An open-label, multicenter study in South Korea included 740 patients with chronic hepatitis B who received tenofovir (TDF) or PEG IFN $\alpha$  alone or in combination and were followed for 120 wk. The results showed that the acute elevation of ALT caused by PEG IFN $\alpha$  generally occurred in the first 4 wk of treatment, and TDF monotherapy rarely caused such elevation<sup>[23]</sup>. Another international, multicenter, randomized controlled study retrospectively analyzed the relationship between the acute elevation of ALT and clinical benefits in a PEG IFN $\alpha$  + LAM combination group and a placebo group (treatment for 48 wk and follow-up for 24 wk). The results showed that the acute elevation of ALT mediated by host immunity was higher than the virus-mediated clearance rate of HBeAg (58% *vs* 20%,  $P = 0.008$ ), and HBsAg clearance was achieved in eight patients with acute elevation of ALT mediated by host immunity<sup>[24]</sup>.

It is suggested that PEG IFN $\alpha$ -2b therapy should be used earlier in the high-risk groups such as those with a family history of HCC. If combined PEG IFN $\alpha$ -2b is applied before HCC occurrence, the outcome may be different, and HCC may either not occur or its occurrence may be delayed. Even if HCC occurs, PEG IFN $\alpha$ -2b combination should be added postoperatively as early as possible to reduce the risk of HCC recurrence and prolong patient survival. It is important to determine whether this patient should continue the use of ETV antiviral therapy after using interferon for the maximum treatment course of 96 wk or discontinue it early. Patients with liver cirrhosis require long-term antiviral therapy<sup>[3]</sup>, while those with HCC complicating HBV infection should be treated with oral antiviral therapy throughout the treatment process<sup>[25]</sup>. Although this patient did not experience cirrhosis, he still developed HCC; therefore, he should be treated with long-term ETV antiviral therapy.

## CONCLUSION

HCC may still occur after antiviral treatment with NAs; thus, it is necessary to check the AFP level and color Doppler ultrasound regularly for 3-6 mo. For patients with non-cirrhotic HCC, if there are no contraindications to interferon, the therapeutic regimen of NAs combined with PEG IFN $\alpha$  and hepatitis B vaccine following hepatectomy should be used as soon as possible to achieve an HBV clinical cure and improve the recurrence-free survival rate.



## ACKNOWLEDGEMENTS

We gratefully thank all the medical staff at The Department of Infectious Diseases of The First Hospital of Quanzhou Affiliated to Fujian Medical University for the collection of clinical specimens.

## REFERENCES

- 1 **Xiao J**, Wang F, Wong NK, He J, Zhang R, Sun R, Xu Y, Liu Y, Li W, Koike K, He W, You H, Miao Y, Liu X, Meng M, Gao B, Wang H, Li C. Global liver disease burdens and research trends: Analysis from a Chinese perspective. *J Hepatol* 2019; **71**: 212-221 [PMID: [30871980](#) DOI: [10.1016/j.jhep.2019.03.004](#)]
- 2 **Qin S**. Interim Report on primary Liver Cancer Clinical Registry survey (CLCS) in China. In: Chinese Society of Clinical Oncology, 2019
- 3 **Chinese Society of Infectious Diseases**, Chinese Medical Association, Chinese Society of Hepatology. Guideline on prevention and treatment of chronic hepatitis B in China (2019 edition). *Zhonghua Chuanran Bing Zazhi* 2019; **37**: 711-736 [DOI: [10.3760/cma.j.issn.1000-6680.2019.12.003](#)]
- 4 **Yang SL**, Liu LP, Sun YF, Yang XR, Fan J, Ren JW, Chen GG, Lai PB. Distinguished prognosis after hepatectomy of HBV-related hepatocellular carcinoma with or without cirrhosis: a long-term follow-up analysis. *J Gastroenterol* 2016; **51**: 722-732 [PMID: [26607653](#) DOI: [10.1007/s00535-015-1146-0](#)]
- 5 **Gawrieh S**, Dakhoul L, Miller E, Scanga A, deLemos A, Kettler C, Burney H, Liu H, Abu-Sbeih H, Chalasani N, Wattacheril J. Characteristics, aetiologies and trends of hepatocellular carcinoma in patients without cirrhosis: a United States multicentre study. *Aliment Pharmacol Ther* 2019; **50**: 809-821 [PMID: [31475372](#) DOI: [10.1111/apt.15464](#)]
- 6 **Kim JM**, Kwon CH, Joh JW, Park JB, Lee JH, Kim SJ, Paik SW, Park CK, Yoo BC. Differences between hepatocellular carcinoma and hepatitis B virus infection in patients with and without cirrhosis. *Ann Surg Oncol* 2014; **21**: 458-465 [PMID: [24132624](#) DOI: [10.1245/s10434-013-3302-1](#)]
- 7 **Sterling RK**, Lissen E, Clumeck N, Sola R, Correa MC, Montaner J, S Sulkowski M, Torriani FJ, Dieterich DT, Thomas DL, Messinger D, Nelson M; APRICOT Clinical Investigators. Development of a simple noninvasive index to predict significant fibrosis in patients with HIV/HCV coinfection. *Hepatology* 2006; **43**: 1317-1325 [PMID: [16729309](#) DOI: [10.1002/hep.21178](#)]
- 8 **Wai CT**, Greenon JK, Fontana RJ, Kalbfleisch JD, Marrero JA, Conjeevaram HS, Lok AS. A simple noninvasive index can predict both significant fibrosis and cirrhosis in patients with chronic hepatitis C. *Hepatology* 2003; **38**: 518-526 [PMID: [12883497](#) DOI: [10.1053/jhep.2003.50346](#)]
- 9 **Qi W**, Zhang Q, Xu Y, Wang X, Yu F, Zhang Y, Zhao P, Guo H, Zhou C, Wang Z, Sun Y, Liu L, Xuan W, Wang J. Peg-interferon and nucleos(t)ide analogue combination at inception of antiviral therapy improves both anti-HBV efficacy and long-term survival among HBV DNA-positive hepatocellular carcinoma patients after hepatectomy/ablation. *J Viral Hepat* 2020; **27**: 387-396 [PMID: [31755220](#) DOI: [10.1111/jvh.13236](#)]
- 10 **Xu XF**, Xing H, Han J, Li ZL, Lau WY, Zhou YH, Gu WM, Wang H, Chen TH, Zeng YY, Li C, Wu MC, Shen F, Yang T. Risk Factors, Patterns, and Outcomes of Late Recurrence After Liver Resection for Hepatocellular Carcinoma: A Multicenter Study From China. *JAMA Surg* 2019; **154**: 209-217 [PMID: [30422241](#) DOI: [10.1001/jamasurg.2018.4334](#)]
- 11 **Qiu JF**, Ye JZ, Feng XZ, Qi YP, Ma L, Yuan WP, Zhong JH, Zhang ZM, Xiang BD, Li LQ. Pre- and post-operative HBsAg levels may predict recurrence and survival after curative resection in patients with HBV-associated hepatocellular carcinoma. *J Surg Oncol* 2017; **116**: 140-148 [PMID: [28628729](#) DOI: [10.1002/jso.24628](#)]
- 12 **Zhou HB**, Li QM, Zhong ZR, Hu JY, Jiang XL, Wang H, Wang H, Yang B, Hu HP. Level of hepatitis B surface antigen might serve as a new marker to predict hepatocellular carcinoma recurrence following curative resection in patients with low viral load. *Am J Cancer Res* 2015; **5**: 756-771 [PMID: [25973313](#)]
- 13 **Kubo S**, Hirohashi K, Tanaka H, Tsukamoto T, Shuto T, Higaki I, Takemura S, Yamamoto T, Nishiguchi S, Kinoshita H. Virologic and biochemical changes and prognosis after liver resection for hepatitis B virus-related hepatocellular carcinoma. *Dig Surg* 2001; **18**: 26-33 [PMID: [11244256](#) DOI: [10.1159/000050093](#)]
- 14 **Tian S**, Hui X, Fan Z, Li Q, Zhang J, Yang X, Ma X, Huang B, Chen D, Chen H. Suppression of hepatocellular carcinoma proliferation and hepatitis B surface antigen secretion with interferon- $\lambda$ 1 or PEG-interferon- $\lambda$ 1. *FASEB J* 2014; **28**: 3528-3539 [PMID: [24769671](#) DOI: [10.1096/fj.14-250704](#)]
- 15 **Ning Q**, Wu D, Wang GQ, Ren H, Gao ZL, Hu P, Han MF, Wang Y, Zhang WH, Lu FM, Wang FS. Roadmap to functional cure of chronic hepatitis B: An expert consensus. *J Viral Hepat* 2019; **26**: 1146-1155 [PMID: [31087479](#) DOI: [10.1111/jvh.13126](#)]
- 16 **Suh SW**, Choi YS. Influence of liver fibrosis on prognosis after surgical resection for resectable single hepatocellular carcinoma. *ANZ J Surg* 2019; **89**: 211-215 [PMID: [30117629](#) DOI: [10.1111/ans.14732](#)]
- 17 **Ko S**, Kanehiro H, Hisanaga M, Nagao M, Ikeda N, Nakajima Y. Liver fibrosis increases the risk of



- intrahepatic recurrence after hepatectomy for hepatocellular carcinoma. *Br J Surg* 2002; **89**: 57-62 [PMID: [11851664](#) DOI: [10.1046/j.0007-1323.2001.01969.x](#)]
- 18 **Chang TT**, Liaw YF, Wu SS, Schiff E, Han KH, Lai CL, Safadi R, Lee SS, Halota W, Goodman Z, Chi YC, Zhang H, Hindes R, Iloeje U, Beebe S, Kreter B. Long-term entecavir therapy results in the reversal of fibrosis/cirrhosis and continued histological improvement in patients with chronic hepatitis B. *Hepatology* 2010; **52**: 886-893 [PMID: [20683932](#) DOI: [10.1002/hep.23785](#)]
  - 19 **Marcellin P**, Gane E, Buti M, Afdhal N, Sievert W, Jacobson IM, Washington MK, Germanidis G, Flaherty JF, Aguilar Schall R, Bornstein JD, Kitrinos KM, Subramanian GM, McHutchison JG, Heathcote EJ. Regression of cirrhosis during treatment with tenofovir disoproxil fumarate for chronic hepatitis B: a 5-year open-label follow-up study. *Lancet* 2013; **381**: 468-475 [PMID: [23234725](#) DOI: [10.1016/S0140-6736\(12\)61425-1](#)]
  - 20 **Shaaban Hanafy A**. Impact of hepatitis B vaccination on HBsAg kinetics, interferon-inducible protein 10 level and recurrence of viremia. *Cytokine* 2017; **99**: 99-105 [PMID: [28802168](#) DOI: [10.1016/j.cyto.2017.08.002](#)]
  - 21 **Lee JH**, Lee YB, Cho EJ, Yu SJ, Yoon JH, Kim YJ. Entecavir Plus Pegylated Interferon and Sequential HBV Vaccination Increases HBsAg Seroclearance: A Randomized Controlled Proof-of-Concept Study. *Clin Infect Dis* 2020 [PMID: [32556157](#) DOI: [10.1093/cid/ciaa807](#)]
  - 22 **Ghany MG**, Feld JJ, Chang KM, Chan HLY, Lok ASF, Visvanathan K, Janssen HLA. Serum alanine aminotransferase flares in chronic hepatitis B infection: the good and the bad. *Lancet Gastroenterol Hepatol* 2020; **5**: 406-417 [PMID: [32057301](#) DOI: [10.1016/S2468-1253\(19\)30344-9](#)]
  - 23 **Ahn SH**, Marcellin P, Ma X, Caruntu FA, Tak WY, Elkhatab M, Chuang WL, Tabak F, Mehta R, Petersen J, Guyer W, Jump B, Chan A, Subramanian M, Crans G, Fung S, Buti M, Gaeta GB, Hui AJ, Papatheodoridis G, Flisiak R, Chan HLY. Correction to: Hepatitis B Surface Antigen Loss with Tenofovir Disoproxil Fumarate Plus Peginterferon Alfa-2a: Week 120 Analysis. *Dig Dis Sci* 2019; **64**: 285-286 [PMID: [30324553](#) DOI: [10.1007/s10620-018-5294-y](#)]
  - 24 **Flink HJ**, Sprengers D, Hansen BE, van Zonneveld M, de Man RA, Schalm SW, Janssen HL; HBV 99-01 Study Group. Flares in chronic hepatitis B patients induced by the host or the virus? *Gut* 2005; **54**: 1604-1609 [PMID: [15923670](#) DOI: [10.1136/gut.2004.062208](#)]
  - 25 **Department of Medical Administration, National Health and Health Commission of the People's Republic of China**. Guidelines for the diagnosis and treatment of primary Liver cancer (2019 edition). *Zhonghua Ganzang Bing Zazhi* 2020; 112-128 [DOI: [10.3760/cma.j.issn.1007-3418.2020.02.004](#)]



Published by **Baishideng Publishing Group Inc**  
7041 Koll Center Parkway, Suite 160, Pleasanton, CA 94566, USA

**Telephone:** +1-925-3991568

**E-mail:** [bpgoffice@wjgnet.com](mailto:bpgoffice@wjgnet.com)

**Help Desk:** <https://www.f6publishing.com/helpdesk>

<https://www.wjgnet.com>

