

World Journal of *Clinical Cases*

World J Clin Cases 2021 January 6; 9(1): 1-290



Contents

Thrice Monthly Volume 9 Number 1 January 6, 2021

OPINION REVIEW

- 1 Necessary problems in re-emergence of COVID-19
Chen S, Ren LZ, Ouyang HS, Liu S, Zhang LY

REVIEW

- 8 COVID-19: An overview and a clinical update
Krishnan A, Hamilton JP, Alqahtani SA, Woreta TA

ORIGINAL ARTICLE

Retrospective Cohort Study

- 24 Log odds of positive lymph nodes is a better prognostic factor for oesophageal signet ring cell carcinoma than N stage
Wang F, Gao SG, Xue Q, Tan FW, Gao YS, Mao YS, Wang DL, Zhao J, Li Y, Yu XY, Cheng H, Zhao CG, Mu JW
- 36 Modified procedure for prolapse and hemorrhoids: Lower recurrence, higher satisfaction
Chen YY, Cheng YF, Wang QP, Ye B, Huang CJ, Zhou CJ, Cai M, Ye YK, Liu CB
- 47 Angiotensin converting enzymes inhibitors or angiotensin receptor blockers should be continued in COVID-19 patients with hypertension
Tian C, Li N, Bai Y, Xiao H, Li S, Ge QG, Shen N, Ma QB

Retrospective Study

- 61 Massively prolapsed intervertebral disc herniation with interlaminar endoscopic spine system Delta endoscope: A case series
Meng SW, Peng C, Zhou CL, Tao H, Wang C, Zhu K, Song MX, Ma XX
- 71 Primary lung cancer with radioiodine avidity: A thyroid cancer cohort study
Lu YL, Chen ST, Ho TY, Chan WH, Wong RJ, Hsueh C, Lin SF
- 81 Is traumatic meniscal lesion associated with acute fracture morphology changes of tibia plateau? A series of arthroscopic analysis of 67 patients
Chen YD, Chen SX, Liu HG, Zhao XS, Ou WH, Li HX, Huang HX

Observational Study

- 91 Role of relaxin in diastasis of the pubic symphysis peripartum
Wang Y, Li YQ, Tian MR, Wang N, Zheng ZC

SYSTEMATIC REVIEWS

- 102 Chinese medicine formulas for nonalcoholic fatty liver disease: Overview of systematic reviews
Dai L, Zhou WJ, Zhong LLD, Tang XD, Ji G

- 118 Comparative profile for COVID-19 cases from China and North America: Clinical symptoms, comorbidities and disease biomarkers

Badawi A, Vasileva D

META-ANALYSIS

- 133 Polymerase chain reaction-based tests for detecting *Helicobacter pylori* clarithromycin resistance in stool samples: A meta-analysis

Gong RJ, Xu CX, Li H, Liu XM

CASE REPORT

- 148 Surgery-first for a patient with mild hemifacial microsomia: A case report and review of literature

Song JY, Yang H, He X, Gao S, Wu GM, Hu M, Zhang Y

- 163 Late-onset non-islet cell tumor hypoglycemia: A case report

Matsumoto S, Yamada E, Nakajima Y, Yamaguchi N, Okamura T, Yajima T, Yoshino S, Horiguchi K, Ishida E, Yoshikawa M, Nagaoka J, Sekiguchi S, Sue M, Okada S, Fukuda I, Shirabe K, Yamada M

- 170 Risk of group aggregative behavior during COVID-19 outbreak: A case report

Zuo H, Hu ZB, Zhu F

- 175 Low-grade fibromyxoid sarcoma of the liver: A case report

Dugalic V, Ignjatovic II, Kovac JD, Ilic N, Sopta J, Ostojic SR, Vasin D, Bogdanovic MD, Dumic I, Milovanovic T

- 183 Treatment of Stanford type A aortic dissection with triple pre-fenestration, reduced diameter, and three-dimensional-printing techniques: A case report

Zhang M, Tong YH, Liu C, Li XQ, Liu CJ, Liu Z

- 190 Hyperprolactinemia due to pituitary metastasis: A case report

Liu CY, Wang YB, Zhu HQ, You JL, Liu Z, Zhang XF

- 197 Pulmonary thromboembolism after distal ulna and radius fractures surgery: A case report and a literature review

Lv B, Xue F, Shen YC, Hu FB, Pan MM

- 204 Myeloid neoplasm with eosinophilia and rearrangement of platelet-derived growth factor receptor beta gene in children: Two case reports

Wang SC, Yang WY

- 211 Sclerosing angiomatoid nodular transformation of the spleen: A case report and literature review

Li SX, Fan YH, Wu H, Lv GY

- 218 Late recurrence of papillary thyroid cancer from needle tract implantation after core needle biopsy: A case report

Kim YH, Choi IH, Lee JE, Kim Z, Han SW, Hur SM, Lee J

- 224** Atypical adult-onset Still's disease with an initial and sole manifestation of liver injury: A case report and review of literature
Yu F, Qin SY, Zhou CY, Zhao L, Xu Y, Jia EN, Wang JB
- 232** Type A aortic dissection developed after type B dissection with the presentation of shoulder pain: A case report
Yin XB, Wang XK, Xu S, He CY
- 236** Hemosuccus pancreaticus caused by gastroduodenal artery pseudoaneurysm associated with chronic pancreatitis: A case report and review of literature
Cui HY, Jiang CH, Dong J, Wen Y, Chen YW
- 245** Endoscopic treatment for acute appendicitis with coexistent acute pancreatitis: Two case reports
Du ZQ, Ding WJ, Wang F, Zhou XR, Chen TM
- 252** Residual tumor and central lymph node metastasis after thermal ablation of papillary thyroid carcinoma: A case report and review of literature
Hua Y, Yang JW, He L, Xu H, Huo HZ, Zhu CF
- 262** Endoscopic salvage treatment of histoacryl after stent application on the anastomotic leak after gastrectomy: A case report
Kim HS, Kim Y, Han JH
- 267** Immunosuppressant treatment for IgG4-related sclerosing cholangitis: A case report
Kim JS, Choi WH, Lee KA, Kim HS
- 274** Intraparenchymal hemorrhage after surgical decompression of an epencephalon arachnoid cyst: A case report
Wang XJ
- 278** Krukenberg tumor with concomitant ipsilateral hydronephrosis and spermatic cord metastasis in a man: A case report
Tsao SH, Chuang CK
- 284** Simultaneous bilateral acromial base fractures after staged reverse total shoulder arthroplasty: A case report
Kim DH, Kim BS, Cho CH

ABOUT COVER

Editorial Board Member of *World Journal of Clinical Cases*, Dr. Antonio Corvino is a PhD in the Motor Science and Wellness Department of University of Naples "Parthenope". After obtaining his MD degree from the School of Medicine, Second University of Naples (2008), he completed a residency in Radiology at the University of Naples Federico II (2014). Following post-graduate training at the Catholic University of Rome, yielding a second level Master's degree in "Internal Ultrasound Diagnostic and Echo-Guided Therapies" (2015), he served on the directive board of Young Directive of Italian Society of Ultrasound in Medicine and Biology (2016-2018). His ongoing research interests involve ultrasound and ultrasound contrast media in abdominal and non-abdominal applications, mainly in gastrointestinal, hepatic, vascular, and musculoskeletal imaging. (L-Editor: Filipodia)

AIMS AND SCOPE

The primary aim of *World Journal of Clinical Cases* (*WJCC*, *World J Clin Cases*) is to provide scholars and readers from various fields of clinical medicine with a platform to publish high-quality clinical research articles and communicate their research findings online.

WJCC mainly publishes articles reporting research results and findings obtained in the field of clinical medicine and covering a wide range of topics, including case control studies, retrospective cohort studies, retrospective studies, clinical trials studies, observational studies, prospective studies, randomized controlled trials, randomized clinical trials, systematic reviews, meta-analysis, and case reports.

INDEXING/ABSTRACTING

The *WJCC* is now indexed in Science Citation Index Expanded (also known as SciSearch®), Journal Citation Reports/Science Edition, PubMed, and PubMed Central. The 2020 Edition of Journal Citation Reports® cites the 2019 impact factor (IF) for *WJCC* as 1.013; IF without journal self cites: 0.991; Ranking: 120 among 165 journals in medicine, general and internal; and Quartile category: Q3.

RESPONSIBLE EDITORS FOR THIS ISSUE

Production Editor: Yan-Xia Xing; Production Department Director: Yun-Xiaojian Wu; Editorial Office Director: Jin-Lai Wang.

NAME OF JOURNAL

World Journal of Clinical Cases

ISSN

ISSN 2307-8960 (online)

LAUNCH DATE

April 16, 2013

FREQUENCY

Thrice Monthly

EDITORS-IN-CHIEF

Dennis A Bloomfield, Sandro Vento, Bao-gan Peng

EDITORIAL BOARD MEMBERS

<https://www.wjgnet.com/2307-8960/editorialboard.htm>

PUBLICATION DATE

January 6, 2021

COPYRIGHT

© 2021 Baishideng Publishing Group Inc

INSTRUCTIONS TO AUTHORS

<https://www.wjgnet.com/bpg/gerinfo/204>

GUIDELINES FOR ETHICS DOCUMENTS

<https://www.wjgnet.com/bpg/GerInfo/287>

GUIDELINES FOR NON-NATIVE SPEAKERS OF ENGLISH

<https://www.wjgnet.com/bpg/gerinfo/240>

PUBLICATION ETHICS

<https://www.wjgnet.com/bpg/GerInfo/288>

PUBLICATION MISCONDUCT

<https://www.wjgnet.com/bpg/gerinfo/208>

ARTICLE PROCESSING CHARGE

<https://www.wjgnet.com/bpg/gerinfo/242>

STEPS FOR SUBMITTING MANUSCRIPTS

<https://www.wjgnet.com/bpg/GerInfo/239>

ONLINE SUBMISSION

<https://www.f6publishing.com>



Krukenberg tumor with concomitant ipsilateral hydronephrosis and spermatic cord metastasis in a man: A case report

Shu-Han Tsao, Cheng-Keng Chuang

ORCID number: Shu-Han Tsao [0000-0002-8490-6736](https://orcid.org/0000-0002-8490-6736); Cheng-Keng Chuang [0000-0001-6154-1220](https://orcid.org/0000-0001-6154-1220).

Author contributions: Tsao SH is the first author; Tsao SH wrote the case report and completed the literature review; Chuang CK performed the final editing and prepared the paper for approval by the authors; All authors read and approved the final manuscript.

Informed consent statement:

Written informed consent was obtained from the patient to publish this case report and the accompanying images.

Conflict-of-interest statement: The authors declare that they have no conflict of interest.

CARE Checklist (2016) statement:

The authors have read the CARE Checklist (2016), and the manuscript was prepared and revised according to the CARE Checklist (2016).

Open-Access: This article is an open-access article that was selected by an in-house editor and fully peer-reviewed by external reviewers. It is distributed in accordance with the Creative Commons Attribution NonCommercial (CC BY-NC 4.0) license, which permits others to distribute, remix, adapt, build

Shu-Han Tsao, Cheng-Keng Chuang, Division of Urology, Department of Surgery, Chang Gung Memorial Hospital, Taoyuan City 333, Taiwan

Corresponding author: Cheng-Keng Chuang, MD, PhD, Chief Doctor, Professor, Division of Urology, Department of Surgery, Chang Gung Memorial Hospital, No. 5 Fuxing Street, Guishan District, Taoyuan City 333, Taiwan. chuang89@cgmh.org.tw

Abstract

BACKGROUND

Tumors of the spermatic cord are rare, and approximately 25% are malignant neoplasms. Metastatic spermatic cord tumors are even rarer. Several studies have revealed that the most frequent primary tumors metastasizing to the spermatic cord and peritesticular tissues are neoplasms of the stomach and prostate. Furthermore, metastasis to the spermatic cord or epididymis may occur *via* retrograde lymphatic and hematic routes. We present the case of a man with gastric cancer that metastasized to the spermatic cord and epididymis, with concomitant ipsilateral hydronephrosis after surgical resection and chemotherapy for his primary tumor.

CASE SUMMARY

A 71-year-old man underwent total gastrectomy for pT4aN2 poorly differentiated gastric adenocarcinoma in December 2016. Two months after surgery, he received adjuvant chemotherapy with TS-1 from February 2017 to February 2018. Surveillance computed tomography (CT) was performed in June 2018, which did not reveal any sign of tumor recurrence. In November 2019, he presented with left lower quadrant abdominal pain and a palpable left inguinal-scrotal mass. CT revealed left mild hydronephrosis and a left scrotal mass measuring 4.0 cm × 1.7 cm. Tumor biomarkers, including alpha-fetoprotein (AFP), lactate dehydrogenase (LDH), beta-human chorionic gonadotropin (βHCG), carcinoembryonic antigen (CEA), and carbohydrate antigen 19-9 (CA19-9) were all normal. Renal and testicular echography showed left hydronephrosis and a left peritesticular soft tissue lesion with blood flow. Diagnostic ureteroscopy showed left lower ureter narrowing without an intraluminal lesion. A biopsy was obtained for the indurated spermatic cord and epididymis, which showed poorly differentiated adenocarcinoma. Immunohistochemical staining demonstrated that the tumor was diffusely and strongly positive for homeobox protein CDX2. The features were consistent with metastatic adenocarcinoma of a primary gastric tumor.

upon this work non-commercially, and license their derivative works on different terms, provided the original work is properly cited and the use is non-commercial. See: <http://creativecommons.org/licenses/by-nc/4.0/>

Manuscript source: Unsolicited manuscript

Specialty type: Medicine, research and experimental

Country/Territory of origin: Taiwan

Peer-review report's scientific quality classification

Grade A (Excellent): 0
Grade B (Very good): B
Grade C (Good): C
Grade D (Fair): 0
Grade E (Poor): 0

Received: October 7, 2020

Peer-review started: October 7, 2020

First decision: October 27, 2020

Revised: November 3, 2020

Accepted: November 13, 2020

Article in press: November 13, 2020

Published online: January 6, 2021

P-Reviewer: Tanabe K

S-Editor: Gao CC

L-Editor: Filipodia

P-Editor: Wang LL



CONCLUSION

In patients with a history of primary cancer, an inguinal mass of unknown cause with accompanying ipsilateral hydronephrosis may be a sign of distant metastasis from a primary tumor, especially of gastrointestinal origin.

Key Words: Case report; Epididymis; Gastric cancer; Krukenberg tumor; Male; Spermatic cord

©The Author(s) 2021. Published by Baishideng Publishing Group Inc. All rights reserved.

Core Tip: Gastric cancer rarely metastasizes to the spermatic cord, but when it does, the prognosis is typically unfavorable. Ipsilateral hydronephrosis caused by retrograde lymphatic metastasis is a possible manifestation of distant metastasis of gastric cancer. Additionally, a preexisting inguinal mass and earlier detection of hydronephrosis could also contribute to a more favorable outcome.

Citation: Tsao SH, Chuang CK. Krukenberg tumor with concomitant ipsilateral hydronephrosis and spermatic cord metastasis in a man: A case report. *World J Clin Cases* 2021; 9(1): 278-283

URL: <https://www.wjgnet.com/2307-8960/full/v9/i1/278.htm>

DOI: <https://dx.doi.org/10.12998/wjcc.v9.i1.278>

INTRODUCTION

Tumors of the spermatic cord are rare, and approximately 25% are malignant^[1]. Among the malignant neoplasms of the spermatic cord or epididymis, 8.1% are of metastatic origin, with the most frequent primary tumors originating in the stomach (42.8%) and the prostate (28.5%)^[2]. Metastasis to the spermatic cord or epididymis can spread through the retrograde lymphatic and hematic routes. We present the case of a patient with gastric cancer that metastasized to the spermatic cord and epididymis, with concomitant ipsilateral hydronephrosis after surgical resection and chemotherapy for treatment of the primary tumor.

CASE PRESENTATION

Chief complaints

A 71-year-old man came to the hospital in November 2019 with a palpable left inguinoscrotal mass and symptoms of intermittent left quadrant abdominal pain for more than 6 mo.

History of present illness

The patient had received total gastrectomy and chemotherapy in December 2016 for pT4aN2 gastric cancer. The histopathology disclosed mixed poorly differentiated adenocarcinoma with signet ring cell components. Chemotherapy regimens against the primary gastric cancer was oral TS-1 20 mg (gimeracil + oteracil + tegafur) from February 2017 to June 2018.

History of past illness

The patient had been in good health.

Personal and family history

The patient denied any positive personal or family history.

Physical examination

The physical examination revealed a palpable, left inguinoscrotal mass with induration at the spermatic cord and epididymis. An abdominal examination showed no palpable mass nor tenderness.

Laboratory examinations

Tumor biomarkers were: AFP, 2.5 ng/mL; prostate-specific antigen, 1.11 ng/mL; LDH 265 U/L; β HCG < 1 mIU/mL; CEA 3.95 ng/mL; and CA19-9, 16.6 U/mL.

Imaging examinations

Renal and testicular echography showed left hydronephrosis and a left peritesticular soft tissue lesion with blood flow. CT revealed a left scrotal mass (Figure 1A) and left mild hydronephrosis (Figure 2A). Left retrograde pyelography revealed multiple stenosis and narrowing points causing left hydronephrosis and hydroureter (Figure 3).

Diagnostic ureteroscopy showed left lower ureter segmental narrowing without an intraluminal lesion. Scrotal exploration and biopsy of the indurated spermatic cord and epididymis disclosed metastatic poorly differentiated adenocarcinoma (Figure 1B). An immunohistochemical study showed nests of poorly differentiated adenocarcinoma diffusely and strongly positive for homeobox protein CDX2 (Figure 4). The features of the tumor were consistent with metastatic adenocarcinoma of the primary gastric cancer.

Positron emission tomography with 2-deoxy-2-[fluorine-18]-fluoro-D-glucose integrated with computed tomography (18 F-FDG PET/CT) from skull vertex to upper thighs was performed at 60 min after injection of 18 F-FDG. The examination revealed a gastric stump recurrence, positive celiac lymph nodes, and distant metastases to the spine, ribs, sternum, pelvic bones, bilateral scapulae, pelvic cavity, left spermatic cord, and epididymis (Figure 5).

FINAL DIAGNOSIS

The patient's diagnosis was recurrent gastric cancer with multiple metastases from the gastric stump to the celiac lymph nodes, spine, ribs, sternum, pelvic bones, bilateral scapulae, pelvic cavity, left spermatic cord, and epididymis.

TREATMENT

Due to widespread metastatic cancer, the patient received palliative chemotherapy. The regimens were oral capecitabine 1000 mg twice a day and oxaliplatin 100 mg every two weeks from December 2019 to April 2020. After ten courses, this treatment was disrupted because the patient's clinical condition deteriorated.

OUTCOME AND FOLLOW-UP

Follow-up abdominal CT in March 2020 showed stationary bone and spermatic cord metastasis. There were no enlarged lymph nodes in the neck, mediastinum, or abdomen, and the left hydronephrosis showed regression (Figure 2B). Unfortunately, the patient's clinical condition deteriorated, and he became cachexic and passed away on June 2020.

DISCUSSION

Metastatic pathways of gastric cancer

Major routes of distant metastasis in gastric cancer are intraperitoneal, lymphatic, and direct invasion into neighboring organs^[3]. The most common sites of metastasis are the liver (48% of patients), peritoneum (32%), lung (15%), and bone (12%). The histological type of gastric cancer affects metastasis. Compared with generic adenocarcinoma, signet ring adenocarcinoma more frequently metastasizes within the peritoneum, to the bone and ovaries, and less frequently, to the lungs and liver^[4].

Krukenberg tumors

Krukenberg tumors are secondary ovarian tumors defined as carcinomas that have a significant signet-ring cell component to the histopathology^[5]. As previously mentioned, the major routes of distant metastasis in gastric cancer are intraperitoneal, lymphatic, and hematogenous. Lymphatic metastasis from the stomach to the ovaries

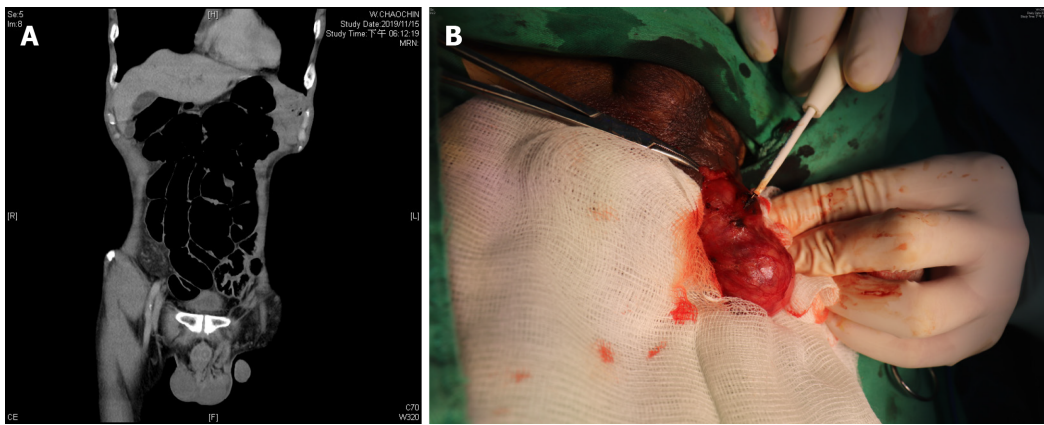


Figure 1 Tumor imaging and excision. A: Contrast-enhanced computed tomography of the abdomen reveals an irregular mass at the left spermatic cord extending to the epididymis; B: Intraoperative photograph of the indurated mass measuring 4.0 cm × 1.7 cm on the spermatic cord and epididymis, without invasion to the testis. A biopsy was obtained from the spot indicated by the pointer.

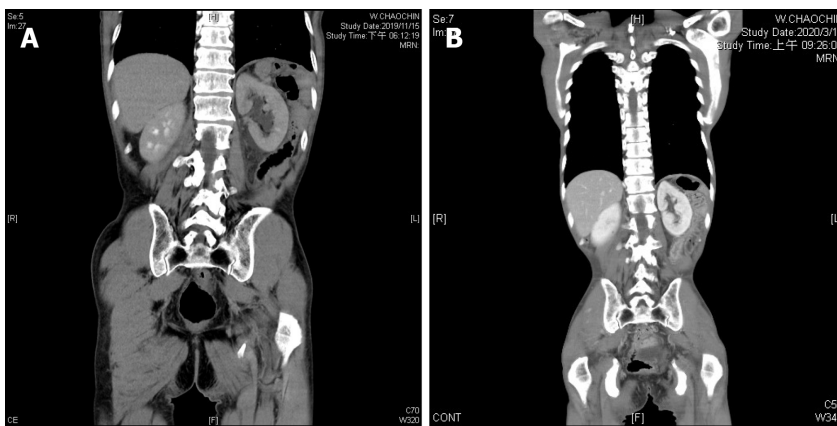


Figure 2 Ipsilateral hydronephrosis. A: Retrograde lymphatic metastasis-related left hydronephrosis in November 2019; B: Left hydronephrosis showed regression in March 2020, after systemic chemotherapy.

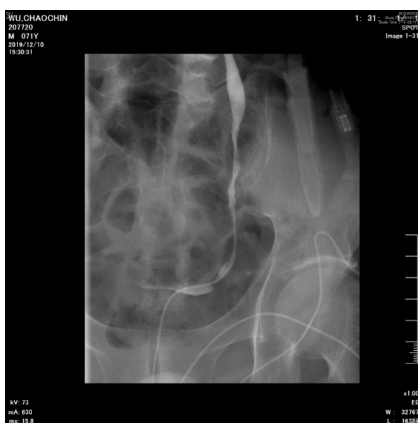

Figure 3 Left ureteral stenosis. Left retrograde pyelography showed multiple stenosis and narrowing points along middle to lower ureter, which led to left hydronephrosis and hydroureter.

predominates. The reason for this predominance could be the lymphatic vessel anatomy of urogenital lymph systems. The receptaculum chyli joins intestinal trunks, which connect *via* the celiac lymph nodes to the gastric lymph nodes. The extensive tumor infiltration of the receptaculum chyli would have resulted in blockage of the thoracic duct, with subsequent retrograde flow. The retrograde lymphatic pathway enables the gastric cancer cells to metastasize easily *via* the receptaculum chyli to the

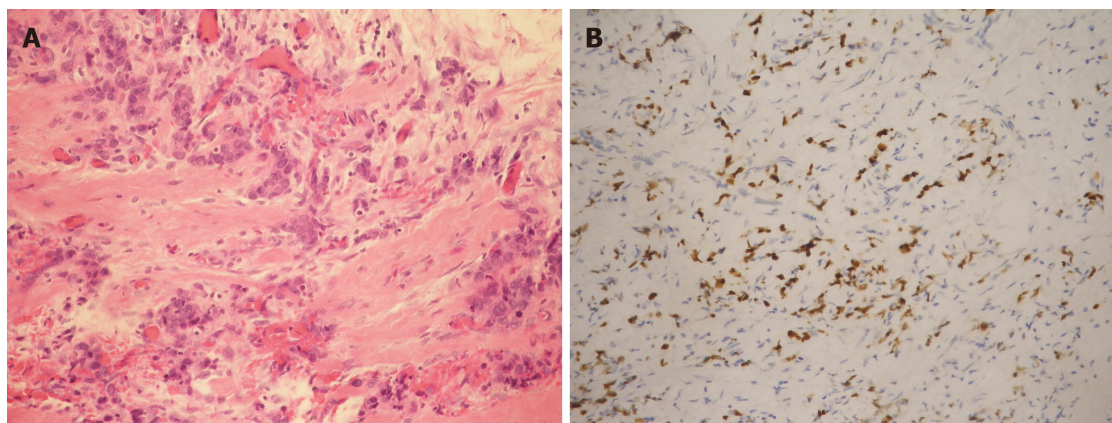


Figure 4 Histopathology. A: Hematoxylin and eosin-stained section showed fibrovascular tissue with infiltration of nests of poorly differentiated adenocarcinoma; B: The immunohistochemically stained section was diffusely and strongly positive for CDX2, which is a marker indicative of adenocarcinoma of intestinal origin.

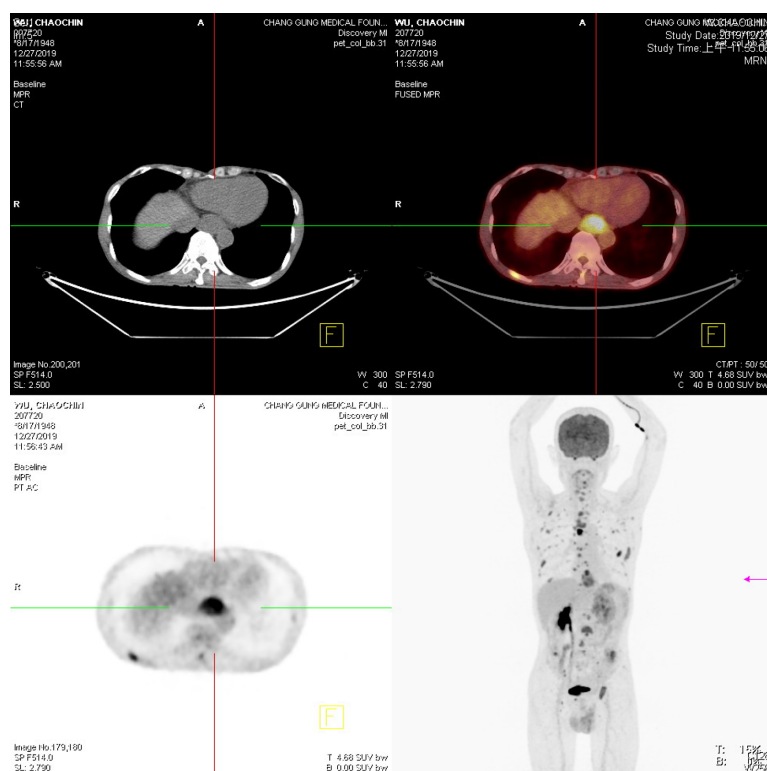

Figure 5 Tumor scan. Whole-body tumor scan from the skull vertex to upper thighs was performed at 60 min after injection of ^{18}F -fluorodeoxyglucose. Purple arrow indicates gastric stump recurrence. Multiple faint nodules were observed in the pelvic cavity, suggesting peritoneal dissemination, as well as the cause of ureteral stenosis.

urogenital lymph vessel trunks and the inguinal region^[6,7].

Krukenberg tumors in men

Metastatic dissemination of gastric signet-ring cell carcinoma to the ovaries is referred to as Krukenberg tumor. The counterpart in male organs derived from the sex cord is an exceedingly rare observation. Excluding lymphomas and leukemias, metastasis constitutes only 0.9% of all testicular tumors, and one of the possible dissemination pathways is retrograde lymphatic spread along the spermatic cord. In our patient, the histopathology disclosed signet-ring cell carcinoma from primary gastric cancer. The patient's CT body scan revealed metastasis to the celiac lymph nodes, which supports the hypothesis of retrograde lymphatic metastasis. Based on the two points above, the clinical diagnosis of the patient is "male Krukenberg tumor" with distant metastasis to the ipsilateral spermatic cord and epididymis^[8].

The prognosis of a metastatic tumor in the spermatic cord has been typically unfavorable. In a review of metastatic tumors in the spermatic cord, the 2-year survival rate after proven metastasis was 36% in a total of 16 patients with a median follow-up duration of 12 mo^[9]. In our case, the patient passed away 8 mo after tumor recurrence. A review of the patient's history showed that the inguinal mass was noted more than 6 mo earlier. We believe that the delay in diagnosis is the main reason for the patient's inferior survival. The patient also had left hydronephrosis caused by external compression of the ureter. The ureteroscopic examination confirmed the segmental narrowing of the left lower ureter. Hydronephrosis secondary to compression by metastatic adenopathy in patients with Krukenberg tumor is previously reported^[10]. Although it cannot be directly proven, we hypothesized that the cause of left hydronephrosis in our patient could have been retrograde lymphatic metastasis from his primary gastric cancer *via* a pathway like that of metastasis of a Krukenberg tumor. Besides the preexisting inguinal mass, earlier detection of hydronephrosis could have contributed to a more favorable outcome of recurrent gastric cancer, especially in patients with normal tumor markers and hydronephrosis without notable urinary calculi. Although CT might not have detected all occult metastases in our patient, a whole-body tumor scan should be done to monitor tumor recurrence before symptoms such as a palpable mass or hydronephrosis caused by a metastatic tumor are found. To the best of our knowledge, this is the first to report of concomitant ipsilateral male genital distant metastasis with ipsilateral hydronephrosis from primary gastric cancer.

CONCLUSION

In patients with a history of primary cancer, an inguinal mass with an unknown cause of ipsilateral hydronephrosis may be a sign of distant metastasis from a primary tumor, especially one of gastrointestinal origin.

REFERENCES

- 1 **Algaba F**, Santaularia JM, Villavicencio H. Metastatic tumor of the epididymis and spermatic cord. *Eur Urol* 1983; **9**: 56-59 [PMID: [6822245](#) DOI: [10.1159/000474045](#)]
- 2 **Rodríguez D**, Olumi AF. Management of spermatic cord tumors: a rare urologic malignancy. *Ther Adv Urol* 2012; **4**: 325-334 [PMID: [23205059](#) DOI: [10.1177/1756287212447839](#)]
- 3 **Li W**, Ng JM, Wong CC, Ng EKW, Yu J. Molecular alterations of cancer cell and tumour microenvironment in metastatic gastric cancer. *Oncogene* 2018; **37**: 4903-4920 [PMID: [29795331](#) DOI: [10.1038/s41388-018-0341-x](#)]
- 4 **Riihimäki M**, Hemminki A, Sundquist K, Sundquist J, Hemminki K. Metastatic spread in patients with gastric cancer. *Oncotarget* 2016; **7**: 52307-52316 [PMID: [27447571](#) DOI: [10.18632/oncotarget.10740](#)]
- 5 **Kiyokawa T**, Young RH, Scully RE. Krukenberg tumors of the ovary: a clinicopathologic analysis of 120 cases with emphasis on their variable pathologic manifestations. *Am J Surg Pathol* 2006; **30**: 277-299 [PMID: [16538048](#) DOI: [10.1097/01.pas.0000190787.85024.cb](#)]
- 6 **Yamanishi Y**, Koshiyama M, Ohnaka M, Ueda M, Ukita S, Hishikawa K, Nagura M, Kim T, Hirose M, Ozasa H, Shirase T. Pathways of metastases from primary organs to the ovaries. *Obstet Gynecol Int* 2011; **2011**: 612817 [PMID: [21915181](#) DOI: [10.1155/2011/612817](#)]
- 7 **Raja K**, Kaushal G, Anand S, Chandrasekar S, Pottakkat B, Gnanasekaran S. Inguinal mass: an unusual presentation of gastroesophageal junction adenocarcinoma. *Int J of Adv Med and Health Res* 2017; **4** [DOI: [10.4103/IJAMR.IJAMR_54_17](#)]
- 8 **Alois M**, Valentina P, Andreas G. The "Krukenberg" tumor in male. *Arch Esp Urol* 2005; **58**: 971-973 [PMID: [16430050](#) DOI: [10.4321/s0004-06142005000900019](#)]
- 9 **Hirano D**, Ohkawa M, Hasegawa R, Okada N, Ishizuka N, Kusumi Y. Metastatic Tumor of the Spermatic Cord in Adults: A Case Report and Review. *Case Rep Urol* 2015; **2015**: 747261 [PMID: [26770863](#) DOI: [10.1155/2015/747261](#)]
- 10 **Moghazy D**, Al-Hendy O, Al-Hendy A. Krukenberg tumor presenting as back pain and a positive urine pregnancy test: a case report and literature review. *J Ovarian Res* 2014; **7**: 36 [PMID: [24708577](#) DOI: [10.1186/1757-2215-7-36](#)]



Published by **Baishideng Publishing Group Inc**
7041 Koll Center Parkway, Suite 160, Pleasanton, CA 94566, USA

Telephone: +1-925-3991568

E-mail: bpgoffice@wjgnet.com

Help Desk: <https://www.f6publishing.com/helpdesk>

<https://www.wjgnet.com>

