

国内版 国际版

Unexplained Postoperative Pain Due to an Occult Spinal Infection: A



网页 图片 视频 学术 词典 地图

检测到您输入了英文，试试切换到国际版？搜英文结果更丰富更准确 >

195,000 条结果 时间不限

Spinal Infection – Causes, Symptoms and Treatments [翻译此页](#)

< **Classification** Cause Risks Symptoms Prognosis >

Spinal infections can be classified by the anatomical location involved: the vertebral column, intervertebral disc space, the spinal canal and adjacent soft tissues. Infection may be caused by bacteria or fungal organisms, and can occur after surgery. Most postoperative infections occur between three days and three months post surgery. Intervertebral disc space infections involve the space between adjacent vertebrae. Disc space infections can be divided into three subcategories: adult hematogenous (spontan...

[在aans.org上查看更多信息](#)

<https://www.aans.org/Patients/Neurosurgical-Conditions-and-Treatments/Spinal-Infections>

Occult infection in pseudarthrosis revision after spinal ... [翻译此页](#)

Author: Marco D. Burkhard, Ruben Loretz, Ilke... Publish Year: 2020

2020-10-17 · **Occult** low-grade **infection** in **spinal** revision surgery has been reported [6, , , , , 17, 18]. Hu et al. found positive cultures indicating subclinical **infection** in 15 of 162 revision spine surgery cases (9.3%). Shifflet et al. and Steinhaus et al. , , evaluated 595 cases of **spinal** revision for various indications. Tissue samples were obtained ...

<https://www.sciencedirect.com/science/article/pii/S1529943020311724>

Dura sac compression due to spinal epidural gas ... [翻译此页](#)

Gas pseudocyst in the **spinal** canal is rare, especially after lumbar surgery and causing **spinal** cord compression. CT and MRI can be used to detect the **spinal** gas. Once gas pseudocyst causes dura sac compression, proper methods should be chosen to treat this kind of intraspinal gas pseudocyst.

Cefazolin-related fever in postoperative spine surgery: a ...<https://pubmed.ncbi.nlm.nih.gov/25365908>

The present report is a case of postoperative immediate-onset cefazolin-related fever in a lumbar spine surgery patient. Case report: A 58-year-old woman presented with progressive low back pain and neurogenic claudication of both extremities for six months. Magnetic resonance images (MRI) of the lumbar spine indicated central canal stenosis with nerve root compression from ...

[PDF] Occult Infections Causing - Spine Surgery Bay Area<https://www.sfspine.com/wp-content/uploads/2015/10/...>

Occult Infections caused by indolent organisms may produce persistent back pain that may be difficult to diagnose. The usual findings considered indicative of **spinal infection** are not reliable in these cases. The authors describe nine patients who presented with **occult infections** of the lumbar spine. Two of the nine had no

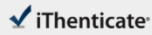
Search Tools

[Turn off Hover Translation \(关闭取词\)](#)

PEOPLE ALSO ASK

Can osteomyelitis cause an epidural abscess? ▾

What are the symptoms of a spinal infection? ▾



59928-Review-check.docx

Quotes Excluded
Bibliography Excluded

2%
SIMILAR

Match Overview

- | | | |
|---|---|----|
| 1 | Crossref 19 words
Joseph Yoon, Johnny Elendy, Michael J. Redmond. "Septi-
arthritis of the lumbar facet joint. Case and literature review". | 1% |
| 2 | Internet 17 words
crawled on 21-Apr-2019
repositorium.sdum.uminho.pt | 1% |

Name of Journal: *World Journal of Clinical Cases*

Manuscript NO: 59928

Manuscript Type: CASE REPORT

Postoperative pain due to an occult spinal infection: A case report

Vande Kerckhove MF *et al.* Occult Spinal Infection

Michiel Frederik Vande Kerckhove, Vincent Fiere, Thais Dutra Vieira, Sami Bahroun,
Marc Szadkowski, Henri d'Astorg

Abstract

BACKGROUND

A high degree of alert for a spinal infection is warranted specially in a patient who

国内版 国际版

Postoperative pain due to an occult spinal infection: A case report



ALL IMAGES VIDEOS

669,000 Results Any time ▾

[PDF] Post-operative Pseudomeningocele after Spine Surgery: ...

irjns.org/article-1-32-en.pdf

post-operative infection, post-operative fibrosis or improper spinal instrumentation and fusion.

Traumatic pseudomeningocele is an uncommon and rarely seen complication following spine surgery, and may be a cause of failed back syndrome in some symptomatic patients. We routinely came across numerous operated patients with

File Size: 587KB Page Count: 4

Case Report: Gas gangrene presenting with back pain

<https://www.ncbi.nlm.nih.gov/pmc/articles/PMC4025197>

The interesting aspects of this case are: first the initial presentation of back pain and second the coexistence of an occult colonic tumour that only presented itself with an aggressive infection. The tumour in this case acted as a portal of entry into the systemic circulation, by providing a small break in the gastrointestinal mucosa and ...

Cited by: 2

Author: Mohamed El Sayad, Albert Chikate, Bala...

Publish Year: 2014

PEOPLE ALSO ASK

Can osteomyelitis cause an epidural abscess? ▾

What are the symptoms of a spinal infection? ▾

What are the symptoms of a paraspinal abscess? ▾

What are the risk factors for spinal infection? ▾

Feedback

Serratia spondylodiscitis after elective lumbar spine ...

<https://pubmed.ncbi.nlm.nih.gov/12461408>

Study design: This report describes two cases of acute spondylodiscitis, caused by, complicating two different conditions: microdiscectomy for herniated nucleus pulposus and decompressing laminotomy for spinal stenosis. Objective: To describe a rare and life-threatening spinal infection and discuss its successful management. Summary of background data: To our knowledge, no published reports in