

World Journal of *Clinical Cases*

World J Clin Cases 2021 April 26; 9(12): 2696-2950



Contents

Thrice Monthly Volume 9 Number 12 April 26, 2021

MINIREVIEWS

- 2696** Standardization of critical care management of non-critically ill patients with COVID-19
Wang CS, Gao Y, Kang K, Fei DS, Meng XL, Liu HT, Luo YP, Yang W, Dai QQ, Gao Y, Zhao MY, Yu KJ
- 2703** Mediastinal lymphadenopathy in COVID-19: A review of literature
Taweasedt PT, Surani S
- 2711** Polycystic ovary syndrome: Pathways and mechanisms for possible increased susceptibility to COVID-19
Ilias I, Goulas S, Zabuliene L

ORIGINAL ARTICLE

Clinical and Translational Research

- 2721** Circulating tumor cells with epithelial-mesenchymal transition markers as potential biomarkers for the diagnosis of lung cancer
Jiang SS, Mao CG, Feng YG, Jiang B, Tao SL, Tan QY, Deng B

Retrospective Study

- 2731** Management and implementation strategies of pre-screening triage in children during coronavirus disease 2019 pandemic in Guangzhou, China
Shi X, Cai YT, Cai X, Wen XL, Wang JY, Ma WC, Shen J, Wu JX, Liu HY, Sun J, He PQ, Lin Y, Zhao DY, Li PQ
- 2739** Clinicopathological features of superficial CD34-positive fibroblastic tumor
Ding L, Xu WJ, Tao XY, Zhang L, Cai ZG
- 2751** Application of a rapid exchange extension catheter technique in type B2/C nonocclusive coronary intervention *via* a transradial approach
Wang HC, Lu W, Gao ZH, Xie YN, Hao J, Liu JM

SYSTEMATIC REVIEWS

- 2763** Paradoxical relationship between proton pump inhibitors and COVID-19: A systematic review and meta-analysis
Zippi M, Fiorino S, Budriesi R, Micucci M, Corazza I, Pica R, de Biase D, Gallo CG, Hong W

META-ANALYSIS

- 2778** Predictive risk factors for recollapse of cemented vertebrae after percutaneous vertebroplasty: A meta-analysis
Ma YH, Tian ZS, Liu HC, Zhang BY, Zhu YH, Meng CY, Liu XJ, Zhu QS

CASE REPORT

- 2791** Malignant pheochromocytoma with cerebral and skull metastasis: A case report and literature review
Chen JC, Zhuang DZ, Luo C, Chen WQ
- 2801** Unresectable esophageal cancer treated with multiple chemotherapies in combination with chemoradiotherapy: A case report
Yura M, Koyanagi K, Hara A, Hayashi K, Tajima Y, Kaneko Y, Fujisaki H, Hirata A, Takano K, Hongo K, Yo K, Yoneyama K, Tamai Y, Dehari R, Nakagawa M
- 2811** Role of positron emission tomography in primary carcinoma ex pleomorphic adenoma of the bronchus: A case report
Yang CH, Liu NT, Huang TW
- 2816** Positive reverse transcription-polymerase chain reaction assay results in patients recovered from COVID-19: Report of two cases
Huang KX, He C, Yang YL, Huang D, Jiang ZX, Li BG, Liu H
- 2823** Laryngeal myxoma: A case report
Yu TT, Yu H, Cui Y, Liu W, Cui XY, Wang X
- 2830** Prostate stromal tumor with prostatic cysts after transurethral resection of the prostate: A case report
Zhao LW, Sun J, Wang YY, Hua RM, Tai SC, Wang K, Fan Y
- 2838** Intramuscular hematoma in rhabdomyolysis patients treated with low-molecular-weight heparin: Report of two cases
Yuan SY, Xie KF, Yang J
- 2845** Partial response to Chinese patent medicine Kangliu pill for adult glioblastoma: A case report and review of the literature
Sun G, Zhuang W, Lin QT, Wang LM, Zhen YH, Xi SY, Lin XL
- 2854** Behcet's disease manifesting as esophageal variceal bleeding: A case report
Xie WX, Jiang HT, Shi GQ, Yang LN, Wang H
- 2862** Successful endoscopic surgery for emphysematous pyelonephritis in a non-diabetic patient with autosomal dominant polycystic kidney disease: A case report
Jiang Y, Lo R, Lu ZQ, Cheng XB, Xiong L, Luo BF
- 2868** Robotically assisted removal of pelvic splenosis fifty-six years after splenectomy: A case report
Tognarelli A, Faggioni L, Erba AP, Faviana P, Durante J, Manassero F, Selli C
- 2874** Pulmonary alveolar proteinosis complicated with nocardiosis: A case report and review of the literature
Wu XK, Lin Q
- 2884** Detection of EGFR-SEPT14 fusion in cell-free DNA of a patient with advanced gastric cancer: A case report
Kim B, Kim Y, Park I, Cho JY, Lee KA

- 2890** Timing of convalescent plasma therapy-tips from curing a 100-year-old COVID-19 patient using convalescent plasma treatment: A case report
Liu B, Ren KK, Wang N, Xu XP, Wu J
- 2899** Torsades de pointes episode in a woman with high-grade fever and inflammatory activation: A case report
Qiu H, Li HW, Zhang SH, Zhou XG, Li WP
- 2908** Salivary duct carcinoma of the submandibular gland presenting a diagnostic challenge: A case report
Uchihashi T, Kodama S, Sugauchi A, Hiraoka S, Hirose K, Usami Y, Tanaka S, Kogo M
- 2916** Allogeneic hematopoietic stem cell transplantation in a 3-year-old boy with congenital pyruvate kinase deficiency: A case report
Ma ZY, Yang X
- 2923** Congenital bilateral cryptorchidism in an infant conceived after maternal breast cancer treatment: A case report
Hu WK, Liu J, Liu RX, Liu XW, Yin CH
- 2930** Sclerosing polycystic adenosis of the submandibular gland: Two case reports
Wu L, Wang Y, Hu CY, Huang CM
- 2937** Budd-Chiari syndrome associated with liver cirrhosis: A case report
Ye QB, Huang QF, Luo YC, Wen YL, Chen ZK, Wei AL
- 2944** Separated root tip formation associated with a fractured tubercle of dens evaginatus: A case report
Wu ZF, Lu LJ, Zheng HY, Tu Y, Shi Y, Zhou ZH, Fang LX, Fu BP

ABOUT COVER

Editorial Board Member of *World Journal of Clinical Cases*, Jing Liu, MD, PhD, Chief Doctor, Professor, Department of Neonatology and NICU, Beijing Chaoyang District Maternal and Child Healthcare Hospital, Beijing 100021, China. liujingbj@live.cn

AIMS AND SCOPE

The primary aim of *World Journal of Clinical Cases* (WJCC, *World J Clin Cases*) is to provide scholars and readers from various fields of clinical medicine with a platform to publish high-quality clinical research articles and communicate their research findings online.

WJCC mainly publishes articles reporting research results and findings obtained in the field of clinical medicine and covering a wide range of topics, including case control studies, retrospective cohort studies, retrospective studies, clinical trials studies, observational studies, prospective studies, randomized controlled trials, randomized clinical trials, systematic reviews, meta-analysis, and case reports.

INDEXING/ABSTRACTING

The WJCC is now indexed in Science Citation Index Expanded (also known as SciSearch®), Journal Citation Reports/Science Edition, Scopus, PubMed, and PubMed Central. The 2020 Edition of Journal Citation Reports® cites the 2019 impact factor (IF) for WJCC as 1.013; IF without journal self cites: 0.991; Ranking: 120 among 165 journals in medicine, general and internal; and Quartile category: Q3. The WJCC's CiteScore for 2019 is 0.3 and Scopus CiteScore rank 2019: General Medicine is 394/529.

RESPONSIBLE EDITORS FOR THIS ISSUE

Production Editor: Ji-Hong Lin; Production Department Director: Xiang Li; Editorial Office Director: Jin-Lai Wang.

NAME OF JOURNAL

World Journal of Clinical Cases

ISSN

ISSN 2307-8960 (online)

LAUNCH DATE

April 16, 2013

FREQUENCY

Thrice Monthly

EDITORS-IN-CHIEF

Dennis A Bloomfield, Sandro Vento, Bao-Gan Peng

EDITORIAL BOARD MEMBERS

<https://www.wjgnet.com/2307-8960/editorialboard.htm>

PUBLICATION DATE

April 26, 2021

COPYRIGHT

© 2021 Baishideng Publishing Group Inc

INSTRUCTIONS TO AUTHORS

<https://www.wjgnet.com/bpg/gerinfo/204>

GUIDELINES FOR ETHICS DOCUMENTS

<https://www.wjgnet.com/bpg/GerInfo/287>

GUIDELINES FOR NON-NATIVE SPEAKERS OF ENGLISH

<https://www.wjgnet.com/bpg/gerinfo/240>

PUBLICATION ETHICS

<https://www.wjgnet.com/bpg/GerInfo/288>

PUBLICATION MISCONDUCT

<https://www.wjgnet.com/bpg/gerinfo/208>

ARTICLE PROCESSING CHARGE

<https://www.wjgnet.com/bpg/gerinfo/242>

STEPS FOR SUBMITTING MANUSCRIPTS

<https://www.wjgnet.com/bpg/GerInfo/239>

ONLINE SUBMISSION

<https://www.f6publishing.com>



Prostate stromal tumor with prostatic cysts after transurethral resection of the prostate: A case report

Li-Wei Zhao, Ji Sun, Yu-Yong Wang, Run-Miao Hua, Sheng-Cheng Tai, Kai Wang, Yi Fan

ORCID number: Li-Wei Zhao 0000-0001-2659-3798; Ji Sun 0000-0002-6759-8329; Yu-Yong Wang 0000-0002-8711-3416; Run-Miao Hua 0000-0003-2367-9238; Sheng-Cheng Tai 0000-0004-2861-9764; Kai Wang 0000-0001-8082-9211; Yi Fan 0000-0002-2641-0716.

Author contributions: Zhao LW and Sun J performed the case report and wrote the manuscript; Wang YY, Hua RM and Tai SC reviewed the literature; Wang K and Fan Y were the patient's surgeons, supervised the work and edited the manuscript; All authors issued final approval for the version to be submitted.

Informed consent statement:

Informed written consent was obtained from the patient, patient's son and patient's brother for publication of this report and any accompanying images obtained at the time of the investigations, but not at the time of writing the patient case report.

Conflict-of-interest statement: All authors declare that they have no conflicts of interest to disclose.

CARE Checklist (2016) statement:

The authors have read the CARE Checklist (2016), and the manuscript was prepared and revised according to the CARE Checklist (2016).

Li-Wei Zhao, Department of Urology, School of Medicine, Hangzhou Normal University, Hangzhou 311121, Zhejiang Province, China

Ji Sun, Run-Miao Hua, Sheng-Cheng Tai, Yi Fan, Department of Urology, Affiliated Xiaoshan Hospital, Hangzhou Normal University, Hangzhou 311202, Zhejiang Province, China

Yu-Yong Wang, Kai Wang, Department of Urology, Affiliated Hangzhou First People's Hospital, Zhejiang University School of Medicine, Hangzhou 310006, Zhejiang Province, China

Corresponding author: Kai Wang, PhD, Academic Fellow, Professor, Surgeon, Technical Editor, Department of Urology, Affiliated Hangzhou First People's Hospital, Zhejiang University School of Medicine, No. 261 Huansha Road, Hangzhou 310006, Zhejiang Province, China. kai_wang2015@163.com

Abstract

BACKGROUND

A prostatic stromal tumor is deemed to be a rare oncology condition. Based on the retrospective analysis of clinical data and scientific literature review, a case of prostatic stromal tumor was reported in this article to explore the diagnosis, treatment and prognosis of this rare disease.

CASE SUMMARY

The present case involved an older male patient who was admitted to our department for a medical consultation of dysuria. Serum prostate-specific antigen was 8.30 ng/mL, Ultrasound and magnetic resonance imaging suggested evident enlargement of the prostate and multiple cystic developments internally. Considering that the patient was an elderly male with a poor health status, transurethral resection of the prostate was performed to improve the symptoms of urinary tract obstruction. Furthermore, based on histopathologic examination and immunohistochemical staining, the patient was pathologically diagnosed with prostatic stromal tumor. The patient did not receive any further adjuvant therapy following surgery leading to a clinical recommendation that the patient should be followed up on a long-term basis. However, during the recent follow-up assessment, the patient demonstrated recurrence of lower urinary tract symptoms and gross hematuria.

CONCLUSION

Referring to scientific literature review, we believe that the management of these lesions requires a thorough assessment of the patient. Furthermore, the treatment

Open-Access: This article is an open-access article that was selected by an in-house editor and fully peer-reviewed by external reviewers. It is distributed in accordance with the Creative Commons Attribution NonCommercial (CC BY-NC 4.0) license, which permits others to distribute, remix, adapt, build upon this work non-commercially, and license their derivative works on different terms, provided the original work is properly cited and the use is non-commercial. See: <http://creativecommons.org/licenses/by-nc/4.0/>

Manuscript source: Unsolicited manuscript

Specialty type: Medicine, research and experimental

Country/Territory of origin: China

Peer-review report's scientific quality classification

Grade A (Excellent): 0
Grade B (Very good): 0
Grade C (Good): C
Grade D (Fair): 0
Grade E (Poor): 0

Received: October 14, 2020

Peer-review started: October 14, 2020

First decision: December 21, 2020

Revised: January 18, 2021

Accepted: March 4, 2021

Article in press: March 4, 2021

Published online: April 26, 2021

P-Reviewer: Ahmed M

S-Editor: Zhang L

L-Editor: Filipodia

P-Editor: Liu JH



of prostate stromal tumors should be based on the imaging examination and pathological classification. Active surgical treatment is of great significance to the prognosis of patients, and subsequent surveillance after the treatment is warranted.

Key Words: Treatment; Prostate stromal tumor; Diagnosis; Prognosis; Prostatic cysts; Case report

©The Author(s) 2021. Published by Baishideng Publishing Group Inc. All rights reserved.

Core Tip: The pathological type of this case was very rare. Few medical reports exist, so there is still a lack of high-level evidence to diagnose and treat this type of tumor. We hope to provide evidence for the diagnosis and treatment of prostate stromal tumors in the future.

Citation: Zhao LW, Sun J, Wang YY, Hua RM, Tai SC, Wang K, Fan Y. Prostate stromal tumor with prostatic cysts after transurethral resection of the prostate: A case report. *World J Clin Cases* 2021; 9(12): 2830-2837

URL: <https://www.wjgnet.com/2307-8960/full/v9/i12/2830.htm>

DOI: <https://dx.doi.org/10.12998/wjcc.v9.i12.2830>

INTRODUCTION

Prostate tumors are one of the most prevalent tumors in men, most of which are prostate cancer. However, interstitial prostate cancer accounts for only 1% of such cases^[1]. Prostate stromal tumors (PST) encompass a spectrum of histologic patterns and have unique clinical behavior. In 1998, according to the degree of stromal cellularity and the presence of mitotic figures, necrosis and stromal overgrowth, Gaudin *et al*^[2] first classified prostatic stromal tumors into two subtypes: Prostatic stromal tumors of uncertain malignant potential (STUMP) and prostatic stromal sarcoma (PSS). This classification was adopted by The World Health Organization in 2005^[3] and has been clinically implemented until the present day. Most of the cases reported in the relevant literature were individual case reports lacking systematic and comprehensive research on the clinical characteristics, imaging diagnosis, treatment and prognosis of PST. In this article, the clinical data and imaging findings of a patient with PST were analyzed retrospectively in the context of the literature in an attempt to explore the diagnosis, treatment and prognosis of this rare disease.

CASE PRESENTATION

Chief complaints

An 87-year-old Chinese male was first admitted to our department with a 1-year history of progressive dysuria and urinary retention for 24 h.

History of present illness

One year ago, the patient presented with progressive dysuria, including urination hesitancy, decreased force of urination, straining, and dribbling. Although his urine flow was fine, he complained of frequent urination and nocturia. There were no dysuria and gross hematuria with no interruption of urinary stream. Even though the patient was on finasteride tablets (5 mg po qd × 1) and tamsulosin (0.2 mg po qd × 1) treatment, symptoms did not improve significantly. The patient developed acute urinary retention 24 h prior to admission.

History of past illness

The patient suffered from epilepsy 2 years prior to hospital admission and was currently on compound sodium valproate and valproic acid sustained release tablets (0.5 g po bid × 1) treatment. In addition, he was suffering from a poor health due to

concomitant medical issues including hypertension, mild anemia, chronic obstructive pulmonary disease and hypothyroidism, though no other medications were given to the patient for the noted additional medical conditions.

Personal and family history

He smoked for more than 60 years but quit recently. His family history was ordinary, and there was no history of genetic heritability of cancer. The patient had no prior imaging examination of the urinary tract system.

Physical examination

No tenderness in the bilateral kidneys, ureters or bladder was discerned on examination. Furthermore, no evident abnormality was found in the external genitalia. Digital rectal examination (DRE) revealed normal anal sphincter tension, though with profound hyperplasia of the prostate gland at a level that the entire boundary could not be examined digitally. The prostate surface was smooth, while its internal bulk felt soft and cystic with an absent central fissure and no palpated nodule.

Laboratory examinations

Serum prostate specific antigen (PSA) was 8.30 ng/mL (normal range: 0-4 ng/mL), free PSA was 3.30 ng/mL, with a total PSA/free PSA ratio of 0.398. Urine cell analysis results revealed white cell count of 2-4/high powered field (HPF) (normal range: 0-5/HPF) and red blood cell count of > 50/HPF (normal range: 0-10/HPF). Urine culture for bacteria was negative. There were no obvious abnormalities in routine blood tests, coagulation function, liver and kidney function, blood electrolytes and other blood biochemical tests.

Imaging examinations

Initial chest computed tomography (CT) revealed no evident nodules in either lung field. Subsequent findings from urinary tract area color ultrasound suggested an evident, enlarged prostate sized at approximately 9.29 cm × 10.98 cm × 9.62 cm protruding into the urinary bladder. Multiple cystic, hypoechoic lesions were detected within the prostate gland. No obvious signs of blood flow were identified within the hypoechoic lesions. Prostate hyperplasia with cystic degeneration was considered (Figure 1). Magnetic resonance imaging revealed that the prostate was profoundly enlarged with resultant compression and right-sided deviation of the urinary bladder and rectum. Irregular density shadows could be seen in the prostate gland area. T2 weighted imaging revealed nonhomogeneous and height signals inside with nonhomogeneous enhancement visible (post enhancement). The prostate peripheral zone was unclear with bilateral seminal vesicles atrophied, though with no evidence of lymph node involvement in the pelvic cavity or tumor invasion to surrounding structures (Figure 2). A preliminary diagnosis of benign prostate hyperplasia with prostatic cysts was concluded.

FINAL DIAGNOSIS

The final diagnosis of the presented case was prostate stromal tumor with prostatic cysts.

TREATMENT

Because the patient was 87-years-old and had previous underlying diseases, including epilepsy, hypertension, chronic obstructive pulmonary disease and hypothyroidism together with such a profoundly enlarged prostate, the symptoms of the urinary tract obstruction were deemed as highly serious. Moreover, PSS could not be completely ruled out from diagnosis. Following consultation with family members and the patient, transurethral resection of the prostate was performed leading to the identification of multiple cystic areas filled with clear, serous fluid during surgery. Postoperative pathology revealed a large number of mesenchymal spindle cells within the cyst wall (Figure 3A), and immunohistochemistry highlighted the following: CD34 (++) (Figure 3B), CK34βE12 (+), Ki-67 (approximately 8% +) (Figure 3C), PSA (-), P504S (-) and actin (-). These analytical findings ascertained a diagnosis of prostatic stromal tumor.

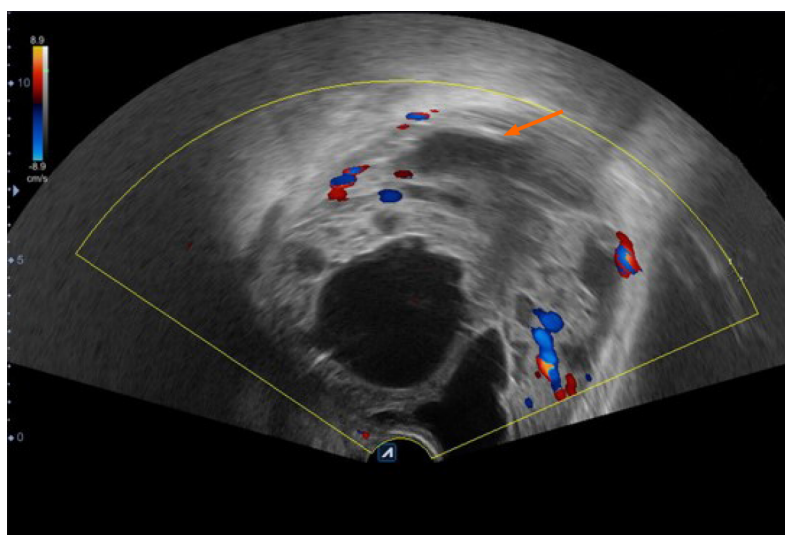


Figure 1 Color-ultrasound of the urinary bladder area suggested an enlarged prostate of approximately 9.29 cm × 10.98 cm × 9.62 cm in size protruding into the urinary bladder. Multiple cystic, hypoechoic lesions were detected in the prostate gland, and no evident signs of blood flow were seen in the hypoechoic lesions (arrowheads). Prostate hyperplasia with cystic degeneration was considered.

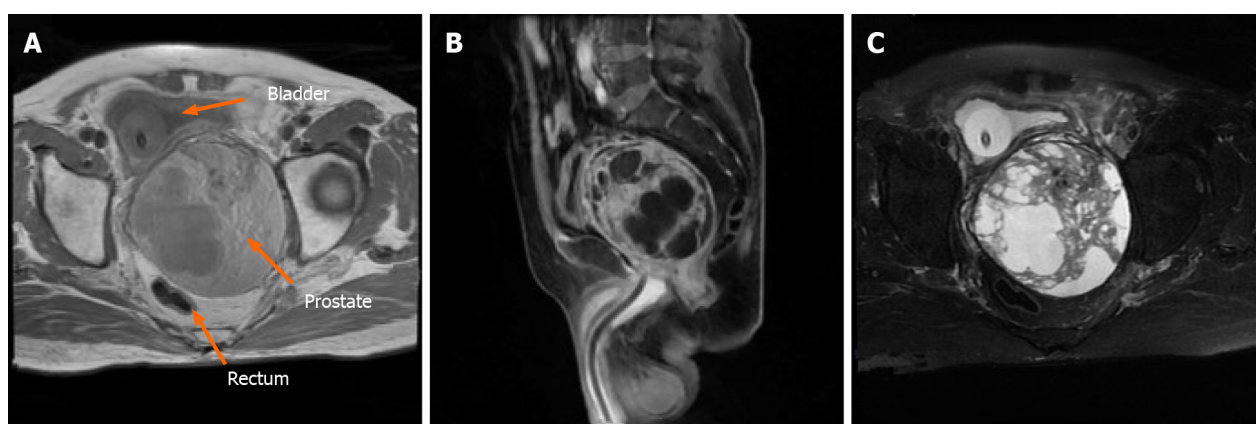


Figure 2 Magnetic resonance imaging revealed that the prostate was evidently enlarged with resultant compression and right-sided deviation of the urinary bladder and rectum (as indicated by arrowheads). Irregular density shadows could be seen in the prostate gland. T2 weighted imaging showed nonhomogeneous and height signals internally. The peripheral zone of the prostate was unclear with bilateral seminal vesicles atrophied and no evidence of lymph node involvement in the pelvic cavity or tumor invasion to the surrounding structures.

OUTCOME AND FOLLOW-UP

Lower urinary tract symptoms of the patient were relieved after the surgery. The International Prostate Symptom Score was reduced, and the postoperative residual urine volume of the bladder was approximately 40 mL. No further adjuvant treatment was administered, and close follow-up was recommended when the patient was discharged from hospital.

Presently, at the time of manuscript submission, the last re-examination of the patient revealed that the patient relapsed with symptoms of urinary frequency, urgency and appeared gross hematuria. A pelvic CT scan of the patient revealed that the prostate was enlarged in size and shaped irregularly. The prostate gland protruded locally into the urinary bladder area with uneven density. In addition, patchy, low-density shadows and punctate calcification could also be seen in the prostate gland, with the boundary between the prostate and bilateral seminal vesicles gland being unclear (Figure 4). We treated the patient with α -receptor blockers to improve the lower urinary tract symptoms. However, the pharmacological effect of these drugs was not satisfactory, and the patient (and his kin) was not willing to undergo the second operation. Consequently, long-term follow-up was still adopted.

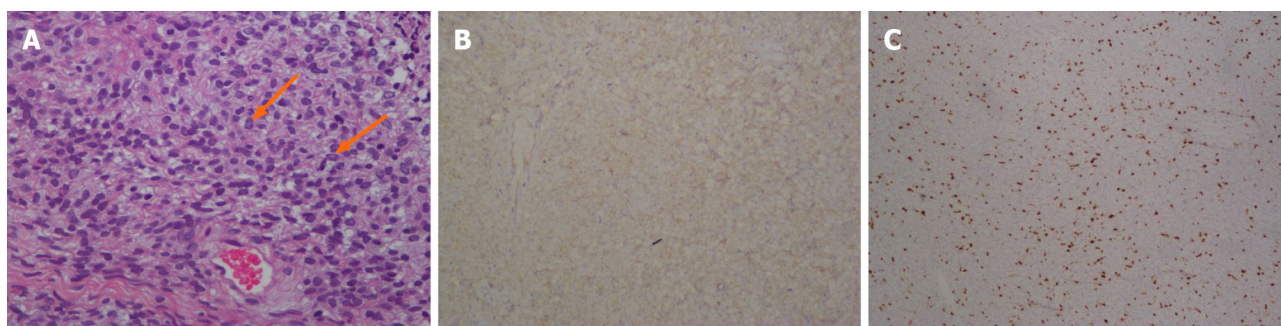


Figure 3 Postoperative histological examination. A: Postoperative histological examination revealed prostatic stromal tumor with considerable, diffused proliferation of heterotypic interstitial cells without any characteristic arrangement. Such tissues consisted of irregular vacuolated spindle cells with abundant eosinophilic cytoplasm and a hyperchromatic nucleus. In addition, the nucleus was slightly enlarged with a few visible nuclear grooves (arrowheads). Tumor cells exhibited mostly round-like and short spindle-like morphology with evident heterotypic and inconspicuous nucleoli. Signs of mitotic activity were relatively abundant and accounted for approximately 7/10 fields in selected active cell growth regions (hematoxylin and eosin stain, 400 × magnification). B: Immunohistochemistry revealed that the tumor cells were diffusely positive for CD34; C: The cells were focally positive for Ki-67 (immunohistochemical stain, 200 × magnification).

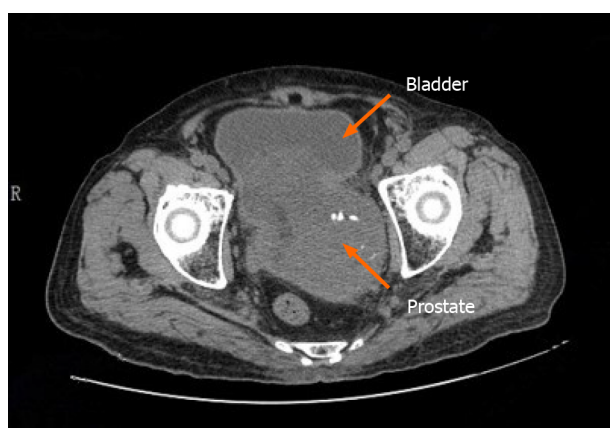


Figure 4 A follow-up pelvic computed tomography revealed that the prostate was enlarged in size with irregular morphology. The prostate gland protruded locally to the bladder with uneven density. Patchy, low-density shadows and punctate calcification can also be seen in the prostate gland with an unclear boundary between the prostate and bilateral seminal vesicles gland.

DISCUSSION

Due to rare cases, the etiology and pathogenesis of PSS is still unknown, and no confirmed risk factors have been identified. The most common clinical manifestations of PST are lower urinary tract symptoms followed by DRE abnormalities, hematuria, changes in defecation habits and acute urinary retention. It is worth noting that PSA, as a specific marker of prostate cancer, lies mostly within normal range or at a slightly elevated level in patients with PST^[4]. A possible reason for this could be that PSA is produced by prostatic epithelial cells, while PSTs have no obvious influence on epithelial cells. The slight increase of PSA levels may also be caused by tissue compression. The onset age of patients with PST is 17-86-years-old, with the median age being 58-years-old, and the peak age of onset being 60-70-years-old^[5-9]. In this case, the patient suffered from lower urinary tract symptoms and acute urinary retention with an onset age being marginally elevated than what was reported in the literature. The PSA level was in the range of 4-10 ng/mL, total PSA/free PSA was normal, and DRE did not identify evident nodules.

Imaging examination plays an important role in early diagnosis, treatment options and relapse detection of the disease^[10]. Transrectal ultrasonography can identify small masses that DRE cannot assert or masses that can easily be missed on diagnosis with a sensitivity of 90%. Pelvic CT can accurately display the size, morphology, extracapsular spread and metastasis of prostate masses, together with providing guidance for treatment recommendations of tumors based on imaging evidence. However, the CT detection rate of early pathological changes is lower than magnetic resonance imaging, where the latter is more accurate in distinguishing tumor boundaries and in identifying suspect masses as adenocarcinoma or otherwise^[11].

Because our reported case was complicated with huge multiple prostatic cysts, patient manifestations present on ultrasound examination and magnetic resonance imaging were not typical.

PSS is a highly malignant PST with high local recurrence and distant metastasis rate, consequently leading to a poor long-term prognosis^[12]. For patients with sarcoma characteristics at first visit, radical prostatectomy should be seriously considered^[6,8]. Presently, it is believed that the presence of sarcoma in tissues is an important factor in the prognosis of PST^[6,13,14]. Surgical resection is the preferred treatment method for PSS. Surgical treatment should focus on optimizing the control of lesions to minimize the risk of positive surgical margin. It is reported that robot-assisted surgery is likely to achieve better surgical results^[15].

STUMP is a unique mesenchymal tumor associated with prostate sarcoma, which can occur simultaneously or subsequently, showing unpredictable biological properties. STUMP is usually difficult to distinguish from benign prostatic hyperplasia in clinical diagnosis. The two conditions overlap in patient age, symptom presentation profiles and epithelial-mesenchymal cross changes in pathology. Epithelial hyperplasia takes an absolute advantage in particular cases so that the diagnosis of STUMP will be concealed and misdiagnosed as benign prostatic hyperplasia^[16]. STUMP tumors are typically recognized as neoplasms even if they do not behave aggressively because it is reported that despite aggressive local resection or radical surgery, 46% of patients with prostatic STUMP will still develop local recurrence with 5% of patients progressing to PSS or suffer from distant metastasis^[6]. Matsuyama *et al*^[17] hypothesized that the diagnosis of STUMP is questionable before radical prostatectomy is performed to obtain complete pathological tissues. Furthermore, because STUMP tumors tend to grow rapidly with a high recurrence rate, it is not suitable to perform resection by transurethral resection, and repeated transurethral resection procedures could possibly transform such tumors from STUMP to PSS. Consequently, the emerging school of thought is that radical prostatectomy is a more effective therapeutic option^[16,18-20].

In essence, in the case of STUMP patient management, the latest concordance in clinical treatment options describes the need to conduct comprehensive evaluations and share decision making for these patients^[21]. The comprehensive evaluation should include the patient's age, palpability of the lesions during DRE with extension of the lesion following tissue sampling and imaging studies in combination with the classification and immunohistochemical results of pathological tissues obtained from prostate biopsy or other surgical procedures. Because published case series are few and far between, there is no corresponding protocol or guideline that can be easily implemented in the management of all STUMP tumors. Stemming from this, management options range from patient observation to radical and extensive surgical resection.

The treatment also requires a thorough evaluation of the body of evidence for malignancy potential, especially regarding undetected sarcomas with subsequent treatment options selected following shared decision-making with the patient. Bidikov *et al*^[21] also suggested that when determining the treatment plan, the size and extent of the lesion, patient age, comorbidities and patient preferences should be considered. In addition, a multidisciplinary recommendation and determination of active surgical treatment for younger patients should be adopted with colleagues from medical oncology and radiation oncology to make joint decisions. However, if STUMP tumors without evidence of sarcoma are confirmed on final surgical pathology, then it is deemed safe to recommend close follow-up without adjuvant therapy, such as monitoring of the lesion with a cystoscope and transrectal ultrasonography following transurethral resection is also an option to attain local control of low-grade tumors^[22].

Although local radiotherapy, chemotherapy and endocrine therapy for PST have been reported, the curative effect is still a matter of debate. The treatment effect is difficult to evaluate and lacks evidence-based medical basis due to the rarity of these tumors.

CONCLUSION

This case was confirmed as PST with prostatic cysts pathologically after the transurethral resection of the prostate. It was associated with tolerable functional outcomes a few months after surgery. Due to the limitations of the patient's poor health status and selection of the patient in this case, transurethral resection of the prostate was the only palliative treatment to improve patient symptoms. The patient

developed recurrence of lower urinary tract symptoms and gross hematuria soon after surgery, for which no further active treatment strategy was implemented. Active surgical treatment is of great significance to patient prognosis. Because only one case was described in this case study, additional PST cases and their close, multidisciplinary clinical management can shed further light onto this rare cancer condition.

REFERENCES

- 1 **Chang YS**, Chuang CK, Ng KF, Liao SK. Prostatic stromal sarcoma in a young adult: a case report. *Arch Androl* 2005; **51**: 419-424 [PMID: [16214726](#) DOI: [10.1080/014850190947822](#)]
- 2 **Gaudin PB**, Rosai J, Epstein JI. Sarcomas and related proliferative lesions of specialized prostatic stroma: a clinicopathologic study of 22 cases. *Am J Surg Pathol* 1998; **22**: 148-162 [PMID: [9500215](#) DOI: [10.1097/00000478-199802000-00002](#)]
- 3 **Chan TY**. World Health Organization classification of tumours: Pathology & genetics of tumours of the urinary system and male genital organs. *Urology* 2005; **65**: 214-215 [DOI: [10.1016/j.urology.2004.09.048](#)]
- 4 **De Berardinis E**, Busetto GM, Antonini G, Giovannone R, Di Placido M, Magliocca FM, Di Silverio A, Gentile V. Incidental prostatic stromal tumor of uncertain malignant potential (STUMP): histopathological and immunohistochemical findings. *Urologia* 2012; **79**: 65-68 [PMID: [22388992](#) DOI: [10.5301/RU.2012.9099](#)]
- 5 **Cavaliere E**, Alaggio R, Castagnetti M, Scarzello G, Bisogno G. Prostatic stromal sarcoma in an adolescent: the role of chemotherapy. *Rare Tumors* 2014; **6**: 5607 [PMID: [25568753](#) DOI: [10.4081/rt.2014.5607](#)]
- 6 **Herawi M**, Epstein JI. Specialized stromal tumors of the prostate: a clinicopathologic study of 50 cases. *Am J Surg Pathol* 2006; **30**: 694-704 [PMID: [16723846](#) DOI: [10.1097/00000478-200606000-00004](#)]
- 7 **Bierhoff E**, Vogel J, Benz M, Giefer T, Wernert N, Pfeifer U. Stromal nodules in benign prostatic hyperplasia. *Eur Urol* 1996; **29**: 345-354 [PMID: [8740022](#) DOI: [10.1159/000473774](#)]
- 8 **Hossain D**, Meiers I, Qian J, MacLennan GT, Bostwick DG. Prostatic stromal hyperplasia with atypia: follow-up study of 18 cases. *Arch Pathol Lab Med* 2008; **132**: 1729-1733 [PMID: [18976007](#)]
- 9 **Osaki M**, Osaki M, Takahashi C, Miyagawa T, Adachi H, Ito H. Prostatic stromal sarcoma: case report and review of the literature. *Pathol Int* 2003; **53**: 407-411 [PMID: [12787317](#) DOI: [10.1046/j.1440-1827.2003.01489.x](#)]
- 10 **Probert JL**, O'Rourke JS, Farrow R, Cox P. Stromal sarcoma of the prostate. *Eur J Surg Oncol* 2000; **26**: 100-101 [PMID: [10718190](#) DOI: [10.1053/ejso.1999.0749](#)]
- 11 **Muglia VF**, Saber G, Maggioni G Jr, Monteiro AJ. MRI findings of prostate stromal tumour of uncertain malignant potential: a case report. *Br J Radiol* 2011; **84**: e194-e196 [PMID: [21933974](#) DOI: [10.1259/bjr/67699443](#)]
- 12 **Sexton WJ**, Lance RE, Reyes AO, Pisters PW, Tu SM, Pisters LL. Adult prostate sarcoma: the M. D. Anderson Cancer Center Experience. *J Urol* 2001; **166**: 521-525 [PMID: [11458058](#) DOI: [10.1016/s0022-5347\(05\)65974-5](#)]
- 13 **Mokhtari M**, Homayoun M, Yazdan Panah S. The Prevalence of Prostatic Stromal Tumor of Uncertain Malignant Potential in Specimens Diagnosed as Prostatic Hyperplasia. *Arch Iran Med* 2016; **19**: 488-490 [PMID: [27362242](#)]
- 14 **Hansel DE**, Herawi M, Montgomery E, Epstein JI. Spindle cell lesions of the adult prostate. *Mod Pathol* 2007; **20**: 148-158 [PMID: [17170745](#) DOI: [10.1038/modpathol.3800676](#)]
- 15 **Mao QQ**, Wang S, Wang P, Qin J, Xia D, Xie LP. Treatment of prostatic stromal sarcoma with robot-assisted laparoscopic radical prostatectomy in a young adult: A case report. *Oncol Lett* 2016; **11**: 2542-2544 [PMID: [27073514](#) DOI: [10.3892/ol.2016.4249](#)]
- 16 **Colombo P**, Ceresoli GL, Boiocchi L, Taverna G, Grizzi F, Bertuzzi A, Santoro A, Roncalli M. Prostatic stromal tumor with fatal outcome in a young man: histopathological and immunohistochemical case presentation. *Rare Tumors* 2010; **2**: e57 [PMID: [21234249](#) DOI: [10.4081/rt.2010.e57](#)]
- 17 **Matsuyama S**, Nohara T, Kawaguchi S, Seto C, Nakanishi Y, Uchiyama A, Ishizawa S. Prostatic Stromal Tumor of Uncertain Malignant Potential Which Was Difficult to Diagnose. *Case Rep Urol* 2015; **2015**: 879584 [PMID: [26839730](#) DOI: [10.1155/2015/879584](#)]
- 18 **Bostwick DG**, Hossain D, Qian J, Neumann RM, Yang P, Young RH, di Sant'agnese PA, Jones EC. Phyllodes tumor of the prostate: long-term followup study of 23 cases. *J Urol* 2004; **172**: 894-899 [PMID: [15310992](#) DOI: [10.1097/01.ju.0000134580.71261.57](#)]
- 19 **Morikawa T**, Goto A, Tomita K, Tsurumaki Y, Ota S, Kitamura T, Fukayama M. Recurrent prostatic stromal sarcoma with massive high-grade prostatic intraepithelial neoplasia. *J Clin Pathol* 2007; **60**: 330-332 [PMID: [17347288](#) DOI: [10.1136/jcp.2006.039032](#)]
- 20 **Musser JE**, Assel M, Mashni JW, Sjoberg DD, Russo P. Adult prostate sarcoma: the Memorial Sloan Kettering experience. *Urology* 2014; **84**: 624-628 [PMID: [25168544](#) DOI: [10.1016/j.urology.2014.05.036](#)]
- 21 **Bidikov L**, Maroni P, Kim S, Crawford ED. 67-year-old Male with Prostatic Stromal Tumor of

- Uncertain Malignant Potential. *Oncology (Williston Park)* 2019; **33** [PMID: 31571179]
- 22 **Bannowsky A**, Probst A, Dunker H, Loch T. Rare and challenging tumor entity: phyllodes tumor of the prostate. *J Oncol* 2009; **2009**: 241270 [PMID: 20069045 DOI: 10.1155/2009/241270]



Published by **Baishideng Publishing Group Inc**
7041 Koll Center Parkway, Suite 160, Pleasanton, CA 94566, USA

Telephone: +1-925-3991568

E-mail: bpgoffice@wjgnet.com

Help Desk: <https://www.f6publishing.com/helpdesk>

<https://www.wjgnet.com>

