

Microsoft Bing

国内版 国际版

FIBULA FRACTURES MANAGEMENT

155 2 3

ALL IMAGES VIDEOS

Select one to refine your search

proximal fibula fractures management distal fibula fractures management

Fibula Fracture: Types, Treatment, Recovery, and More

<https://www.healthline.com/health/fibular-fractures>

Apr 04, 2017 · The general process for healing a fibula fracture is immobilization with a splint or cast for several weeks, after which you might get a walking boot to help you walk. Recovery time depends on ...

Author: Neel Duggal

Tibia Fracture · Bone Fracture Repair

Fibula fracture: Symptoms, treatment, and recovery

<https://www.medicalnewstoday.com/articles/315565>

Feb 02, 2017 · Doctors will treat open fibula fractures immediately and look for any other injuries. Antibiotics will be administered to prevent infection. A tetanus shot will also be given if necessary.

Author: Valencia Higuera

3 Common Types of Fibula Fractures and How to Fix Them

<https://www.verywellhealth.com/fibula-fractures-2549440>

< ucture Types Diagnosis Treatment Risks Prevention >

Chat with Bing

Are humans beings so curiosity?

Say something...

Fibula

Leg Bone

The fibula or calf bone is a leg bone on the lateral side of the tibia, to which it is connected above and below. It is the smaller of the two bones and, in proportion to its length, the slenderest of all the long bones. Its upper extremity is small, placed toward the back of the head of the tibia, below the knee joint and excluded from the formation of this joint. Its lower ...

Wikipedia

People also search for: Tibia · Femur · Ulna · Patella · Humerus · Scapula · Radius · Phalanx bone · Sternum · Metatarsal bones · Calcaneus

Data from: Wikipedia

Wikipedia text under CC-BY-SA license

Suggest an edit

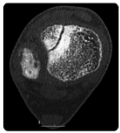
激活 Windows
转到“设置”以激活 Windows。

Select one to refine your search


proximal fibula fractures management

distal fibula fractures management

1. Summary



Fracture type	ED management	Follow-up
Isolated undisplaced distal fibula phys...	Below-knee cast, non-weight bearing	Fracture clinic within 7-10 days with x- ...
Undisplaced distal tibia physcal	No reduction required. Immobilise in abo ...	Fracture clinic within 7 days with x-ray
Displaced distal tibia physcal	Closed reduction with above-knee cast, n ...	If treated with closed reduction, fractu ...
Tillaux and triplane fracture <2 mm disp ...	No reduction. Above-knee cast, non-weigh ...	Fracture clinic within 7 days



Fibula

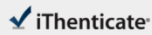Leg Bone

The fibula or calf bone is a leg bone on the lateral side of the tibia, to which it is connected above and below. It is the smaller of the two bones and, in proportion to its length, the slenderest of all the [bones](#). Its upper extremity is small, placed toward the back of the head of the tibia, below the knee joint and excluded from the formation of this joint. Its lower e. [+](#)

W

Wikipedia

People also search for: [Tibia](#) · [Femur](#) · [Ulna](#) · [Patella](#) · [Humerus](#)



60467-Review-check.docx

Quotes Excluded
Bibliography Excluded

4%

Name of Journal: *World Journal of Orthopedics*

Manuscript NO: 60467

Manuscript Type: REVIEW

Fibula fractures management

Canton G *et al.* Fibula fractures management

Gianluca Canton, Andrea Sborgia, Guido Maritan, Roberto Fattori, Federico Roman,
Marko Tomic, Massimo Max Morandi, Luigi Murena

Abstract

Isolated distal fibula fractures represent the majority of ankle fractures. These fractures are often the result of a low-energy trauma with external rotation and supination mechanism. Diagnosis is based on clinical signs and radiographic exam. Stress x-rays have a role in detecting associated mortise instability. Management depends on fracture

Match Overview

- | | | |
|---|--|-----|
| 1 | Dessner 41 words
Erdem Gürkan Bilgili, Mehmet Faruk Çatma, Alper Öz
türk, Serhan Ünüel, Önder Erman. "Comparison of differ... | 1% |
| 2 | Dessner 21 words
Ovid Cothman, Jason T. Bartheau, Nachshon Shazar, Sh
ay A. Tannenbaum. "Lateral malleolus closed reduction an | <1% |
| 3 | Internet 21 words
crawled on 03-Aug-2020
insights.ovid.com | <1% |
| 4 | Dessner 20 words
Sohail Younis, Alan Saleh, Asishik Ahluwalia, Shabnoza
Z. Hafeez, Zaira Hayati, Palaknirany Ramash. "Systematic | <1% |
| 5 | Arenholz 19 words
Arenholz J, Meyer, Erik G, Zachwieja, Charles M, Lassar,
Jonathan R, M. Kaplan. "Management of Isolated Later... | <1% |
| 6 | Dessner 18 words
Vincenzo Giordano, Guilherme Borli, Alexandre Lemre Go
dy-Santos, Robinson Esteves Pires et al. "Nailing the It | <1% |
| 7 | Internet 18 words
crawled on 15-Nov-2020
link.springer.com | <1% |
| 8 | Dessner 16 words
Tha-Ba LeBa, Zsigmond Ougata, Randal P. Morris, Vinod | <1% |

国内版 国际版

Fibula fractures management



ALL

IMAGES

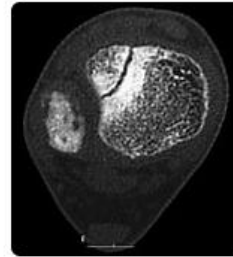
VIDEOS

Select one to refine your search

proximal fibula fractures management

distal fibula fractures management

1. Summary



Fracture type	ED management	Follow-up
Isolated undisplaced distal fibula physeal	Below-knee cast, non-weight bearing	Fracture clinic within 7-10 days with x-ray
Undisplaced distal tibia physeal	No reduction required. Immobilise in above-knee cast, non-weight bearing	Fracture clinic within 7 days with x-ray
Displaced distal tibia physeal	Closed reduction with above-knee cast, non-weight bearing	If treated with closed reduction, fracture clinic within 7 days with x-ray
Tillaux and triplane fracture <2 mm displacement	No reduction. Above-knee cast, non-weight bearing	Fracture clinic within 7 days with x-ray

1 more rows ...

Mar 29 2021

Distal tibia and-or fibula physeal fractures - Emergency ...

www.rch.org.au/clinicalguide/guideline_index/fractures/ankle_emergency/

Was this helpful?

PEOPLE ALSO ASK

What should you do to heal a fibula fracture?

