

# World Journal of *Clinical Cases*

*World J Clin Cases* 2021 July 6; 9(19): 4881-5351



## Contents

Thrice Monthly Volume 9 Number 19 July 6, 2021

## OPINION REVIEW

- 4881** Fear of missing out: A brief overview of origin, theoretical underpinnings and relationship with mental health  
*Gupta M, Sharma A*

## REVIEW

- 4890** Molecular pathways in viral hepatitis-associated liver carcinogenesis: An update  
*Elpek GO*
- 4918** Gastroenterology and liver disease during COVID-19 and in anticipation of post-COVID-19 era: Current practice and future directions  
*Oikonomou KG, Papamichalis P, Zafeiridis T, Xanthoudaki M, Papapostolou E, Valsamaki A, Bouliaris K, Papamichalis M, Karvouniaris M, Vlachostergios PJ, Skoura AL, Komnos A*
- 4939** Enhancing oxygenation of patients with coronavirus disease 2019: Effects on immunity and other health-related conditions  
*Mohamed A, Alawna M*

## MINIREVIEWS

- 4959** Clinical potentials of ginseng polysaccharide for treating gestational diabetes mellitus  
*Zhao XY, Zhang F, Pan W, Yang YF, Jiang XY*
- 4969** Remarkable gastrointestinal and liver manifestations of COVID-19: A clinical and radiologic overview  
*Fang LG, Zhou Q*
- 4980** Liver injury in COVID-19: Known and unknown  
*Zhou F, Xia J, Yuan HX, Sun Y, Zhang Y*
- 4990** COVID-19 and gastroenteric manifestations  
*Chen ZR, Liu J, Liao ZG, Zhou J, Peng HW, Gong F, Hu JF, Zhou Y*
- 4998** Role of epithelial-mesenchymal transition in chemoresistance in pancreatic ductal adenocarcinoma  
*Hu X, Chen W*
- 5007** Insights into the virologic and immunologic features of SARS-COV-2  
*Polat C, Ergunay K*

## ORIGINAL ARTICLE

## Basic Study

- 5019 SMAC exhibits anti-tumor effects in ECA109 cells by regulating expression of inhibitor of apoptosis protein family

Jiang N, Zhang WQ, Dong H, Hao YT, Zhang LM, Shan L, Yang XD, Peng CL

## Case Control Study

- 5028 Efficacy of Solitaire AB stent-release angioplasty in acute middle cerebral artery atherosclerosis obliterative cerebral infarction

Wang XF, Wang M, Li G, Xu XY, Shen W, Liu J, Xiao SS, Zhou JH

## Retrospective Study

- 5037 Diagnostic value of different color ultrasound diagnostic method in endometrial lesions

Lin XL, Zhang DS, Ju ZY, Li XM, Zhang YZ

- 5046 Clinical and pathological features and risk factors for primary breast cancer patients

Lei YY, Bai S, Chen QQ, Luo XJ, Li DM

- 5054 Outcomes of high-grade aneurysmal subarachnoid hemorrhage patients treated with coiling and ventricular intracranial pressure monitoring

Wen LL, Zhou XM, Lv SY, Shao J, Wang HD, Zhang X

- 5064 Microwave ablation combined with hepatectomy for treatment of neuroendocrine tumor liver metastases

Zhang JZ, Li S, Zhu WH, Zhang DF

- 5073 Clinical application of individualized total arterial coronary artery bypass grafting in coronary artery surgery

Chen WG, Wang BC, Jiang YR, Wang YY, Lou Y

## Observational Study

- 5082 Early diagnosis, treatment, and outcomes of five patients with acute thallium poisoning

Wang TT, Wen B, Yu XN, Ji ZG, Sun YY, Li Y, Zhu SL, Cao YL, Wang M, Jian XD, Wang T

- 5092 Sarcopenia in geriatric patients from the plateau region of Qinghai-Tibet: A cross-sectional study

Pan SQ, Li YM, Li XF, Xiong R

- 5102 Medium-term efficacy of arthroscopic debridement vs conservative treatment for knee osteoarthritis of Kellgren-Lawrence grades I-III

Lv B, Huang K, Chen J, Wu ZY, Wang H

## Prospective Study

- 5112 Impact of continuous positive airway pressure therapy for nonalcoholic fatty liver disease in patients with obstructive sleep apnea

Hirono H, Watanabe K, Hasegawa K, Kohno M, Terai S, Ohkoshi S

**Randomized Controlled Trial**

- 5126** Erector spinae plane block at lower thoracic level for analgesia in lumbar spine surgery: A randomized controlled trial  
*Zhang JJ, Zhang TJ, Qu ZY, Qiu Y, Hua Z*

**SYSTEMATIC REVIEWS**

- 5135** Controversies' clarification regarding ribavirin efficacy in measles and coronaviruses: Comprehensive therapeutic approach strictly tailored to COVID-19 disease stages  
*Liatsos GD*
- 5179** Systematic review and meta-analysis of trans-jugular intrahepatic portosystemic shunt for cirrhotic patients with portal vein thrombosis  
*Zhang JB, Chen J, Zhou J, Wang XM, Chen S, Chu JG, Liu P, Ye ZD*

**CASE REPORT**

- 5191** Myelodysplastic syndrome transformed into B-lineage acute lymphoblastic leukemia: A case report  
*Zhu YJ, Ma XY, Hao YL, Guan Y*
- 5197** Imaging presentation and postoperative recurrence of peliosis hepatis: A case report  
*Ren SX, Li PP, Shi HP, Chen JH, Deng ZP, Zhang XE*
- 5203** Delayed retroperitoneal hemorrhage during extracorporeal membrane oxygenation in COVID-19 patients: A case report and literature review  
*Zhang JC, Li T*
- 5211** Autologous tenon capsule packing to treat posterior exit wound of penetrating injury: A case report  
*Yi QY, Wang SS, Gui Q, Chen LS, Li WD*
- 5217** Treatment of leiomyomatosis peritonealis disseminata with goserelin acetate: A case report and review of the literature  
*Yang JW, Hua Y, Xu H, He L, Huo HZ, Zhu CF*
- 5226** Homozygous deletion, c. 1114-1116del, in exon 8 of the *CRPPA* gene causes congenital muscular dystrophy in Chinese family: A case report  
*Yang M, Xing RX*
- 5232** Successful diagnosis and treatment of jejunal diverticular haemorrhage by full-thickness enterotomy: A case report  
*Ma HC, Xiao H, Qu H, Wang ZJ*
- 5238** Liver metastasis as the initial clinical manifestation of sublingual gland adenoid cystic carcinoma: A case report  
*Li XH, Zhang YT, Feng H*
- 5245** Severe hyperbilirubinemia in a neonate with hereditary spherocytosis due to a *de novo* ankyrin mutation: A case report  
*Wang JF, Ma L, Gong XH, Cai C, Sun JJ*

- 5252** Long-term outcome of indwelling colon observed seven years after radical resection for rectosigmoid cancer: A case report  
*Zhuang ZX, Wei MT, Yang XY, Zhang Y, Zhuang W, Wang ZQ*
- 5259** Diffuse xanthoma in early esophageal cancer: A case report  
*Yang XY, Fu KI, Chen YP, Chen ZW, Ding J*
- 5266** COVID-19 or treatment associated immunosuppression may trigger hepatitis B virus reactivation: A case report  
*Wu YF, Yu WJ, Jiang YH, Chen Y, Zhang B, Zhen RB, Zhang JT, Wang YP, Li Q, Xu F, Shi YJ, Li XP*
- 5270** Maintenance treatment with infliximab for ulcerative ileitis after intestinal transplantation: A case report  
*Fujimura T, Yamada Y, Umeyama T, Kudo Y, Kanamori H, Mori T, Shimizu T, Kato M, Kawaida M, Hosoe N, Hasegawa Y, Matsubara K, Shimojima N, Shinoda M, Obara H, Naganuma M, Kitagawa Y, Hoshino K, Kuroda T*
- 5280** Infliximab treatment of glycogenosis Ib with Crohn's-like enterocolitis: A case report  
*Gong YZ, Zhong XM, Zou JZ*
- 5287** Hemichorea due to ipsilateral thalamic infarction: A case report  
*Li ZS, Fang JJ, Xiang XH, Zhao GH*
- 5294** Intestinal gangrene secondary to congenital transmesenteric hernia in a child misdiagnosed with gastrointestinal bleeding: A case report  
*Zheng XX, Wang KP, Xiang CM, Jin C, Zhu PF, Jiang T, Li SH, Lin YZ*
- 5302** Collagen VI-related myopathy with scoliosis alone: A case report and literature review  
*Li JY, Liu SZ, Zheng DF, Zhang YS, Yu M*
- 5313** Neuromuscular electrical stimulation for a dysphagic stroke patient with cardiac pacemaker using magnet mode change: A case report  
*Kim M, Park JK, Lee JY, Kim MJ*
- 5319** Four-year-old anti-N-methyl-D-aspartate receptor encephalitis patient with ovarian teratoma: A case report  
*Xue CY, Dong H, Yang HX, Jiang YW, Yin L*
- 5325** Glutamic acid decarboxylase 65-positive autoimmune encephalitis presenting with gelastic seizure, responsive to steroid: A case report  
*Yang CY, Tsai ST*
- 5332** Ectopic opening of the common bile duct into the duodenal bulb with recurrent choledocholithiasis: A case report  
*Xu H, Li X, Zhu KX, Zhou WC*
- 5339** Small bowel obstruction caused by secondary jejunal tumor from renal cell carcinoma: A case report  
*Bai GC, Mi Y, Song Y, Hao JR, He ZS, Jin J*
- 5345** Brugada syndrome associated with out-of-hospital cardiac arrest: A case report  
*Ni GH, Jiang H, Men L, Wei YY, A D, Ma X*

**ABOUT COVER**

Editorial Board Member of *World Journal of Clinical Cases*, Fan-Bo Meng, MD, PhD, Chief Doctor, Deputy Director, Professor, Department of Cardiology, China-Japan Union Hospital of Jilin University, Changchun 130000, Jilin Province, China. mengfb@jlu.edu.cn

**AIMS AND SCOPE**

The primary aim of *World Journal of Clinical Cases* (WJCC, *World J Clin Cases*) is to provide scholars and readers from various fields of clinical medicine with a platform to publish high-quality clinical research articles and communicate their research findings online.

WJCC mainly publishes articles reporting research results and findings obtained in the field of clinical medicine and covering a wide range of topics, including case control studies, retrospective cohort studies, retrospective studies, clinical trials studies, observational studies, prospective studies, randomized controlled trials, randomized clinical trials, systematic reviews, meta-analysis, and case reports.

**INDEXING/ABSTRACTING**

The WJCC is now indexed in Science Citation Index Expanded (also known as SciSearch®), Journal Citation Reports/Science Edition, Scopus, PubMed, and PubMed Central. The 2020 Edition of Journal Citation Reports® cites the 2019 impact factor (IF) for WJCC as 1.013; IF without journal self cites: 0.991; Ranking: 120 among 165 journals in medicine, general and internal; and Quartile category: Q3. The WJCC's CiteScore for 2019 is 0.3 and Scopus CiteScore rank 2019: General Medicine is 394/529.

**RESPONSIBLE EDITORS FOR THIS ISSUE**

Production Editor: Yan-Xia Xing, Production Department Director: Yun-Xiaoqian Wu, Editorial Office Director: Jin-Lai Wang.

**NAME OF JOURNAL**

*World Journal of Clinical Cases*

**ISSN**

ISSN 2307-8960 (online)

**LAUNCH DATE**

April 16, 2013

**FREQUENCY**

Thrice Monthly

**EDITORS-IN-CHIEF**

Dennis A Bloomfield, Sandro Vento, Bao-Gan Peng

**EDITORIAL BOARD MEMBERS**

<https://www.wjgnet.com/2307-8960/editorialboard.htm>

**PUBLICATION DATE**

July 6, 2021

**COPYRIGHT**

© 2021 Baishideng Publishing Group Inc

**INSTRUCTIONS TO AUTHORS**

<https://www.wjgnet.com/bpg/gerinfo/204>

**GUIDELINES FOR ETHICS DOCUMENTS**

<https://www.wjgnet.com/bpg/GerInfo/287>

**GUIDELINES FOR NON-NATIVE SPEAKERS OF ENGLISH**

<https://www.wjgnet.com/bpg/gerinfo/240>

**PUBLICATION ETHICS**

<https://www.wjgnet.com/bpg/GerInfo/288>

**PUBLICATION MISCONDUCT**

<https://www.wjgnet.com/bpg/gerinfo/208>

**ARTICLE PROCESSING CHARGE**

<https://www.wjgnet.com/bpg/gerinfo/242>

**STEPS FOR SUBMITTING MANUSCRIPTS**

<https://www.wjgnet.com/bpg/GerInfo/239>

**ONLINE SUBMISSION**

<https://www.f6publishing.com>



Retrospective Study

# Diagnostic value of different color ultrasound diagnostic method in endometrial lesions

Xiao-Lin Lin, Dong-Sheng Zhang, Zhi-Ye Ju, Xiu-Ming Li, Yao-Zhu Zhang

**ORCID number:** Xiao-Lin Lin 0000-0002-7311-4821; Dong-Sheng Zhang 0000-0003-4926-742X; Zhi-Ye Ju 0000-0002-8008-3576; Xiu-Ming Li 0000-0003-2966-652X; Yao-Zhu Zhang 0000-0003-2543-4422.

**Author contributions:** Zhang YZ and Lin XL designed this retrospective study; Lin XL and Zhang DS wrote this paper; Lin XL, Zhang DS, Ju ZY and Li XM were responsible for sorting the data.

**Institutional review board statement:** The study was reviewed and approved by the Scientific Research Ethics Committee of Shandong Pingyi County Hospital of Traditional Chinese Medicine Institutional Review Board (approval No. 201803-016).

**Informed consent statement:** All study participants, or their legal guardian, provided informed written consent prior to study enrollment.

**Conflict-of-interest statement:** The authors declare that they have no conflict of interest.

**Data sharing statement:** No additional data are available.

**Open-Access:** This article is an open-access article that was

**Xiao-Lin Lin, Dong-Sheng Zhang,** Department of Ultrasound, Pingyi County Traditional Chinese Medicine Hospital, Linyi 273300, Shandong Province, China

**Zhi-Ye Ju, Yao-Zhu Zhang,** Department of Ultrasound, Rizhao Peoples Hospital, Rizhao 276800, Shandong Province, China

**Xiu-Ming Li,** Department of Gastroenterology, Pingyi County Traditional Chinese Medicine Hospital, Linyi 273300, Shandong Province, China

**Corresponding author:** Yao-Zhu Zhang, MD, Attending Doctor, Department of Ultrasound, Rizhao Peoples Hospital, No. 126 Taian Road, Rizhao 276800, Shandong Province, China. [yaozhu\\_zh2020@126.com](mailto:yaozhu_zh2020@126.com)

## Abstract

### BACKGROUND

Endometrial lesions include endometrial cancer and inferior fibroids. Among them, endometrial cancer as a malignant tumor seriously endangers the life and health of patients. Ultrasonography is an important means of diagnosing female reproductive system diseases, and it is of critical value for the early diagnosis of endometrial cancer. However, different ultrasound inspection programs have achieved different results. It is of great significance to choose a suitable inspection program.

### AIM

To explore the diagnostic efficacy of different ultrasonic examination methods in clinical endometrial lesions.

### METHODS

The 140 patients with endometrial lesions who were treated in our hospital from April 2018 to October 2019 were used as the research subjects. All patients underwent transvaginal color ultrasound and transabdominal color ultrasound. We compared the diagnostic coincidence and image display effects of the two different examination methods, and the endometrial thickness, blood flow, uterine effusion and resistance index of different diseases were observed by transvaginal color ultrasound.

### RESULTS

The diagnostic coincidence rate of all types of diseases of transvaginal color



selected by an in-house editor and fully peer-reviewed by external reviewers. It is distributed in accordance with the Creative Commons Attribution NonCommercial (CC BY-NC 4.0) license, which permits others to distribute, remix, adapt, build upon this work non-commercially, and license their derivative works on different terms, provided the original work is properly cited and the use is non-commercial. See: <http://creativecommons.org/licenses/by-nc/4.0/>

**Manuscript source:** Unsolicited manuscript

**Specialty type:** Medicine, research and experimental

**Country/Territory of origin:** China

**Peer-review report's scientific quality classification**

Grade A (Excellent): 0  
Grade B (Very good): B  
Grade C (Good): C  
Grade D (Fair): 0  
Grade E (Poor): 0

**Received:** December 15, 2020

**Peer-review started:** December 15, 2020

**First decision:** January 17, 2021

**Revised:** January 28, 2021

**Accepted:** March 10, 2021

**Article in press:** March 10, 2021

**Published online:** July 6, 2021

**P-Reviewer:** Hatta W, Park SJ

**S-Editor:** Gao CC

**L-Editor:** Filipodia

**P-Editor:** Li JH



ultrasound was significantly higher than that of transabdominal color ultrasound ( $P = 0.001$ ,  $0.005$ ,  $0.001$  and  $0.001$ ). In addition, the excellent and good rate of image display of transvaginal color ultrasound was higher than that of transabdominal color ultrasound ( $P = 0.001$ ). There were significant differences in endometrial thickness in patients with different types of endometrial lesions through the transvaginal color examination ( $P = 0.001$ ). The incidence rate of uterine effusion in patients with endometrial carcinoma was significantly higher than that in patients with other types of endometrial lesions ( $P = 0.001$ ), and the rate of the blood flow was the highest ( $P = 0.001$ ). The comparison of blood flow resistance index indicated that the blood flow resistance index in endometrial cancer patients was the lowest, which shows that the difference was statistically significant ( $P = 0.001$ ).

## CONCLUSION

The overall diagnostic efficacy of transvaginal color ultrasound in the clinical diagnosis of endometrial lesions is better than that of transabdominal color ultrasound, which held higher diagnostic coincidence rate and image display effect. There were significant differences in the thickness of the endometrium and the blood flow in different types of lesions.

**Key Words:** Endometrial lesions; Transvaginal color ultrasound; Transabdominal color ultrasound; Diagnostic conformity; Blood flow; Resistance index

©The Author(s) 2021. Published by Baishideng Publishing Group Inc. All rights reserved.

**Core Tip:** Ultrasonography is an important means of diagnosing female reproductive system diseases, and it is of critical value for the early diagnosis of endometrial cancer. We explored the diagnostic efficacy of different ultrasonic examination methods in clinical endometrial lesions. The display effect of the patients with clinical endometrial lesions who received transvaginal color ultrasound examination was better than that of patients who received transabdominal color ultrasound, and the diagnostic coincidence rate was higher.

**Citation:** Lin XL, Zhang DS, Ju ZY, Li XM, Zhang YZ. Diagnostic value of different color ultrasound diagnostic method in endometrial lesions. *World J Clin Cases* 2021; 9(19): 5037-5045

**URL:** <https://www.wjgnet.com/2307-8960/full/v9/i19/5037.htm>

**DOI:** <https://dx.doi.org/10.12998/wjcc.v9.i19.5037>

## INTRODUCTION

Endometrial lesions are a common gynecological disease in women that ranges in severity and types, including endometrial carcinoma and uterine submucous myoma. The relative research on endometrial lesions suggests that there is high sensitivity of the endometrium to estrogen and progesterone. Endometrial lesions may occur in women when the endocrine system is chronically disturbed[1].

Epidemiological analysis suggests that endometrial carcinoma is a common malignant tumor in women. Increasing work, stress and changing living habits have led to universalization of endocrine disorders, and the incidence rate of this disease increased significantly[2]. The development of early treatment to detect the endometrial lesions and identify them as benign or malignant is imperative[3].

As one of the commonly used methods of clinical examination, the ultrasound has shown good diagnostic efficacy in many female reproductive system diseases. It has the advantages of being noninvasive, simple and easy to review[4]. However, the selection of different ultrasonic examination schemes in clinical endometrial lesions has an effect on the diagnosis. Two commonly used methods of examination include transvaginal color ultrasound and transabdominal color ultrasound. In order to facilitate the selection of the color ultrasound examination scheme, this paper used comparative study to further clarify the diagnostic efficacy of these two color



ultrasound examination schemes.

## MATERIALS AND METHODS

### Basic information

A total of 140 patients with endometrial lesions treated in our hospital from April 2018 to October 2019 were selected for this research approved by the Ethics Committee. Inclusion criteria: (1) Patients with confirmed endometrial lesions; (2) Patients who were informed of the direction and objective of this study and signed the agreement voluntarily; and (3) Patients with nonemergency procedures. Exclusion criteria: (1) Patients with combined severe infection; (2) Patients with combined liver, heart, lung and other organ lesions; (3) Patients with cognitive impairment or inability to follow up; and (4) Patients with hematologic diseases. These 140 patients, aged between 33 and 78, with an average age of 56.52 ( $\pm 3.87$ ), were collected under the observation of education level, including 18 cases of junior high school, 55 cases of high school, 38 cases of junior college and 29 cases of undergraduate degree and above.

### Methods

The color ultrasound examination was performed 3-7 d after their menstruation with a Voluson E8 color ultrasound diagnostic instrument (GE, United States) with the probe frequency set to 5.0-9.0 MHz.

**Transabdominal color ultrasound examination:** One hour before the examination, the patient was advised to drink water properly until filling her bladder to clearly display her uterus. During the examination, the patient was supine, and the ultrasound probe was placed over the pubic symphysis to complete the multiangle plain scan. Then, the patient was told to change the position, and uterine, pelvic and uterine rectum effusion of the patient were observed.

**Transvaginal color ultrasound examination:** The patient was asked to empty the bladder taking the lithotomy for examination, sterilizing the condom and applying the coupling agent to the ultrasonic probe. The probe was inserted slowly into the vaginal fornix of the patient, and the uterine shape, size and position of the endometrium were observed.

### Observation indicators

The diagnosis conformity situation of various endometrial lesions (endometrial carcinoma, endometrial polyp, submucous myoma, endometrial hyperplasia) between the two groups was compared according to the pathological results of surgery.

The endometrial thickness, intrauterine effusion, blood flow display and blood flow resistance index of patients with different types of transvaginal ultrasound were compared.

The images of excellent and good conditions displayed by the two detection methods were compared and divided into excellent, good and poor. Excellent: clear image; good: relatively blurred image; poor: unable to identify. The image display excellent rate = (the number of excellent examples + the number of good examples)/the total cases  $\times 100\%$ .

### Statistical analysis

All the data in this observation were analyzed by SPSS20.0 statistical software. mean  $\pm$  SD indicated measurement information. The four groups were tested by *F* test and  $\chi^2$  test, with the counting data represented with the rate. *P* < 0.05 was defined as statistically significant.

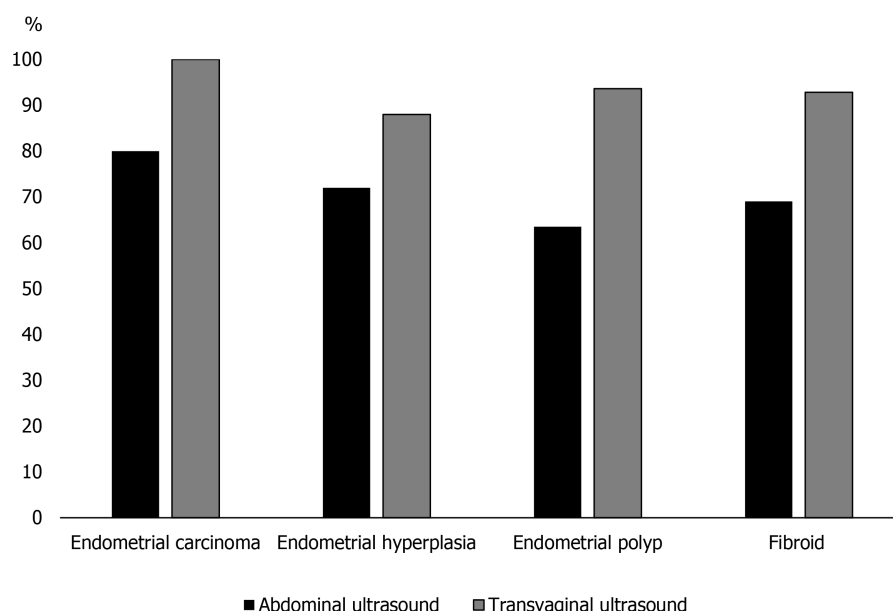
## RESULTS

### Comparison of diagnosis conformity situation of different types of lesions between transvaginal color ultrasound and transabdominal color ultrasound

As can be seen from Table 1 and Figure 1, the diagnostic coincidence rate of the transvaginal color Doppler ultrasound for endometrial carcinoma, endometrial polyp, endometrial hyperplasia and submucosal fibroids of the uterus were significantly higher, and the final surgical examination was taken as the reference standard (*P* =

**Table 1 Comparison of the diagnosis conformity situation between the two examination schemes in different types of lesions**

Type	Cases, <i>n</i>	Transabdominal color ultrasound, <i>n</i> (%)	Transvaginal color ultrasound, <i>n</i> (%)	$\chi^2$	<i>P</i> value
Endometrial carcinoma	10	8 (80.00)	10 (100.00)	22.222	0.001
Endometrial hyperplasia	25	18 (72.00)	22 (88.00)	8.000	0.005
Endometrial polyp	63	40 (63.49)	59 (93.65)	27.012	0.001
Submucous myoma of uterus	42	29 (69.05)	39 (92.86)	18.385	0.001

**Figure 1 Comparison of the diagnostic conformity situation of all kinds of endometrial lesions in the two examination schemes.**

0.001, 0.005, 0.001 and 0.001, respectively).

### **Comparison of image of two inspection methods showing excellent and good conditions**

As can be seen from Table 2, the excellent and good rate of transvaginal color Doppler ultrasound was higher than that of transabdominal color Doppler ultrasound ( $P = 0.001$ ).

### **Comparison of endometrial thickness of different types of patients with transvaginal ultrasound**

As can be seen from Table 3, endometrial thickness of patients with endometrial carcinoma and endometrial hyperplasia was greater than 10 mm, with significant differences in endometrial thickness among different lesion types ( $P = 0.001$ ).

### **Comparison of uterine cavity effusion, blood flow display situation and blood flow resistance index of different types of patients with transvaginal ultrasound**

It can be seen from the data in Table 4 that the incidence rates of the uterine cavity effusion and blood flow display were the highest in endometrial carcinoma through the transvaginal color ultrasound, which indicated that the difference was statistically significant ( $P = 0.0001$  and  $0.001$ , respectively), and the comparison of blood flow resistance index indicated that the blood flow resistance index in endometrial carcinoma patients was the lowest ( $P = 0.001$ ).

### **Display of the results of 2 cases through transvaginal ultrasound**

Figure 2 is a transvaginal color ultrasound image of patients with endometrial carcinoma. There is usually an enhanced/weakened echo region in patients with endometrial carcinoma, whose uterine morphology is irregular, occurring endometrial

**Table 2 Comparison of image display effect of two inspection methods**

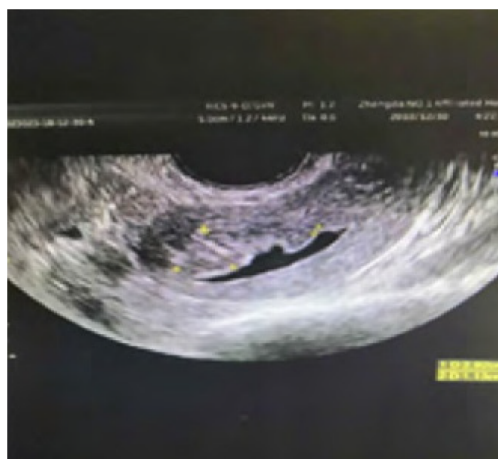
Display effect	Transabdominal color ultrasound, <i>n</i> of 140 (%)	Transvaginal color ultrasound, <i>n</i> of 140 (%)	$\chi^2$	<i>P</i> value
Excellent	79 (56.43)	106 (75.71)	8.291	0.004
Good	22 (15.71)	21 (15.00)	0.019	0.889
Poor	39 (27.86)	13 (9.29)	11.400	0.001
Showing excellent rate	101 (72.14)	127 (90.71)	11.400	0.001

**Table 3 Comparison of endometrial thickness in different lesion types**

Endometrial thickness	Endometrial carcinoma, <i>n</i> of 10 (%)	Endometrial hyperplasia, <i>n</i> of 25 (%)	Endometrial polyp, <i>n</i> of 63 (%)	Submucous myoma of uterus, <i>n</i> of 42 (%)	$\chi^2$	<i>P</i> value
< 5 mm	0 (0.00)	0 (0.00)	12 (19.05)	3 (7.14)	36.214	0.001
5-10 mm	0 (0.00)	0 (0.00)	20 (31.75)	24 (57.14)		
> 10 mm	10 (100.00)	25 (100.00)	31 (49.21)	15 (35.71)		

**Table 4 Comparison of the uterine cavity effusion, blood flow display situation and blood flow resistance index of different types of patients**

Project	Endometrial carcinoma, <i>n</i> of 10 (%)	Endometrial hyperplasia, <i>n</i> of 25 (%)	Endometrial polyp, <i>n</i> of 63 (%)	Submucous myoma of uterus, <i>n</i> of 42 (%)	$\chi^2/F$	<i>P</i> value
Uterine cavity effusion	10 (100.00)	6 (24.00)	10 (15.87)	10 (23.81)	25.631	0.001
Blood flow display situation	10 (100.00)	6 (24.00)	9 (14.29)	9 (21.43)	23.414	0.001
Resistance index	0.34 (0.05)	0.72 (0.11)	0.70 (0.09)	0.53 (0.07)	79.014	0.001

**Figure 2** Image of transvaginal color ultrasound in patients with endometrial carcinoma.

thickening typically, with blurred myometrium boundary and abundant and messy blood flow signals in the lesion. **Figure 3** is the image of a transvaginal color ultrasound in patients with endometrial hyperplasia, with irregular thickening endometrium and uneven echo as well as cystic echo and relatively full uterine in shape.

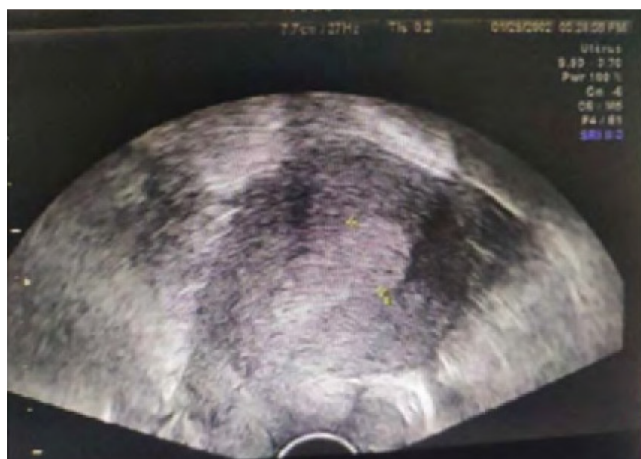


Figure 3 Image of transvaginal color ultrasound in patients with endometrial hyperplasia.

## DISCUSSION

There are many types of endometrial lesions, and they account for 20%-30% of malignant tumors of the female genital tract. It is difficult to distinguish many kinds of lesions directly from clinical symptoms. Thus, the type of lesion needs to be identified by imaging and pathological biopsy[5,6]. If patients can obtain an effective diagnosis in time and have a timely intervention, progression of the disease can be fully avoided, and deterioration of some benign lesions can be prevented. Diagnostic curettage is often used to obtain intrauterine tissue from patients for pathological examination. However, the uterine curettage examination itself is traumatic, has a small focus for some malignant lesions, has a high missed diagnosis rate of no targeted uterine curettage examination and can result in infertility[7,8].

Imaging examination is one of the most commonly used examination methods in the clinic, as it can obtain information on almost all visceral, skeletal and vascular diseases of the human body and has an important reference basis in clinical diagnosis [9,10]. Common imaging methods of endometrial lesions include color ultrasound, computed tomography (CT), X-ray, magnetic resonance imaging (MRI), catheter and angiography, among others. However, there are radiation hazards from X-ray imaging and CT[11]. In contrast to X-ray imaging and CT, MRI has no radiation hazard and high soft tissue resolution. It has high diagnostic efficiency for endometrial lesions [12]. However, MRI is expensive and takes a long time to examine. Therefore, MRI is not applied in the clinical as often as ultrasound, CT, X-ray or color ultrasound.

Color ultrasound is based on the basic principle of different reflected waves when ultrasonic waves travel in different human tissues and encounter different media. By transmitting a special set of ultrasonic waves to the subject, the echo delay time and strength information are obtained. The image information of the tested part is formed by computer system processing[13]. In the diagnosis of endometrial lesions, color ultrasound can clearly show the boundary between the lesion and the surrounding tissue and the situation of hemodynamic changes, which provides a sufficient diagnostic basis for clinical doctors. However, during routine transabdominal color ultrasound examination, the imaging effect is easily disturbed by the frequency of the probe, the depth of the probe, the scope of the patient's focus, the thickness of the fat layer, whether the bladder is filled and other factors that lead to the deterioration of the quality of endometrial imaging, which can result in the occurrence of a missed diagnosis and misdiagnosis[14].

Compared with transabdominal color ultrasound, transvaginal ultrasound is less dependent on bladder filling and is not disturbed by body weight, intestinal gas or other factors. The closer the position of the vaginal fornix probe is to the focus, the better the image display effect will be. Thus, the endometrial thickness can be measured accurately, and the scope, size and nature of the lesion can be located and quantitatively diagnosed[15,16]. Some clinical studies also believe that transvaginal color ultrasound on the basis of two-dimensional ultrasound combined with three-dimensional ultrasound technology can be used to observe the uterine conditions of patients from different angles. Multiple sections and multiple perspectives were used to conduct the observations. This is more helpful to observe the relationship between the lesion and the endometrial wall so that the doctor can judge the depth of lesion

infiltration and to improve the diagnostic accuracy[17-19].

Ultrasound performance varies among patients with different types of lesions when transvaginal color ultrasound is used. In uterine endometrial carcinoma patients, there is usually an enhanced/weakened echo region. Its uterine morphology is irregular, and endometrial thickening typically occurs. The boundary of the myometrium is blurred, and there are abundant and messy blood flow signals in the lesion. In patients with endometrial hyperplasia, the thickening of the endometrium is irregular, and the echo is uneven. There is a cystic echo, and the uterine shape is relatively full. There is no obvious blood flow signal, and the boundary between the endometrium and myometrium is clear. In patients with submucous myoma of the uterus, the performance of the line of the uterine cavity is biased. The boundary between the endometrium and edge is clear and presented as oval or round nodules. The echo is relatively smooth, the blood flow signal in the tumor is punctate, and the periphery is annular. Endometrial polyps are generally round and hyperechoic. The patient's intimal base layer can be seen as a point-like blood flow signal, and the boundary is relatively clear.

The results of this study show that the diagnostic coincidence rate of transvaginal color ultrasound was higher than that of transabdominal color. The overall image shows that the excellent and good rate of transvaginal color Doppler ultrasound is higher than that of transabdominal color ultrasound. There were significant differences in endometrial thickness, uterine effusion, blood flow, resistance index and other parameters in different types of patients undergoing transvaginal ultrasound examination. In the research by Leonardi *et al*[20], the value of transvaginal color ultrasound and transabdominal color ultrasound in the examination of endometrial lesions was compared. The result showed that the diagnostic coincidence rate of transvaginal color ultrasound, the total excellent and good rates of image clarity and the score of image definition were higher than those of transabdominal color ultrasound, which is similar to the findings of this study, and that transvaginal color ultrasound can be confirmed to have higher application value than transabdominal color ultrasound in the diagnosis of endometrial lesions.

## CONCLUSION

In summary, the display effect of the patients with clinical endometrial lesions who receive transvaginal color ultrasound examination is better than that of patients who receive transabdominal color ultrasound, and the diagnostic coincidence rate is higher. Thus, it can be preferred.

## ARTICLE HIGHLIGHTS

### Research background

Endometrial lesions include endometrial cancer and inferior fibroids. Ultrasonography is an important means of diagnosing female reproductive system diseases, and it is of critical value for the early diagnosis of endometrial cancer.

### Research motivation

In clinical application, the choice of different ultrasound examination schemes has a certain impact on the diagnosis of endometrial lesions. In order to facilitate the choice of clinical color ultrasound examination schemes, two commonly used examination methods including vaginal color ultrasound and abdominal color ultrasound were compared.

### Research objectives

To explore the diagnostic effects of different ultrasound examination methods in clinical endometrial lesions and provide guidance for clinical diagnosis in choosing appropriate examination schemes.

### Research methods

All 140 patients underwent transvaginal color ultrasound and transabdominal color ultrasound. We compared the diagnostic coincidence and image display effects of two examination methods, and the endometrial thickness, blood flow, uterine effusion and

resistance index of different diseases were observed by transvaginal color ultrasound.

### Research results

Compared with transabdominal color ultrasound, transvaginal ultrasound is less dependent on bladder filling and is not disturbed by body weight, intestinal gas or other factors. The closer the position of the vaginal fornix probe is to the focus, the better the image display effect will be. Thus, the endometrial thickness can be measured accurately, and the scope, size and nature of the lesion can be located and quantitatively diagnosed.

### Research conclusions

The diagnostic coincidence rate of patients with clinical endometrial lesions examined by transvaginal color ultrasound is relatively high, which is worthy of promotion.

### Research perspectives

This research innovatively compares the diagnostic value of different ultrasound examination schemes for endometrial lesions and provides a more reasonable scheme.

## REFERENCES

- 1 Xu J, Qiao L, Xiong K, Cheng S, Luo H, Wang Y, He J, Chen X, Pan M. Diagnostic Value of Quantitative Analysis by Contrast-Enhanced Ultrasound of Endometrial Lesions. *J Ultrasound Med* 2020 [PMID: 32930398 DOI: 10.1002/jum.15492]
- 2 Méndez Fernández R, Barrera Ortega J. Magnetic resonance imaging of pelvic endometriosis. *Radiologia* 2017; **59**: 286-296 [PMID: 28476282 DOI: 10.1016/j.rx.2017.02.002]
- 3 Gupta A, Bhatnagar A, Seth BN, Dang A, Gupta V. Bladder Endometriosis Mimicking TCC - A Case Report. *J Clin Diagn Res* 2016; **10**: PD12-PD13 [PMID: 27042525 DOI: 10.7860/JCDR/2016/17488.7213]
- 4 Soljačić Vraneš H, Djaković I, Kraljević Z, Nakić Radoš S, Leniček T, Kuna K. Clinical value of transvaginal ultrasonography in comparison to hysteroscopy with histopathologic examination in diagnosing endometrial abnormalities. *Acta Clin Croat* 2019; **58**: 249-254 [PMID: 31819320 DOI: 10.20471/acc.2019.58.02.07]
- 5 Desplats V, Vitte RL, du Cheyron J, Roseau G, Fauconnier A, Moryoussef F. Preoperative rectosigmoid endoscopic ultrasonography predicts the need for bowel resection in endometriosis. *World J Gastroenterol* 2019; **25**: 696-706 [PMID: 30783373 DOI: 10.3748/wjg.v25.i6.696]
- 6 Loh SH, Lew BL, Sim WY. Primary Cutaneous Endometriosis of Umbilicus. *Ann Dermatol* 2017; **29**: 621-625 [PMID: 28966521 DOI: 10.5021/ad.2017.29.5.621]
- 7 Sudderuddin S, Helbren E, Telesca M, Williamson R, Rockall A. MRI appearances of benign uterine disease. *Clin Radiol* 2014; **69**: 1095-1104 [PMID: 25017452 DOI: 10.1016/j.crad.2014.05.108]
- 8 Gerges B, Lu C, Reid S, Chou D, Chang T, Condous G. Sonographic evaluation of immobility of normal and endometriotic ovary in detection of deep endometriosis. *Ultrasound Obstet Gynecol* 2017; **49**: 793-798 [PMID: 27281370 DOI: 10.1002/uog.15990]
- 9 Jafarey YS, Hanley CS, Berlinski RA, Warner C, Armstrong A. Medical management of leiomyomata and suspected endometriosis in an Allen's swamp monkey (*Allenopithecus nigroviridis*). *J Zoo Wildl Med* 2015; **46**: 913-917 [PMID: 26667550 DOI: 10.1638/2014-0224.1]
- 10 Agostinho L, Cruz R, Osório F, Alves J, Setúbal A, Guerra A. MRI for adenomyosis: a pictorial review. *Insights Imaging* 2017; **8**: 549-556 [PMID: 28980163 DOI: 10.1007/s13244-017-0576-z]
- 11 Zhang J, Liu X. Clinicopathological features of endometriosis in abdominal wall--clinical analysis of 151 cases. *Clin Exp Obstet Gynecol* 2016; **43**: 379-383 [PMID: 27328495]
- 12 Zhang Y, Xiao X, Xu F, Lin Q, Xu J, Du B. Evaluation of Uterosacral Ligament Involvement in Deep Endometriosis by Transvaginal Ultrasonography. *Front Pharmacol* 2019; **10**: 374 [PMID: 31031624 DOI: 10.3389/fphar.2019.00374]
- 13 Seo JW, Lee DY, Yoon BK, Choi D. The Efficacy of Postoperative Cyclic Oral Contraceptives after Gonadotropin-Releasing Hormone Agonist Therapy to Prevent Endometrioma Recurrence in Adolescents. *J Pediatr Adolesc Gynecol* 2017; **30**: 223-227 [PMID: 27744096 DOI: 10.1016/j.jpog.2016.10.004]
- 14 Shi H, Chen X, Lv B, Zhang X. Concurrent tamoxifen-related Müllerian adenofibromas in uterus and ovary. *Int J Clin Exp Pathol* 2015; **8**: 15381-15385 [PMID: 26823898]
- 15 DE Oliveira R, Adami F, Mafra FA, Bianco B, Vilarino FL, Barbosa CP. Causes of endometriosis and prevalent infertility in patients undergoing laparoscopy without achieving pregnancy. *Minerva Ginecol* 2016; **68**: 250-258 [PMID: 26126067]
- 16 Green RW, Epstein E. Dynamic contrast-enhanced ultrasound improves diagnostic performance in endometrial cancer staging. *Ultrasound Obstet Gynecol* 2020; **56**: 96-105 [PMID: 31647145 DOI: 10.1002/uog.21885]
- 17 Alborzi S, Rasekhi A, Shomali Z, Madadi G, Alborzi M, Kazemi M, Hosseini Nohandani A. Diagnostic accuracy of magnetic resonance imaging, transvaginal, and transrectal ultrasonography in



- deep infiltrating endometriosis. *Medicine (Baltimore)* 2018; **97**: e9536 [PMID: [29465552](#) DOI: [10.1097/MD.00000000000009536](#)]
- 18 **Novelli AA**, Puppo A, Ceccaroni M, Olearo E, Monterossi G, Mantovani G, Pelligra S, Olearo PL, Fanfani F, Scambia G. Diagnostic accuracy and economic impact of three work-up strategies identifying risk groups in endometrial cancer, fully incorporating sentinel lymph node algorithm. *Facts Views Vis Obgyn* 2020; **12**: 169-177 [PMID: [33123692](#)]
- 19 **Capozzi VA**, Merisio C, Rolla M, Pugliese M, Morganelli G, Cianciolo A, Gambino G, Armano G, Sozzi G, Riccò M, Berretta R. Confounding factors of transvaginal ultrasound accuracy in endometrial cancer. *J Obstet Gynaecol* 2020; 1-6 [PMID: [33063589](#) DOI: [10.1080/01443615.2020.1799342](#)]
- 20 **Leonardi M**, Robledo KP, Espada M, Vanza K, Condous G. SonoPODography: A new diagnostic technique for visualizing superficial endometriosis. *Eur J Obstet Gynecol Reprod Biol* 2020; **254**: 124-131 [PMID: [32961428](#) DOI: [10.1016/j.ejogrb.2020.08.051](#)]



Published by **Baishideng Publishing Group Inc**  
7041 Koll Center Parkway, Suite 160, Pleasanton, CA 94566, USA

**Telephone:** +1-925-3991568

**E-mail:** [bpgoffice@wjgnet.com](mailto:bpgoffice@wjgnet.com)

**Help Desk:** <https://www.f6publishing.com/helpdesk>

<https://www.wjgnet.com>

