

World Journal of *Gastrointestinal Surgery*

World J Gastrointest Surg 2021 January 27; 13(1): 1-95



Contents

Monthly Volume 13 Number 1 January 27, 2021

OPINION REVIEW

- 1 Colonic Crohn's disease – decision is more important than incision: A surgical dilemma
Chiarello MM, Cariatì M, Brisinda G

MINIREVIEWS

- 7 Role of artificial intelligence in hepatobiliary and pancreatic surgery
Bari H, Wadhwani S, Dasari BVM

ORIGINAL ARTICLE

Retrospective Cohort Study

- 19 Laparoscopic hepatectomy reduces postoperative complications and hospital stay in overweight and obese patients
Heise D, Bednarsch J, Kroh A, Schipper S, Eickhoff R, Coolsen M, Van Dam R, Lang S, Neumann U, Ulmer F

Retrospective Study

- 30 Pancreas-preserving duodenal resections *vs* pancreatoduodenectomy for groove pancreatitis. Should we revisit treatment algorithm for groove pancreatitis?
Egorov V, Petrov R, Schegolev A, Dubova E, Vankovich A, Kondratyev E, Dobriakov A, Kalinin D, Schvetz N, Poputichikova E
- 50 Evaluation of prognostic factors and clinicopathological patterns of recurrence after curative surgery for colorectal cancer
Melli F, Bartolini I, Risaliti M, Tucci R, Ringressi MN, Muiasan P, Taddei A, Amedei A

SYSTEMATIC REVIEWS

- 76 Xanthogranulomatous appendicitis: A comprehensive literature review
Akbulut S, Demyati K, Koc C, Tuncer A, Sahin E, Ozcan M, Samdanci E

CASE REPORT

- 87 Multidetector computed tomography three-dimensional and multiplanar reconstruction diagnosis of a rare cause of gastrointestinal bleeding: A case report
Cai Y, Chen XB, Mai DH, Wu P, Chen YH, Chen H

ABOUT COVER

Editorial board member of *World Journal of Gastrointestinal Surgery*, Dr. Raphael LC Araujo is a Professor of Liver Surgery at Federal University of São Paulo (UNIFESP -Brazil). After earning his medical degree from University of the State of Rio de Janeiro (2003), he undertook training in Surgical Oncology at AC Camargo Cancer Center. Afterwards, he spent two years (2010-2012) as Research Fellow in Hepatopancreatobiliary Service at Memorial Sloan-Kettering Cancer Center (New York, United States), working on multimodal approaches for hepatopancreatobiliary malignancies, mainly for colorectal liver metastases and pancreas cancer. Subsequently, he performed residency in Hepatopancreatobiliary Service at Hospital Paul Brousse (France; 2012-2013) and then earned both a PhD (2015) and post-doctorate (2017) degree in Gastroenterology from the University of São Paulo. (L-Editor: Filipodia)

AIMS AND SCOPE

The primary aim of *World Journal of Gastrointestinal Surgery* (WJGS, *World J Gastrointest Surg*) is to provide scholars and readers from various fields of gastrointestinal surgery with a platform to publish high-quality basic and clinical research articles and communicate their research findings online.

WJGS mainly publishes articles reporting research results and findings obtained in the field of gastrointestinal surgery and covering a wide range of topics including biliary tract surgical procedures, biliopancreatic diversion, colectomy, esophagectomy, esophagostomy, pancreas transplantation, and pancreatectomy, etc.

INDEXING/ABSTRACTING

The WJGS is now abstracted and indexed in Science Citation Index Expanded (SCIE, also known as SciSearch®), Current Contents/Clinical Medicine, Journal Citation Reports/Science Edition, PubMed, and PubMed Central. The 2020 edition of Journal Citation Reports® cites the 2019 impact factor (IF) for WJGS as 1.863; IF without journal self cites: 1.824; Ranking: 109 among 210 journals in surgery; Quartile category: Q3; Ranking: 77 among 88 journals in gastroenterology and hepatology; and Quartile category: Q4.

RESPONSIBLE EDITORS FOR THIS ISSUE

Production Editor: Jia-Hui Li; Production Department Director: Xiang Li; Editorial Office Director: Ya-Juan Ma.

NAME OF JOURNAL

World Journal of Gastrointestinal Surgery

ISSN

ISSN 1948-9366 (online)

LAUNCH DATE

November 30, 2009

FREQUENCY

Monthly

EDITORS-IN-CHIEF

Shu-You Peng, Varut Lohsiriwat, Jin Gu

EDITORIAL BOARD MEMBERS

<https://www.wjgnet.com/1948-9366/editorialboard.htm>

PUBLICATION DATE

January 27, 2021

COPYRIGHT

© 2021 Baishideng Publishing Group Inc

INSTRUCTIONS TO AUTHORS

<https://www.wjgnet.com/bpg/gerinfo/204>

GUIDELINES FOR ETHICS DOCUMENTS

<https://www.wjgnet.com/bpg/GerInfo/287>

GUIDELINES FOR NON-NATIVE SPEAKERS OF ENGLISH

<https://www.wjgnet.com/bpg/gerinfo/240>

PUBLICATION ETHICS

<https://www.wjgnet.com/bpg/GerInfo/288>

PUBLICATION MISCONDUCT

<https://www.wjgnet.com/bpg/gerinfo/208>

ARTICLE PROCESSING CHARGE

<https://www.wjgnet.com/bpg/gerinfo/242>

STEPS FOR SUBMITTING MANUSCRIPTS

<https://www.wjgnet.com/bpg/GerInfo/239>

ONLINE SUBMISSION

<https://www.f6publishing.com>



Colonic Crohn's disease – decision is more important than incision: A surgical dilemma

Maria Michela Chiarello, Maria Cariati, Giuseppe Brisinda

ORCID number: Maria Michela Chiarello 0000-0003-3455-0062; Maria Cariati 0000-0002-3278-2567; Giuseppe Brisinda 0000-0001-8820-9471.

Author contributions: Chiarello MM conceived the original idea; Chiarello MM and Cariati M performed a comprehensive review of all available literature, synthesized the data; Chiarello MM and Brisinda G wrote the manuscript; Chiarello MM and Brisinda G contributed to the study design, manuscript structure and performed a final critical appraisal of the manuscript; all authors read and approved the final manuscript.

Conflict-of-interest statement: The authors declare that they have no conflict of interest.

Open-Access: This article is an open-access article that was selected by an in-house editor and fully peer-reviewed by external reviewers. It is distributed in accordance with the Creative Commons Attribution NonCommercial (CC BY-NC 4.0) license, which permits others to distribute, remix, adapt, build upon this work non-commercially, and license their derivative works on different terms, provided the original work is properly cited and the use is non-commercial. See: <http://creativecommons.org/licenses/by-nc/4.0/>

Maria Michela Chiarello, Maria Cariati, Department of Surgery, General Surgery Operative Unit, San Giovanni di Dio Hospital, Crotone 88900, Italy

Giuseppe Brisinda, Department of Medical and Surgical Sciences, Abdominal Surgery Clinical Area, Catholic School of Medicine, Fondazione Policlinico Universitario A Gemelli IRCCS, Rome 00168, Italy

Corresponding author: Giuseppe Brisinda, MD, Assistant Professor, Department of Medical and Surgical Sciences, Abdominal Surgery Clinical Area, Catholic School of Medicine, Fondazione Policlinico Universitario A Gemelli IRCCS, Largo A Gemelli 8, Rome 00168, Italy.

gbrisin@tin.it

Abstract

The most common localization for intestinal Crohn's disease (CD) is the terminal ileum and ileocecal area. It is estimated that patients with CD have one in four chance of undergoing surgery during their life. As surgery in ulcerative colitis ultimately cures the disease, in CD, regardless of the extent of bowel removed, the risk of disease recurrence is as high as 40%. In elective surgery, management of isolated Crohn's colitis continues to evolve. Depending on the type of surgery performed, colonic CD patients often require further medical or surgical therapy to prevent or treat recurrence. The elective surgical treatment of colonic CD is strictly dependent on the localization of disease, and the choice of the procedure is dependent of the extent of colonic involvement and previous resection. The most common surgical options in colonic CD are total proctocolectomy (TPC) with permanent ileostomy, segmental bowel resection, subtotal colectomy. TPC completely removes all colonic and rectal disease and avoids the use of a potentially diseased anus. We will review current options for the elective surgical treatment of colonic CD, based on the current literature and our own personal experience.

Key Words: Crohn's disease; Colonic Crohn's disease; Surgery; Surgical treatment; Colonic resection; Segmental colectomy; Total colectomy

©The Author(s) 2021. Published by Baishideng Publishing Group Inc. All rights reserved.

[p://creativecommons.org/licenses/by-nc/4.0/](https://creativecommons.org/licenses/by-nc/4.0/)

Manuscript source: Invited manuscript

Specialty type: Gastroenterology and hepatology

Country/Territory of origin: Italy

Peer-review report's scientific quality classification

Grade A (Excellent): 0

Grade B (Very good): B

Grade C (Good): 0

Grade D (Fair): 0

Grade E (Poor): 0

Received: November 12, 2020

Peer-review started: November 12, 2020

First decision: November 29, 2020

Revised: December 4, 2020

Accepted: December 11, 2020

Article in press: December 11, 2020

Published online: January 27, 2021

P-Reviewer: Stift A

S-Editor: Chen XF

L-Editor: A

P-Editor: Li JH



Core Tip: The most common localization for intestinal Crohn's disease (CD) is the terminal ileum and ileocecal area. In elective surgery, management of isolated Crohn's colitis continues to evolve. As surgery in ulcerative colitis ultimately cures the disease, in CD, regardless of the extent of bowel removed, the risk of disease recurrence is as high as 40%. Depending on the type of surgery performed, colonic CD patients often require further medical or surgical therapy to prevent or treat recurrence. The elective surgical treatment of colonic CD is strictly dependent on the localization of disease, and the choice of the procedure is dependent of the extent of colonic involvement and previous resection.

Citation: Chiarello MM, Cariati M, Brisinda G. Colonic Crohn's disease – decision is more important than incision: A surgical dilemma. *World J Gastrointest Surg* 2021; 13(1): 1-6

URL: <https://www.wjgnet.com/1948-9366/full/v13/i1/1.htm>

DOI: <https://dx.doi.org/10.4240/wjgs.v13.i1.1>

INTRODUCTION

The most common localization for intestinal Crohn's disease (CD) is the terminal ileum and ileocecal area. CD can involve the entirety of the gastrointestinal tract and can be multifocal^[1]. Incidence of isolated colonic CD varies from 25% to 60% of all comers^[2]. In up to 40% of colonic CD, the rectum is spared from inflammation, a prerequisite for restoration of intestinal continuity in favorable cases, in contrast with ulcerative colitis (UC), where rectal involvement is the norm^[2,3]. On the other hand, severe perianal fistulizing CD is a contraindication to restorative procedures.

COLONIC CROHN'S DISEASE

Colonic CD has clinical and phenotypical features that are different from the more common ileitis (Table 1). Colonic CD without perianal fistulizing involvement is often associated with a less aggressive phenotype and lower indication to surgery than ileal or ileocolonic CD^[4]. Extraintestinal symptoms are statistically more frequent in colonic CD^[5].

It is estimated that patients with CD have one in four chance of undergoing surgery during their life, but as surgery in UC ultimately cures the disease, in CD, regardless of the extent of bowel removed, the risk of disease recurrence is as high as 40%^[6]. Depending on the type of surgery performed, colonic CD patients often require further medical or surgical therapy to prevent or treat recurrence.

Up to 31% of all colonic CD patients will require an end ileostomy in their lifetime. Restoration of intestinal continuity and preservation of adequate function and quality of life are of paramount importance.

The indication for operative management of CD include acute disease complications (*i.e.*, toxic colitis with or without associated megacolon, hemorrhage, and perforation), chronic disease complications, such as neoplasia, growth retardation, and extra-intestinal manifestations, or failed medical therapy^[2]. Failed medical therapy can take several forms including unresponsive disease, incomplete response, medication-related complications, and non-compliance with pharmacological therapies.

The surgical treatment of colonic CD is strictly dependent on the localization of disease, disease phenotype and patient's physiologic characteristics. Timing of surgery is critical to avoid an urgent operation often associated with postoperative complications and a temporary or permanent fecal diversion. The most common post-operative complications, such as leakage, abscess and peritonitis, occur in 13%-17% of all procedures, mostly when carried in emergency setting^[7].

Patients suffering intraabdominal septic complications have statistically significantly higher 1-, 2-, 5-, and 10-year surgical recurrence rates (25%, 29%, 50%, and 57%) than patients without such complications (4%, 7%, 19%, and 38%, $P = 0.0003$)^[8].

Patients undergoing emergency surgery for CD are at high risk for surgical site infections (SSI), due to severe malnutrition, anemia, immunosuppression secondary to medical therapy (especially with steroids) and chronic illness^[7,9]. Previous studies have

Table 1 Features of ileal/ileocolonic Crohn's disease, isolated colonic Crohn's disease, and ulcerative colitis

Characteristics	Ileal and ileocolonic CD	Isolated colonic CD	Ulcerative colitis
Sex	Slight female predominance (55%)	Female predominance (65%)	Equal or slight male predominance
Genetics	Crohn's-associated genotype including NOD2/CARD15	Genotype midway between CD and UC	UC-associated genotype including HLA-DRB1*01:03
Serology	ASCA commonly positive; pANCA usually negative	ASCA less commonly positive than ileal CD; pANCA positive	ASCA usually negative; pANCA commonly positive
Mucosa-associated microbiota	Marked changes commonly including increased proteobacteria (<i>e.g.</i> , <i>E. coli</i>) and fusobacteria	Intermediate changes similar to ileal/ileocolonic CD but less consistent	Modest changes, including slight increase in <i>E. coli</i>
Response to mesalazine	No efficacy	No efficacy	Good efficacy
Response to anti-TNF	Good efficacy	Good efficacy, probably better than for ileal/ileocolonic CD	Good efficacy
Response to exclusive enteral nutrition	Good efficacy	Probably good efficacy	No efficacy
Surgery rate and type	Required in majority	Required in minority. High failure for pouch-anal reconstruction	Required in minority. Low failure for pouch-anal reconstruction

CD: Crohn's disease; ASCA: Anti-*Saccharomyces cerevisiae*; HLA: Human leucocyte antigen; pANCA: Perinuclear antineutrophil cytoplasmic antibodies; TNF: Tumor necrosis factor; UC: Ulcerative colitis.

looked at the efficacy of oral antimicrobial prophylaxis with mechanical preparation during inflammatory bowel disease surgery, with a reduction in SSI of 10% when CD patients are treated with oral and intravenous antimicrobial prophylaxis^[9]. However, surgery for Crohn is often complicated by the presence active intraabdominal infection and strictures precluding effective bowel preparation. This results in a higher risk of SSI in CD patients when compared to other elective colorectal operations^[10].

In severe fulminant isolated CD or indeterminate colitis the surgical approach of choice is a subtotal colectomy (SC) with end ileostomy. The procedure can often be performed laparoscopically and it is usually well tolerated if properly timed. Moreover, it leaves a chance to restore the sphincter function.

In elective surgery, management of isolated Crohn's colitis continues to evolve^[11-13]. In this article, we will review current options for the elective surgical treatment of colonic CD, based on the current literature and our own personal experience.

Accurate preoperative assessment of the disease and patient's characteristics are mandatory, especially in terms of location and natural history of the disease, previous resections, current therapy and general medical conditions. Since preoperative anemia, such as hemoglobin level of < 10 g/dL, is associated with an increased postoperative anastomotic leakage rate, an adequate treatment of anemia is mandatory before surgery. Nutrition and drug therapy optimization are advised in the elective setting^[7]. In presence of abscess or signs of sepsis, surgery should be postponed after percutaneous or laparoscopic drainage and antibiotic treatment. Parenteral nutrition is also advised and liberally used in these patients.

The elective surgical treatment of colonic CD is strictly dependent on the localization of disease, and the choice of the procedure is dependent of the extent of colonic involvement and previous resection (Figure 1). The most common surgical options in colonic CD are total proctocolectomy (TPC) with permanent ileostomy, segmental bowel resection (SBR), SC. TPC completely removes all colonic and rectal disease and avoids the use of a potentially diseased anus.

Perianal manifestations are linked to increased progression to complicated colonic CD.

The fecal stream plays an important role on the genesis of CD. Fistulizing disease in CD has a poor outcome if not properly treated. The fistulas can be treated through traditional surgery as seton drainage and long-term antibiotics, but exclusion of anal function, even temporary, can help in refractory perianal CD. Most recently the use of monoclonal antibodies to tumor necrosis factor alfa has been described to enhance healing of fistula, including perianal, in CD and allow to make a safe anastomosis in 80% of patient primarily treated with resection and terminal ileostomy, while allowing the healing of perianal disease when administered preoperatively in a number of patients.

In spite of new therapies, severe rectal and perianal involvement remains a contraindication to primary anastomosis, due to a high incidence (50%) of

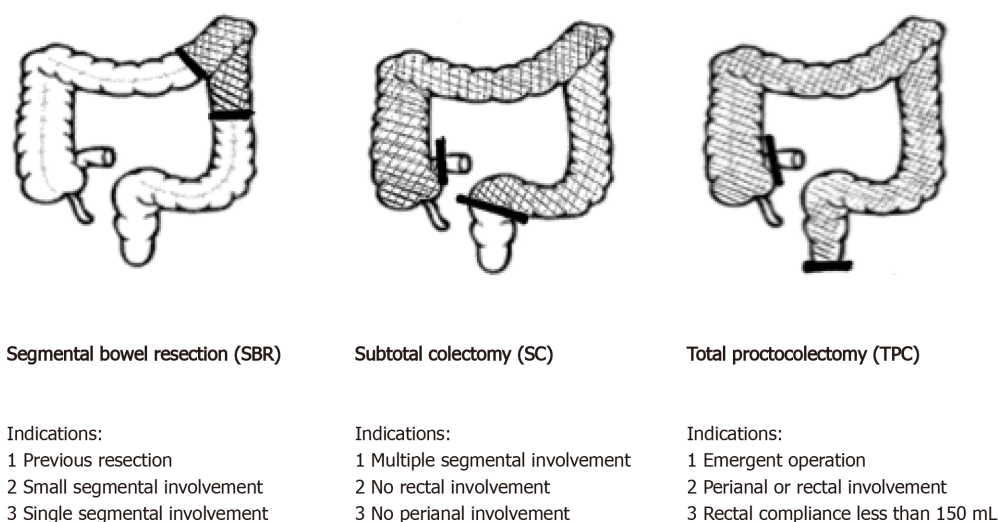


Figure 1 Surgical procedures and indications in isolated colonic Crohn's disease.

complications, such as leakage and refractory complex rectal fistula. Consequently, in the presence of perianal or rectal disease and colitis, TPC should be preferred.

Patients with proctocolitis that warrant operative treatment usually require a TPC with creation of a permanent ileostomy, especially those persons with colitis whose proctitis, anorectal sphincter dysfunction, or anoperineal sepsis is too severe for rectal preservation. In patients with CD recurrence in the small bowel after TPC is the lowest of all surgical options (around 30%).

TPC with permanent stoma is the safest option to avoid further operations in high-risk patients. On the other hand, TPC carries significant risks of perineal wound and stoma complications^[6] and many patients prefer to avoid a permanent stoma. This has led to the adoption of sphincter preserving surgical strategies including segmental colectomy for limited disease and SC with anastomosis when the rectum is healthy.

SBR for CD colitis may offer improved function and a lower risk of a permanent stoma in the short term, but in the long-term recurrence rates as high as 50% (from 32% to 62% in different series)^[6,13-19] can affect the anastomosis and other sites in the colon (Table 2). This technique showed an increased risk of postoperative complications^[6]. Time to recurrence is faster following SBR compared to other surgical procedures; these patients require immunosuppressive medications and develop drug refractory distal disease.

However, segmental colectomy allows a good colonic function and a perceived postoperative quality of life that is the highest of the three procedures.

Indication to SBR are a single colonic CD localization (< 20 cm of macroscopic involvement)^[20].

Patients with extensive colonic involvement, or multiple segmental involvement, relative rectal sparing, and adequate ano-rectal continence are candidates to SC and ileo-rectal anastomosis. The recurrence rate for this approach varies from 41% to 74% in different series^[6,14]. Both SC and SBR are equally effective treatment options for colonic CD with limited colonic involvement. Segmental colectomy is associated with earlier recurrences than subtotal/total procedure.

It should be emphasized that a recurrence can be treated medically and can take place years after the index surgery. Therefore, segmental or SC with ileorectal anastomosis allow a reasonable quality of life in young patients for a number of years, delaying the need for permanent fecal diversion.

Despite the increasing experience with laparoscopy in CD, one-fifth of selected cases still need conversion^[12,21,22]. Several conditions, such as recurrent CD with dense adhesions, abdominopelvic sepsis, fistulizing CD, inflammatory mass, are at risk of a laparotomy, and when the severity of these condition is preoperatively known, a primary open approach should be considered. As far as laparoscopic techniques in colonic CD, even in high volume centers for Crohn surgery the conversion rates are higher than 25%^[23]. Laparoscopy is the gold standard for ileocecal resection in CD^[12], and several studies have demonstrated the superiority of laparoscopy over laparotomy in this setting, but the learning curve of colonic CD is steeper^[24].

Table 2 Recurrence after segmental bowel resection and after total colectomy in patients with isolated colonic Crohn's disease

Ref.	Patient/type of surgery	Recurrence rate (%)
Longo <i>et al</i> ^[16] , 1988	18 segmental bowel resection	62
	131 total colectomy	65
Allan <i>et al</i> ^[15] , 1989	36 segmental bowel resection	66
	63 total colectomy	53
Bernell <i>et al</i> ^[18] , 2001	134 segmental bowel resection	49
	106 total colectomy	53
Andersson <i>et al</i> ^[19] , 2002	31 segmental bowel resection	39
	26 total colectomy	46
Martel <i>et al</i> ^[17] , 2002	84 segmental bowel resection	43
	39 total colectomy	41
Fichera <i>et al</i> ^[13] , 2005	55 segmental bowel resection	38.8
	49 total colectomy	22.9
	75 total proctocolectomy	9.3

CONCLUSION

In conclusion the surgeon must remember that CD cannot be cured with surgery only. Instead, surgery is used in conjunction with maximal medical therapy to treat symptoms of the disease and improve the patient's quality of life. Surgical interventions should be limited in scope.

The management of isolated CD colitis continues to evolve. A surgical approach appears mandatory when the disease is no longer responsive to medical therapies, or when the complications of medical therapies become debilitating. Preoperative treatment with antibiotics, nutritional support, percutaneous drains, optimization of the medical treatment should be considered before colonic resection with a planned anastomosis. In CD colitis, a planned surgery avoids an emergency operation and the need for ileostomy. SBR were associated with the increased likelihood of developing postoperative SSI as opposed to extended colectomies. Segmental resections were performed mostly for strictures or fistulae/abscesses in the descending or sigmoid colon, and, in addition, more of these procedures were safely completed by an anastomosis. Extended colectomies were performed for non-stricturing/non-penetrating disease and were more often completed by stoma formation.

Elective surgery is strictly dependent on the localization of the disease. The choice of procedure is dependent of the extent of colonic involvement and previous resection of the small bowel. The presence and extent of proctitis should be taken into account especially when planning left-sided resections.

Isolated colonic CD patients tend to have better outcomes if treated in high-volume centers, and in the absence of local expertise, patients requiring elective surgery should be referred to a specialist unit.

REFERENCES

- Justiniano CF, Aquina CT, Becerra AZ, Xu Z, Boodry CI, Swanger AA, Monson JRT, Fleming FJ. Postoperative Mortality After Nonelective Surgery for Inflammatory Bowel Disease Patients in the Era of Biologics. *Ann Surg* 2019; **269**: 686-691 [PMID: [29232213](#) DOI: [10.1097/SLA.0000000000002628](#)]
- Tonelli F, Paroli GM. [Colorectal Crohn's disease: indications to surgical treatment]. *Ann Ital Chir* 2003; **74**: 665-672 [PMID: [15206808](#)]
- Scaringi S, Di Martino C, Zambonin D, Fazi M, Canonico G, Leo F, Ficari F, Tonelli F. Colorectal cancer and Crohn's colitis: clinical implications from 313 surgical patients. *World J Surg* 2013; **37**: 902-910 [PMID: [23381673](#) DOI: [10.1007/s00268-013-1922-z](#)]
- Arora U, Kedia S, Garg P, Bopanna S, Jain S, Yadav DP, Goyal S, Gupta V, Sahni P, Pal S, Dash NR, Madhusudhan KS, Sharma R, Makharia G, Ahuja V. Colonic Crohn's Disease Is Associated with Less Aggressive Disease Course Than Ileal or Ileocolonic Disease. *Dig Dis Sci* 2018; **63**: 1592-1599

- [PMID: 29611078 DOI: 10.1007/s10620-018-5041-4]
- 5 **Toshniwal J**, Chawhani R, Thawrani A, Sharma R, Arora A, Kotecha HL, Goyal M, Kirnake V, Jain P, Tyagi P, Bansal N, Sachdeva M, Ranjan P, Kumar M, Sharma P, Singla V, Bansal R, Shah V, Bhalla S, Kumar A. All ileo-cecal ulcers are not Crohn's: Changing perspectives of symptomatic ileocecal ulcers. *World J Gastrointest Endosc* 2017; **9**: 327-333 [PMID: 28744345 DOI: 10.4253/wjge.v9.i7.327]
 - 6 **Angriman I**, Pirozzolo G, Bardini R, Cavallin F, Castoro C, Scarpa M. A systematic review of segmental vs subtotal colectomy and subtotal colectomy vs total proctocolectomy for colonic Crohn's disease. *Colorectal Dis* 2017; **19**: e279-e287 [PMID: 28614620 DOI: 10.1111/codi.13769]
 - 7 **Chiarello MM**, Brisinda G. A commentary on: Preoperative hypoalbuminemia is an independent risk factor for postoperative complications in Crohn's disease patients with normal BMI: A cohort study. *Int J Surg* 2020; **81**: 100-101 [PMID: 32768447 DOI: 10.1016/j.ijsu.2020.07.020]
 - 8 **Iesalnieks I**, Spinelli A, Frasson M, Di Candido F, Scheef B, Horesh N, Iborra M, Schlitt HJ, El-Hussuna A. Risk of postoperative morbidity in patients having bowel resection for colonic Crohn's disease. *Tech Coloproctol* 2018; **22**: 947-953 [PMID: 30543038 DOI: 10.1007/s10151-018-1904-0]
 - 9 **Uchino M**, Ikeuchi H, Bando T, Chohno T, Sasaki H, Horio Y, Nakajima K, Takesue Y. Efficacy of Preoperative Oral Antibiotic Prophylaxis for the Prevention of Surgical Site Infections in Patients With Crohn Disease: A Randomized Controlled Trial. *Ann Surg* 2019; **269**: 420-426 [PMID: 29064884 DOI: 10.1097/SLA.0000000000002567]
 - 10 **Cima RR**, Bergquist JR, Hanson KT, Thiels CA, Habermann EB. Outcomes are Local: Patient, Disease, and Procedure-Specific Risk Factors for Colorectal Surgical Site Infections from a Single Institution. *J Gastrointest Surg* 2017; **21**: 1142-1152 [PMID: 28470562 DOI: 10.1007/s11605-017-3430-1]
 - 11 **Kiran RP**, Nisar PJ, Church JM, Fazio VW. The role of primary surgical procedure in maintaining intestinal continuity for patients with Crohn's colitis. *Ann Surg* 2011; **253**: 1130-1135 [PMID: 21394010 DOI: 10.1097/SLA.0b013e318212b1a4]
 - 12 **Mege D**, Michelassi F. Laparoscopy in Crohn Disease: Learning Curve and Current Practice. *Ann Surg* 2020; **271**: 317-324 [PMID: 30080737 DOI: 10.1097/SLA.0000000000002995]
 - 13 **Fichera A**, McCormack R, Rubin MA, Hurst RD, Michelassi F. Long-term outcome of surgically treated Crohn's colitis: a prospective study. *Dis Colon Rectum* 2005; **48**: 963-969 [PMID: 15785882 DOI: 10.1007/s10350-004-0906-3]
 - 14 **Tekkis PP**, Purkayastha S, Lanitis S, Athanasiou T, Heriot AG, Orchard TR, Nicholls RJ, Darzi AW. A comparison of segmental vs subtotal/total colectomy for colonic Crohn's disease: a meta-analysis. *Colorectal Dis* 2006; **8**: 82-90 [PMID: 16412066 DOI: 10.1111/j.1463-1318.2005.00903.x]
 - 15 **Allan A**, Andrews H, Hilton CJ, Keighley MR, Allan RN, Alexander-Williams J. Segmental colonic resection is an appropriate operation for short skip lesions due to Crohn's disease in the colon. *World J Surg* 1989; **13**: 611-616 [PMID: 2815805 DOI: 10.1007/BF01658882]
 - 16 **Longo WE**, Ballantyne GH, Cahow CE. Treatment of Crohn's colitis. Segmental or total colectomy? *Arch Surg* 1988; **123**: 588-590 [PMID: 3358685 DOI: 10.1001/archsurg.1988.01400290070011]
 - 17 **Martel P**, Betton PO, Gallot D, Malafosse M. Crohn's colitis: experience with segmental resections; results in a series of 84 patients. *J Am Coll Surg* 2002; **194**: 448-453 [PMID: 11949750 DOI: 10.1016/s1072-7515(02)01122-5]
 - 18 **Bernell O**, Lapidus A, Hellers G. Recurrence after colectomy in Crohn's colitis. *Dis Colon Rectum* 2001; **44**: 647-654 [PMID: 11357022 DOI: 10.1007/BF02234559]
 - 19 **Andersson P**, Olaison G, Bodemar G, Nyström PO, Sjö Dahl R. Surgery for Crohn colitis over a twenty-eight-year period: fewer stomas and the replacement of total colectomy by segmental resection. *Scand J Gastroenterol* 2002; **37**: 68-73 [PMID: 11843039 DOI: 10.1080/003655202753387383]
 - 20 **Lightner AL**. Segmental Resection versus Total Proctocolectomy for Crohn's Colitis: What is the Best Operation in the Setting of Medically Refractory Disease or Dysplasia? *Inflamm Bowel Dis* 2018; **24**: 532-538 [PMID: 29462390 DOI: 10.1093/ibd/izx064]
 - 21 **Fichera A**. Laparoscopic treatment of Crohn's disease. *World J Surg* 2011; **35**: 1500-1504 [PMID: 21384239 DOI: 10.1007/s00268-011-1031-9]
 - 22 **Fichera A**, Peng SL, Elisseou NM, Rubin MA, Hurst RD. Laparoscopy or conventional open surgery for patients with ileocolonic Crohn's disease? *Surgery* 2007; **142**: 566-571 [PMID: 17950349 DOI: 10.1016/j.surg.2007.08.004]
 - 23 **Galata C**, Kienle P, Weiss C, Seyfried S, Reißfelder C, Hardt J. Risk factors for early postoperative complications in patients with Crohn's disease after colorectal surgery other than ileocecal resection or right hemicolectomy. *Int J Colorectal Dis* 2019; **34**: 293-300 [PMID: 30460473 DOI: 10.1007/s00384-018-3196-2]
 - 24 **Umanskiy K**, Malhotra G, Chase A, Rubin MA, Hurst RD, Fichera A. Laparoscopic colectomy for Crohn's colitis. A large prospective comparative study. *J Gastrointest Surg* 2010; **14**: 658-663 [PMID: 20127200 DOI: 10.1007/s11605-010-1157-3]



Published by **Baishideng Publishing Group Inc**
7041 Koll Center Parkway, Suite 160, Pleasanton, CA 94566, USA

Telephone: +1-925-3991568

E-mail: bpgoffice@wjgnet.com

Help Desk: <https://www.f6publishing.com/helpdesk>

<https://www.wjgnet.com>

