

World Journal of *Clinical Cases*

World J Clin Cases 2021 May 6; 9(13): 2951-3226



Contents

Thrice Monthly Volume 9 Number 13 May 6, 2021

REVIEW

- 2951 Patients with cirrhosis during the COVID-19 pandemic: Current evidence and future perspectives
Su HY, Hsu YC

MINIREVIEWS

- 2969 Immunotherapy for pancreatic cancer
Yoon JH, Jung YJ, Moon SH

ORIGINAL ARTICLE

Retrospective Study

- 2983 Scrotal septal flap and two-stage operation for complex hypospadias: A retrospective study
Chen S, Yang Z, Ma N, Wang WX, Xu LS, Liu QY, Li YQ
- 2994 Clinical diagnosis of severe COVID-19: A derivation and validation of a prediction rule
Tang M, Yu XX, Huang J, Gao JL, Cen FL, Xiao Q, Fu SZ, Yang Y, Xiong B, Pan YJ, Liu YX, Feng YW, Li JX, Liu Y
- 3008 Prognostic value of hemodynamic indices in patients with sepsis after fluid resuscitation
Xu HP, Zhuo XA, Yao JJ, Wu DY, Wang X, He P, Ouyang YH

Observational Study

- 3014 Updated Kimura-Takemoto classification of atrophic gastritis
Kotelevets SM, Chekh SA, Chukov SZ

SYSTEMATIC REVIEWS

- 3024 Systematic review and meta-analysis of the impact of deviations from a clinical pathway on outcomes following pancreatoduodenectomy
Karunakaran M, Jonnada PK, Barreto SG

META-ANALYSIS

- 3038 Early vs late cholecystectomy in mild gall stone pancreatitis: An updated meta-analysis and review of literature
Walayat S, Baig M, Puli SR

CASE REPORT

- 3048 Effects of intravascular laser phototherapy on delayed neurological sequelae after carbon monoxide intoxication as evaluated by brain perfusion imaging: A case report and review of the literature
Liu CC, Hsu CS, He HC, Cheng YY, Chang ST

- 3056** *Crumbs homolog 2* mutation in two siblings with steroid-resistant nephrotic syndrome: Two case reports
Lu J, Guo YN, Dong LQ
- 3063** Intracortical chondroma of the metacarpal bone: A case report
Yoshida Y, Anazawa U, Watanabe I, Hotta H, Aoyama R, Suzuki S, Nagura T
- 3070** Vancomycin-related convulsion in a pediatric patient with neuroblastoma: A case report and review of the literature
Ye QF, Wang GF, Wang YX, Lu GP, Li ZP
- 3079** Pulmonary arterial hyper-tension in a patient with hereditary hemorrhagic telangiectasia and family gene analysis: A case report
Wu J, Yuan Y, Wang X, Shao DY, Liu LG, He J, Li P
- 3090** Misdiagnosed dystrophic epidermolysis bullosa pruriginosa: A case report
Wang Z, Lin Y, Duan XW, Hang HY, Zhang X, Li LL
- 3095** Spontaneous coronary dissection should not be ignored in patients with chest pain in autosomal dominant polycystic kidney disease: A case report
Qian J, Lai Y, Kuang LJ, Chen F, Liu XB
- 3102** Sarcomatoid carcinoma of the pancreas — multimodality imaging findings with serial imaging follow-up: A case report and review of literature
Lim HJ, Kang HS, Lee JE, Min JH, Shin KS, You SK, Kim KH
- 3114** Acute pancreatitis and small bowel obstruction caused by a migratory gastric bezoar after dissolution therapy: A case report
Wang TT, He JJ, Liu J, Chen WW, Chen CW
- 3120** Intracardiac, pulmonary cement embolism in a 67-year-old female after cement-augmented pedicle screw instrumentation: A case report and review of literature
Liang TZ, Zhu HP, Gao B, Peng Y, Gao WJ
- 3130** Acute urinary retention in the first and second-trimester of pregnancy: Three case reports
Zhuang L, Wang XY, Sang Y, Xu J, He XL
- 3140** Sarcoidosis mimicking metastases in an echinoderm microtubule-associated protein-like 4 anaplastic lymphoma kinase positive non-small-lung cancer patient: A case report
Chen X, Wang J, Han WL, Zhao K, Chen Z, Zhou JY, Shen YH
- 3147** Three-dimensional printed talar prosthesis with biological function for giant cell tumor of the talus: A case report and review of the literature
Yang QD, Mu MD, Tao X, Tang KL
- 3157** Successful upgrade to cardiac resynchronization therapy for cardiac implantation-associated left subclavian vein occlusion: A case report
Zhong JY, Zheng XW, Li HD, Jiang LF

- 3163** Sodium-glucose co-transporter-2 inhibitor-associated euglycemic diabetic ketoacidosis that prompted the diagnosis of fulminant type-1 diabetes: A case report
Yasuma T, Okano Y, Tanaka S, Nishihama K, Eguchi K, Inoue C, Maki K, Uchida A, Uemura M, Suzuki T, D'Alessandro-Gabazza CN, Gabazza EC, Yano Y
- 3170** Perioperative massive cerebral stroke in thoracic patients: Report of three cases
Jian MY, Liang F, Liu HY, Han RQ
- 3177** Renal artery embolization in the treatment of urinary fistula after renal duplication: A case report and review of literature
Yang T, Wen J, Xu TT, Cui WJ, Xu J
- 3185** Clinical characteristics of intrahepatic biliary papilloma: A case report
Yi D, Zhao LJ, Ding XB, Wang TW, Liu SY
- 3194** Association between scrub typhus encephalitis and diffusion tensor tractography detection of Papez circuit injury: A case report
Kwon HG, Yang JH, Kwon JH, Yang D
- 3200** Alström syndrome with a novel mutation of *ALMS1* and Graves' hyperthyroidism: A case report and review of the literature
Zhang JJ, Wang JQ, Sun MQ, Xu D, Xiao Y, Lu WL, Dong ZY
- 3212** Laparoscopic uncontained power morcellation-induced dissemination of ovarian endodermal sinus tumors: A case report
Oh HK, Park SN, Kim BR
- 3219** Treatment of acute severe ulcerative colitis using accelerated infliximab regimen based on infliximab trough level: A case report
Garate ALSV, Rocha TB, Almeida LR, Quera R, Barros JR, Baima JP, Saad-Hossne R, Sassaki LY

ABOUT COVER

Editorial Board Member of *World Journal of Clinical Cases*, Rama R Vunnam, MBBS, MD, Assistant Professor, Department of Medicine, Penn State Health Milton S. Hershey Medical Center, Hershey, PA 17033, United States. rvunnam@pennstatehealth.psu.edu

AIMS AND SCOPE

The primary aim of *World Journal of Clinical Cases* (WJCC, *World J Clin Cases*) is to provide scholars and readers from various fields of clinical medicine with a platform to publish high-quality clinical research articles and communicate their research findings online.

WJCC mainly publishes articles reporting research results and findings obtained in the field of clinical medicine and covering a wide range of topics, including case control studies, retrospective cohort studies, retrospective studies, clinical trials studies, observational studies, prospective studies, randomized controlled trials, randomized clinical trials, systematic reviews, meta-analysis, and case reports.

INDEXING/ABSTRACTING

The WJCC is now indexed in Science Citation Index Expanded (also known as SciSearch®), Journal Citation Reports/Science Edition, Scopus, PubMed, and PubMed Central. The 2020 Edition of Journal Citation Reports® cites the 2019 impact factor (IF) for WJCC as 1.013; IF without journal self cites: 0.991; Ranking: 120 among 165 journals in medicine, general and internal; and Quartile category: Q3. The WJCC's CiteScore for 2019 is 0.3 and Scopus CiteScore rank 2019: General Medicine is 394/529.

RESPONSIBLE EDITORS FOR THIS ISSUE

Production Editor: Yan-Xia Xing, Production Department Director: Yun-Xiaoqian Wu, Editorial Office Director: Jin-Lai Wang.

NAME OF JOURNAL

World Journal of Clinical Cases

ISSN

ISSN 2307-8960 (online)

LAUNCH DATE

April 16, 2013

FREQUENCY

Thrice Monthly

EDITORS-IN-CHIEF

Dennis A Bloomfield, Sandro Vento, Bao-Gan Peng

EDITORIAL BOARD MEMBERS

<https://www.wjgnet.com/2307-8960/editorialboard.htm>

PUBLICATION DATE

May 6, 2021

COPYRIGHT

© 2021 Baishideng Publishing Group Inc

INSTRUCTIONS TO AUTHORS

<https://www.wjgnet.com/bpg/gerinfo/204>

GUIDELINES FOR ETHICS DOCUMENTS

<https://www.wjgnet.com/bpg/GerInfo/287>

GUIDELINES FOR NON-NATIVE SPEAKERS OF ENGLISH

<https://www.wjgnet.com/bpg/gerinfo/240>

PUBLICATION ETHICS

<https://www.wjgnet.com/bpg/GerInfo/288>

PUBLICATION MISCONDUCT

<https://www.wjgnet.com/bpg/gerinfo/208>

ARTICLE PROCESSING CHARGE

<https://www.wjgnet.com/bpg/gerinfo/242>

STEPS FOR SUBMITTING MANUSCRIPTS

<https://www.wjgnet.com/bpg/GerInfo/239>

ONLINE SUBMISSION

<https://www.f6publishing.com>

Acute pancreatitis and small bowel obstruction caused by a migratory gastric bezoar after dissolution therapy: A case report

Ting-Ting Wang, Jia-Jun He, Jun Liu, Wei-Wei Chen, Chao-Wu Chen

ORCID number: Ting-Ting Wang 0000-0001-9460-2894; Jia-Jun He 0000-0003-3406-9746; Jun Liu 0000-0001-8738-6548; Wei-Wei Chen 0000-0002-8423-1177; Chao-Wu Chen 0000-0003-3339-3691.

Author contributions: Wang TT was the main author of this article; He JJ modified the manuscript; Liu J and Chen WW contributed to manuscript drafting; Chen CW were responsible for revising the manuscript for important intellectual content; All authors issued final approval for the version to be submitted.

Informed consent statement:

Written informed consent was obtained from the patient for publication of this case report.

Conflict-of-interest statement: The authors declared that they have no conflicts of interest regarding this work.

CARE Checklist (2016) statement:

The authors have read the CARE Checklist (2016), and the manuscript was prepared and revised according to the CARE Checklist (2016).

Open-Access: This article is an open-access article that was selected by an in-house editor and fully peer-reviewed by external reviewers. It is distributed in

Ting-Ting Wang, Jia-Jun He, Department of Gastroenterology, The First Clinical Medical College, Dalian Medical University, Dalian 116044, Liaoning Province, China

Jun Liu, Wei-Wei Chen, Chao-Wu Chen, Endoscopy Center, Department of Gastroenterology, Clinical Medical College, Yangzhou University, Yangzhou 225009, Jiangsu Province, China

Corresponding author: Chao-Wu Chen, MD, Associate Chief Physician, Endoscopy Center, Department of Gastroenterology, Clinical Medical College, Yangzhou University, No. 88 South University Ave, Yangzhou 225009, Jiangsu Province, China. sbyy_ccw@163.com

Abstract

BACKGROUND

Bezoars are conglomerates of indigestible foreign material that can be found in the gastrointestinal tract. Gastric ulcer, gastrointestinal perforation, and intestinal obstruction are the main complications. Acute pancreatitis secondary to bezoar is rare. Here, we present a rare case of a migratory gastric bezoar complicated by acute pancreatitis and small bowel obstruction after dissolution therapy.

CASE SUMMARY

A 65-year-old woman underwent gastroscopy because of epigastric pain, which revealed a huge bezoar and a gastric ulcer 10 d prior. The patient was discharged with a prescription of drinking 1 L Coca-Cola daily for 6 d, without repeat gastroscopy. However, she suddenly developed epigastric pain, nausea and vomiting for 3 d. Abdominal computed tomography (CT) revealed mild inflammation of the pancreas. Magnetic resonance cholangiopancreatography showed no abnormalities in the pancreatic duct or common bile duct. The nasogastric tube still showed drainage of more than 1.6 L of dark fluid each day after symptomatic treatment. Abdominal CT re-examination suggested intestinal obstruction. Esophagogastroduodenoscopy revealed a huge yellowish hard mass in the jejunal lumen, and we used the basket and net to fragment the bezoar. She was discharged with a good outcome.

CONCLUSION

Endoscopic therapy is the first choice for gastric bezoars. When mechanical disintegration cannot be achieved, timing of repeat endoscopy is important during Coca-Cola dissolution therapy.

Key Words: Bezoar; Intestinal obstruction; Acute pancreatitis; Dissolution therapy;

accordance with the Creative Commons Attribution NonCommercial (CC BY-NC 4.0) license, which permits others to distribute, remix, adapt, build upon this work non-commercially, and license their derivative works on different terms, provided the original work is properly cited and the use is non-commercial. See: <http://creativecommons.org/licenses/by-nc/4.0/>

Manuscript source: Unsolicited manuscript

Specialty type: Medicine, research and experimental

Country/Territory of origin: China

Peer-review report's scientific quality classification

Grade A (Excellent): 0
Grade B (Very good): 0
Grade C (Good): C
Grade D (Fair): 0
Grade E (Poor): 0

Received: November 15, 2020

Peer-review started: November 15, 2020

First decision: January 27, 2021

Revised: February 8, 2021

Accepted: March 3, 2021

Article in press: March 3, 2021

Published online: May 6, 2021

P-Reviewer: Kozarek R

S-Editor: Fan JR

L-Editor: Filipodia

P-Editor: Xing YX



Endoscopy; Case report

©The Author(s) 2021. Published by Baishideng Publishing Group Inc. All rights reserved.

Core Tip: Coca-Cola dissolution therapy is as an easy, safe, and cost-effective option for gastric bezoars. Acute pancreatitis and small intestinal obstruction secondary to a migratory gastric bezoar during Coca-Cola dissolution therapy has not been previously reported. Here, we report a case of acute pancreatitis and small bowel obstruction caused by a migratory gastric bezoar after dissolution therapy.

Citation: Wang TT, He JJ, Liu J, Chen WW, Chen CW. Acute pancreatitis and small bowel obstruction caused by a migratory gastric bezoar after dissolution therapy: A case report. *World J Clin Cases* 2021; 9(13): 3114-3119

URL: <https://www.wjgnet.com/2307-8960/full/v9/i13/3114.htm>

DOI: <https://dx.doi.org/10.12998/wjcc.v9.i13.3114>

INTRODUCTION

Bezoars are accumulations of indigestible foreign material that can be found in the gastrointestinal tract^[1]. They usually occur in patients with reduced gastric motor and delayed gastric emptying^[2]. The clinical manifestations of gastric bezoars are mainly nonspecific such as dyspepsia, anorexia, epigastric pain, nausea and vomiting^[3]. Major complications include gastric ulcer, gastrointestinal perforation, and intestinal obstruction^[4]. Coca-Cola dissolution therapy of gastric bezoars is an easy, safe, and cost-effective option^[5]. However, acute pancreatitis and small intestinal obstruction caused by a migratory gastric bezoar during Coca-Cola dissolution therapy has not been previously reported.

Here, we report a case of acute pancreatitis and small bowel obstruction caused by a migratory gastric bezoar after dissolution therapy.

CASE PRESENTATION

Chief complaints

A 65-year-old woman was admitted to our department with epigastric pain, nausea, and vomiting for 3 d.

History of present illness

The patient underwent gastroscopy because of epigastric pain, which showed a huge bezoar and a gastric ulcer 10 d prior (Figure 1). The bezoar could not be removed by endoscopy due to its large size and hardness. The patient was discharged with a prescription of drinking 1 L Coca-Cola daily for the following 6 d. However, she did not accept re-examination by gastroscopy to observe the efficacy of dissolution therapy. Subsequently, the patient was admitted to our department with epigastric pain, nausea, and vomiting for 3 d. Follow-up medical history showed that she had been ingesting persimmons frequently in the recent 2 mo.

History of past illness

No significant medical history was recorded such as previous gastric surgery, hyperlipidemia, or alcohol consumption.

Personal and family history

The patient had no previous or family history of similar illnesses.

Physical examination

The clinical abdominal examination revealed epigastric tenderness and distension without rebound tenderness. All other vital signs were stable.

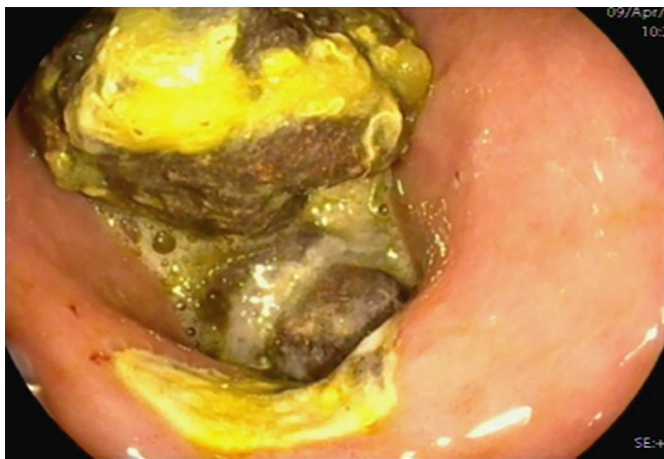

Figure 1 Gastroscope before admission revealed a gastric ulcer and a large bezoar in the stomach.

Laboratory examinations

Abnormally elevated laboratory findings at admission included a leukocyte count of $14830/\text{mm}^3$, aspartate transaminase 60 IU/L, alanine transaminase 64 IU/L, -glutamyl transpeptidase 418 IU/L, and alkaline phosphatase 167 IU/L. Serum amylase and lipase were > 3 times higher than the upper limit of normal, at 507 IU/L and 745 IU/L, respectively.

Imaging examinations

Abdominal computed tomography (CT) revealed mild inflammation of the pancreas (Figure 2). Subsequent magnetic resonance cholangiopancreatography (MRCP) showed no abnormalities in the pancreatic duct or common bile duct.

Further diagnostic work-up

After symptomatic treatment, including gastrointestinal decompression, fluid resuscitation and antibiotic therapy, the abdominal pain was relieved. The levels of serum transaminase, amylase and lipase were gradually reduced. However, the nasogastric tube showed drainage of > 1.6 L of dark fluid each day after admission. Abdominal CT re-examination demonstrated gastric distension and loops of small intestine with multiple gas-fluid levels, which suggested intestinal obstruction (Figure 3).

FINAL DIAGNOSIS

The final diagnosis was acute pancreatitis and small bowel obstruction.

TREATMENT

Esophagogastroduodenoscopy was performed, and a large yellowish hard mass was found in the jejunal lumen, which was suspected to have migrated from the stomach (Figure 4A). We fragmented the bezoar with the basket and net so that the endoscope could pass through the obstructed lumen (Figure 4B).

OUTCOME AND FOLLOW-UP

The patient was discharged in good condition after 3 d. There has been no evidence of recurrence of acute pancreatitis for 3 years during follow-up.

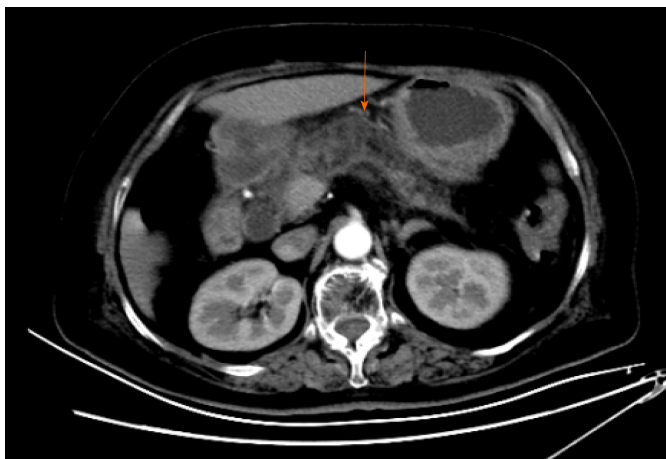

Figure 2 Abdominal computed tomography revealed mild inflammation of the pancreas.

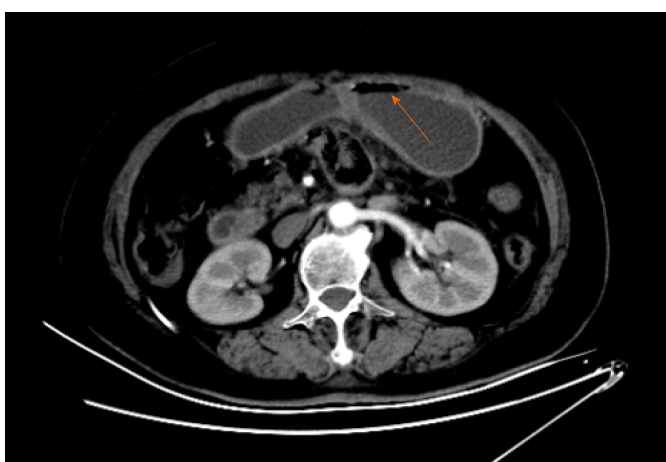


Figure 3 Abdominal computed tomography re-examination revealed gastric distension and loops of small intestine with multiple gas-fluid levels, which suggested intestinal obstruction.

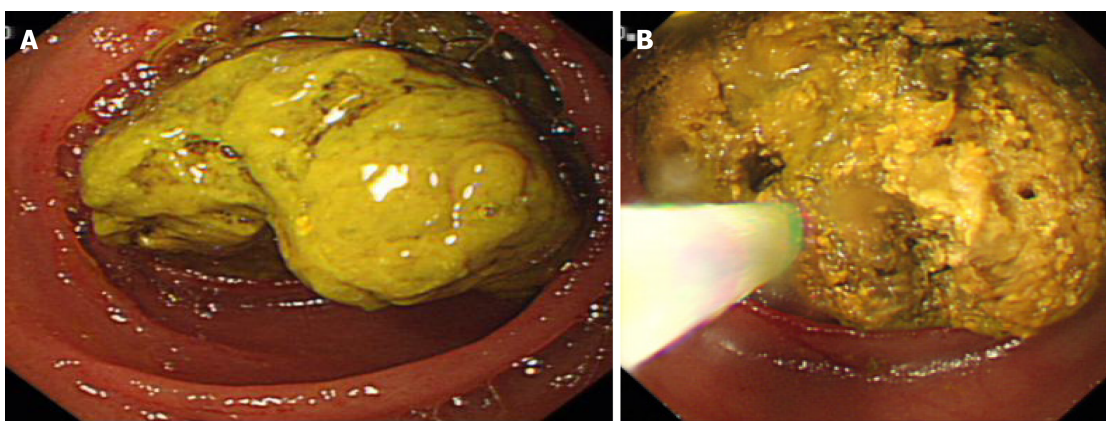


Figure 4 Esophagogastroduodenoscopy. A: Large yellowish hard mass in the jejunal lumen; B: Forward-viewing endoscope was urgently used to fragment the bezoar with the help of a basket and net.

DISCUSSION

Bezoars can be classified into four main types depending on their component sources: phytobezoars, trichobezoars, pharmacobezoars and lactobezoars^[6]. Phytobezoars are the most common type, and are composed of indigestible vegetables or fruits or other food material^[7]. The predisposing factors include prior gastric surgery, excessive consumption of foods with high fiber and tannins, diabetes mellitus, mental retardation, peptic ulcer, hypothyroidism, and poor mastication^[8]. The clinical symptoms of bezoars are mainly nonspecific, and some patients may be asymptomatic or present with gastrointestinal symptoms, such as epigastric pain, dyspepsia, anorexia, nausea and vomiting, which depends on the location and size of the bezoars^[3,4]. Gastric ulcer, accounting for approximately 52%, is the main complication, followed by gastrointestinal perforation and intestinal obstruction^[4,9]. In addition, obstruction caused by bezoars mostly occurs at the distal end of the ileum and ileocecal valve with overall rates of 0.4%-4%^[10]. This may be due to migration of the gastric bezoar, and the major symptoms include abdominal pain, nausea and vomiting^[11].

For our patient, no abnormalities were found in the pancreatic duct or common bile duct on abdominal CT and MRCP. However, acute pancreatitis secondary to phytobezoar has seldom been reported so far. The mechanism of acute pancreatitis in our patient may have been as follows. The migratory bezoar may have obstructed the ampulla of Vater, causing spasm and congestion of the sphincter of Oddi, which led to the occurrence of acute pancreatitis. Second, bezoar-induced small intestinal obstruction may have caused gradually increased pressure in the small bowel. The regurgitation of bile may have abnormally activated trypsin once the pressure of the intestine was higher than that of the pancreatic duct, thus inducing acute pancreatitis. Most gastric phytobezoars can be successfully treated with oral intake of Coca-Cola, through dissolving or diminishing the size or softening the bezoars. Ladas *et al*^[5] reviewed 46 patients from 24 papers and found that 91% of patients were successfully treated with Coca-Cola, either alone or conjunction with endoscopic extraction^[5]. The mechanism of Coca-Cola dissolution is not thoroughly explained. Coca-Cola has an acidity of pH 2.6, which resembles gastric acid, and may be important in digesting fiber. In addition, sodium bicarbonate mucolytic effect and the penetration of carbon dioxide (CO₂) bubbles are also the important factors in the dissolving mechanism^[12]. However, the CO₂ bubbles could increase the pressure in the stomach temporarily, which may help to push the shrunken bezoar through the pylorus and further lead to gastric outlet obstruction or small intestinal obstruction^[13]. Diospyrobezoar is a type of phytobezoar caused by persimmons, which is considered more difficult to dissolve completely by only drinking Coca-Cola compared with other types of phytobezoars because of their hard consistency^[12]. In our case, migration of the diospyrobezoar resulted in small intestinal obstruction and acute pancreatitis during oral administration of Coca-Cola. The treatment of gastric bezoars includes chemical dissolution, endoscopic fragmentation and extraction, and surgery^[2]. Moreover, endoscopic procedures are the preferred treatment for gastric bezoars, through using snares, baskets, biopsy forceps, microwave or laser devices, depending on the location, size and texture of the bezoars^[2,6]. It is difficult to achieve mechanical disintegration when the bezoars are large or hard. Dissolution therapy should be performed first to diminish the size and soften the bezoars, followed by adjuvant endoscopic treatment. Additionally, emergency treatment such as endoscopy or surgery is needed to handle complicated small bowel obstruction^[14]. In the present case, the patient was discharged with a prescription of drinking Coca-Cola daily because the bezoar was too large to be removed directly under endoscopy. Unfortunately, the migratory bezoar resulted in acute pancreatitis and small bowel obstruction after partial dissolution with Coca-Cola.

CONCLUSION

We report a case of acute pancreatitis and small bowel obstruction caused by a migratory gastric bezoar, highlighting that endoscopic treatment should be the first choice for gastric bezoars, and that timing of repeat endoscopy is crucial during Coca-Cola dissolution therapy for patients who cannot achieve mechanical disintegration.

REFERENCES

- 1 **Altintoprak F**, Gemici E, Yildiz YA, Yener Uzunoglu M, Kivilcim T. Intestinal Obstruction due to Bezoar in Elderly Patients: Risk Factors and Treatment Results. *Emerg Med Int* 2019; **2019**: 3647356 [PMID: 30911418 DOI: 10.1155/2019/3647356]
- 2 **Paschos KA**, Chatzigeorgiadis A. Pathophysiological and clinical aspects of the diagnosis and treatment of bezoars. *Ann Gastroenterol* 2019; **32**: 224-232 [PMID: 31040619 DOI: 10.20524/aog.2019.0370]
- 3 **Gök AFK**, Sönmez RE, Kantarcı TR, Bayraktar A, Emiroğlu S, İlhan M, Güloğlu R. Discussing treatment strategies for acute mechanical intestinal obstruction caused by phytobezoar: A single-center retrospective study. *Ulus Travma Acil Cerrahi Derg* 2019; **25**: 503-509 [PMID: 31475322 DOI: 10.14744/tjtes.2019.24557]
- 4 **Kim JH**, Chang JH, Nam SM, Lee MJ, Maeng IH, Park JY, Im YS, Kim TH, Park IY, Han SW. Duodenal obstruction following acute pancreatitis caused by a large duodenal diverticular bezoar. *World J Gastroenterol* 2012; **18**: 5485-5488 [PMID: 23082068 DOI: 10.3748/wjg.v18.i38.5485]
- 5 **Ladas SD**, Kamberoglou D, Karamanolis G, Vlachogiannakos J, Zouboulis-Vafiadis I. Systematic review: Coca-Cola can effectively dissolve gastric phytobezoars as a first-line treatment. *Aliment Pharmacol Ther* 2013; **37**: 169-173 [PMID: 23252775 DOI: 10.1111/apt.12141]
- 6 **Ugenti I**, Travaglio E, Lagouvardou E, Caputi Iambrenghi O, Martines G. Successful endoscopic treatment of gastric phytobezoar: A case report. *Int J Surg Case Rep* 2017; **37**: 45-47 [PMID: 28633127 DOI: 10.1016/j.ijscr.2017.06.015]
- 7 **Zwicky S**, Inauen W, Pfefferkorn U. Case Report: Phytobezoar Causing Gastric Outlet Obstruction as a Late Complication After Biliopancreatic Diversion with Duodenal Switch. *Obes Surg* 2020; **30**: 3233-3235 [PMID: 32232642 DOI: 10.1007/s11695-020-04531-2]
- 8 **Gökbulut V**, Kaplan M, Kaçar S, Akdoğan Kayhan M, Coşkun O, Kayaçetin E. Bezoar in upper gastrointestinal endoscopy: A single center experience. *Turk J Gastroenterol* 2020; **31**: 85-90 [PMID: 32141815 DOI: 10.5152/tjg.2020.18890]
- 9 **Iwamuro M**, Tanaka S, Shiode J, Imagawa A, Mizuno M, Fujiki S, Toyokawa T, Okamoto Y, Murata T, Kawai Y, Tanioka D, Okada H, Yamamoto K. Clinical characteristics and treatment outcomes of nineteen Japanese patients with gastrointestinal bezoars. *Intern Med* 2014; **53**: 1099-1105 [PMID: 24881731 DOI: 10.2169/internalmedicine.53.2114]
- 10 **Mohseni M**, Kruse B. An Unusual Mimic of Intermittent Bowel Obstruction. *Am J Case Rep* 2019; **20**: 1920-1922 [PMID: 31865361 DOI: 10.12659/AJCR.920621]
- 11 **Wang PY**, Wang X, Zhang L, Li HF, Chen L, Wang B. Bezoar-induced small bowel obstruction: Clinical characteristics and diagnostic value of multi-slice spiral computed tomography. *World J Gastroenterol* 2015; **21**: 9774-9784 [PMID: 26361425 DOI: 10.3748/wjg.v21.i33.9774]
- 12 **Ha SS**, Lee HS, Jung MK, Jeon SW, Cho CM, Kim SK, Choi YH. Acute intestinal obstruction caused by a persimmon phytobezoar after dissolution therapy with Coca-Cola. *Korean J Intern Med* 2007; **22**: 300-303 [PMID: 18309693]
- 13 **Lu L**, Zhang XF. Gastric Outlet Obstruction--An Unexpected Complication during Coca-Cola Therapy for a Gastric Bezoar: A Case Report and Literature Review. *Intern Med* 2016; **55**: 1085-1089 [PMID: 27150859 DOI: 10.2169/internalmedicine.55.5567]
- 14 **Nasri B**, Calin M, Shah A, Gilchrist B. A rare cause of small bowel obstruction due to bezoar in a virgin abdomen. *Int J Surg Case Rep* 2016; **19**: 144-146 [PMID: 26764889 DOI: 10.1016/j.ijscr.2015.12.039]



Published by **Baishideng Publishing Group Inc**
7041 Koll Center Parkway, Suite 160, Pleasanton, CA 94566, USA

Telephone: +1-925-3991568

E-mail: bpgoffice@wjgnet.com

Help Desk: <https://www.f6publishing.com/helpdesk>

<https://www.wjgnet.com>

