


World Journal of *Gastrointestinal Surgery*

World J Gastrointest Surg 2021 December 27; 13(12): 1523-1769



Contents

Monthly Volume 13 Number 12 December 27, 2021

FRONTIER

- 1523 Photodynamic therapy: A next alternative treatment strategy for hepatocellular carcinoma?
Zhu F, Wang BR, Zhu ZF, Wang SQ, Chai CX, Shang D, Li M

REVIEW

- 1536 Role of mesenteric component in Crohn's disease: A friend or foe?
Yin Y, Zhu ZX, Li Z, Chen YS, Zhu WM
- 1550 Neoadjuvant treatment strategies for hepatocellular carcinoma
Xu L, Chen L, Zhang W
- 1567 Mucinous adenocarcinoma: A unique clinicopathological subtype in colorectal cancer
Huang A, Yang Y, Shi JY, Li YK, Xu JX, Cheng Y, Gu J

MINIREVIEWS

- 1584 Endoscopic therapy of weight regain after bariatric surgery
Bulajic M, Vadalà di Prampero SF, Bošković I, Costamagna G
- 1597 Patient-centered developments in colon- and rectal cancer with a multidisciplinary international team: From translational research to national guidelines
Link KH, Kornmann M, Staib L, Kreuser ED, Gaus W, Röttinger E, Suhr P, Maulbecker-Armstrong C, Danenberg P, Danenberg K, Schatz M, Sander S, Ji ZL, Li JT, Peng SY, Bittner R, Beger HG, Traub B
- 1615 Advances in liver transplantation for unresectable colon cancer liver metastasis
Cui X, Geng XP, Zhou DC, Yang MH, Hou H

ORIGINAL ARTICLE

Retrospective Study

- 1628 Pediatric T-tube in adult liver transplantation: Technical refinements of insertion and removal
Spoletini G, Bianco G, Franco A, Frongillo F, Nure E, Giovinozzo F, Galiandro F, Tringali A, Perri V, Costamagna G, Avolio AW, Agnes S
- 1638 Preoperative calculation of angles of vision and working area in laparoscopic surgery to treat a giant hiatal hernia
Lara FJP, Zubizarreta Jimenez R, Moya Donoso FJ, Hernández Gonzalez JM, Prieto-Puga Arjona T, del Rey Moreno A, Pitarch Martinez M
- 1651 Effect of aluminum phosphate gel on prevention of early rebleeding after ligation of esophageal variceal hemorrhage
Zhang ZL, Peng MS, Chen ZM, Long T, Wang LS, Xu ZL

- 1660** Postoperative complications after robotic resection of colorectal cancer: An analysis based on 5-year experience at a large-scale center

Huang ZX, Zhou Z, Shi HR, Li TY, Ye SP

- 1673** 'Short' pancreaticojejunostomy might be a valid option for treatment of chronic pancreatitis in many cases

Murruste M, Kirsimägi Ü, Kase K, Veršinina T, Talving P, Lepner U

- 1685** Risk factors for perioperative complications in laparoscopic surgeries of retrorectal cystic lesions

Wang PP, Lin C, Zhou JL, Xu KW, Qiu HZ, Wu B

- 1696** Liver resection *vs* radiofrequency ablation in single hepatocellular carcinoma of posterosuperior segments in elderly patients

Delvecchio A, Inchingolo R, Laforgia R, Ratti F, Gelli M, Anelli MF, Laurent A, Vitali G, Magistri P, Assirati G, Felli E, Wakabayashi T, Pessaux P, Piardi T, di Benedetto F, de'Angelis N, Briceño J, Rampoldi A, Adam R, Cherqui D, Aldrighetti LA, Memeo R

Observational Study

- 1708** Expression of adipokine ghrelin and ghrelin receptor in human colorectal adenoma and correlation with the grade of dysplasia

Stojasavljevic-Shapeski S, Virovic-Jukic L, Tomas D, Duvnjak M, Tomasic V, Hrabar D, Kralj D, Budimir I, Barsic N, Ljubcic N

SYSTEMATIC REVIEWS

- 1721** Right sided diverticulitis in western countries: A review

Epifani AG, Cassini D, Ciocchi R, Accardo C, Di Candido F, Ardu M, Baldazzi G

- 1736** Platelet rich plasma effectiveness in bowel anastomoses: A systematic review

Geropoulos G, Psarras K, Giannis D, Martzivanou EC, Papaioannou M, Kakos CD, Pavlidis ET, Symeonidis N, Koliakos G, Pavlidis TE

- 1754** Current and future role of three-dimensional modelling technology in rectal cancer surgery: A systematic review

Przedlacka A, Pellino G, Fletcher J, Bello F, Tekkis PP, Kontovounisios C

ABOUT COVER

Editorial Board Member of *World Journal of Gastrointestinal Surgery*, Marcello Donati, FACS, MD, PhD, Professor, Department of Surgery and Medical-Surgical specialties, University of Catania, Catania 95125, Italy. mdonati@unict.it

AIMS AND SCOPE

The primary aim of *World Journal of Gastrointestinal Surgery* (WJGS, *World J Gastrointest Surg*) is to provide scholars and readers from various fields of gastrointestinal surgery with a platform to publish high-quality basic and clinical research articles and communicate their research findings online.

WJGS mainly publishes articles reporting research results and findings obtained in the field of gastrointestinal surgery and covering a wide range of topics including biliary tract surgical procedures, biliopancreatic diversion, colectomy, esophagectomy, esophagostomy, pancreas transplantation, and pancreatectomy, etc.

INDEXING/ABSTRACTING

The WJGS is now abstracted and indexed in Science Citation Index Expanded (SCIE, also known as SciSearch®), Current Contents/Clinical Medicine, Journal Citation Reports/Science Edition, PubMed, and PubMed Central. The 2021 edition of Journal Citation Reports® cites the 2020 impact factor (IF) for WJGS as 2.582; IF without journal self cites: 2.564; 5-year IF: 3.378; Journal Citation Indicator: 0.53; Ranking: 97 among 212 journals in surgery; Quartile category: Q2; Ranking: 73 among 92 journals in gastroenterology and hepatology; and Quartile category: Q4.

RESPONSIBLE EDITORS FOR THIS ISSUE

Production Editor: Rui-Rui Wu, Production Department Director: Xiang Li, Editorial Office Director: Ya-Juan Ma.

NAME OF JOURNAL

World Journal of Gastrointestinal Surgery

ISSN

ISSN 1948-9366 (online)

LAUNCH DATE

November 30, 2009

FREQUENCY

Monthly

EDITORS-IN-CHIEF

Shu-You Peng, Varut Lohsiriwat

EDITORIAL BOARD MEMBERS

<https://www.wjgnet.com/1948-9366/editorialboard.htm>

PUBLICATION DATE

December 27, 2021

COPYRIGHT

© 2021 Baishideng Publishing Group Inc

INSTRUCTIONS TO AUTHORS

<https://www.wjgnet.com/bpg/gerinfo/204>

GUIDELINES FOR ETHICS DOCUMENTS

<https://www.wjgnet.com/bpg/gerinfo/287>

GUIDELINES FOR NON-NATIVE SPEAKERS OF ENGLISH

<https://www.wjgnet.com/bpg/gerinfo/240>

PUBLICATION ETHICS

<https://www.wjgnet.com/bpg/gerinfo/288>

PUBLICATION MISCONDUCT

<https://www.wjgnet.com/bpg/gerinfo/208>

ARTICLE PROCESSING CHARGE

<https://www.wjgnet.com/bpg/gerinfo/242>

STEPS FOR SUBMITTING MANUSCRIPTS

<https://www.wjgnet.com/bpg/gerinfo/239>

ONLINE SUBMISSION

<https://www.f6publishing.com>



Retrospective Study

Pediatric T-tube in adult liver transplantation: Technical refinements of insertion and removal

Gabriele Spoletini, Giuseppe Bianco, Antonio Franco, Francesco Frongillo, Erida Nure, Francesco Giovinnazzo, Federica Galiandro, Andrea Tringali, Vincenzo Perri, Guido Costamagna, Alfonso Wolfango Avolio, Salvatore Agnes

ORCID number: Gabriele Spoletini 0000-0002-6855-4515; Giuseppe Bianco 0000-0001-7451-4002; Antonio Franco 0000-0001-6773-3848; Francesco Frongillo 0000-0003-4357-9270; Erida Nure 0000-0002-2264-0258; Francesco Giovinnazzo 0000-0002-3392-9292; Federica Galiandro 0000-0001-5041-4867; Andrea Tringali 0000-0002-9614-3449; Vincenzo Perri 0000-0002-0278-8693; Guido Costamagna 0000-0002-8100-2731; Alfonso Wolfango Avolio 0000-0003-2491-7625; Salvatore Agnes 0000-0002-3341-4221.

Author contributions: Spoletini G and Bianco G were responsible for the conception, design, data analysis and drafting the article; Franco A and Tringali A were responsible for the acquisition of data and provided important intellectual content of the manuscript; Frongillo F, Nure E, Giovinnazzo F, Galiandro F, Perri V, Costamagna G, Avolio AW and Agnes S provided substantial contributions to analysis and interpretation of data and made critical revisions of the manuscript; all authors approved the final version submitted.

Institutional review board statement: The Institutional

Gabriele Spoletini, Giuseppe Bianco, Antonio Franco, Francesco Frongillo, Erida Nure, Francesco Giovinnazzo, Federica Galiandro, Alfonso Wolfango Avolio, Salvatore Agnes, General Surgery and Liver Transplantation Unit, Fondazione Policlinico Universitario Agostino Gemelli IRCCS, Rome 00168, Italy

Andrea Tringali, Vincenzo Perri, Guido Costamagna, Digestive Endoscopy Unit, Fondazione Policlinico Universitario Agostino Gemelli IRCCS, Rome 00168, Italy

Corresponding author: Gabriele Spoletini, FEBS, MD, PhD, Doctor, General Surgery and Liver Transplantation Unit, Fondazione Policlinico Universitario Agostino Gemelli IRCCS, Largo Agostino Gemelli 8, Rome 00168, Italy. gabriele.spoletini@policlinicogemelli.it

Abstract

BACKGROUND

With the increasing use of extended-criteria donor organs, the interest around T-tubes in liver transplantation (LT) was restored whilst concerns regarding T-tube-related complications persist.

AIM

To describe insertion and removal protocols implemented at our institution to safely use pediatric rubber 5-French T-tubes and subsequent outcomes in a consecutive series of adult patients.

METHODS

Data of consecutive adult LT patients from brain-dead donors, treated from March 2017 to December 2019, were collected (*i.e.*, biliary complications, adverse events, treatment after T-Tube removal). Patients with upfront hepatico-jejunostomy, endoscopically removed T-tubes, those who died or received retransplantation before T-tube removal were excluded.

RESULTS

Seventy-two patients were included in this study; T-tubes were removed 158 d (median; IQR 128-206 d) after LT. In four (5.6%) patients accidental T-tube removal occurred requiring monitoring only; in 68 (94.4%) patients Nelaton drain insertion was performed according to our protocol, resulting in 18 (25%) patients

Review Board of Fondazione Policlinico Universitario A Gemelli IRCCS provided approval for this study (IRB No. 3796).

Conflict-of-interest statement: The authors declare no conflicts of interest.

Data sharing statement: No additional data are available.

Country/Territory of origin: Italy

Specialty type: Transplantation

Provenance and peer review: Invited article; Externally peer reviewed.

Peer-review report's scientific quality classification

Grade A (Excellent): 0
Grade B (Very good): B
Grade C (Good): 0
Grade D (Fair): 0
Grade E (Poor): 0

Open-Access: This article is an open-access article that was selected by an in-house editor and fully peer-reviewed by external reviewers. It is distributed in accordance with the Creative Commons Attribution NonCommercial (CC BY-NC 4.0) license, which permits others to distribute, remix, adapt, build upon this work non-commercially, and license their derivative works on different terms, provided the original work is properly cited and the use is non-commercial. See: <http://creativecommons.org/licenses/by-nc/4.0/>

Received: March 17, 2021

Peer-review started: March 17, 2021

First decision: May 4, 2021

Revised: May 17, 2021

Accepted: November 24, 2021

Article in press: November 24, 2021

Published online: December 27, 2021

P-Reviewer: Perisetti A

S-Editor: Zhang H

L-Editor: A

P-Editor: Zhang H



with a biliary output, subsequently removed after 2 d (median; IQR 1-4 d). Three (4%) patients required endoscopic retrograde cholangiopancreatography (ERCP) due to persistent Nelaton drain output. Three (4%) patients developed suspected biliary peritonitis, requiring ERCP with sphincterotomy and nasobiliary drain insertion (only one revealing contrast extravasation); no patient required percutaneous drainage or emergency surgery.

CONCLUSION

The use of pediatric rubber 5-French T-tubes in LT proved safe in our series after insertion and removal procedure refinements.

Key Words: Liver transplantation; T-tube; Kehr; Biliary fistula; Endoscopic retrograde cholangio-pancreatography; Biliary drainage

©The Author(s) 2021. Published by Baishideng Publishing Group Inc. All rights reserved.

Core Tip: The use of small caliber T-tubes and a peculiar insertion technique minimize the size of the choledochotomy and reduce the chance of T-tube related adverse events; a careful T-tube removal procedure with the insertion of a temporary Nelaton drain mitigates the risk of uncontrolled biliary fistula and the need for emergency procedures.

Citation: Spoletini G, Bianco G, Franco A, Frongillo F, Nure E, Giovinnazzo F, Galiandro F, Tringali A, Perri V, Costamagna G, Avolio AW, Agnes S. Pediatric T-tube in adult liver transplantation: Technical refinements of insertion and removal. *World J Gastrointest Surg* 2021; 13(12): 1628-1637

URL: <https://www.wjgnet.com/1948-9366/full/v13/i12/1628.htm>

DOI: <https://dx.doi.org/10.4240/wjgs.v13.i12.1628>

INTRODUCTION

Duct-to-duct biliary anastomosis is the most common technique of biliary reconstruction in deceased-donor liver transplantation (LT). In the past, T-tubes have been routinely used during biliary anastomoses in LT because it provides easy access to the biliary tree, and maintains lower pressure inside the biliary system. Furthermore, quality and quantity of bile production can be monitored and the occurrence of anastomotic strictures and early bile leaks can be reduced. However, in the 90's, many centers stopped using T-tubes based on growing evidence of safe duct-to-duct biliary reconstruction without biliary splinting, and randomized trials demonstrated non-inferior results without the use of T-tubes[1,2]. In addition, concerns regarding the risk of biliary fistulae, major adverse events following T-tube removal and reduced cost-effectiveness were reported[3,4]. Since nowadays more marginal organs are accepted (e.g., steatotic livers, liver donation after cardiac death, and reconditioned grafts) the usefulness of T-tubes in LT is newly discussed. Two single-center randomized trials showed improved results using T-tubes; in particular, a reduced incidence and severity of biliary complications and anastomotic strictures were reported[5,6]. The risk of biliary peritonitis after T-tube removal seems to be attenuated using rubber instead of silicone-coated T-tubes. No consensus around the benefits of T-tube use in LT has been achieved yet, even though evidences were reassessed with several meta-analyses[7-10].

Our center continued to use T-tubes in LT, and the insertion technique, removal protocol and device types were continuously modified and updated over the years with the intent to minimize the risk of T-tube-related adverse events. In particular, a pediatric T-tube in adult patients was implemented to minimize the size of the necessary choledochotomy and possibly post-removal complications. In this study, we describe insertion and removal protocols implemented at our institution for the safe use of pediatric rubber 5-French T-tubes and subsequent outcomes in a consecutive series of adult patients.

MATERIALS AND METHODS

Consecutive adult patients who underwent LT, between March 2017 and December 2019, after the introduction of a pediatric 5-French rubber T-tube at our unit, were included in this retrospective analysis; enrollment was limited to December 2019 to allow a minimum follow-up of 6 mo.

Perioperative and follow-up data were collected including: recipients, donors and intraoperative assessment, early bile leaks (defined as bile leakage from surgical drains or wounds within 30 d from LT), accidental T-tube removal, endoscopic and interventional radiology procedures on the bile ducts, time to T-tube removal, biliary fistulae after T-tube removal, episodes of biliary peritonitis and need for surgical intervention. Biliary fistulae were divided in uncontrolled and controlled depending whether the patients developed biliary peritonitis or not.

The primary objective of our study was to investigate the safety profile of T-tube insertion and removal techniques in LT recipients defined as the incidence of T-tube removal related biliary complications. We analyzed the incidence of biliary complications after T-tube removal in patients who received a duct-to-duct biliary anastomosis over a 5-French pediatric rubber T-tube, which was subsequently removed without instrumental aid [*e.g.*, endoscopic retrograde cholangiopancreatography (ERCP)-assisted or during surgery]. In particular, we focused on the need for endoscopic, interventional radiology or surgical treatment after T-tube removal. Even patients with an accidental T-tube removal were included in our analysis to evaluate whether our insertion technique is protective against bile leaks in such circumstance. Patients who had the T-tube removed during endoscopic interventions on the bile ducts were excluded and summarized separately. Patients with an up-front bilio-enteric anastomosis, those who died or received retransplantation before T-tube removal were excluded.

The study protocol was approved by the Ethics Committee of the Fondazione Policlinico Universitario Agostino Gemelli IRCCS (protocol No. 3796).

T-tube insertion protocol

The policy of our hospital foresees routine placement of T-tubes in all liver transplants except for bilio-enteric anastomoses. Our standard biliary reconstruction technique is an end-to-end duct-to-duct anastomosis with interrupted Vicryl 6/0 stitches and extraluminal knots. Recipient's and graft bile duct ends are trimmed short enough to obtain a straight, non-redundant bile duct to avoid kinking after minimizing liver cephalad and duodenum caudal retraction. Firstly, the posterior half of the anastomosis is sewn with interrupted stitches. Then, a T-tube is inserted through a small choledochotomy approximately 2 cm caudal to the anastomosis. In March 2017, we adopted pediatric 5-French rubber T-tubes (Bard Medical, GA) as our standard device. Main steps of T-tube insertion are shown in [Figure 1](#). The smallest right-angle dissector in our DDLT set (6¼ inches Mixer forceps, Aesculap, DE) is advanced inside the recipient bile duct through the open anterior half of the anastomosis; the tip of the instrument is pushed against the anterior wall of the choledochus; the resulting bulge on the choledochus is incised with a no. 11 scalpel ([Figure 1A](#)). This allows creating a choledochotomy < 2 mm in size which is necessary to advance the tip of the right-angle dissector. Grabbing and pulling the T-tube is avoided as this would require opening the jaws of the right-angle and inevitably expand the size of the choledochotomy. Instead, a 3/0 silk tie is pulled through the choledochotomy ([Figure 1B](#)) and stitched to the horizontal end of the T-tube ([Figure 1C](#)). Only then the silk tie is completely pulled through, which allows the T-tube to slide through the choledochotomy to obtain a perfect fit of the T-tube ([Figure 1D](#)). The lower branch of the vertical portion of the T-tube usually self-allocates inside the distal choledochus ([Figure 1E](#)) while the upper branch is placed with forceps. The anterior wall of the anastomosis is completed ([Figure 1F](#)) with interrupted stitches and the T-tube is externalized through the right upper quadrant, cranial to the transverse skin incision. A video of the insertion technique is provided separately (see supplementary material).

T-tube management

During the first week after LT, bile output is collected daily for quantitative and qualitative assessment to aid postoperative patient management. Before discharge, a T-tube cholangiogram is performed and, in absence of biliary anomalies, the T-tube is capped and secured underneath a wound dressing, which is kept in place for approximately 3 mo. T-tube cholangiograms are performed on demand. In order to insure

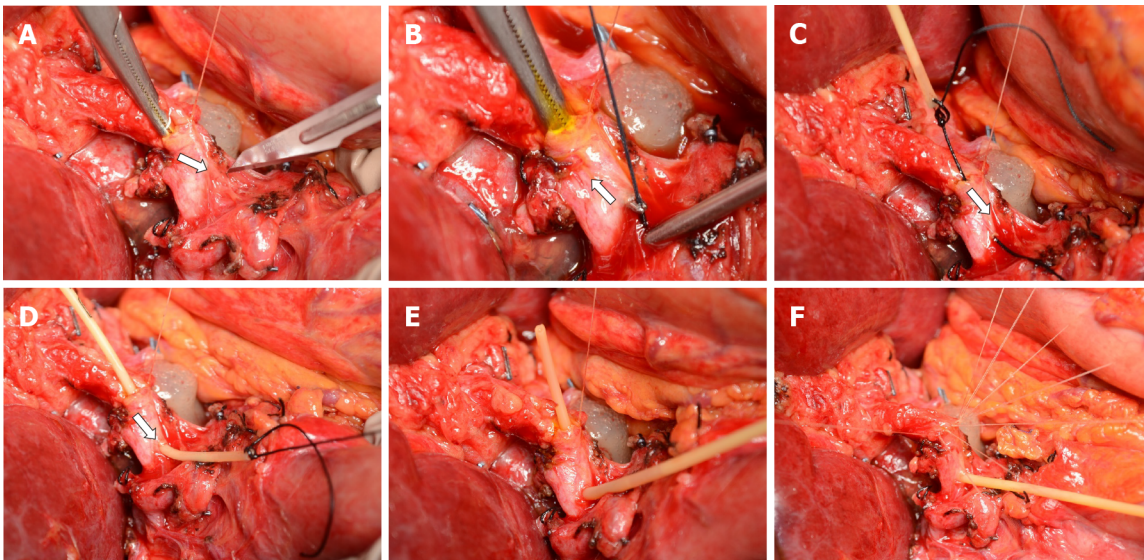


Figure 1 T-tube insertion protocol. A: The right-angle is advanced through the open anterior layer of the duct-to-duct anastomosis and a choledochotomy is created with a no. 11 scalpel; B-D: A silk tie is grabbed and pulled through the choledochotomy after being stitched to the horizontal end of the T-tube; E: the T-tube is allocated inside the bile duct; F: the anastomosis is completed with interrupted Vicryl 6/0 stitches.

adequate T-tube management after discharge at home, patients receive care instructions. During outpatient visits, T-tubes are evaluated by dedicated transplant staff.

T-tube removal protocol

T-tube removal is planned approximately 90 d after LT as an in-patient procedure. Directly after admitting the patients, history and examination are taken and transplant records are reviewed in search of details that could predict a higher risk of biliary complications from T-tube removal (*e.g.*, discrepancy in ducts caliber graft > recipient, complex arterial reconstruction, arterial thrombosis). Patients without evidence of increased risk proceed directly with the removal after the administration of a smooth-muscle relaxant and antibiotic prophylaxis. Patients with increased risk of biliary complications receive a T-tube cholangiogram to detail biliary anatomy and to anticipate critical anatomical conditions to insure safe T-tube removal. If the cholangiogram reveals anatomical problems, the bile duct is prophylactically stented during ERCP or the removal proceeds under fluoroscopic guidance and a stent is inserted on demand. An abdominal ultrasound is also performed in high-risk patients to acquire baseline information before the T-tube is removed.

Figure 2 shows a bedside, standard removal procedure. After informed consent, the patient's abdomen is prepped and draped and local anesthetic is administered around the T-tube exit site. The T-tube is removed and the length between the exit site and the end of the T-tube is measured (Figure 2A and B). Through the exit site of the T-tube, a flexible 8-French Nelaton drain (Teleflex Medical, PA) is advanced 2-3 cm shorter than the length measured on the T-tube with the aim to reach the space near the choledochotomy without entering it accidentally. The drain is secured to the skin with a stitch and connected to a drain bag. The insertion of a Nelaton drain aims at draining possible bile leaks from the choledochotomy. An abdominal ultrasound is performed in search of intrabdominal fluid collections when clinically indicated. The following day, the Nelaton drain is removed, if no bile leak was present, or retracted by approximately 2 cm in case of bile output. The same process is repeated on the following day until the drain is clear of bile and the patient can be discharged.

RESULTS

During the study period, 96 patients received 97 Liver transplants in our center: 92 had an end-to-end duct-to-duct anastomosis over a 5 French T-tube and 5 received an upfront hepaticojejunostomy. Seven patients (five with biliary complications from ischemic cholangiopathy) required endoscopic intervention and removal of the T-tube together with endoscopic biliary stenting: One patient with a bile leak on day 28 post-

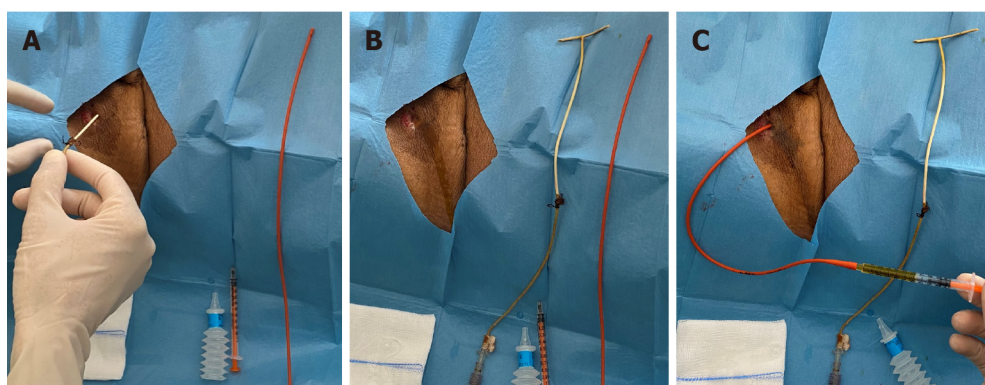


Figure 2 Bedside, standard T-tube removal procedure. A: The T-tube is removed; B: A Nelaton drain is kept aside to measure the length of the T-tube internal tract (whiter portion of the T-tube); C: The Nelaton drain is inserted approximately 2 cm shorter than the measured length.

LT required hepaticojejunostomy after failed endoscopic management attempts due to bile duct end necrosis; four patients had non-anastomotic biliary strictures, and two had biliary stones. After applying the exclusion criteria, 72 patients were included in the study. The characteristics of the study population are reported in [Table 1](#).

Accidental T-tube removal occurred in four (5.6%) cases, on days 11, 13, 87 and 122 post-LT, respectively, and none required active treatment (abdominal ultrasound showing no signs of bile leak).

T-tube cholangiograms were performed in all patients before capping the T-tube. Removal of the T-tube took place as an in-patient procedure, after a median of 158 d (IQR 128-206 d) post-LT. Twenty-five (34.7%) patients received a T-tube cholangiogram before removal, because of deranged liver function tests ($n = 14$) followed by a history of complex anatomy or complications with the hepatic artery ($n = 11$). There were no cases of incomplete T-tube removal (*i.e.*, no retained broken pieces after extraction). In 68 (94.6%) cases it was possible to insert a Nelaton drain through the exit site of the T-tube. Of these, 18 (25%) patients had a biliary output from the Nelaton drain, which was removed after a median of 2 d (IQR 1-4 d) from insertion. [Table 2](#) summarizes management details of the study population. Three (4%) patients had persistent output from the Nelaton drain despite the progressive retraction on a daily basis, as described in the protocol. Therefore, the patients underwent ERCP with endoscopic sphincterotomy and temporary naso-biliary drain ($n = 1$), endoscopic stenting ($n = 1$), while one patient required hepatico-jejunostomy due to a tight bile duct stenosis. Three (4%) patients without output from the Nelaton drain developed symptoms of biliary peritonitis, and underwent ERCP. Of note, ERCP revealed contrast extravasation from the bile duct only in one patient; nevertheless, all three patients received sphincterotomy and temporary naso-biliary drain insertion, which was removed after symptom resolution. Altogether, biliary fistula after T-tube removal occurred in 6 patients (4% controlled and 4% uncontrolled fistula respectively). T-tube-related events are shown in [Table 3](#).

No patient required percutaneous drainage of bile collections or emergency surgery after T-tube removal. No patient death occurred or was related to T-tube removal.

DISCUSSION

Biliary complications from T-tube use are within the most feared and disappointing events after LT. Minimizing the risk of such complications is pivotal for maintaining positive outcomes in LT recipients. With this intent, we refined our insertion technique and removal protocol. Suspected biliary peritonitis after T-tube removal occurred only in 4% of our patients. Of these, only one patient had confirmed contrast extravasation at the time of ERCP, and, therefore, the remaining two had probably a self-limiting bile leak. Remarkably, no patient developed biliary peritonitis or bile collections requiring emergency interventional radiology procedures or surgery. Compared with a systematic review, reporting the incidence of biliary peritonitis of 5% to 33% after T-tube removal, our experience demonstrates that the attention to the insertion and removal technique is essential to preserve LT recipients' safety[11]. As shown in clinical and animal studies, rubber have been preferred over silicone T-tubes in general surgery owing to their ability to induce a stronger fibrogenic reaction forming a

Table 1 Patients' characteristics and surgical data

Variable	Study population <i>n</i> = 72, median (IQR)/ <i>n</i>
Male sex	61 (84.7%)
Recipient age (yr)	57 (50-61)
Body mass index (kg/m ²)	27 (23-29)
Underlying liver disease	
Hepatitis C virus	21 (29.2%)
Hepatitis B virus	7 (9.7%)
Alcohol-related liver disease	25 (34.7%)
Primary biliary cirrhosis	2 (2.8%)
Polycystic liver disease	2 (2.8%)
Acute liver failure	4 (5.6%)
Other	11 (15.3%)
HCC	41 (56.9%)
MELD score	17 (12-22)
Donor age (yr)	62 (45-73)
Use of temporary porto-caval shunt	29 (40.3%)
Use of veno-venous bypass	6 (8.3%)
Total ischemia time (min)	435 (390-488)

HCC: Hepatocellular carcinoma; MELD: Model for end-stage liver disease.

Table 2 T-tube management in the study population

Variable	Study population <i>n</i> = 72, median (IQR)/ <i>n</i>
Time to removal of T-tube (d)	158 (128-206)
T-tube cholangiogram before removal	25 (35%)
Nelaton drain successful insertion	68 (94%)
Nelaton drain with bile output	18 (25%)
Time to removal of Nelaton drain	2 (2-4)
Active treatment required	
ERCP	6 (8%)
Hepatico-jejunostomy	1 (1%)
Emergency surgery	0

ERCP: Endoscopic retrograde cholangiopancreatography.

pseudo-channel that conveys the bile externally after the tube is removed[12]. Keeping the choledochotomy small using a pediatric 5-French T-tube supposedly increases chances that the surrounding tissues can fold the hole in the choledochus after the T-tube is removed; this may explain our low incidence of uncontrolled post-removal biliary fistula. Furthermore, developed fistulae seemed smaller, requiring endoscopic intervention only in a few cases and emergency surgery in no cases. In addition, no bile leak from choledochotomy occurred during cholangiogram in controls, probably owing to the exact fit achieved keeping the choledochotomy the size of the T-tube.

Biliary peritonitis is a surgical emergency that can lead to sepsis and multiorgan failure, especially in the vulnerable LT population[13]. By inserting a Nelaton drain through the T-tube exit site, our removal protocol minimizes consequences of bile

Table 3 Summary of events and treatment required in the study population after T-tube removal

	Events	First-line treatment	Definitive treatment
Accidental T-tube removal	4	4 monitoring	
Post T-tube removal bile leak			
Controlled fistula (through Nelaton drain)	18	15 monitoring 3 ERCP	- 2 stent; 1 HJ
Biliary peritonitis	3 suspected	3 ERCP (1 confirmed)	3 NBD

ERCP: Endoscopic retrograde cholangiopancreatography; HJ: Hepatico-jejunostomy; NBD: Naso-biliary drain.

leaks. The placement of a straight drain by interventional radiologists, with the aim to reduce the occurrence of biliary peritonitis, has been already described in 1998[14]. Similarly, we use a Nelaton drain, which is inserted at the bedside as soon as the T-tube is removed. Some patients with biliary output from the Nelaton drain (controlled biliary fistula) could be considered as potentially saved from developing biliary peritonitis (uncontrolled fistula).

Several alternatives to conventional T-tube placement have been described. A tunneled retroperitoneal route has been proposed with the rationale to support T-tube tract development allowing to control fistula after removal[15]. Intraductal stent placement has been adopted to overcome the side effects of external T-tubes in 20 patients with a bile duct caliber < 5 mm. The downside with this approach is the need for endoscopic removal 4 to 6 mo after placement and the reported complication rate was still significant in 4 patients[16]. A randomized clinical trial is ongoing in which custom-made 2 cm-segment of an 8 French T-tube are inserted in the biliary duct without suture fixation, which is removed *via* ERCP and sphincterotomy 4 to 6 mo after LT[17]. Resorbable internal biliary stents for LT have been tested *in vitro* and have been already employed to treat refractory anastomotic strictures in LT recipients[18, 19]. In a matched case-control study, a transcystic straight drain has been used with improved results compared with T-tube placement; however, the technique is not applicable in bile ducts with a low cystic duct confluence [20].

Concerns over the lack of fibrous tract formation around the T-tube have been addressed by delaying the time of removal (transplant recipients might have impaired healing processes due to the steroidal treatment and ascites formation). On the other hand, a higher rate of biliary stricture have been observed, supposedly because of the prolonged permanence of the T-tube inside the bile duct and increased risk of microbial contamination[21].

In our center, we maintained our T-tube policy, which is a limitation of our study as we have no comparative group (no-T-tube group). Moreover, our LT recipients are inevitably subjected to an extra hospital admission to remove the T-tube. The need to hospitalize patients for the removal procedure can also cause delays due to limited bed capacities, as shown in our time to T-tube removal, which is often longer than 3 mo. A relevant proportion of patients had the T-Tube removed during interventional ERCP for biliary complications mainly related to ischemic cholangiopathy, if T-tubes aggravate such complications remains unclear. The long-lasting presence of a foreign body could contaminate ischemic bile ducts and contribute to damage[22].

CONCLUSION

We managed to mitigate the risk of complications related to T-tube insertion and removal, which partly explains the reason why we did not change our policy. Altogether, we demonstrated safety, and our outcomes are not inferior to those reported in literature. With our study, we provide insight on LT management of patients who received a T-tube, which we believe could be of interest in the contemporary context of increased donor risk and regained attention around the use of T-tubes.

ARTICLE HIGHLIGHTS

Research background

The use of T-tube in liver transplantation (LT) remains controversial despite being the objective of randomized trials and meta-analyses. Since the 90's many centers stopped using T-tubes in LT. More recently, the increasing use of extended-criteria organs has revived the interest around the usefulness of T-tube in LT.

Research motivation

In our center, we maintained our T-tube policy refining the T-tube insertion and removal techniques continuously. Since March 2017, we have adopted a pediatric rubber 5-French T-tube for splinting the biliary duct-to-duct anastomosis in adult LT recipients.

Research objectives

To describe the insertion and removal protocols implemented at our institution for the safe use of pediatric rubber 5-French T-tubes and the subsequent outcomes in a consecutive series of adult patients.

Research methods

We retrospectively analyzed data of consecutive adult LT recipients from brain-dead-donors, treated from March 2017 to December 2019, regarding biliary complications, adverse events, and treatment required after T-tube removal. Patients with upfront hepatico-jejunostomy, endoscopically removed T-tubes, those who died or received retransplantation before T-tube removal were excluded.

Research results

Out of 72 patients who had the T-tube removed, 68 (94.4%) had per-protocol Nelaton drain insertion through the T-tube exit site. Of these, biliary output was observed in 18 (25%) patients. The Nelaton drain was removed after 2 d (median; IQR 1-4 d). Three (4%) patients required endoscopic retrograde cholangiopancreatography (ERCP) due to persistent Nelaton drain biliary output. Three (4%) patients developed suspected biliary peritonitis, requiring ERCP with sphincterotomy and nasobiliary drain insertion (only one revealing contrast extravasation). No patients required percutaneous drainage of bile collections or emergency surgery after T-tube removal. In four (5.6%) patients accidental T-tube removal occurred, none requiring active treatment. There was no mortality associated with T-tube removal.

Research conclusions

In our series of adult LT recipients, the use of a pediatric T-tube was safe with insertion and removal technique refinements, resulting in minor morbidity and no mortality after T-tube removal.

Research perspectives

With the increasing use of extended-criteria donor grafts in LT, the use of T-tubes is regaining interest, regarding bile output and quality measure and for bile duct protection purposes to reduce the risk of stenosis and leaks. In this perspective, refined insertion and removal techniques are pivotal to ensure low morbidity associated with the use of the T-tube.

ACKNOWLEDGEMENTS

We would like to thank Franziska M Lohmeyer, PhD, Fondazione Policlinico Universitario Agostino Gemelli IRCCS, for her support revising our manuscript.

REFERENCES

- 1 **Vougas V**, Rela M, Gane E, Muiesan P, Melendez HV, Williams R, Heaton ND. A prospective randomised trial of bile duct reconstruction at liver transplantation: T tube or no T tube? *Transpl Int* 1996; **9**: 392-395 [PMID: [8819276](#) DOI: [10.1007/bf00335701](#)]
- 2 **Scatton O**, Meunier B, Cherqui D, Boillot O, Sauvanet A, Boudjema K, Launois B, Fagniez PL,

- Belghiti J, Wolff P, Houssin D, Soubrane O. Randomized trial of choledochocholedochostomy with or without a T tube in orthotopic liver transplantation. *Ann Surg* 2001; **233**: 432-437 [PMID: 11224633 DOI: 10.1097/0000658-200103000-00019]
- 3 **Shimoda M**, Saab S, Morrissey M, Ghobrial RM, Farmer DG, Chen P, Han SH, Bedford RA, Goldstein LI, Martin P, Busuttil RW. A cost-effectiveness analysis of biliary anastomosis with or without T-tube after orthotopic liver transplantation. *Am J Transplant* 2001; **1**: 157-161 [PMID: 12099364 DOI: 10.1034/j.1600-6143.2001.10210.x]
- 4 **Amador A**, Charco R, Martí J, Navasa M, Rimola A, Calatayud D, Rodríguez-Laiz G, Ferrer J, Romero J, Ginesta C, Fondevila C, Fuster J, García-Valdecasas JC. Clinical trial on the cost-effectiveness of T-tube use in an established deceased donor liver transplantation program. *Clin Transplant* 2007; **21**: 548-553 [PMID: 17645718 DOI: 10.1111/j.1399-0012.2007.00688.x]
- 5 **Weiss S**, Schmidt SC, Ulrich F, Pascher A, Schumacher G, Stockmann M, Puhl G, Guckelberger O, Neumann UP, Pratschke J, Neuhaus P. Biliary reconstruction using a side-to-side choledochocholedochostomy with or without T-tube in deceased donor liver transplantation: a prospective randomized trial. *Ann Surg* 2009; **250**: 766-771 [PMID: 19809299 DOI: 10.1097/SLA.0b013e3181bd920a]
- 6 **López-Andújar R**, Orón EM, Carregnat AF, Suárez FV, Herraiz AM, Rodríguez FS, Carbó JJ, Ibars EP, Sos JE, Suárez AR, Castillo MP, Pallardó JM, De Juan Burgueño M. T-tube or no T-tube in cadaveric orthotopic liver transplantation: the eternal dilemma: results of a prospective and randomized clinical trial. *Ann Surg* 2013; **258**: 21-29 [PMID: 23426348 DOI: 10.1097/SLA.0b013e318286e0a0]
- 7 **Sotiropoulos GC**, Sgourakis G, Radtke A, Molmenti EP, Goumas K, Mylona S, Fouzas I, Karaliotas C, Lang H. Orthotopic liver transplantation: T-tube or not T-tube? *Transplantation* 2009; **87**: 1672-1680 [PMID: 19502959 DOI: 10.1097/TP.0b013e3181a5cf3f]
- 8 **Riediger C**, Müller MW, Michalski CW, Hüser N, Schuster T, Kleeff J, Friess H. T-Tube or no T-tube in the reconstruction of the biliary tract during orthotopic liver transplantation: systematic review and meta-analysis. *Liver Transpl* 2010; **16**: 705-717 [PMID: 20517904 DOI: 10.1002/lt.22070]
- 9 **Paes-Barbosa FC**, Massarollo PC, Bernardo WM, Ferreira FG, Barbosa FK, Raslan M, Szutan LA. Systematic review and meta-analysis of biliary reconstruction techniques in orthotopic deceased donor liver transplantation. *J Hepatobiliary Pancreat Sci* 2011; **18**: 525-536 [PMID: 21127915 DOI: 10.1007/s00534-010-0346-5]
- 10 **Sun N**, Zhang J, Li X, Zhang C, Zhou X. Biliary tract reconstruction with or without T-tube in orthotopic liver transplantation: a systematic review and meta-analysis. *Expert Rev Gastroenterol Hepatol* 2015; **9**: 529-538 [PMID: 25583036 DOI: 10.1586/17474124.2015.1002084]
- 11 **Akamatsu N**, Sugawara Y, Hashimoto D. Biliary reconstruction, its complications and management of biliary complications after adult liver transplantation: a systematic review of the incidence, risk factors and outcome. *Transpl Int* 2011; **24**: 379-392 [PMID: 21143651 DOI: 10.1111/j.1432-2277.2010.01202.x]
- 12 **Koivusalo A**, Eskelinen M, Wolff H, Talva M, Mäkisalo H. Development of T-tube tracts in piglets: effect of insertion method and material of T-tubes. *Res Exp Med (Berl)* 1997; **197**: 53-61 [PMID: 9226763 DOI: 10.1007/s004330050055]
- 13 **Avolio AW**, Franco A, Schlegel A, Lai Q, Meli S, Burra P, Patrono D, Ravaioli M, Bassi D, Ferla F, Pagano D, Viola P, Camagni S, Dondossola D, Montalti R, Alrawashdeh W, Vitale A, Teofili L, Spoletini G, Magistri P, Bongini M, Rossi M, Mazzaferro V, Di Benedetto F, Hammond J, Vivarelli M, Agnes S, Colledan M, Carraro A, Cescon M, De Carlis L, Caccamo L, Gruttadauria S, Muiesan P, Cillo U, Romagnoli R, De Simone P. Development and Validation of a Comprehensive Model to Estimate Early Allograft Failure Among Patients Requiring Early Liver Transplant. *JAMA Surg* 2020; **155**: e204095 [PMID: 33112390 DOI: 10.1001/jamasurg.2020.4095]
- 14 **Goodwin SC**, Bittner CA, Patel MC, Noronha MA, Chao K, Sayre JW. Technique for reduction of bile peritonitis after T-tube removal in liver transplant patients. *J Vasc Interv Radiol* 1998; **9**: 986-990 [PMID: 9840046 DOI: 10.1016/s1051-0443(98)70437-3]
- 15 **Navez J**, Mohkam K, Darnis B, Cazauran JB, Ducerf C, Mabrut JY. Biliary Duct-to-Duct Reconstruction with a Tunneled Retroperitoneal T-Tube During Liver Transplantation: a Novel Approach to Decrease Biliary Leaks After T-Tube Removal. *J Gastrointest Surg* 2017; **21**: 723-730 [PMID: 27815760 DOI: 10.1007/s11605-016-3313-x]
- 16 **Tranchart H**, Zalinski S, Sepulveda A, Chirica M, Prat F, Soubrane O, Scatton O. Removable intraductal stenting in duct-to-duct biliary reconstruction in liver transplantation. *Transpl Int* 2012; **25**: 19-24 [PMID: 21954951 DOI: 10.1111/j.1432-2277.2011.01339.x]
- 17 **Goumard C**, Cachanado M, Herrero A, Rousseau G, Dondero F, Compagnon P, Boleslawski E, Mabrut JY, Salamé E, Soubrane O, Simon T, Scatton O. Biliary reconstruction with or without an intraductal removable stent in liver transplantation: study protocol for a randomized controlled trial. *Trials* 2015; **16**: 598 [PMID: 26719017 DOI: 10.1186/s13063-015-1139-6]
- 18 **Battistel M**, Senzolo M, Ferrarese A, Lupi A, Cillo U, Boccagni P, Zanusi G, Stramare R, Quaia E, Burra P, Barbiero G. Biodegradable Biliary Stents for Percutaneous Treatment of Post-liver Transplantation Refractory Benign Biliary Anastomotic Strictures. *Cardiovasc Intervent Radiol* 2020; **43**: 749-755 [PMID: 32133551 DOI: 10.1007/s00270-020-02442-4]
- 19 **Girard E**, Chagnon G, Moreau-Gaudry A, Letoublon C, Favier D, Dejean S, Trilling B, Nottelet B. Evaluation of a biodegradable PLA-PEG-PLA internal biliary stent for liver transplantation: in vitro degradation and mechanical properties. *J Biomed Mater Res B Appl Biomater* 2021; **109**: 410-419

- [PMID: 32876396 DOI: 10.1002/jbm.b.34709]
- 20 **Panaro F**, Glaise A, Miggino M, Bouyabrine H, Carabalona J, Gallix B, Navarro F. Rubber transcystic drainage reduces the post-removal biliary complications in liver transplantation: a matched case-control study. *Langenbecks Arch Surg* 2013; **398**: 169-176 [PMID: 22718298 DOI: 10.1007/s00423-012-0970-4]
 - 21 **Lattanzi B**, Lai Q, Guglielmo N, Giannelli V, Merli M, Giusto M, Melandro F, Ginanni Corradini S, Mennini G, Berloco PB, Rossi M. Graft macrosteatosis and time of T-tube removal as risk factors for biliary strictures after liver transplantation. *Clin Transplant* 2013; **27**: E332-E338 [PMID: 23647461 DOI: 10.1111/ctr.12124]
 - 22 **Pravisani R**, De Simone P, Patrono D, Lauterio A, Cescon M, Gringeri E, Colledan M, Di Benedetto F, di Francesco F, Antonelli B, Manzia TM, Carraro A, Vivarelli M, Regalia E, Vennarecci G, Guglielmo N, Cesaretti M, Avolio AW, Valentini MF, Lai Q, Baccarani U. An Italian survey on the use of T-tube in liver transplantation: old habits die hard! *Updates Surg* 2021; **73**: 1381-1389 [PMID: 33792888 DOI: 10.1007/s13304-021-01019-1]



Published by **Baishideng Publishing Group Inc**
7041 Koll Center Parkway, Suite 160, Pleasanton, CA 94566, USA

Telephone: +1-925-3991568

E-mail: bpgoffice@wjgnet.com

Help Desk: <https://www.f6publishing.com/helpdesk>

<https://www.wjgnet.com>

