

# World Journal of *Clinical Cases*

*World J Clin Cases* 2021 June 6; 9(16): 3796-4115



## Contents

Thrice Monthly Volume 9 Number 16 June 6, 2021

## REVIEW

- 3796 COVID-19 and the digestive system: A comprehensive review  
*Wang MK, Yue HY, Cai J, Zhai YJ, Peng JH, Hui JF, Hou DY, Li WP, Yang JS*

## MINIREVIEWS

- 3814 COVID-19 impact on the liver  
*Baroiu L, Dumitru C, Iancu A, Leşe AC, Drăgănescu M, Baroiu N, Anghel L*
- 3826 Xenogeneic stem cell transplantation: Research progress and clinical prospects  
*Jiang LL, Li H, Liu L*

## ORIGINAL ARTICLE

## Case Control Study

- 3838 Histopathological classification and follow-up analysis of chronic atrophic gastritis  
*Wang YK, Shen L, Yun T, Yang BF, Zhu CY, Wang SN*

## Retrospective Study

- 3848 Effectiveness of sharp recanalization of superior vena cava-right atrium junction occlusion  
*Wu XW, Zhao XY, Li X, Li JX, Liu ZY, Huang Z, Zhang L, Sima CY, Huang Y, Chen L, Zhou S*
- 3858 Management and outcomes of surgical patients with intestinal Behçet's disease and Crohn's disease in southwest China  
*Zeng L, Meng WJ, Wen ZH, Chen YL, Wang YF, Tang CW*
- 3869 Clinical and radiological outcomes of dynamic cervical implant arthroplasty: A 5-year follow-up  
*Zou L, Rong X, Liu XJ, Liu H*

## Observational Study

- 3880 Differential analysis revealing APOC1 to be a diagnostic and prognostic marker for liver metastases of colorectal cancer  
*Shen HY, Wei FZ, Liu Q*

## Randomized Clinical Trial

- 3895 Comparison of white-light endoscopy, optical-enhanced and acetic-acid magnifying endoscopy for detecting gastric intestinal metaplasia: A randomized trial  
*Song YH, Xu LD, Xing MX, Li KK, Xiao XG, Zhang Y, Li L, Xiao YJ, Qu YL, Wu HL*

## CASE REPORT

- 3908** Snapping wrist due to bony prominence and tenosynovitis of the first extensor compartment: A case report  
*Hu CJ, Chow PC, Tzeng IS*
- 3914** Massive retroperitoneal hematoma as an acute complication of retrograde intrarenal surgery: A case report  
*Choi T, Choi J, Min GE, Lee DG*
- 3919** Internal fixation and unicompartmental knee arthroplasty for an elderly patient with patellar fracture and anteromedial osteoarthritis: A case report  
*Nan SK, Li HF, Zhang D, Lin JN, Hou LS*
- 3927** Haemangiomas in the urinary bladder: Two case reports  
*Zhao GC, Ke CX*
- 3936** Endoscopic diagnosis and treatment of an appendiceal mucocele: A case report  
*Wang TT, He JJ, Zhou PH, Chen WW, Chen CW, Liu J*
- 3943** Diagnosis and spontaneous healing of asymptomatic renal allograft extra-renal pseudo-aneurysm: A case report  
*Xu RF, He EH, Yi ZX, Li L, Lin J, Qian LX*
- 3951** Rehabilitation and pharmacotherapy of neuromyelitis optica spectrum disorder: A case report  
*Wang XJ, Xia P, Yang T, Cheng K, Chen AL, Li XP*
- 3960** Undifferentiated intimal sarcoma of the pulmonary artery: A case report  
*Li X, Hong L, Huo XY*
- 3966** Chest pain in a heart transplant recipient: A case report  
*Chen YJ, Tsai CS, Huang TW*
- 3971** Successful management of therapy-refractory pseudoachalasia after Ivor Lewis esophagectomy by bypassing colonic pull-up: A case report  
*Flemming S, Lock JF, Hankir M, Reimer S, Petritsch B, Germer CT, Seyfried F*
- 3979** Old unreduced obturator dislocation of the hip: A case report  
*Li WZ, Wang JJ, Ni JD, Song DY, Ding ML, Huang J, He GX*
- 3988** Laterally spreading tumor-like primary rectal mucosa-associated lymphoid tissue lymphoma: A case report  
*Wei YL, Min CC, Ren LL, Xu S, Chen YQ, Zhang Q, Zhao WJ, Zhang CP, Yin XY*
- 3996** Coronary artery aneurysm combined with myocardial bridge: A case report  
*Ye Z, Dong XF, Yan YM, Luo YK*
- 4001** Thoracoscopic diagnosis of traumatic pericardial rupture with cardiac hernia: A case report  
*Wu YY, He ZL, Lu ZY*

- 4007** Delayed diagnosis and comprehensive treatment of cutaneous tuberculosis: A case report  
*Gao LJ, Huang ZH, Jin QY, Zhang GY, Gao MX, Qian JY, Zhu SX, Yu Y*
- 4016** Rapidly progressing primary pulmonary lymphoma masquerading as lung infectious disease: A case report and review of the literature  
*Jiang JH, Zhang CL, Wu QL, Liu YH, Wang XQ, Wang XL, Fang BM*
- 4024** Asymptomatic carbon dioxide embolism during transoral vestibular thyroidectomy: A case report  
*Tang JX, Wang L, Nian WQ, Tang WY, Xiao JY, Tang XX, Liu HL*
- 4032** Transient immune hepatitis as post-coronavirus disease complication: A case report  
*Drăgănescu AC, Săndulescu O, Bilașco A, Kouris C, Streinu-Cercel A, Luminos M, Streinu-Cercel A*
- 4040** Acute inferior myocardial infarction in a young man with testicular seminoma: A case report  
*Scafa-Udriste A, Popa-Fotea NM, Bataila V, Calmac L, Dorobantu M*
- 4046** Asymptomatic traumatic rupture of an intracranial dermoid cyst: A case report  
*Zhang MH, Feng Q, Zhu HL, Lu H, Ding ZX, Feng B*
- 4052** Parotid mammary analogue secretory carcinoma: A case report and review of literature  
*Min FH, Li J, Tao BQ, Liu HM, Yang ZJ, Chang L, Li YY, Liu YK, Qin YW, Liu WW*
- 4062** Liver injury associated with the use of selective androgen receptor modulators and post-cycle therapy: Two case reports and literature review  
*Koller T, Vrbova P, Meciarova I, Molcan P, Smitka M, Adamcova Selcanova S, Skladany L*
- 4072** Spinal epidural abscess due to coinfection of bacteria and tuberculosis: A case report  
*Kim C, Lee S, Kim J*
- 4081** Rare complication of inflammatory bowel disease-like colitis from glycogen storage disease type 1b and its surgical management: A case report  
*Lui FCW, Lo OSH*
- 4090** Thymosin as a possible therapeutic drug for COVID-19: A case report  
*Zheng QN, Xu MY, Gan FM, Ye SS, Zhao H*
- 4095** Arrhythmogenic right ventricular cardiomyopathy characterized by recurrent syncope during exercise: A case report  
*Wu HY, Cao YW, Gao TJ, Fu JL, Liang L*
- 4104** Delayed pseudoaneurysm formation of the carotid artery following the oral cavity injury in a child: A case report  
*Chung BH, Lee MR, Yang JD, Yu HC, Hong YT, Hwang HP*
- 4110** Atezolizumab-induced anaphylactic shock in a patient with hepatocellular carcinoma undergoing immunotherapy: A case report  
*Bian LF, Zheng C, Shi XL*

**ABOUT COVER**

Editorial Board Member of *World Journal of Clinical Cases*, Gwo-Ping Jong, FCCP, MD, MHSc, PhD, Associate Professor, Department of Public Health, Chung Shan Medical University, Taichung 40201, Taiwan. cgp8009@yahoo.com.tw

**AIMS AND SCOPE**

The primary aim of *World Journal of Clinical Cases* (WJCC, *World J Clin Cases*) is to provide scholars and readers from various fields of clinical medicine with a platform to publish high-quality clinical research articles and communicate their research findings online.

WJCC mainly publishes articles reporting research results and findings obtained in the field of clinical medicine and covering a wide range of topics, including case control studies, retrospective cohort studies, retrospective studies, clinical trials studies, observational studies, prospective studies, randomized controlled trials, randomized clinical trials, systematic reviews, meta-analysis, and case reports.

**INDEXING/ABSTRACTING**

The WJCC is now indexed in Science Citation Index Expanded (also known as SciSearch®), Journal Citation Reports/Science Edition, Scopus, PubMed, and PubMed Central. The 2020 Edition of Journal Citation Reports® cites the 2019 impact factor (IF) for WJCC as 1.013; IF without journal self cites: 0.991; Ranking: 120 among 165 journals in medicine, general and internal; and Quartile category: Q3. The WJCC's CiteScore for 2019 is 0.3 and Scopus CiteScore rank 2019: General Medicine is 394/529.

**RESPONSIBLE EDITORS FOR THIS ISSUE**

Production Editor: Yan-Xia Xing, Production Department Director: Yun-Xiaoqian Wu, Editorial Office Director: Jin-Lai Wang.

**NAME OF JOURNAL**

*World Journal of Clinical Cases*

**ISSN**

ISSN 2307-8960 (online)

**LAUNCH DATE**

April 16, 2013

**FREQUENCY**

Thrice Monthly

**EDITORS-IN-CHIEF**

Dennis A Bloomfield, Sandro Vento, Bao-Gan Peng

**EDITORIAL BOARD MEMBERS**

<https://www.wjgnet.com/2307-8960/editorialboard.htm>

**PUBLICATION DATE**

June 6, 2021

**COPYRIGHT**

© 2021 Baishideng Publishing Group Inc

**INSTRUCTIONS TO AUTHORS**

<https://www.wjgnet.com/bpg/gerinfo/204>

**GUIDELINES FOR ETHICS DOCUMENTS**

<https://www.wjgnet.com/bpg/GerInfo/287>

**GUIDELINES FOR NON-NATIVE SPEAKERS OF ENGLISH**

<https://www.wjgnet.com/bpg/gerinfo/240>

**PUBLICATION ETHICS**

<https://www.wjgnet.com/bpg/GerInfo/288>

**PUBLICATION MISCONDUCT**

<https://www.wjgnet.com/bpg/gerinfo/208>

**ARTICLE PROCESSING CHARGE**

<https://www.wjgnet.com/bpg/gerinfo/242>

**STEPS FOR SUBMITTING MANUSCRIPTS**

<https://www.wjgnet.com/bpg/GerInfo/239>

**ONLINE SUBMISSION**

<https://www.f6publishing.com>



## Undifferentiated intimal sarcoma of the pulmonary artery: A case report

Xin Li, Liu Hong, Xiao-Yan Huo

**ORCID number:** Xin Li 0000-0002-1986-332X; Liu Hong 0000-0001-6348-3431; Xiao-Yan Huo 0000-0001-6671-8021.

**Author contributions:** Li X and Huo XY contributed to the echocardiographic consultation and manuscript writing and revision; Liu H contributed to the pathological analysis and literature research; all authors read and approved the final manuscript.

**Informed consent statement:**

Informed written consent was obtained from the patient for publication of this report and any accompanying images.

**Conflict-of-interest statement:** The authors declare that they have no conflict of interest to report.

**CARE Checklist (2016) statement:**

The authors have read the CARE Checklist (2016), and the manuscript was prepared and revised according to the CARE Checklist (2016).

**Open-Access:** This article is an open-access article that was selected by an in-house editor and fully peer-reviewed by external reviewers. It is distributed in accordance with the Creative Commons Attribution NonCommercial (CC BY-NC 4.0) license, which permits others to

Xin Li, Liu Hong, Xiao-Yan Huo, Department of Ultrasonography, Chinese People's Liberation Army General Hospital-Sixth Medical Center, Beijing 100048, China

**Corresponding author:** Xin Li, PhD, Department of Ultrasonography, Chinese People's Liberation Army General Hospital-Sixth Medical Center, No. 6 Fucheng Road, Haidian District, Beijing 100048, China. [lixin\\_dp@163.com](mailto:lixin_dp@163.com)

### Abstract

#### BACKGROUND

Since 1923, only a few hundred cases of pulmonary arterial sarcoma (PAS) have been reported. It is easy for PAS to be misdiagnosed as pulmonary thromboembolism, which makes treatment difficult. The median survival time without surgical treatment for PAS is only 1.5-3 mo. Echocardiography is widely used in screening for pulmonary artery space-occupying lesions in patients with chest pain, dyspnea, and cough; furthermore, it is typically considered the first imaging examination for patients with PAS.

#### CASE SUMMARY

In May 2017, a 39-year-old male patient experienced chest pain with no particular obvious cause. At that time, the cause was thought to be pulmonary embolism. In July 2017, positron emission tomography-computed tomography revealed space-occupying lesions in the right lung and multiple metastases in both lungs. The lesions of the right lung were biopsied, and pathology revealed undifferentiated sarcoma. Chemotherapy had been performed since July 2017 in another hospital. In December 2019, the patient was admitted to our hospital for the sake of CyberKnife treatment. Echocardiography suggested: (1) A right ventricular outflow tract (RVOT) solid mass of the main pulmonary artery; and (2) mild pulmonary valve regurgitation. Ultrasonography showed the absence of a thrombus in the deep veins of either lower limb.

#### CONCLUSION

PAS is a single, central space-occupying lesion involving the RVOT and pulmonary valve. Echocardiography of PAS has its own characteristics.

**Key Words:** Echocardiography; Computed tomography; Pulmonary arterial sarcoma; Pulmonary thromboembolism; Main pulmonary artery; Right ventricular outflow tract; Case report



distribute, remix, adapt, build upon this work non-commercially, and license their derivative works on different terms, provided the original work is properly cited and the use is non-commercial. See: <http://creativecommons.org/licenses/by-nc/4.0/>

**Manuscript source:** Unsolicited manuscript

**Specialty type:** Respiratory system

**Country/Territory of origin:** China

**Peer-review report's scientific quality classification**

Grade A (Excellent): 0

Grade B (Very good): B

Grade C (Good): C

Grade D (Fair): 0

Grade E (Poor): 0

**Received:** December 2, 2020

**Peer-review started:** December 2, 2020

**First decision:** January 29, 2021

**Revised:** February 16, 2021

**Accepted:** March 29, 2021

**Article in press:** March 29, 2021

**Published online:** June 6, 2021

**P-Reviewer:** Goebel WS

**S-Editor:** Liu M

**L-Editor:** Wang TQ

**P-Editor:** Wang LL



©The Author(s) 2021. Published by Baishideng Publishing Group Inc. All rights reserved.

**Core Tip:** Echocardiography has a high sensitivity in the diagnosis of pulmonary artery space-occupying lesions. The misdiagnosis of pulmonary arterial sarcoma (PAS) by echocardiography is attributed to insufficient knowledge of this disease. If the following four features are detected, a diagnosis of PAS should be considered: (1) A single pulmonary arterial mass involving the right ventricular outflow tract or pulmonary valve; (2) varying degrees of pulmonary stenosis detected based on ultrasonic measurements; (3) the mass can move slightly and blood supply can be seen inside; and (4) use of ultrasonography of the lower extremity and inferior vena cava to exclude thrombus.

**Citation:** Li X, Hong L, Huo XY. Undifferentiated intimal sarcoma of the pulmonary artery: A case report. *World J Clin Cases* 2021; 9(16): 3960-3965

**URL:** <https://www.wjgnet.com/2307-8960/full/v9/i16/3960.htm>

**DOI:** <https://dx.doi.org/10.12998/wjcc.v9.i16.3960>

## INTRODUCTION

Malignant lesions of the pulmonary artery mainly include primary lung sarcoma and metastasis, and benign lesions mainly include pulmonary thrombus, benign granuloma, and myxoma. Takayasu's arteritis and Behcet disease are rarely observed. Since 1923, only a few hundred cases of pulmonary arterial sarcoma (PAS) have been reported in the literature. Because of the small number of cases, limited knowledge of the disease, and the lack of unique PAS clinical manifestations, it is easy for PAS to be misdiagnosed as pulmonary thromboembolism (PTE) or pulmonary hypertension, which makes treatment difficult. It has been reported that the vast majority of PAS patients cannot be diagnosed before surgery or death, and they die within a few days to a month after diagnosis[1]. The median survival time without surgical treatment for PAS is only 1.5 mo to 3 mo, but the mean survival time after early diagnosis and surgical treatment can be extended to 17 mo.

The diagnosis of PAS relies on pathological findings, but there are risks in sourcing the material for these examinations. Imaging examination is the best method for screening for pulmonary artery space-occupying lesions in PAS patients with chest pain, dyspnea, and cough. Positron emission tomography (PET)-computed tomography (CT) images show a mass shadow in patients with PAS as a result of the abnormally increased fludeoxyglucose intake, and PAS displays progressive enhancement in dynamic enhanced magnetic resonance imaging. CT images show that the proximal part of the PAS tumor is convex toward the right ventricular outflow tract (RVOT) or toward the blood flow. These features are useful in the differential diagnosis of benign and malignant pulmonary arterial masses[2]. Transthoracic echocardiography (TTE) is widely used because it is radiation-free and low-cost and has good repeatability, and it is typically the first imaging examination for patients with PAS.

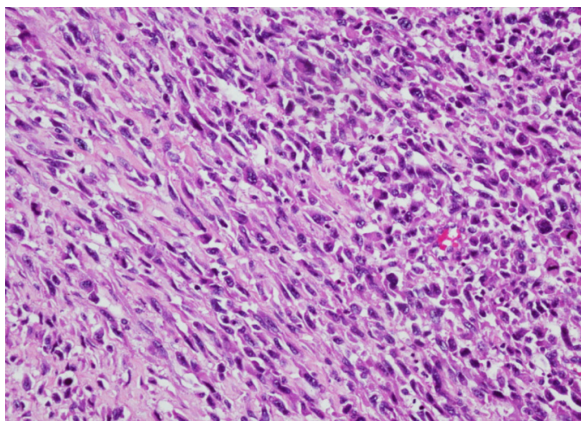
## CASE PRESENTATION

### Chief complaints

PAS was diagnosed two years ago.

### History of present illness

In May 2017, a 39-year-old patient experienced chest pain with no particular obvious cause. At that time, the cause was thought to be pulmonary embolism, but treatment for embolism was not effective. In July 2017, a PET-CT scan at another hospital showed space-occupying lesions in the right lung and multiple metastases in both lungs (images not available). The lesions of the right lung were biopsied, and pathology revealed undifferentiated sarcoma. The tumor was composed of spindle and pleomorphic cells with obvious atypia, arranged into fascicles (Figure 1). Chemo-



**Figure 1** The undifferentiated intimal sarcoma is composed of spindle and pleomorphic cells with obvious atypia.

therapy had been performed since July 2017 in another hospital. In November 2019, the PET-CT images showed that the tumor activity was inhibited after chemoradiotherapy in the hilum of the right lung. However, multiple nodules and patchy images of both lungs and nodules at the superior vena cava were found, indicating occurrence of metastasis. The patient was admitted to our hospital in December 2019, whose CT images acquired at our hospital showed multiple nodules and patchy images in the right lung (Figure 2). At that time, despite the absence of other symptoms, the patient reported that breathing difficulties may develop if he makes any slight movements.

#### **History of past illness**

The patient had a 25-year history of smoking. He had no history of exposure to chemical, radioactive, or toxic substances.

#### **Personal and family history**

The patient was a businessman. There was no family history of genetic disease.

#### **Physical examination**

The patient is male, with a height of 168 cm and weight of 52 kg. The results of physical examination at our hospital suggested a heart rate of 82 beats per minute and normal rhythm, and no pathological murmur or pericardial friction rubs were found in all valve auscultation areas.

#### **Laboratory examinations**

The patient's D-dimer value in another hospital was unknown.

#### **Imaging examinations**

The patient's echocardiography performed at our hospital showed that the right ventricle was enlarged. The internal diameter of the right ventricular infundibulum was increased by about 30 mm, and the diameter of the main pulmonary artery (MPA) was about 29 mm. A solid mass of about 14 mm × 7 mm was detected below the pulmonary valve adjacent to the RVOT (Figure 3). During the cardiac cycle, the mass oscillated between the RVOT and MPA (Video 1). Mild pulmonary regurgitation was observed. A mosaic-like blood flow within the mass was detected. The velocity of pulmonary artery blood flow around the mass increased slightly and the MPA stenosis was estimated as approximately 50%. No space-occupying lesions were found in the branches of the right or left MPA. No thrombus was detected by ultrasound in the deep veins of either lower limb. These findings suggested: (1) an RVOT solid mass of the MPA; and (2) mild pulmonary valve regurgitation.

---

## **FINAL DIAGNOSIS**

---

PAS with multiple metastases of both lungs.



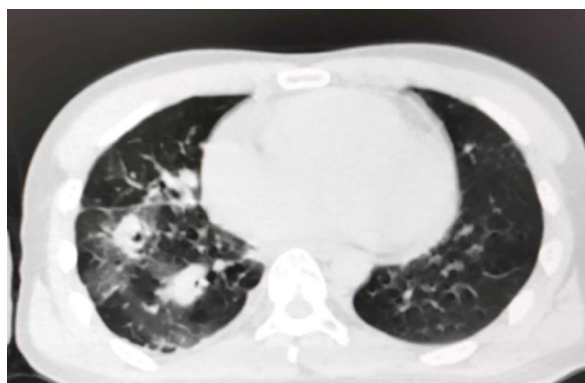


Figure 2 Computed tomography images revealing multiple nodules and patchy images in the right lung.

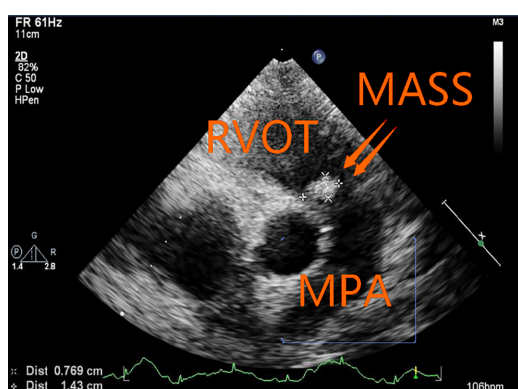


Figure 3 A solid mass of 14 mm × 7 mm was detected in the pulmonary artery. RVOT: Right ventricular outflow tract; MPA: Main pulmonary artery.

## TREATMENT

Chemotherapy had been performed since July 2017. Doxorubicin and ifosfamide were administered for 20 courses of treatment, followed by radiotherapy for the right lung lesion in November 2019. In December 2019, the patient received CyberKnife treatment at our hospital.

## OUTCOME AND FOLLOW-UP

The patient was discharged in January 2020 and died the following month.

## DISCUSSION

PAS is a large arterial sarcoma with no recognized staging system. It can be categorized into two types: Intimal sarcoma and luminal sarcoma. The latter type is rarely seen, and PAS mainly refers to intimal sarcoma[3]. The World Health Organization classification (2013 version) of soft-tissue tumors includes PAS as a soft-tissue malignant tumor with uncertain differentiation, which may originate from multipotent mesenchymal cells in the intima, most of which are poorly differentiated spindle-cell sarcomas with the feature of fibroblast and/or myofibroblast differentiation. Cell atypia, mitosis, and necrosis vary among cases. Sebenik *et al*[4] classified tumors as “differentiated types” and “undifferentiated types.”

PAS is most likely to be misdiagnosed as PTE[5]. The basis for the differential diagnosis of PAS and PTE by ultrasound can be described as follows. First of all, there are no clear signs of PTE using TTE, and only an enlarged right heart and dilated pulmonary arteries can be detected, whereas TTE of PAS can clearly show space-occupying lesions of the pulmonary artery. Second, deep venous thrombosis is considered to be an indicator of PTE, and vascular ultrasound of PAS showed no

thrombosis in the deep veins of the lower extremities or the inferior vena cava. Third, 85% of PAS occur in the MPA, which are a single, central space-occupying lesion involving the RVOT and pulmonary valve. PTE primarily occurs in the pulmonary lobar and segmental artery branches. The incidence of RVOT malignant tumors of the MPA is much greater than that of benign tumors, and angiosarcoma is often detected. When lesions of the MPA involve RVOT, the diagnosis is likely PAS. Additionally, the PAS is able to move slightly, and the blood flow signal is also seen in the tumor, whereas PTE can barely move without a blood flow signal inside. Lastly, different degrees of pulmonary artery stenosis can be detected in patients with PAS, whereas PTE is typically associated with different degrees of pulmonary hypertension. This is useful to distinguish PAS from PTE with the same right ventricular volume overloaded. In this case, a solid mass, detected in the RVOT-MPA, oscillated with cardiac cycle. The pulmonary valve was affected, and mild pulmonary valve regurgitation was detected. Blood flow signal was found in the tumor. The mass occupied approximately 50% of the internal diameter of the MPA. The local blood flow rate of the pulmonary artery was slightly increased, and ultrasound revealed no thrombosis in the deep veins. Ultrasonic findings were consistent with the PAS diagnosis.

The clinical manifestations of PAS and PTE are also different[6]. First, the course of PAS is progressive, and thrombolytic therapy is less effective. However, the course of acute PTE is rapid, and 11% of patients with PTE die within one hour. If the active thrombus enters the central pulmonary artery, the rate of early mortality ranges from 80% to 100%. Second, the diagnostic sensitivity of positive D-dimer for acute PTE is as high as 92%-100%. Although an increase in D-dimer can result in a false-positive diagnosis of PTE, D-dimer can be used as the primary basis for identification, and a negative D-dimer is basically a reason to exclude PTE. Third, when PAS is identified, metastases occur in 50% of cases, with distant metastases occurring in 16% of cases[7]. In this case, the initial onset occurred two years ago, the efficacy of thrombolytic therapy was unsatisfactory, and the PET-CT images showed multiple metastases in both lungs only after two months. It was more likely to be PAS although the D-dimer value was unknown.

Transesophageal echocardiography (TEE) is more advantageous than TTE in identifying whether there is sessile tumor, the capsule is intact, the internal echo is homogeneous, there is blood supply inside, and there is filling defect of pulmonary artery or not[8]. Although intracardiac or pulmonary thrombosis, which is missed by TTE, can be detected through TEE in about 80% of patients with PTE[9], the thrombus volume was smaller than that of PAS malignant tumor. No sessile tumor and no blood flow signal can be measured.

## CONCLUSION

Taking all of the findings together, echocardiography has a high sensitivity for the diagnosis of pulmonary artery space-occupying lesions. The misdiagnosis of PAS by echocardiography is attributed to the lack of knowledge of this disease. If the following four features are detected, a diagnosis of PAS should be considered: (1) A single pulmonary arterial mass involving RVOT or the pulmonary valve; (2) varying degrees of pulmonary stenosis based on ultrasonic detection; (3) the mass is able to move slightly and blood supply can be seen inside; and (4) ultrasound of the lower extremity and inferior vena cava can exclude thrombus. If PAS cannot be identified by TTE, TEE should be performed. If PAS is initially diagnosed by ultrasound, the D-dimer test is negative, and other imaging findings are associated with lung space-occupying lesions, a clinical pathological biopsy should be performed.

## REFERENCES

- 1 Wyler von Ballmoos MC, Chan EY, Reardon MJ. Imaging and Surgical Treatment of Primary Pulmonary Artery Sarcoma. *Int J Cardiovasc Imaging* 2019; **35**: 1429-1433 [PMID: 30535656 DOI: 10.1007/s10554-018-1489-8]
- 2 Xi XY, Gao W, Gong JN, Guo XJ, Wu JY, Yang YH, Yang MF. Value of <sup>18</sup>F-FDG PET/CT in differentiating malignancy of pulmonary artery from pulmonary thromboembolism: a cohort study and literature review. *Int J Cardiovasc Imaging* 2019; **35**: 1395-1403 [PMID: 30747369 DOI: 10.1007/s10554-019-01553-5]
- 3 Harbhajanka A, Dahoud W, Michael CW, Elliot R. Cytohistological correlation,

- immunohistochemistry and Murine Double Minute Clone 2 amplification of pulmonary artery intimal sarcoma: A case report with review of literature. *Diagn Cytopathol* 2019; **47**: 494-497 [PMID: 30552756 DOI: 10.1002/dc.24131]
- 4 **Sebenik M**, Ricci A Jr, DiPasquale B, Mody K, Pytel P, Jee KJ, Knuutila S, Scholes J. Undifferentiated intimal sarcoma of large systemic blood vessels: report of 14 cases with immunohistochemical profile and review of the literature. *Am J Surg Pathol* 2005; **29**: 1184-1193 [PMID: 16096408]
- 5 **David S**, Hoepfer MM, Vogel-Claussen J, Cebotari S. Pulmonary Arterial Sarcoma Presenting as Acute Pulmonary Embolism. *Am J Respir Crit Care Med* 2017; **196**: 523 [PMID: 28504896 DOI: 10.1164/rccm.201703-0596IM]
- 6 **Deng L**, Zhu J, Xu J, Guo S, Liu S, Song Y. Clinical presentation and surgical treatment of primary pulmonary artery sarcoma. *Interact Cardiovasc Thorac Surg* 2018; **26**: 243-247 [PMID: 29049745 DOI: 10.1093/icvts/ivx318]
- 7 **Todaro MC**, Orlassino R, Fornengo C, Ravera A, Macchia G, Soffiantino F, Lovato RL, Senatore G. [A case of pulmonary artery sarcoma and review of the literature]. *G Ital Cardiol (Rome)* 2017; **18**: 792-795 [PMID: 29105675]
- 8 **Rudkovskaia AA**, Bandyopadhyay D. Intraluminal Arterial Filling Defects Misdiagnosed as Pulmonary Emboli: What Else Could They Be? *Clin Chest Med* 2018; **39**: 505-513 [PMID: 30122175 DOI: 10.1016/j.ccm.2018.04.004]
- 9 **Fyfe DA**, Kline CH, Sade RM, Gillette PC. Transesophageal echocardiography detects thrombus formation not identified by transthoracic echocardiography after the Fontan operation. *J Am Coll Cardiol* 1991; **18**: 1733-1737 [PMID: 1960321]



Published by **Baishideng Publishing Group Inc**  
7041 Koll Center Parkway, Suite 160, Pleasanton, CA 94566, USA

**Telephone:** +1-925-3991568

**E-mail:** [bpgoffice@wjgnet.com](mailto:bpgoffice@wjgnet.com)

**Help Desk:** <https://www.f6publishing.com/helpdesk>

<https://www.wjgnet.com>

