11-May-2021 03:52PM 2027 words • 10 matches • 9 sources FAQ

iThenticate 61089_Auto_Edited-check.docx

Quotes Excluded
Bibliography Excluded

9%
SIMILAR

**Name of Journal:** *World Journal of Clinical Cases*

**Manuscript NO:** 61089

**Manuscript Type:** CASE REPORT

**Single solitary seminal vesicle metastasis from ileal adenocarcinoma presenting with haematospermia: A case report**

Cheng XB *et al*. Seminal vesicle metastasis from ileal adenocarcinoma

Xiao-Bao Cheng, Zhen-Quan Lu, Wayne Lam, MK Yiu, Ji-Shi Li

**Abstract**

BACKGROUND

Although metastatic adenocarcinoma of the ileum is not uncommon, single solitary metastasis to the seminal vesicle has not been reported. We report a patient presented with recurrent haematospermia diagnosed with metastasis to the seminal vesicle following ileal adenocarcinoma resection, his subsequent management and outcome.

Match Overview

1 Internet 27 words crawled on 04-Mar-2021 www.wjgnet.com 2%

2 Crossref 24 words Aziz Zaanan, Mélanie Gauthier, David Malka, Christophe Lo cher et al. "Second-line chemotherapy with fluorouracil, leuc 1%

3 Internet 20 words crawled on 13-Apr-2016 pagepressjournals.org 1%

4 Internet 16 words crawled on 31-Oct-2020 ar.iiarjournals.org 1%

5 Crossref 15 words Kotoe Takayoshi, Hitoshi Kusaba, Masato Uenomachi, Kenji Mitsugi et al. "Suggestion of added value by bevacizumab to 1%

6 Internet 15 words crawled on 07-Jun-2014 www.ijms.ie 1%

7 Internet 14 words crawled on 20-Jun-2019 f6publishing.blob.core.windows.net 1%

8 Internet 13 words crawled on 02-Oct-2020 bmccancer.biomedcentral.com 1%

9 Internet 13 words crawled on 01-Dec-2017 bmcurol.biomedcentral.com 1%

激活 Windows

国内版 国际版

Microsoft Bing

Single solitary seminal vesicle metastasis from ileal adenocarcinoma

Sign in

ALL IMAGES VIDEOS

Add the Give with Bing e

5,310 Results Any time

(PDF) Primary adenocarcinoma of the seminal vesicles. A ...
https://www.researchgate.net/publication/301508984...
Primary **adenocarcinoma** of the **seminal** vesicles (SV) are extremely rare and approximately only 60 cases have been reported in the literature. Due to the lack of specific symptoms the patients often ...

(PDF) Metastatic primary seminal vesicle adenocarcinoma ...
https://www.researchgate.net/publication/320328453...
**Metastatic** primary **seminal** vesicle **adenocarcinoma**: Management of a rare tumour with multiagent chemotherapy and hormonal therapy October 2017 BMJ Case Reports 2017:bcr-2017-221896

Images of Single Solitary Seminal Vesicle Metastasis From Ile...
bing.com/images

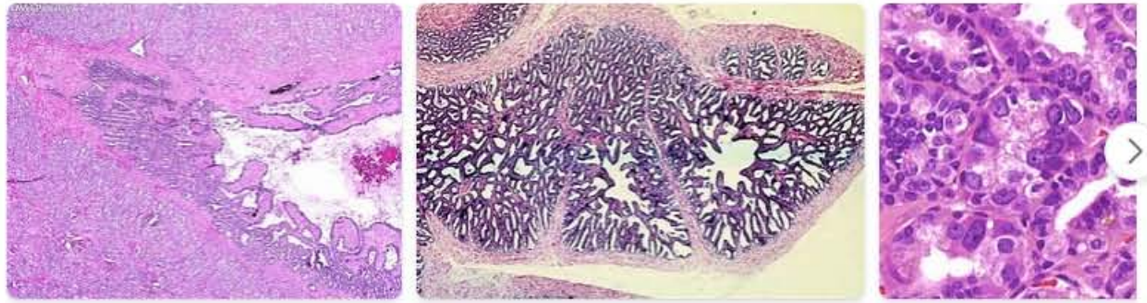

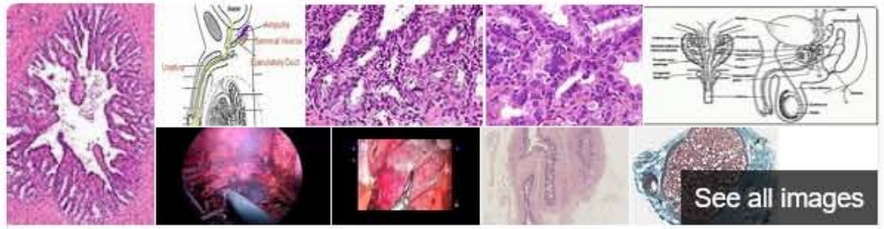


## Seminal vesicle

The seminal vesicles, vesicular glands, or seminal glands, are a pair of simple tubular glands posteroinferior to the urinary bladder of some male mammals. Carnivores do not have seminal vesicles. Seminal vesicles are located within the pelvis.

W Wikipedia

**People also search for:** Prostate · Vas deferens · Bulbourethral gland · Epididymis · Ejaculatory duct · Testicle · Scrotum · Spermatic cord +

Data from: Wikipedia · Freebase

Suggest an edit

Search Tools

Microsoft Bing

Single solitary seminal vesicle metastasis from ileal adenocarc

ALL IMAGES VIDEOS MAPS NEWS SHOPPING

2,310 Results Any time

Primary Seminal Vesicle Adenocarcinoma Presenting as ...
https://www.researchgate.net/publication/6382487...
We **report** a rare **case** of isolated penile **metastasis** from **seminal** vesicle **adenocarcinoma** associated with ipsilateral renal agenesis in a 62-year-old man.

(PDF) Primary adenocarcinoma of the seminal vesicles. A ...
https://www.researchgate.net/publication/301508984...
In this **report** we describe what we consider to be the second **case** of **seminal** vescicle (SV) **metastasis** from an unknown primary melanoma. only **presenting** symptom was a palpable firm nodule of the ...

(PDF) Primary Mucinous Adenocarcinoma of a Seminal Vesicle ...
https://www.researchgate.net/publication/6283019...
Also, Lee et al. 9 reported **a case** of mucinous **adenocarcinoma present** in a **seminal** vesicle cyst. Jaidane et al. 10 reported an **adenocarcinoma** of a ureter draining a dysplastic pelvic kidney and ...

Neurilemmoma of a seminal vesicle | Request PDF
https://www.researchgate.net/publication/6127708...
Discussion: This unusual **case** of a **solitary** schwannoma of the **seminal** vesicle in a patient with a locally advanced rectal **adenocarcinoma** illustrates the difficulty in diagnosing these rare lesions ...

Cystic Schwannoma of a Seminal Vesicle | Request PDF
https://www.researchgate.net/publication/221858385...
Discussion: This unusual **case** of a **solitary** schwannoma of the **seminal** vesicle in a patient with a locally advanced rectal **adenocarcinoma** illustrates the difficulty in diagnosing these rare lesions ...

Imaging of the Seminal Vesicle and Vas Deferens | Request PDF
https://www.researchgate.net/publication/26674090...
In this **report** we describe what we consider to be the second **case** of **seminal** vescicle (SV) **metastasis** from an unknown primary melanoma. only **presenting** symptom was a palpable firm nodule of the ...

Association of hemospermia with prostate cancer | Request PDF
https://www.researchgate.net/publication/51369412...
6 Although **seminal** vesicle **adenocarcinoma** can be observed in males at every age, the mean patient age