

# World Journal of *Clinical Cases*

*World J Clin Cases* 2021 March 16; 9(8): 1761-2021



**REVIEW**

- 1761** Cardiac rehabilitation and its essential role in the secondary prevention of cardiovascular diseases  
*Winnige P, Vysoky R, Dosbaba F, Batalik L*

**ORIGINAL ARTICLE****Case Control Study**

- 1785** Association between homeobox protein transcript antisense intergenic ribonucleic acid genetic polymorphisms and cholangiocarcinoma  
*Lampropoulou DI, Laschos K, Aravantinos G, Georgiou K, Papiris K, Theodoropoulos G, Gazouli M, Filippou D*

**Retrospective Study**

- 1793** Risk factors for post-hepatectomy liver failure in 80 patients  
*Xing Y, Liu ZR, Yu W, Zhang HY, Song MM*
- 1803** Outcomes of laparoscopic bile duct exploration for choledocholithiasis with small common bile duct  
*Huang XX, Wu JY, Bai YN, Wu JY, Lv JH, Chen WZ, Huang LM, Huang RF, Yan ML*

**Observational Study**

- 1814** Three-dimensional finite element analysis with different internal fixation methods through the anterior approach  
*Xie XJ, Cao SL, Tong K, Zhong ZY, Wang G*
- 1827** Bedside cardiopulmonary ultrasonography evaluates lung water content in very low-weight preterm neonates with patent ductus arteriosus  
*Yu LF, Xu CK, Zhao M, Niu L, Huang XM, Zhang ZQ*

**CASE REPORT**

- 1835** Conservative endodontic management using a calcium silicate bioceramic sealer for delayed root fracture: A case report and review of the literature  
*Zheng P, Shen ZY, Fu BP*
- 1844** Brain magnetic resonance imaging findings and radiologic review of maple syrup urine disease: Report of three cases  
*Li Y, Liu X, Duan CF, Song XF, Zhuang XH*
- 1853** A three-year clinical investigation of a Chinese child with craniometaphyseal dysplasia caused by a mutated ANKH gene  
*Wu JL, Li XL, Chen SM, Lan XP, Chen JJ, Li XY, Wang W*
- 1863** Intradural osteomas: Report of two cases  
*Li L, Ying GY, Tang YJ, Wu H*

- 1871** Gastroesophageal varices in a patient presenting with essential thrombocythemia: A case report  
*Wang JB, Gao Y, Liu JW, Dai MG, Yang SW, Ye B*
- 1877** Chest pain showing precordial ST-segment elevation in a 96-year-old woman with right coronary artery occlusion: A case report  
*Wu HY, Cheng G, Cao YW*
- 1885** Subcutaneous panniculitis-like T-cell lymphoma invading central nervous system in long-term clinical remission with lenalidomide: A case report  
*Sun J, Ma XS, Qu LM, Song XS*
- 1893** Imaging findings of primary pulmonary synovial sarcoma with secondary distant metastases: A case report  
*Li R, Teng X, Han WH, Li Y, Liu QW*
- 1901** Severe community-acquired pneumonia caused by *Leptospira interrogans*: A case report and review of literature  
*Bao QH, Yu L, Ding JJ, Chen YJ, Wang JW, Pang JM, Jin Q*
- 1909** Bilateral common peroneal neuropathy due to rapid and marked weight loss after biliary surgery: A case report  
*Oh MW, Gu MS, Kong HH*
- 1916** Retroperitoneal laparoscopic partial resection of the renal pelvis for urothelial carcinoma: A case report  
*Wang YL, Zhang HL, Du H, Wang W, Gao HF, Yu GH, Ren Y*
- 1923** 17 $\alpha$ -hydroxylase/17,20 carbon chain lyase deficiency caused by p.Tyr329fs homozygous mutation: Three case reports  
*Zhang D, Sun JR, Xu J, Xing Y, Zheng M, Ye SD, Zhu J*
- 1931** Epithelioid angiomyolipoma of the pancreas: A case report and review of the literature  
*Zhu QQ, Niu ZF, Yu FD, Wu Y, Wang GB*
- 1940** Computed tomography imaging features for amyloid dacryolith in the nasolacrimal excretory system: A case report  
*Che ZG, Ni T, Wang ZC, Wang DW*
- 1946** Epidural analgesia followed by epidural hydroxyethyl starch prevented post-dural puncture headache: Twenty case reports and a review of the literature  
*Song LL, Zhou Y, Geng ZY*
- 1953** Extracorporeal membrane oxygenation for coronavirus disease 2019-associated acute respiratory distress syndrome: Report of two cases and review of the literature  
*Wen JL, Sun QZ, Cheng Z, Liao XZ, Wang LQ, Yuan Y, Li JW, Hou LS, Gao WJ, Wang WJ, Soh WY, Li BF, Ma DQ*
- 1968** Human parvovirus B19-associated early postoperative acquired pure red cell aplasia in simultaneous pancreas-kidney transplantation: A case report  
*Wang H, Fu YX, Song WL, Wang Z, Feng G, Zhao J, Nian YQ, Cao Y*

- 1976** Diabetes insipidus with impaired vision caused by germinoma and perioptic meningeal seeding: A case report  
*Yang N, Zhu HJ, Yao Y, He LY, Li YX, You H, Zhang HB*
- 1983** Madelung disease: A case report  
*Chen KK, Ni LS, Yu WH*
- 1989** Laryngopharyngeal reflux disease management for recurrent laryngeal contact granuloma: A case report  
*Li K, Chen WY, Li YY, Wang TL, Tan MJ, Chen Z, Chen H*
- 1996** *Mycobacterium abscessus* infection after facial injection of argireline: A case report  
*Chen CF, Liu J, Wang SS, Yao YF, Yu B, Hu XP*
- 2001** Inadvertent globe penetration during retrobulbar anesthesia: A case report  
*Dai Y, Sun T, Gong JF*
- 2008** Systemic lupus erythematosus combined with primary hyperfibrinolysis and protein C and protein S deficiency: A case report  
*Liao YX, Guo YF, Wang YX, Liu AH, Zhang CL*
- 2015** Interstitial lung disease induced by the roots of *Achyranthes japonica* Nakai: Three case reports  
*Moon DS, Yoon SH, Lee SI, Park SG, Na YS*

**ABOUT COVER**

Gokul Sridharan, MD, PhD, Associate Professor, Oral Pathology and Microbiology, YMT Dental College and Hospital, Navi Mumbai, Mumbai 400018, Maharashtra, India. drgokuls@gmail.com

**AIMS AND SCOPE**

The primary aim of *World Journal of Clinical Cases* (WJCC, *World J Clin Cases*) is to provide scholars and readers from various fields of clinical medicine with a platform to publish high-quality clinical research articles and communicate their research findings online.

WJCC mainly publishes articles reporting research results and findings obtained in the field of clinical medicine and covering a wide range of topics, including case control studies, retrospective cohort studies, retrospective studies, clinical trials studies, observational studies, prospective studies, randomized controlled trials, randomized clinical trials, systematic reviews, meta-analysis, and case reports.

**INDEXING/ABSTRACTING**

The WJCC is now indexed in Science Citation Index Expanded (also known as SciSearch®), Journal Citation Reports/Science Edition, Scopus, PubMed, and PubMed Central. The 2020 Edition of Journal Citation Reports® cites the 2019 impact factor (IF) for WJCC as 1.013; IF without journal self cites: 0.991; Ranking: 120 among 165 journals in medicine, general and internal; and Quartile category: Q3. The WJCC's CiteScore for 2019 is 0.3 and Scopus CiteScore rank 2019: General Medicine is 394/529.

**RESPONSIBLE EDITORS FOR THIS ISSUE**

Production Editor: Jia-Hui Li; Production Department Director: Yu-Jie Ma; Editorial Office Director: Jin-Li Wang.

**NAME OF JOURNAL**

*World Journal of Clinical Cases*

**ISSN**

ISSN 2307-8960 (online)

**LAUNCH DATE**

April 16, 2013

**FREQUENCY**

Thrice Monthly

**EDITORS-IN-CHIEF**

Dennis A Bloomfield, Sandro Vento, Bao-Gan Peng

**EDITORIAL BOARD MEMBERS**

<https://www.wjgnet.com/2307-8960/editorialboard.htm>

**PUBLICATION DATE**

March 16, 2021

**COPYRIGHT**

© 2021 Baishideng Publishing Group Inc

**INSTRUCTIONS TO AUTHORS**

<https://www.wjgnet.com/bpg/gerinfo/204>

**GUIDELINES FOR ETHICS DOCUMENTS**

<https://www.wjgnet.com/bpg/GerInfo/287>

**GUIDELINES FOR NON-NATIVE SPEAKERS OF ENGLISH**

<https://www.wjgnet.com/bpg/gerinfo/240>

**PUBLICATION ETHICS**

<https://www.wjgnet.com/bpg/GerInfo/288>

**PUBLICATION MISCONDUCT**

<https://www.wjgnet.com/bpg/gerinfo/208>

**ARTICLE PROCESSING CHARGE**

<https://www.wjgnet.com/bpg/gerinfo/242>

**STEPS FOR SUBMITTING MANUSCRIPTS**

<https://www.wjgnet.com/bpg/GerInfo/239>

**ONLINE SUBMISSION**

<https://www.f6publishing.com>



## Inadvertent globe penetration during retrobulbar anesthesia: A case report

Ying Dai, Tao Sun, Jun-Fang Gong

**ORCID number:** Ying Dai 0000-0002-5828-366X; Tao Sun 0000-0001-7641-7089; Jun-Fang Gong 0000-0002-8028-1628.

**Author contributions:** Sun T collected the data of the case and performed vitreoretinal surgery; Dai Y and Sun T drafted the manuscript; Gong JF reviewed the manuscript and provided constructive input; All authors read and approved final manuscript.

**Informed consent statement:**

Written informed consent was obtained from the patient for publication of this case report and any accompanying images.

**Conflict-of-interest statement:** The authors declare that they have no competing interests.

**CARE Checklist (2016) statement:**

The authors have read the CARE Checklist (2016), and the manuscript was prepared and revised according to the CARE Checklist (2016).

**Open-Access:** This article is an open-access article that was selected by an in-house editor and fully peer-reviewed by external reviewers. It is distributed in accordance with the Creative Commons Attribution NonCommercial (CC BY-NC 4.0)

**Ying Dai, Tao Sun, Jun-Fang Gong,** Department of Ophthalmology, The Fourth Affiliated Hospital of Nantong University/The First People's Hospital of Yancheng, Yancheng 224000, Jiangsu Province, China

**Corresponding author:** Tao Sun, MM, Chief Doctor, Surgeon, Department of Ophthalmology, The Fourth Affiliated Hospital of Nantong University/The First People's Hospital of Yancheng, No. 10 Nancheng River Road, Yancheng 224000, Jiangsu Province, China.

[suntao\\_13003@163.com](mailto:suntao_13003@163.com)

### Abstract

#### BACKGROUND

To report the possible reasons for needle perforation and complications related to perforation, as well as the clinical management of subretinal hemorrhage (SRH) during retrobulbar injection.

#### CASE SUMMARY

A 65-year-old female was scheduled to undergo pars plana vitrectomy (PPV) in her left eye for rhegmatogenous retinal detachment (RRD). During retrobulbar anesthesia, needle perforation of the globe occurred. Massive SRH in the inferotemporal quadrant together with vitreous hemorrhage were observed. The patient underwent PPV combined with retinotomy for removal of the massive SRH. After earlier surgical intervention, successful reattachment of the retina was achieved.

#### CONCLUSION

Inadvertent globe penetration during retrobulbar anesthesia is associated with a poor prognosis and may result in blindness. Timely detection and earlier intervention may be beneficial.

**Key Words:** Needle perforation; Globe penetration; Retrobulbar anesthesia; Subretinal hemorrhage; Pars plana vitrectomy; Retinotomy; Case report

©The Author(s) 2021. Published by Baishideng Publishing Group Inc. All rights reserved.

**Core Tip:** Inadvertent globe penetration during retrobulbar anesthesia is an uncommon



license, which permits others to distribute, remix, adapt, build upon this work non-commercially, and license their derivative works on different terms, provided the original work is properly cited and the use is non-commercial. See: <http://creativecommons.org/licenses/by-nc/4.0/>

**Manuscript source:** Unsolicited manuscript

**Specialty type:** Ophthalmology

**Country/Territory of origin:** China

**Peer-review report's scientific quality classification**

Grade A (Excellent): 0  
Grade B (Very good): 0  
Grade C (Good): C  
Grade D (Fair): 0  
Grade E (Poor): 0

**Received:** November 25, 2020

**Peer-review started:** November 26, 2020

**First decision:** December 24, 2020

**Revised:** January 2, 2021

**Accepted:** January 21, 2021

**Article in press:** January 21, 2021

**Published online:** March 16, 2021

**P-Reviewer:** Morya AK

**S-Editor:** Zhang H

**L-Editor:** Filipodia

**P-Editor:** Li JH



and serious complication. We present a case of needle perforation of the globe during retrobulbar injection. We discuss the results of our literature search for evidence related to reasons for needle perforation and complications related to perforation, as well as the clinical management of subretinal hemorrhage, in an effort to encourage ophthalmologists to pay more attention to this sight-threatening complication. If iatrogenic perforations occur, timely detection and earlier intervention may be beneficial for prognosis.

**Citation:** Dai Y, Sun T, Gong JF. Inadvertent globe penetration during retrobulbar anesthesia: A case report. *World J Clin Cases* 2021; 9(8): 2001-2007

**URL:** <https://www.wjgnet.com/2307-8960/full/v9/i8/2001.htm>

**DOI:** <https://dx.doi.org/10.12998/wjcc.v9.i8.2001>

## INTRODUCTION

As a common procedure in ophthalmic practice, retrobulbar injection is performed to deliver agents to the muscle pyramid for anesthesia or treatment. It is generally used for pain relief caused by glaucoma, surgical anesthesia, and postoperative treatment to reduce inflammation and prevent infection. As an invasive practice, retrobulbar injection carries risk for globe perforation, retrobulbar hemorrhage, temporary amaurosis, and life-threatening respiratory arrest<sup>[1]</sup>. The complications related to globe perforation include retinal toxicity, choroidal hemorrhage, vitreous hemorrhage (VH), retinal tear, retinal detachment (RD), proliferative vitreoretinopathy (PVR)<sup>[1,2]</sup>. We present a case of subretinal hemorrhage (SRH) due to inadvertent globe perforation during retrobulbar injection. We discuss the results of our literature search for evidence related to reasons for needle perforation and complications related to perforation and the clinical management of SRH in an effort to encourage ophthalmologists to pay more attention to this sight-threatening complication.

## CASE PRESENTATION

### Chief complaints

A 65-year-old female came to our department with a complaint of severe vision impairment in her left eye for 10 d.

### History of present illness

At 10 d before admission, the patient complained of severe vision impairment and dark shadows in the visual field. No symptoms of pain, soreness, or redness in the left eye were described. No history of trauma was reported. During these 10 d, the patient did not receive any treatment.

### History of past illness

The patient had a history of hypertension for 2 years, which was controlled by oral antihypertensive agents. She had no history of eye surgery or high myopia.

### Personal and family history

The patient had no significant personal or family history.

### Physical examination

At the time of her admission, the patient underwent a detailed ophthalmic examination that included measurements of preoperative visual acuity and intraocular pressure (IOP), as well as anterior segment evaluation with a slit-lamp microscope and a dilated fundus examination. (Table 1). The axial length of the globe was 22.97 mm.

### Laboratory examinations

Serum laboratory testing, electrocardiography, and chest X-ray were normal.

**Table 1 Clinical characteristics of the patient**

Clinical characteristics	Right eye	Left eye
Preoperative visual acuity	20/400	FC/BE
IOP (mmHg)	13 mmHg	12 mmHg
Anterior segment evaluation	Cataract	Cataract
Fundus examination	Macular hole, retinal break	RRD with two quadrants, macula off detachment, two retinal breaks

IOP: Intraocular pressure; RRD: Rhegmatogenous retinal detachment.

### Imaging examinations

Fundus photography (Figure 1A) and optical coherence tomography (OCT) (Figure 1B and C) revealed this patient had rhegmatogenous retinal detachment (RRD) that extended over two quadrants and included the macula, with retinal breaks at 4 and 7 o'clock on the globe's equator.

## FINAL DIAGNOSIS

RRD was diagnosed.

## TREATMENT

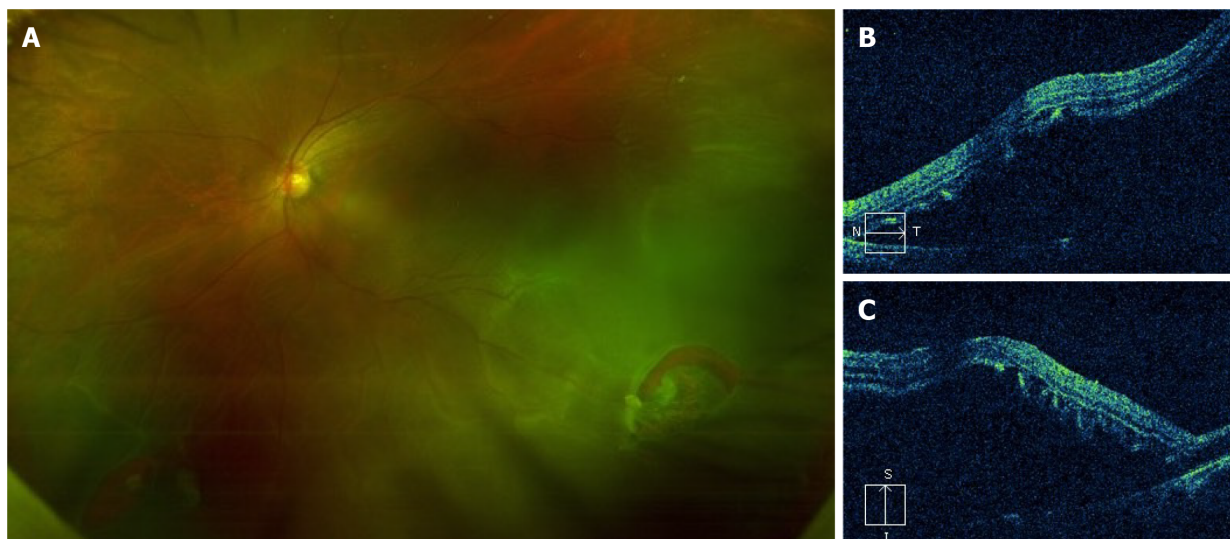
This patient was scheduled to undergo pars plana vitrectomy (PPV) on her left eye due to RRD. The treating ophthalmologist noticed some resistance during retrobulbar anesthesia, at the time of needle insertion. Before the injection of ropivacaine, the patient felt severe pain. Subsequently, we observed subconjunctival hemorrhage and an altered red reflex. We considered the possibility of inadvertent globe penetration during retrobulbar injection. An experienced senior ophthalmologist re-administered retrobulbar anesthesia. Three cannulas for PPV were established at 4.0 mm from the corneoscleral limbus in the inferotemporal, superotemporal, and superonasal quadrants. With the help of a noncontact wide-angle viewing system, massive SRH and VH were observed in the inferotemporal quadrant. Needle perforation of the globe during retrobulbar injection was confirmed.

During PPV, we found it was difficult to remove the SRH from the site of retinal break. Thus, it was appropriate to enlarge the retinal break and perform retinotomy for removal of the massive SRH. This procedure involves the use of heavy liquids to flatten the retina and laser photocoagulation in the areas surrounding the retinal breaks and tear. The position of needle entry was approximately 4 disc diameters temporal to the optic disc. After air/fluid exchange and laser photocoagulation, 4.5 mL of silicone oil was injected into the left eye. This patient underwent phacoemulsification, implantation of an intraocular lens, PPV, retinotomy, removal of the SRH, air/fluid exchange, laser photocoagulation, and silicone oil injection.

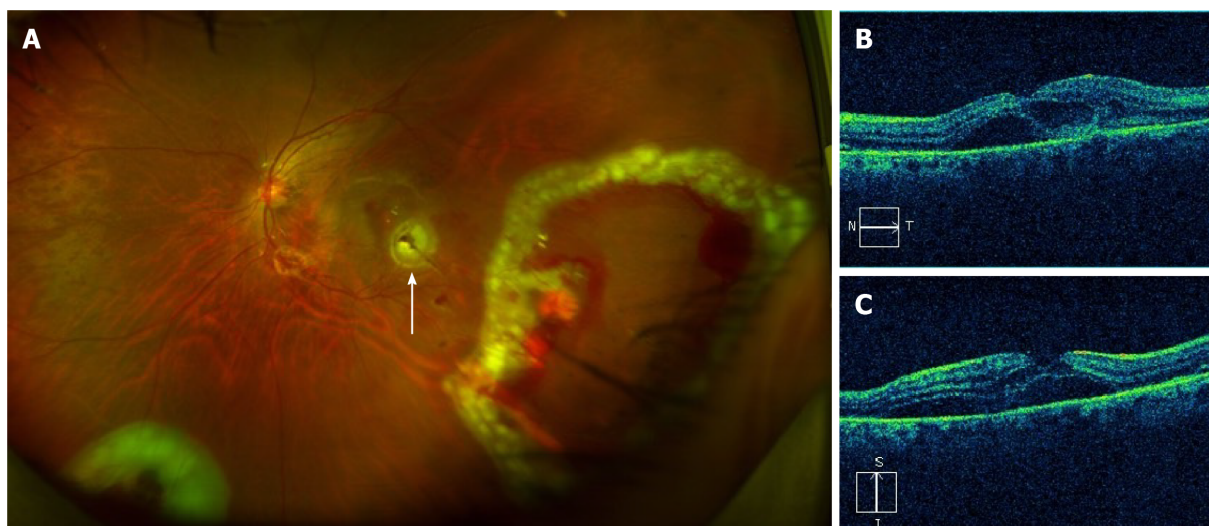
## OUTCOME AND FOLLOW-UP

After earlier surgical intervention, successful reattachment of the retina was achieved. On the third postoperative day, fundus photography revealed an attached retina, the position of needle entry, endo-laser spots and minor hemorrhage (Figure 2). At 4 wk postoperatively, the patient's best-corrected visual acuity (BCVA) improved to 20/250. Further fundus examination showed that the retina remained flat and that the minor hemorrhage had disappeared (Figure 3). At 3 mo, the patient's BCVA recovered to 20/200. At 5 mo after PPV, the patient underwent silicone oil removal. During the subsequent 6 mo follow-up, the retina remained flat.





**Figure 1 Fundus photography and optical coherence tomography obtained before surgery.** A: Before surgery, dilated fundus examination showed rhegmatogenous retinal detachment extending over two quadrants and macula-off detachment in the left eye. Retinal breaks at 4 and 7 o' clock on the globe's equator were noted; B and C: Optical coherence tomography showed macula-off detachment in the left eye.



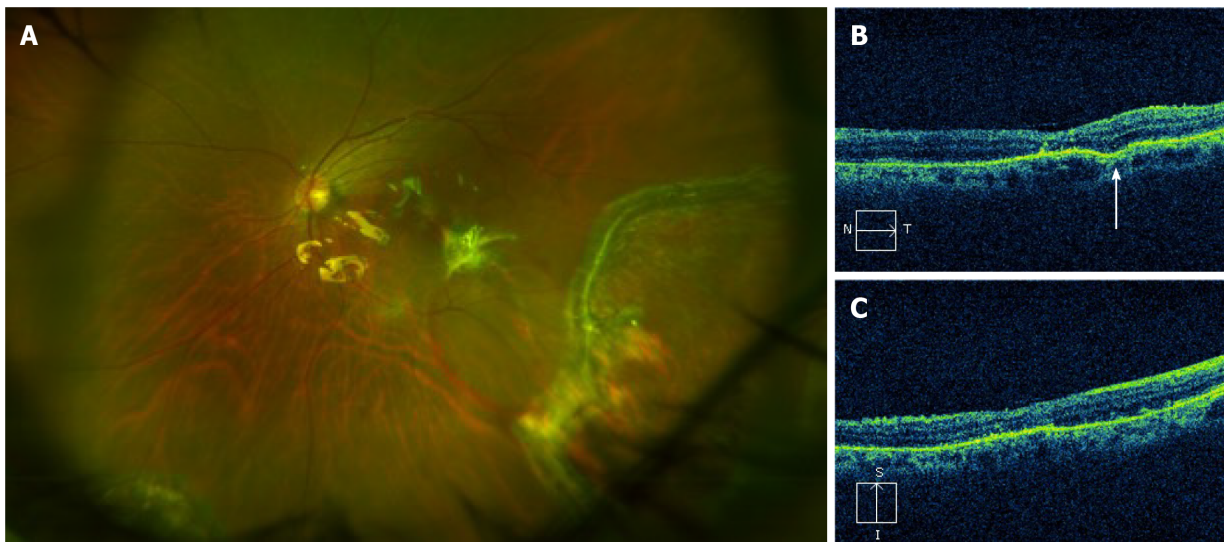
**Figure 2 Fundus photography and optical coherence tomography obtained on the third postoperative day.** A: On the third postoperative day, fundus photography revealed the re-attached retina, the position of needle entry (white arrow), endo-laser spots, and minor hemorrhage; B and C: Optical coherence tomography revealed a small amount of fluid between the neuroepithelial layer of the retina and the retina pigment epithelium.

## DISCUSSION

Inadvertent globe penetration during retrobulbar injection is an uncommon and serious complication of ophthalmic surgery that is associated with a poor prognosis and, sometimes, blindness. The complications associated with globe penetration include retinal tear, retinal toxicity, choroidal hemorrhage, SRH, VH, RD, and PVR<sup>[1,2]</sup>.

The reported incidence of ocular perforation during retrobulbar anesthesia is approximately 0.075%<sup>[3,4]</sup>. Scleral perforation associated with retrobulbar anesthesia is more common than scleral perforation associated with peribulbar anesthesia<sup>[2]</sup>. The perforation rate of peribulbar anesthesia is 0.0062%, so the technique is considered safer, but peribulbar anesthesia is less effective than retrobulbar anesthesia<sup>[2,3]</sup>. When this complication is recognized, the patient may feel a sharp pain, accompanied by a sudden loss of vision<sup>[5]</sup>. Early signs of this serious complication include increased IOP and an abnormal red reflex<sup>[5]</sup>. Usually, needle perforation of the globe requires surgical intervention, such as laser photocoagulation or vitreoretinal surgery.

The causes of inadvertent globe penetration during retrobulbar injection include: The use of long and sharp disposable needles; incorrect angle of needle insertion; poor



**Figure 3 Fundus photography and optical coherence tomography obtained 4 wk postoperatively.** A: Fundus examination revealed the flat retina and disappearance of the minor hemorrhage; B and C: Optical coherence tomography revealed that the structure of the macula had returned to normal. A scar (white arrow) was observed in the retinal pigment epithelium layer on the temporal side of the macula.

patient cooperation during surgery; previous history of a scleral buckling operation; high myopia<sup>[3]</sup>. In order to avoid ocular perforation, general anesthesia is a better alternative for uncooperative patients, such as children or those with neurosis or psychosis. Previous research indicates that highly myopic eyes with longer axial length have higher risk of globe perforation during local anesthesia<sup>[2]</sup>. The risk of perforation is 10- to 30-fold higher in highly myopic eyes with axial length  $\geq 26.0$  mm that are otherwise normal<sup>[2]</sup>. To reduce the risk of globe penetration in highly myopic eyes, it is advisable to use B-ultrasound examination to exclude staphyloma at the injection site preoperatively. Recently, Foad *et al*<sup>[6]</sup> explored the accuracy and safety of real-time ultrasound-guided retrobulbar regional anesthesia, as compared with blind technique, for cataract surgery. Foad *et al*<sup>[6]</sup> used the Siemens® ACUSON X600™ Ultrasound System. Ultrasound-guided retrobulbar regional anesthesia allows for real-time visualization as the needle advances and as local anesthetic spreads<sup>[6]</sup>. Foad *et al*<sup>[6]</sup> reported that ultrasound-guided retrobulbar injection may decrease risk for sight-threatening or life-threatening complications. However, our patients had no high-risk factors, and in this case, one possible explanation was that the younger surgeon lacked experience, resulting in an incorrect angle of needle insertion.

Iatrogenic perforations may result in iatrogenic retinal tears. In cases of iatrogenic retinal tears without RD or VH, treatment should include laser photocoagulation or cryotherapy. Iatrogenic retinal tears are mostly located in the posterior part of the equator, and inferotemporal breaks are more common<sup>[7]</sup>. The iatrogenic tear in this case was consistent with this pattern of localization. In cases of the inadvertent intravitreal injection of local anesthetic agents, IOP may suddenly increase, sometimes resulting in central retinal artery occlusion<sup>[7]</sup>. Medications vary in terms of their retinal toxicity. Liang *et al*<sup>[8]</sup> previously investigated the toxicity of various concentrations of intravitreal lidocaine, bupivacaine, and a combination of both in animal models. Reversible changes were observed on electroretinography. No permanent histologic abnormalities were observed<sup>[8]</sup>. In line with this result, after intravitreally injecting lidocaine (concentration  $< 0.2\%$ ), no obvious functional or histological changes were noted in the cornea or retina of rabbits<sup>[9]</sup>. Olmez *et al*<sup>[10]</sup> explored the effect of intravitreal ropivacaine on retinal thickness and integrity in animal models. More extensive retinal thinning was observed in eyes injected with 0.1 mL of 1% ropivacaine, compared with eyes injected with 0.1 mL of 0.75% or 0.5% ropivacaine<sup>[10]</sup>. The mean total retinal thickness was lower in the ropivacaine group than in controls. Histopathological analysis revealed structural abnormalities in the retinas of eyes that received 0.1 mL of 0.75% or 1% ropivacaine<sup>[10]</sup>. The authors hypothesized that the toxic effects of intravitreal ropivacaine on animal retinas were concentration dependent<sup>[10]</sup>. In this situation, surgical options, such as PPV, should be considered to minimize the retinal toxicity caused by medication.

Perforation signs, such as VH, SRH, and RD were noted. In our case, massive SRH in the inferotemporal quadrant and VH were observed. We sought to determine

whether the SRH required surgical intervention. SRH may contribute to photoreceptor damage and vision loss through the following three mechanisms: Toxicity, traction effects, and barrier effects<sup>[11]</sup>. During the absorption of SRH, the engulfed erythrocytes are metabolized, and hemosiderin is converted to ferritin<sup>[11]</sup>. The released iron has toxic effects on retinal and choriocapillaris circulation, resulting in photoreceptor and retinal pigment epithelium (RPE) apoptosis<sup>[11]</sup>. The second mechanism of retinal damage is traction caused by the SRH<sup>[11]</sup>. During clot retraction, fibrin may contribute to retinal traction<sup>[11]</sup>. To the best of our knowledge, the RPE is responsible for the transfer of nutrients and metabolites<sup>[11]</sup>. Furthermore, retinal damage secondary to SRH and the final visual prognosis are time dependent<sup>[11]</sup>. In addition to SRH duration, SRH thickness is associated with the final visual outcome<sup>[11]</sup>. In this case, earlier surgical drainage of the SRH appeared to be necessary and was performed to minimize toxin- and barrier-mediated damage.

Currently, various techniques are available for the surgical drainage of SRH, such as pneumatic displacement and PPV combined with retinotomy and tissue plasminogen activator (tPA)-assisted PPV<sup>[12]</sup>. Retinotomy for clot extraction may result in mechanical damage to the retina and aggravate proliferation. For large and massive SRH, tPA treatment alone is usually insufficient for dissolving the clot<sup>[11]</sup>. Although tremendous advances in vitreoretinal surgical techniques for the management of SRH have been made over recent decades, there is still no consensus on the optimal approach. In terms of treatment, the preferred approach depends on the duration, size, thickness, and location of the SRH, as well as surgeon preference. For small SRH, the risk-benefit profile suggests that the conservative approach may achieve a satisfactory prognosis<sup>[12]</sup>. For massive SRH, vitreoretinal specialists are in favor of surgical drainage<sup>[12]</sup>. Given the massive SRH in this RRD patient, PPV combined with retinotomy was carried out. Because there was enough space between the neurosensory retina and the RPE in this case of RRD, there was less risk for mechanical damage to the retina during the retinotomy for clot extraction. In the future, large randomized controlled trials should be conducted to better evaluate the safety and efficacy of various options for the removal of SRH.

## CONCLUSION

To avoid iatrogenic perforations during local anesthesia, it may be advisable for surgeons to use blunt needles with length of less than 35.0 mm<sup>[2]</sup>. For retrobulbar anesthesia, 3-4 mL of anesthetic agents should be enough for vitreoretinal surgery. During injection, patients should gaze straight ahead or in the superonasal direction<sup>[2]</sup>. Of course, before any ophthalmic procedure, the surgeon must consider the patient's detailed information, such as axial length, to select the appropriate anesthetic approach. Moreover, the risks of retrobulbar anesthesia must be explained to the patient. If iatrogenic perforations occur, timely detection and earlier intervention may be beneficial for prognosis.

## REFERENCES

- 1 **Han Y**, Lam HH, Stewart JM. Endophthalmitis due to inadvertent globe penetration during retrobulbar injection of saline solution for laser in situ keratomileusis. *J Cataract Refract Surg* 2009; **35**: 1132-1133 [PMID: 19465301 DOI: 10.1016/j.jcrs.2009.01.032]
- 2 **Schrader WF**, Schargus M, Schneider E, Josifova T. Risks and sequelae of scleral perforation during peribulbar or retrobulbar anesthesia. *J Cataract Refract Surg* 2010; **36**: 885-889 [PMID: 20494757 DOI: 10.1016/j.jcrs.2009.12.029]
- 3 **Wadood AC**, Dhillon B, Singh J. Inadvertent ocular perforation and intravitreal injection of an anesthetic agent during retrobulbar injection. *J Cataract Refract Surg* 2002; **28**: 562-565 [PMID: 11973111 DOI: 10.1016/s0886-3350(01)01075-6]
- 4 **Ramsay RC**, Knobloch WH. Ocular perforation following retrobulbar anesthesia for retinal detachment surgery. *Am J Ophthalmol* 1978; **86**: 61-64 [PMID: 677234 DOI: 10.1016/0002-9394(78)90016-8]
- 5 **Tran KD**, Crane AM, Flynn HW Jr. Management of inadvertent needle penetration resulting in subretinal triamcinolone acetonide and retinal detachment. *Am J Ophthalmol Case Rep* 2018; **10**: 288-289 [PMID: 29780955 DOI: 10.1016/j.ajoc.2018.04.010]
- 6 **Foad AZ**, Mansour MA, Ahmed MB, Elgamel HR, Ibrahim HEE, Elawamy A. Real-time ultrasound-guided retrobulbar block vs blind technique for cataract surgery (pilot study). *Local Reg Anesth* 2018; **11**: 123-128 [PMID: 30584353 DOI: 10.2147/LRA.S178771]



- 7 **Gadkari SS.** Evaluation of 19 cases of inadvertent globe perforation due to periocular injections. *Indian J Ophthalmol* 2007; **55**: 103-107 [PMID: [17322598](#) DOI: [10.4103/0301-4738.30702](#)]
- 8 **Liang C, Peyman GA, Sun G.** Toxicity of intraocular lidocaine and bupivacaine. *Am J Ophthalmol* 1998; **125**: 191-196 [PMID: [9467446](#) DOI: [10.1016/s0002-9394\(99\)80091-9](#)]
- 9 **Nishide T, Kadonosono K, Itoh N, Yazama F, Endoh Y, Sawada H, Ohno S.** The Effect of Intraocular Lidocaine in White Rabbit Eyes. *Jpn J Ophthalmol* 2000; **44**: 569 [PMID: [11033141](#) DOI: [10.1016/s0021-5155\(00\)00237-9](#)]
- 10 **Olmez G, Soker Cakmak S, Ipek Soker S, Nergiz Y, Yildiz F.** Effects of intravitreal ropivacaine on retinal thickness and integrity in the guinea pig. *Curr Ther Res Clin Exp* 2005; **66**: 394-400 [PMID: [24672138](#) DOI: [10.1016/j.curtheres.2005.08.005](#)]
- 11 **Hochman MA, Seery CM, Zarbin MA.** Pathophysiology and management of subretinal hemorrhage. *Surv Ophthalmol* 1997; **42**: 195-213 [PMID: [9406367](#) DOI: [10.1016/s0039-6257\(97\)00089-1](#)]
- 12 **Yiu G, Mahmoud TH.** Subretinal hemorrhage. *Dev Ophthalmol* 2014; **54**: 213-222 [PMID: [25196772](#) DOI: [10.1159/000360469](#)]



Published by **Baishideng Publishing Group Inc**  
7041 Koll Center Parkway, Suite 160, Pleasanton, CA 94566, USA

**Telephone:** +1-925-3991568

**E-mail:** [bpgoffice@wjgnet.com](mailto:bpgoffice@wjgnet.com)

**Help Desk:** <https://www.f6publishing.com/helpdesk>

<https://www.wjgnet.com>

