

Celiac plexus neurolysis in pancreatic cancer: The endoscopic ultrasound approach

Andrada Seicean

Andrada Seicean, Regional Institute of Gastroenterology and Hepatology Cluj-Napoca, University of Medicine and Pharmacy "Iuliu Hatieganu", 400162 Cluj-Napoca, Romania

Author contributions: Seicean A solely wrote this manuscript. Correspondence to: Andrada Seicean, MD, PhD, Associate Professor, Regional Institute of Gastroenterology and Hepatology Cluj-Napoca, University of Medicine and Pharmacy "Iuliu Hatieganu", Croitorilor Street 19-21, 400162 Cluj-Napoca, Romania. andradasicean@yahoo.com

Telephone: +40-74-4332107 Fax: +40-26-4431758

Received: October 3, 2013 Revised: November 1, 2013

Accepted: November 18, 2013

Published online: January 7, 2014

© 2014 Baishideng Publishing Group Co., Limited. All rights reserved.

Key words: Endoscopic ultrasound; Celiac neurolysis; Pancreas; Cancer; Pain

Core tip: Endoscopic ultrasound-guided celiac plexus neurolysis should be considered as the adjunct method to standard pain management. It moderately reduces pain in pancreatic cancer, without eliminating it. Nearly all patients need to continue opioid use, often at a constant dose. The central technique is easy to perform, but intraganglia injection seems to give better results. This review focuses on methods of celiac neurolysis, with details about endoscopic ultrasound-guided celiac plexus neurolysis, indications and outcomes with regard to efficacy and safety, novel techniques, and predictors of pain response.

Abstract

Pain in pancreatic cancer is often a major problem of treatment. Administration of opioids is frequently limited by side effects or insufficient analgesia. Endoscopic ultrasound-guided celiac plexus neurolysis (EUS-CPN) represents an alternative for the palliative treatment of visceral pain in patients with pancreatic cancer. This review focuses on the indications, technique, outcomes of EUS-CPN and predictors of pain relief. EUS-CPN should be considered as the adjunct method to standard pain management. It moderately reduces pain in pancreatic cancer, without eliminating it. Nearly all patients need to continue opioid use, often at a constant dose. The effect on quality of life is controversial and survival is not influenced. The approach could be done in the central position of the celiac axis, which is easy to perform, or in the bilateral position of the celiac axis, with similar results in terms of pain alleviation. The EUS-CPN with multiple intraganglia injection approach seems to have better results, although extended studies are still needed. Further trials are required to enable more confident conclusions regarding timing, quantity of alcohol injected and the method of choice. Severe complications have rarely been reported, and great care should be taken in choosing the site of alcohol injection.

Seicean A. Celiac plexus neurolysis in pancreatic cancer: The endoscopic ultrasound approach. *World J Gastroenterol* 2014; 20(1): 110-117 Available from: URL: <http://www.wjg-net.com/1007-9327/full/v20/i1/110.htm> DOI: <http://dx.doi.org/10.3748/wjg.v20.i1.110>

INTRODUCTION

The incidence of pancreatic cancer has increased over the last decade^[1,2]. Few of the patients are diagnosed at a resectable stage (12%-20%)^[3,4] and vascular resection during duodenopancreatectomy increases the 30-d post-operative morbidity and mortality rate^[5]. For pancreatic cancer patients, the standardized net survival at 5 years is 6% for men and 10% for women^[6]. Thus, palliative treatment is crucial in management. In this context, one of the most important symptoms to treat is pain. In the initial phase, the pain is visceral, but with disease progression, somatic pain may occur, especially due to the peri-

pancreatic invasion of neural structures or muscles. Medicinal palliation of pain from pancreatic cancer begins with non-opioid drugs, such as paracetamol, stepping up to opioids, such as tramadol, and, eventually, more powerful opioids, such as morphine or fentanyl. However, the dosage of opioid medication sometimes reaches a limit level due to side effects, such as nausea, constipation, somnolence, addiction, confusion or respiratory depression, and failure in achieving adequate analgesia. In these situations, neurodestructive methods involving the main pancreatic pain pathways, such as celiac block or thoracoscopic splanchnicectomy, seem efficient.

The celiac “plexus” is the largest plexus of the sympathetic nervous system, innervating the upper abdominal organs (pancreas, diaphragm, liver, spleen, adrenal glands, kidneys, abdominal aorta, mesentery, stomach, small bowel, ascending colon and the proximal portion of the transverse colon). The celiac plexus is situated within the retroperitoneal space posterior to the stomach and pancreas, close to the celiac axis, and it is separated from the vertebral column by the crush of the diaphragm. It comprises a dense network of ganglia around the aorta, with considerable variability in size (0.5–4.5 cm), number^[7–11] and position (from the T12–L1 disc space to the middle of the L2 vertebral body). The left celiac plexus is typically located more caudally than its counterpart on the right. Celiac neurolysis may target either the plexus or the ganglia.

The preganglionic sympathetic fibres of the celiac plexus are grouped into the greater (T5–10), lesser (T10–11) and the least (T12) splanchnic nerves, and the plexus also receives parasympathetic fibres from the celiac branch of the right vagus nerve. All of these fibres are interrupted during thoracoscopic splanchnicectomy performed under general anaesthesia (Figure 1).

This review focuses on the following aspects: methods of celiac plexus neurolysis, with details about endoscopic ultrasound-guided celiac plexus neurolysis (EUS-CPN), indications and outcomes, including efficacy, predictors of pain response, safety and novel techniques.

CELIAC PLEXUS NEUROLYSIS

This involves chemical destruction of celiac ganglia and corresponding neural pathways by injecting dehydrated alcohol into the network of the celiac plexus. The result is moderate neuronal degeneration associated with residual fibrosis^[7].

The initial method involved a posterior approach, accomplished under guidance by fluoroscopy or computed tomography (CT). The pain level at 12 wk after the procedure was significantly lower than with systemic analgesic therapy^[8]. Unfortunately, in some cases the pleura or neural structures were accidentally touched by the needle, with subsequent development of serious side effects such as pneumothorax and paraplegia, respectively^[8].

As a consequence, the anterior approach came to be considered a better option for CPN, accomplished either

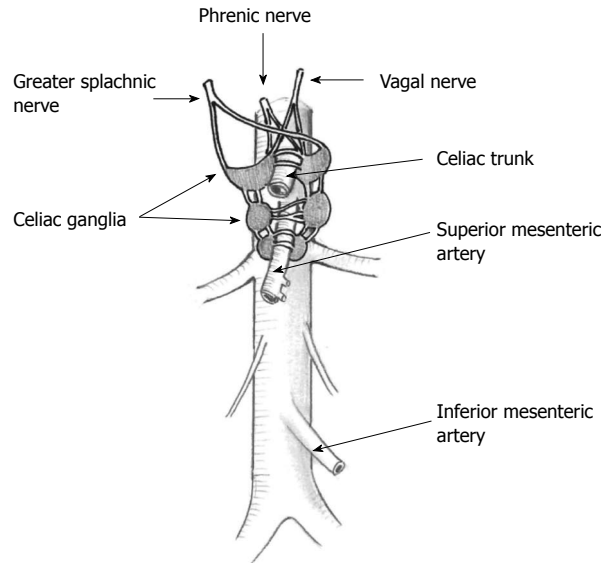


Figure 1 Anatomy of the celiac area (courtesy of Dr. Gombosiu C).

transcutaneously under ultrasound (US) guidance (developed in 1995^[9]), CT guidance or endoscopic US (EUS) guidance (introduced in 1996^[10]) or, more invasively, by means of surgery. More recently, the laparoscopic technique has been implemented^[11,12].

The advantages of the EUS approach are the fine orientation of the needle above or lateral to the celiac trunk and the real-time performance of the procedure, under Doppler control of vessel interposition. In addition, the technique is easy, requiring only 2–3 min immediately after the staging or sampling of an inoperable pancreatic tumour. Better results can be expected owing to the better orientation of the needle, compared to the US or CT approach, and the real-time accomplishment of the procedure.

The technique consists of preprocedural hydration with 500 mL saline, followed by CPN performed with the patient in the left lateral position, under either general anaesthesia with propofol, or deep intravenous sedation with 2–4 mg of midazolam. Some endosonographers favour antibiotic prophylaxis, avoiding a retroperitoneal abscess^[13–16], although alcohol is considered to be a bactericidal agent^[17]. Bacterial translocation from the gut can be reduced by performing a single needle pass and by avoiding simultaneous gastric acid suppression treatment^[17,18]. After colour Doppler assessment of vessel–gut interposition, a therapeutic linear-array echo-endoscope is used and the puncture site is chosen. Proximity to the diaphragm should be avoided, because of the potential for immediate pain due to the spread of alcohol. The devices used are 22-G or 19-G needles, or preferably fenestrated 20-G needles especially designed for EUS-CPN (Cook Medical, Winston-Salem, NC, United States). Recently, the use of a forward-viewing echo-endoscope has been reported in five patients^[19].

For central injection, which is easier to perform, the needle is advanced above the celiac trunk, in the space

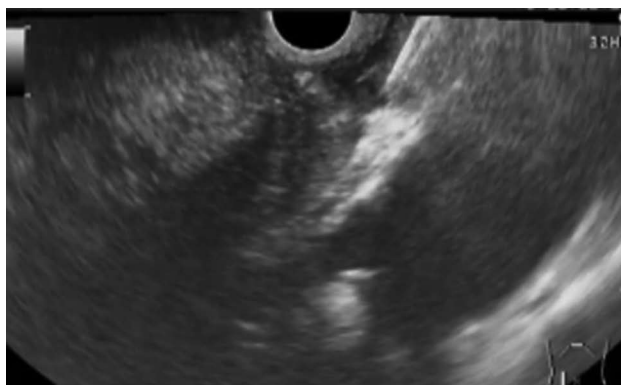

Figure 2 Endoscopic ultrasound images showing the position of the needle above the celiac plexus.

between the aorta and the origin of the celiac axis. If bilateral injection is chosen, the echo-endoscope, situated above the celiac axis, is rotated to one side until the origin of the celiac axis is no longer seen, and half of the entire solution is injected; the procedure is then repeated on the opposite side.

When ganglia are targeted, the echo-endoscope is rotated clockwise and celiac ganglia are found above the celiac trunk, alongside the trunk, and below the trunk, just above the superior mesenteric artery takeoff^[20]. The ganglia are small hypoechoic nodules with hyperechoic foci in the center. Sometimes their interconnection can be seen. In large ganglia, thin linear hypoechoic lines arising from the edges of the ganglion are suggestive of small neural fibres^[20]. The rate of ganglia detection varies between 79%-89% and it may also vary among endosonographers (65%-97%)^[21-23]. As many ganglia as possible should be injected. The actual recommendations are to start the injection in the central part of the ganglia for those within 1 cm in diameter, or in the deepest part of the larger ganglia, and to perform the injection during the withdrawal of the needle, but only inside the ganglia^[24].

Following the Doppler assessment of the area, aspiration is performed in order to rule out placement of the needle inside a vessel, which may lead to severe complications (Figure 2). Any lack of resistance during injection might suggest that the vascular space has been punctured; the needle should be withdrawn, and the aspiration test repeated. The injection starts with 3-10 mL of a local analgesic to prevent transient pain exacerbation induced by the neurolytic agent. Lidocaine 1%-2%^[13,14,20,25], or a better analgesic such as bupivacaine 0.25%-0.75%^[10,23,26-28], can be used. Subsequently, 10-20 mL of a neurolytic agent (98% dehydrated alcohol) is injected and a hyperechoic cloud is seen in the area of the needle tip as the substance spreads.

All patients must be kept under close observation for 2 h after the procedure, to monitor blood pressure, heart rate and temperature, and to identify any immediate complications.

Technical difficulties may occur in some cases because the anatomical landmarks could not be properly visual-

ized. For example, during the bilateral technique, after one side injection, the alcohol spreads and impedes the view of the opposite side. Sometimes, the celiac plexus region cannot be reached with the needle, as is the case in patients with cachexia who have very little fat tissue around the aorta, or when the diaphragm insertion is too close to the celiac trunk.

Other approaches such as thoracoscopic splanchnicectomy, EUS-guided direct celiac ganglion irradiation with ¹²⁵I seeds or radiofrequency ablation can be considered as alternative methods for celiac plexus destruction^[11,29,30].

INDICATIONS OF EUS-CPN

The NCCN guidelines, version 1.2013 for pancreatic adenocarcinoma, recommend EUS-CPN for the treatment of severe tumour-associated pain. This technique is useful especially when intolerable adverse effects of opioid therapy occur, such as drowsiness, delirium, dry mouth, anorexia, constipation, nausea and vomiting, or an analgesic “ceiling” is seen due to neurotoxicity. In the case of jaundice caused by an unresectable pancreatic head tumour, biliary drainage should be offered first, followed by open CPN if pain persists^[31].

Relative contraindications to EUS-CPN include difficult access due to anatomical distortion from previous surgery or congenital malformations. The absolute contraindications for EUS-CPN are the same as for any other invasive procedure: coagulopathy, platelets < 50000, and patients who are unable or unwilling to cooperate^[32].

OUTCOMES

Efficacy for EUS-CPN

The main goals when performing EUS-CPN are the alleviation of pain and the improvement of quality of life. This procedure added no benefits regarding survival in two randomized controlled trials^[13,27].

Although the quality of life was unchanged after CPN in one randomized trial^[16], there are reports of improvement of parameters of quality of life such as functional status, work capability, sleep, and enjoyment of leisure activities^[14,26]. The occurrence and duration of terminal delirium have also been reported as reduced after this procedure^[33].

The assessment of pain intensity in chronic cancer patients uses different measurement scales. Visual analogue scales have proved to be less suitable in old patients with opioid use, due to limited communication skills and cognitive impairment during the last days of life, making self-reporting of pain more difficult^[34]. Numerical rating scales are preferable in assessing cancer pain exacerbations to verbal rating scales^[35]. As a result, observation of pain-related behaviours and discomfort is indicated in patients with cognitive impairment, in order to assess the presence of pain^[36-38], and multidimensional questionnaires which evaluate the pain intensity together with other parameters of interference with pain are useful^[26].

Although the real benefit of EUS-CPN compared

Table 1 Pain relief and techniques used in patients with endoscopic ultrasound-guided celiac plexus neurolysis

Ref.	n	Pain evaluation	Technique of EUS-CPN	Follow-up period (wk)	Pain alleviation
Doi <i>et al</i> ^[23] 2013	68	Numeric rating scale	Ganglia <i>vs</i> central	1	73% <i>vs</i> 45%
Leblanc <i>et al</i> ^[14] 2013	20	Numeric rating scale	Ganglia + central	6	90%
Seicean <i>et al</i> ^[26] 2013	32	Brief pain inventory	Central	2	75%
Wiechowska-Kozłowska <i>et al</i> ^[25] 2012	29	Numeric rating scale	Central + bilateral	8-12	76%
Wyse <i>et al</i> ^[27] 2011	48	Likert scale	Bilateral	12	60.70%
LeBlanc <i>et al</i> ^[13] 2011	50	Numeric rating scale	Central <i>vs</i> bilateral	14	69% <i>vs</i> 81%
Iwata <i>et al</i> ^[39] 2011	47	Visual analogue scale	Central	1	68.10%
Ascunce <i>et al</i> ^[20] 2011	64	Numeric rating scale	Ganglia or bilateral	1	50%
Sakamoto <i>et al</i> ^[40] 2010	67	Visual analogue scale	Under celiac trunk	4	33%-93%
Sahai <i>et al</i> ^[41] 2009	160	Visual analogue scale	Central <i>vs</i> bilateral	1	70% <i>vs</i> 45%
Ramirez-Luna <i>et al</i> ^[42] 2008	10	Visual analogue scale	Central	4	72.20%
Levy <i>et al</i> ^[15] 2008	17	General descriptors	Ganglia	4	94%
Tran <i>et al</i> ^[28] 2006	10	Numeric rating scale	Central	Not stated	70%
Gunaratnam <i>et al</i> ^[43] 2001	58	Visual analogue scale	Bilateral	24	78%
Wiersema <i>et al</i> ^[10] 1996	30	Visual analogue scale	Bilateral	12	79%-88%

EUS-CPN: Endoscopic ultrasound-guided celiac plexus neurolysis.

to placebo has not been studied, pain relief after the procedure varies between 45%-94% in different papers (Table 1). Two subsequent meta-analyses showed a mean rate of pain alleviation of 72%-80%, with a much lower rate of complete pain response^[24,42,43]. However, many of the patients still required the same dose of analgesic and EUS-CPN should be considered as an adjunct method to standard pain management^[24]. The post-neurolytic residual pain could be related to non-visceral pain, due to the invasion of the muscles or surrounding connective tissue, but factors concerning the technique used (type of technique, quantity of alcohol injected, timing of the procedure) have not been extensively studied.

The type of technique used for obtaining the best response is still controversial. Eleven studies on the central or bilateral technique have been published to date, showing a pain alleviation rate of 50%-88% at 1-14 wk after the procedure (Table 1). Bilateral technique, used in six of these studies, was associated with a rate of pain alleviation of 45%-88%, while central technique showed 68%-72% alleviation. To date, only one randomized controlled trial has compared the central and bilateral techniques of EUS-CPN and showed no difference in duration of pain relief (11 wk *vs* 14 wk), complete pain relief (2/29 patients *vs* 2/21 patients) or reduction in pain medication (9/29 patients *vs* 7/21 patients)^[13]. The choice between the central or bilateral technique remains difficult, depending on the personal skills and the experience of every endosonographer. Our experience has showed good results with the central technique, which we consider easier to perform^[26].

EUS-guided direct ganglia neurolysis, first reported by Levy in 2007, showed much better results in terms of pain alleviation (7 of 17 patients, 94%) at 2-4 wk; the known side effects - diarrhoea or hypotension - were noted. For the first time, long-lasting postprocedural pain relief (2.2 d) was reported in 7 of 17 patients^[15]. One-week follow-up of pain alleviation showed better results for EUS-CPN at the celiac ganglia compared to EUS-CPN at the celiac trunk region using bilateral injection

(67.5% *vs* 33%)^[14]. However, this technique has been used in only a few studies. One randomized controlled trial compared direct ganglia neurolysis with central neurolysis. The positive response rate at day 7 and the complete response rate were higher in the ganglia neurolysis group (75.5% *vs* 45.5% and 50% *vs* 18.2%, respectively)^[23].

Early vs late injection

A randomized, double-blind, controlled trial in 96 patients showed that CPN was effective in pain reduction at 1-mo and 3-mo follow-up, but opioid consumption was constant - although it increased in the control group^[27]. In the group of patients without radiochemotherapy, pain was significantly reduced and the need for increased opioids was prevented. In patients with radiochemotherapy, on the other hand, pain was significantly reduced only at 3 mo of follow-up. The authors concluded that this technique would be effective only for patients who refuse, or are ineligible for radiochemotherapy^[27].

Amount of ethanol injection

The majority of cases have been performed using 10-20 mL alcohol^[13-15,26,27]. Only one study compared the results when 10 or 20 mL alcohol injection was used during intraganglia or central injection and no difference in pain alleviation was noted^[14].

Repetitiveness of the procedure

The benefit of repeated EUS-CPN was studied in 24 patients and results are less encouraging. The rate of successful pain relief was much lower than for the first EUS-CPN (29% *vs* 67% at 1-mo follow-up), and disease progression was a factor which limited the response^[44].

EFFICACY FOR PERCUTANEOUS CPN AND ALTERNATIVE APPROACHES

Two important meta-analyses of the percutaneous approach have been published. The first one included 1117

Table 2 Immediate and late complications reported for endoscopic ultrasound-guided celiac plexus neurolysis in adenocarcinoma patients

Ref.	No. of procedures	Complications	Indication	Technique	Substance
Muscatiello <i>et al</i> ^[16]	1	Retroperitoneal abscess	PC	Not stated	Alcohol + bupivacaine
Gimeno-García <i>et al</i> ^[49]	1	Celiac axis infarction, kidney, splenic, hepatic infarction, death	PC	Bilateral	Alcohol + bupivacaine
Fujii <i>et al</i> ^[50]	1	Anterior spinal cord infarction with lower paraplegia	PC	Ganglia + central	Alcohol + bupivacaine
Wiechowska-Kozłowska <i>et al</i> ^[25]	29	Hypotension-1 Pain exacerbation-2 Transient diarrhoea-3	PC	Bilateral + central	Alcohol + bupivacaine
Mittal <i>et al</i> ^[53]	1	Anterior spinal cord infarct with lower paraplegia	PC	Ganglia + central	Alcohol + bupivacaine
O'Toole <i>et al</i> ^[17]	31	Hypotension-1	PC	Bilateral	Alcohol + bupivacaine
Levy <i>et al</i> ^[15]	17	Pain exacerbation-2	PC	Ganglia	Alcohol + bupivacaine
Leblanc <i>et al</i> ^[14]	20	Lightheadedness-1 Transient diarrhea-2 Transient nausea and vomiting-3	PC	Central + ganglia	Alcohol + bupivacaine
Doi <i>et al</i> ^[23]	68	Transient hypotension-3 Upper gastrointestinal bleeding-1 Pain exacerbation-17 Transient diarrhea-5 Inebriation-2	PC	Central + ganglia	Alcohol + bupivacaine
Jang <i>et al</i> ^[52]	1	Liver and splenic infarction, ischemia of the stomach and small bowel	Pancreatic metastasis	Central	Alcohol + bupivacaine + triamcinolone

PC: Plexus neurolysis in adenocarcinoma.

patients, 63% of them with pancreatic cancer, in whom bilateral X-ray-, US- or CT-guided neurolysis was performed. Pain alleviation at 2 wk was excellent; 90% relief was recorded at 3 mo after the procedure, and 70%-90% of patients experienced pain relief right up to the time of death. Transient pain was seen in most of the patients under study (96% in two of the studies analysed), transient diarrhoea in 44%, and transient hypotension in 38%. Severe neurological side effects were noted in 5 of the 268 patients (1%)^[45]. A second meta-analysis, including 358 patients with CT-guided CPN, from six randomized controlled trials, showed a limited advantage in pain alleviation at 4 and 8 wk (0.42 and 0.44, respectively, on a visual analogue scale of 0-10), but opioid consumption was significantly lower, with fewer side effects^[46].

To date, only one published randomized trial has compared the efficacy of CPN and thoracoscopic splanchnicectomy, and the results were not significant compared to the control medical management group. The main limitation of the study was the small number of patients included in each arm of the study^[11].

EUS-guided direct celiac ganglion irradiation with ¹²⁵I seeds was performed in 23 patients, with significant pain reduction 2 wk later. Initial pain exacerbation was seen in 26% of the patients, but no major complications occurred up to the time of death^[29].

Radiofrequency ablations of pancreatic mass and celiac plexus have been reported as successful in the treatment of chronic pain^[30].

Predictors of response rate

A retrospective study compared the results of ganglia injection with those of non-direct ganglia injection (40

vs 24 patients). The median number of visualized ganglia was two. The pain response rate was 50% at 1 wk, 77% at 30 d, and opioid consumption was 57% lower at 1-wk follow-up. Pain alleviation was significantly lower for patients in whom the ganglia were not visualized, and it was also lower, albeit not significantly so, for tumours located in the body or tail of the pancreas, for large tumours and for patients with severe pain at presentation^[20].

A second study of 47 patients with central-injection CPN showed 68% pain alleviation at 1 wk. The predictors of poor pain alleviation were direct invasion of celiac ganglia and left diffusion of the neurolytic agent^[37].

Safety

Many complications have been described for EUS celiac block indicated for chronic pancreatitis, and some of these complications have been seen in EUS-CPN for pancreatic cancer, such as transient diarrhoea (4%-15%) and transient hypotension (1%)^[14,18,47,48] or alcohol intolerance. Nowadays, it is considered that the potential immediate complications are rare, such as hypotension, tachycardia, initial pain enhancement, severe bleeding and paraplegia. The late side effects include diarrhoea, hypotension, fever and paraplegia^[48].

Recently, severe complications of EUS-CPN have been reported in individual cases, and endosonographers should be aware of them (Table 2). Permanent lower paraplegia, due to spinal cord infarction, was noted in one patient; the mechanism was considered to be alcohol diffusion *via* the left T12 intercostal artery towards the anterior spinal artery, or vasospasm caused by alcohol or acute thrombosis due to injection of a high volume into the celiac area^[50-53]. Injury of the lumbar artery leading

into the artery of Adamkiewicz could be involved. This major artery originates from the aorta, varies in position from T7 to L4, supplies the lower two-thirds of the anterior spinal artery, and it is anatomically closely related to the celiac ganglion^[53]. The clinical manifestations, reported 14 h after the procedure, comprised motor weakness, decreased pain and temperature sensation below T7-L1, and detrusor atony. Prolonged periprocedural hypotension may have played a part^[53]. Extreme caution should be taken concerning the placement of the needle tip, including Doppler US examination of the area and aspiration before injection.

Another complication was thrombosis of the celiac trunk, with wall thickening and bubble-like pneumatosis of the stomach, duodenum, jejunum, ileal loops and ascending colon. Signs of hepatic infarction of segment I and III, near-total right kidney, as well as splenic infarction were discovered, and the evolution was fatal. The explanation was the sclerosing effect of alcohol after injection^[49]. Alcohol neurolysis for treatment of chronic pancreatitis has been recorded as leading to necrosis and perforation of the stomach and aorta with lethal outcome^[51], as well as splenic, gastric and pancreatic infarction^[52]. The infarction of the liver, spleen, stomach, and proximal small bowel after celiac neurolysis for pancreatic metastasis was reported in one case, as vasospasm resulted from the diffusion of ethanol into the celiac artery^[54].

Retroperitoneal abscesses have been previously noted in chronic pancreatitis patients with triamcinolone injection, especially after gastric acid suppression therapy^[17,18], but one case has been described in pancreatic cancer, too^[16]. However, antibiotic prophylaxis has not been carried out in many studies^[23,25-28].

Initial pain exacerbation after EUS-CPN was reported in up to 29%-34% of cases^[15,22]. Previous studies considered initial pain exacerbation as a sign of greater pain relief at follow-up^[15], but this was not confirmed in further studies^[22].

Novel techniques

In the attempt to improve the technique, Sakamoto *et al*^[40] used broad plexus neurolysis near the superior mesenteric artery with the aim of administering the neurolytic agent to a larger number of ganglia. The authors checked the spread of the neurolytic agent around the celiac axis and showed that the new technique achieved neurolysis in five or six areas in a higher proportion of patients than the previous method. With regard to the pain levels at 7 d and 30 d, significant reduction was obtained for five and six areas of neurolytic agent diffusion, but not for three or four areas. However, this study had some limitations: there were methodological problems, the physicians' experience increased during the study, not all patients (only 60 of 67) had pancreatic cancer, and the overall success rate for pain alleviation was only 50% at 30 d, the lowest rate ever reported at that time^[38].

CONCLUSION

EUS-CPN should be considered as an adjunct method to standard pain management. It moderately eases pain in pancreatic cancer without eliminating it completely. Nearly all patients need to continue opioid use, often at a constant dose. Multicentre, randomized, controlled trials are required to provide more reliable conclusions on timing, quantity of alcohol injected and the method of choice. Until then, in the light of the severe complications reported recently, great care should be taken when choosing the site of alcohol injection.

REFERENCES

- 1 **Bosetti C**, Bertuccio P, Malvezzi M, Levi F, Chatenoud L, Negri E, La Vecchia C. Cancer mortality in Europe, 2005-2009, and an overview of trends since 1980. *Ann Oncol* 2013; **24**: 2657-2671 [PMID: 23921790 DOI: 10.1093/annonc/mdt301]
- 2 **Simard EP**, Ward EM, Siegel R, Jemal A. Cancers with increasing incidence trends in the United States: 1999 through 2008. *CA Cancer J Clin* 2012; Epub ahead of print [PMID: 22281605 DOI: 10.3322/caac.20141]
- 3 **Nienhuijs SW**, van den Akker SA, de Vries E, de Hingh IH, Visser O, Lemmens VE. Nationwide improvement of only short-term survival after resection for pancreatic cancer in the Netherlands. *Pancreas* 2012; **41**: 1063-1066 [PMID: 22617713 DOI: 10.1097/MPA.0b013e31824c3dbf]
- 4 **Paulson AS**, Tran Cao HS, Tempero MA, Lowy AM. Therapeutic advances in pancreatic cancer. *Gastroenterology* 2013; **144**: 1316-1326 [PMID: 23622141 DOI: 10.1053/j.gastro.2013.01.078]
- 5 **Castleberry AW**, White RR, De La Fuente SG, Clary BM, Blazer DG, McCann RL, Pappas TN, Tyler DS, Scarborough JE. The impact of vascular resection on early postoperative outcomes after pancreaticoduodenectomy: an analysis of the American College of Surgeons National Surgical Quality Improvement Program database. *Ann Surg Oncol* 2012; **19**: 4068-4077 [PMID: 22932857 DOI: 10.1245/s10434-012-2585-y]
- 6 **Jooste V**, Grosclaude P, Remontet L, Launoy G, Baldi I, Molinié F, Arveux P, Bossard N, Bouvier AM, Colonna M. Unbiased estimates of long-term net survival of solid cancers in France. *Int J Cancer* 2013; **132**: 2370-2377 [PMID: 23001495 DOI: 10.1002/ijc.27857]
- 7 **Vranken JH**, Zuurmond WW, Van Kemenade FJ, Dzijic M. Neurohistopathologic findings after a neurolytic celiac plexus block with alcohol in patients with pancreatic cancer pain. *Acta Anaesthesiol Scand* 2002; **46**: 827-830 [PMID: 12139538 DOI: 10.1034/j.1399-6576.2002.460712.x]
- 8 **Wong GY**, Schroeder DR, Carns PE, Wilson JL, Martin DP, Kinney MO, Mantilla CB, Warner DO. Effect of neurolytic celiac plexus block on pain relief, quality of life, and survival in patients with unresectable pancreatic cancer: a randomized controlled trial. *JAMA* 2004; **291**: 1092-1099 [PMID: 14996778 DOI: 10.1001/jama.291.9.1092]
- 9 **Greiner L**, Ulatowski L, Prohm P. [Sonographically guided and intraoperative alcohol block of the celiac ganglia in conservatively uncontrollable cancer-induced epigastric pain]. *Ultraschall Med* 1983; **4**: 57-59 [PMID: 6648478 DOI: 10.1055/s-2007-1013039]
- 10 **Wiersema MJ**, Wiersema LM. Endosonography-guided celiac plexus neurolysis. *Gastrointest Endosc* 1996; **44**: 656-662 [PMID: 8979053 DOI: 10.1016/S0016-5107(96)70047-0]
- 11 **Johnson CD**, Berry DP, Harris S, Pickering RM, Davis C, George S, Imrie CW, Neoptolemos JP, Sutton R. An open randomized comparison of clinical effectiveness of protocol-driven opioid analgesia, celiac plexus block or thoracoscopic

- splanchnicectomy for pain management in patients with pancreatic and other abdominal malignancies. *Pancreatol* 2009; **9**: 755-763 [PMID: 20090396 DOI: 10.1159/000199441]
- 12 **Allen PJ**, Chou J, Janakos M, Strong VE, Coit DG, Brennan MF. Prospective evaluation of laparoscopic celiac plexus block in patients with unresectable pancreatic adenocarcinoma. *Ann Surg Oncol* 2011; **18**: 636-641 [PMID: 20953910 DOI: 10.1245/s10434-010-1372-x]
 - 13 **LeBlanc JK**, Al-Haddad M, McHenry L, Sherman S, Juan M, McGreevy K, Johnson C, Howard TJ, Lillemoe KD, DeWitt J. A prospective, randomized study of EUS-guided celiac plexus neurolysis for pancreatic cancer: one injection or two? *Gastrointest Endosc* 2011; **74**: 1300-1307 [PMID: 22000795 DOI: 10.1016/j.gie.2011.07.073]
 - 14 **Leblanc JK**, Rawl S, Juan M, Johnson C, Kroenke K, McHenry L, Sherman S, McGreevy K, Al-Haddad M, Dewitt J. Endoscopic Ultrasound-Guided Celiac Plexus Neurolysis in Pancreatic Cancer: A Prospective Pilot Study of Safety Using 10mL versus 20mL Alcohol. *Diagn Ther Endosc* 2013; **2013**: 327036 [PMID: 23365492 DOI: 10.1155/2013/327036]
 - 15 **Levy MJ**, Topazian MD, Wiersema MJ, Clain JE, Rajan E, Wang KK, de la Mora JG, Gleeson FC, Pearson RK, Pelaez MC, Petersen BT, Vege SS, Chari ST. Initial evaluation of the efficacy and safety of endoscopic ultrasound-guided direct ganglia neurolysis and block. *Am J Gastroenterol* 2008; **103**: 98-103 [PMID: 17970834 DOI: 10.1111/j.1572-0241.2007.01607.x]
 - 16 **Muscattello N**, Panella C, Pietrini L, Tonti P, Ierardi E. Complication of endoscopic ultrasound-guided celiac plexus neurolysis. *Endoscopy* 2006; **38**: 858 [PMID: 17001583 DOI: 10.1055/s-2006-925382]
 - 17 **O'Toole TM**, Schumlewitz N. Complication rates of EUS-guided celiac plexus blockade and neurolysis: results of a large case series. *Endoscopy* 2009; **41**: 593-597 [PMID: 19588286 DOI: 10.1055/s-0029-1214868]
 - 18 **Gress F**, Schmitt C, Sherman S, Ciaccia D, Ikenberry S, Lehman G. Endoscopic ultrasound-guided celiac plexus block for managing abdominal pain associated with chronic pancreatitis: a prospective single center experience. *Am J Gastroenterol* 2001; **96**: 409-416 [PMID: 11232683]
 - 19 **Eloubeidi MA**. Initial evaluation of the forward-viewing echoendoscope prototype for performing fine-needle aspiration, Tru-cut biopsy, and celiac plexus neurolysis. *J Gastroenterol Hepatol* 2011; **26**: 63-67 [PMID: 21175795 DOI: 10.1111/j.1440-1746.2010.06409.x]
 - 20 **Ascunce G**, Ribeiro A, Reis I, Rocha-Lima C, Sleeman D, Merchan J, Levi J. EUS visualization and direct celiac ganglia neurolysis predicts better pain relief in patients with pancreatic malignancy (with video). *Gastrointest Endosc* 2011; **73**: 267-274 [PMID: 21295640 DOI: 10.1016/j.gie.2010.10.029]
 - 21 **Gleeson FC**, Levy MJ, Papachristou GI, Pelaez-Luna M, Rajan E, Clain JE, Topazian MD. Frequency of visualization of presumed celiac ganglia by endoscopic ultrasound. *Endoscopy* 2007; **39**: 620-624 [PMID: 17549662 DOI: 10.1055/s-2007-966337]
 - 22 **Ha TI**, Kim GH, Kang DH, Song GA, Kim S, Lee JW. Detection of celiac ganglia with radial scanning endoscopic ultrasonography. *Korean J Intern Med* 2008; **23**: 5-8 [PMID: 18363273 DOI: 10.3904/kjim.2008.23.1.5]
 - 23 **Doi S**, Yasuda I, Kawakami H, Hayashi T, Hisai H, Irisawa A, Mukai T, Katanuma A, Kubota K, Ohnishi T, Ryozaawa S, Hara K, Itoi T, Hanada K, Yamao K. Endoscopic ultrasound-guided celiac ganglia neurolysis vs. celiac plexus neurolysis: a randomized multicenter trial. *Endoscopy* 2013; **45**: 362-369 [PMID: 23616126 DOI: 10.1055/s-0032-1326225]
 - 24 **Levy MJ**, Chari ST, Wiersema MJ. Endoscopic ultrasound-guided celiac neurolysis. *Gastrointest Endosc Clin N Am* 2012; **22**: 231-47, viii [PMID: 22632946 DOI: 10.1016/j.giec.2012.04.003]
 - 25 **Wiechowska-Kozłowska A**, Boer K, Wójcicki M, Milkiewicz P. The efficacy and safety of endoscopic ultrasound-guided celiac plexus neurolysis for treatment of pain in patients with pancreatic cancer. *Gastroenterol Res Pract* 2012; **2012**: 503098 [PMID: 22474439]
 - 26 **Seicean A**, Cainap C, Gulei I, Tantau M, Seicean R. Pain palliation by endoscopic ultrasound-guided celiac plexus neurolysis in patients with unresectable pancreatic cancer. *J Gastrointest Liver Dis* 2013; **22**: 59-64 [PMID: 23539392]
 - 27 **Wyse JM**, Carone M, Paquin SC, Usatii M, Sahai AV. Randomized, double-blind, controlled trial of early endoscopic ultrasound-guided celiac plexus neurolysis to prevent pain progression in patients with newly diagnosed, painful, inoperable pancreatic cancer. *J Clin Oncol* 2011; **29**: 3541-3546 [PMID: 21844506 DOI: 10.1200/JCO.2010.32.2750]
 - 28 **Tran QN**, Urayama S, Meyers FJ. Endoscopic ultrasound-guided celiac plexus neurolysis for pancreatic cancer pain: a single-institution experience and review of the literature. *J Support Oncol* 2006; **4**: 460-462, 464; discussion 460-462 [PMID: 17080734]
 - 29 **Wang KX**, Jin ZD, Du YQ, Zhan XB, Zou DW, Liu Y, Wang D, Chen J, Xu C, Li ZS. EUS-guided celiac ganglion irradiation with iodine-125 seeds for pain control in pancreatic carcinoma: a prospective pilot study. *Gastrointest Endosc* 2012; **76**: 945-952 [PMID: 22841501 DOI: 10.1016/j.gie.2012.05.032]
 - 30 **Cavallini M**, La Torre M, Citone M, Rossi M, Rebonato A, Nava AK, Ferrari L, Salvi PF, Ziparo V. A novel approach in surgical palliation for unresectable pancreatic cancer with untreatable chronic pain: radiofrequency ablation of pancreatic mass and celiac plexus. *Am Surg* 2010; **76**: E108-E109 [PMID: 21513624]
 - 31 **NCCN guidelines 2013 for pancreatic adenocarcinoma**. Available from: URL: http://www.nccn.org/professionals/physician_gls/pdf/pancreatic.pdf
 - 32 **Soweid AM**, Azar C. Endoscopic ultrasound-guided celiac plexus neurolysis. *World J Gastrointest Endosc* 2010; **2**: 228-231 [PMID: 21160938 DOI: 10.4253/wjge.v2.i6.228]
 - 33 **Eisenberg E**, Carr DB, Chalmers TC. Neurolytic celiac plexus block for treatment of cancer pain: a meta-analysis. *Anesth Analg* 1995; **80**: 290-295 [PMID: 7818115]
 - 34 **Arcidiacono PG**, Calori G, Carrara S, McNicol ED, Testoni PA. Celiac plexus block for pancreatic cancer pain in adults. *Cochrane Database Syst Rev* 2011; **(3)**: CD007519 [PMID: 21412903 DOI: 10.1002/14651858.CD007519.pub2]
 - 35 **Arai YC**, Nishihara M, Kobayashi K, Kanazawa T, Hayashi N, Tohyama Y, Nishida K, Arakawa M, Suzuki C, Kinoshita A, Kondo M, Matsubara S, Yokoe N, Hayashi R, Ohta A, Sato J, Ushida T. Neurolytic celiac plexus block reduces occurrence and duration of terminal delirium in patients with pancreatic cancer. *J Anesth* 2013; **27**: 88-92 [PMID: 22990527 DOI: 10.1007/s00540-012-1486-3]
 - 36 **Jensen MP**, Karoly P. Self-report scales and procedures for assessing pain in adults. In: Turk DC, Melzack R. Handbook of pain assessment. New York: Guilford Press, 2001; 15-34
 - 37 **Brunelli C**, Zecca E, Martini C, Campa T, Fagnoni E, Bagnasco M, Lanata L, Caraceni A. Comparison of numerical and verbal rating scales to measure pain exacerbations in patients with chronic cancer pain. *Health Qual Life Outcomes* 2010; **8**: 42 [PMID: 20412579 DOI: 10.1186/1477-7525-8-42]
 - 38 **Ripamonti CI**, Santini D, Maranzano E, Berti M, Roila F. Management of cancer pain: ESMO Clinical Practice Guidelines. *Ann Oncol* 2012; **23** Suppl 7: vii139-vii154 [PMID: 22997447 DOI: 10.1093/annonc/mds233]
 - 39 **Iwata K**, Yasuda I, Enya M, Mukai T, Nakashima M, Doi S, Iwashita T, Tomita E, Moriwaki H. Predictive factors for pain relief after endoscopic ultrasound-guided celiac plexus neurolysis. *Dig Endosc* 2011; **23**: 140-145 [PMID: 21429019 DOI: 10.1111/j.1443-1661.2010.01046.x]
 - 40 **Sakamoto H**, Kitano M, Kamata K, Komaki T, Imai H, Chikugo T, Takeyama Y, Kudo M. EUS-guided broad plexus neurolysis over the superior mesenteric artery using a

- 25-gauge needle. *Am J Gastroenterol* 2010; **105**: 2599-2606 [PMID: 20823834 DOI: 10.1038/ajg.2010.339]
- 41 **Sahai AV**, Lemelin V, Lam E, Paquin SC. Central vs. bilateral endoscopic ultrasound-guided celiac plexus block or neurolysis: a comparative study of short-term effectiveness. *Am J Gastroenterol* 2009; **104**: 326-329 [PMID: 19174816 DOI: 10.1038/ajg.2008.64]
 - 42 **Ramirez-Luna MA**, Chavez-Tapia NC, Franco-Guzman AM, Garcia-Saenz-de Sicilia M, Tellez-Avila FI. Endoscopic ultrasound-guided celiac plexus neurolysis in patients with unresectable pancreatic cancer. *Rev Gastroenterol Mex* 2008; **73**: 63-67 [PMID: 19666248]
 - 43 **Gunaratnam NT**, Sarma AV, Norton ID, Wiersema MJ. A prospective study of EUS-guided celiac plexus neurolysis for pancreatic cancer pain. *Gastrointest Endosc* 2001; **54**: 316-324 [PMID: 11522971 DOI: 10.1067/mge.2001.117515]
 - 44 **Puli SR**, Reddy JB, Bechtold ML, Antillon MR, Brugge WR. EUS-guided celiac plexus neurolysis for pain due to chronic pancreatitis or pancreatic cancer pain: a meta-analysis and systematic review. *Dig Dis Sci* 2009; **54**: 2330-2337 [PMID: 19137428 DOI: 10.1007/s10620-008-0651-x]
 - 45 **Kaufman M**, Singh G, Das S, Concha-Parra R, Erber J, Micames C, Gress F. Efficacy of endoscopic ultrasound-guided celiac plexus block and celiac plexus neurolysis for managing abdominal pain associated with chronic pancreatitis and pancreatic cancer. *J Clin Gastroenterol* 2010; **44**: 127-134 [PMID: 19826273]
 - 46 **McGreevy K**, Hurley RW, Erdek MA, Aner MM, Li S, Cohen SP. The effectiveness of repeat celiac plexus neurolysis for pancreatic cancer: a pilot study. *Pain Pract* 2013; **13**: 89-95 [PMID: 22568823 DOI: 10.1111/j.1533-2500.2012.00557.x]
 - 47 **Hoffman BJ**. EUS-guided celiac plexus block/neurolysis. *Gastrointest Endosc* 2002; **56**: S26-S28 [PMID: 12297745 DOI: 10.1016/S0016-5107(02)70082-5]
 - 48 **Sakamoto H**, Kitano M, Komaki T, Imai H, Kamata K, Kudo M. Endoscopic ultrasound-guided neurolysis in pancreatic cancer. *Pancreatol* 2011; **11** Suppl 2: 52-58 [PMID: 21471704 DOI: 10.1159/000323513]
 - 49 **Gimeno-García AZ**, Elwassief A, Paquin SC, Sahai AV. Fatal complication after endoscopic ultrasound-guided celiac plexus neurolysis. *Endoscopy* 2012; **44** Suppl 2 UCTN: E267 [PMID: 22814913 DOI: 10.1055/s-0032-1309709]
 - 50 **Fujii L**, Clain JE, Morris JM, Levy MJ. Anterior spinal cord infarction with permanent paralysis following endoscopic ultrasound celiac plexus neurolysis. *Endoscopy* 2012; **44** Suppl 2 UCTN: E265-E266 [PMID: 22814912 DOI: 10.1055/s-0032-1309708]
 - 51 **Loeve US**, Mortensen MB. Lethal necrosis and perforation of the stomach and the aorta after multiple EUS-guided celiac plexus neurolysis procedures in a patient with chronic pancreatitis. *Gastrointest Endosc* 2013; **77**: 151-152 [PMID: 22624792 DOI: 10.1016/j.gie.2012.03.005]
 - 52 **Jang HY**, Cha SW, Lee BH, Jung HE, Choo JW, Cho YJ, Ju HY, Cho YD. Hepatic and splenic infarction and bowel ischemia following endoscopic ultrasound-guided celiac plexus neurolysis. *Clin Endosc* 2013; **46**: 306-309 [PMID: 23767046 DOI: 10.5946/ce.2013.46.3.306]
 - 53 **Mittal MK**, Rabinstein AA, Wijdicks EF. Pearls & oysters: Acute spinal cord infarction following endoscopic ultrasound-guided celiac plexus neurolysis. *Neurology* 2012; **78**: e57-e59 [PMID: 22371417 DOI: 10.1212/WNL.0b013e318248df51]
 - 54 **Ahmed HM**, Friedman SE, Henriques HF, Berk BS. End-organ ischemia as an unforeseen complication of endoscopic-ultrasound-guided celiac plexus neurolysis. *Endoscopy* 2009; **41** Suppl 2: E218-E219 [PMID: 19757362 DOI: 10.1055/s-0029-1214941]

P- Reviewers: Iglesias-Garcia J, Katanuma A, Meister T
S- Editor: Qi Y **L- Editor:** Logan S **E- Editor:** Zhang DN





Published by **Baishideng Publishing Group Co., Limited**
Flat C, 23/F., Lucky Plaza,
315-321 Lockhart Road, Wan Chai, Hong Kong, China
Fax: +852-65557188
Telephone: +852-31779906
E-mail: bpgoffice@wjgnet.com
<http://www.wjgnet.com>



ISSN 1007-9327



9 771007 932045