

World Journal of *Clinical Cases*

World J Clin Cases 2021 May 6; 9(13): 2951-3226



Contents

Thrice Monthly Volume 9 Number 13 May 6, 2021

REVIEW

- 2951 Patients with cirrhosis during the COVID-19 pandemic: Current evidence and future perspectives
Su HY, Hsu YC

MINIREVIEWS

- 2969 Immunotherapy for pancreatic cancer
Yoon JH, Jung YJ, Moon SH

ORIGINAL ARTICLE

Retrospective Study

- 2983 Scrotal septal flap and two-stage operation for complex hypospadias: A retrospective study
Chen S, Yang Z, Ma N, Wang WX, Xu LS, Liu QY, Li YQ
- 2994 Clinical diagnosis of severe COVID-19: A derivation and validation of a prediction rule
Tang M, Yu XX, Huang J, Gao JL, Cen FL, Xiao Q, Fu SZ, Yang Y, Xiong B, Pan YJ, Liu YX, Feng YW, Li JX, Liu Y
- 3008 Prognostic value of hemodynamic indices in patients with sepsis after fluid resuscitation
Xu HP, Zhuo XA, Yao JJ, Wu DY, Wang X, He P, Ouyang YH

Observational Study

- 3014 Updated Kimura-Takemoto classification of atrophic gastritis
Kotelevets SM, Chekh SA, Chukov SZ

SYSTEMATIC REVIEWS

- 3024 Systematic review and meta-analysis of the impact of deviations from a clinical pathway on outcomes following pancreatoduodenectomy
Karunakaran M, Jonnada PK, Barreto SG

META-ANALYSIS

- 3038 Early vs late cholecystectomy in mild gall stone pancreatitis: An updated meta-analysis and review of literature
Walayat S, Baig M, Puli SR

CASE REPORT

- 3048 Effects of intravascular laser phototherapy on delayed neurological sequelae after carbon monoxide intoxication as evaluated by brain perfusion imaging: A case report and review of the literature
Liu CC, Hsu CS, He HC, Cheng YY, Chang ST

- 3056** *Crumbs homolog 2* mutation in two siblings with steroid-resistant nephrotic syndrome: Two case reports
Lu J, Guo YN, Dong LQ
- 3063** Intracortical chondroma of the metacarpal bone: A case report
Yoshida Y, Anazawa U, Watanabe I, Hotta H, Aoyama R, Suzuki S, Nagura T
- 3070** Vancomycin-related convulsion in a pediatric patient with neuroblastoma: A case report and review of the literature
Ye QF, Wang GF, Wang YX, Lu GP, Li ZP
- 3079** Pulmonary arterial hyper-tension in a patient with hereditary hemorrhagic telangiectasia and family gene analysis: A case report
Wu J, Yuan Y, Wang X, Shao DY, Liu LG, He J, Li P
- 3090** Misdiagnosed dystrophic epidermolysis bullosa pruriginosa: A case report
Wang Z, Lin Y, Duan XW, Hang HY, Zhang X, Li LL
- 3095** Spontaneous coronary dissection should not be ignored in patients with chest pain in autosomal dominant polycystic kidney disease: A case report
Qian J, Lai Y, Kuang LJ, Chen F, Liu XB
- 3102** Sarcomatoid carcinoma of the pancreas — multimodality imaging findings with serial imaging follow-up: A case report and review of literature
Lim HJ, Kang HS, Lee JE, Min JH, Shin KS, You SK, Kim KH
- 3114** Acute pancreatitis and small bowel obstruction caused by a migratory gastric bezoar after dissolution therapy: A case report
Wang TT, He JJ, Liu J, Chen WW, Chen CW
- 3120** Intracardiac, pulmonary cement embolism in a 67-year-old female after cement-augmented pedicle screw instrumentation: A case report and review of literature
Liang TZ, Zhu HP, Gao B, Peng Y, Gao WJ
- 3130** Acute urinary retention in the first and second-trimester of pregnancy: Three case reports
Zhuang L, Wang XY, Sang Y, Xu J, He XL
- 3140** Sarcoidosis mimicking metastases in an echinoderm microtubule-associated protein-like 4 anaplastic lymphoma kinase positive non-small-lung cancer patient: A case report
Chen X, Wang J, Han WL, Zhao K, Chen Z, Zhou JY, Shen YH
- 3147** Three-dimensional printed talar prosthesis with biological function for giant cell tumor of the talus: A case report and review of the literature
Yang QD, Mu MD, Tao X, Tang KL
- 3157** Successful upgrade to cardiac resynchronization therapy for cardiac implantation-associated left subclavian vein occlusion: A case report
Zhong JY, Zheng XW, Li HD, Jiang LF

- 3163** Sodium-glucose co-transporter-2 inhibitor-associated euglycemic diabetic ketoacidosis that prompted the diagnosis of fulminant type-1 diabetes: A case report
Yasuma T, Okano Y, Tanaka S, Nishihama K, Eguchi K, Inoue C, Maki K, Uchida A, Uemura M, Suzuki T, D'Alessandro-Gabazza CN, Gabazza EC, Yano Y
- 3170** Perioperative massive cerebral stroke in thoracic patients: Report of three cases
Jian MY, Liang F, Liu HY, Han RQ
- 3177** Renal artery embolization in the treatment of urinary fistula after renal duplication: A case report and review of literature
Yang T, Wen J, Xu TT, Cui WJ, Xu J
- 3185** Clinical characteristics of intrahepatic biliary papilloma: A case report
Yi D, Zhao LJ, Ding XB, Wang TW, Liu SY
- 3194** Association between scrub typhus encephalitis and diffusion tensor tractography detection of Papez circuit injury: A case report
Kwon HG, Yang JH, Kwon JH, Yang D
- 3200** Alström syndrome with a novel mutation of *ALMS1* and Graves' hyperthyroidism: A case report and review of the literature
Zhang JJ, Wang JQ, Sun MQ, Xu D, Xiao Y, Lu WL, Dong ZY
- 3212** Laparoscopic uncontained power morcellation-induced dissemination of ovarian endodermal sinus tumors: A case report
Oh HK, Park SN, Kim BR
- 3219** Treatment of acute severe ulcerative colitis using accelerated infliximab regimen based on infliximab trough level: A case report
Garate ALSV, Rocha TB, Almeida LR, Quera R, Barros JR, Baima JP, Saad-Hossne R, Sassaki LY

ABOUT COVER

Editorial Board Member of *World Journal of Clinical Cases*, Rama R Vunnam, MBBS, MD, Assistant Professor, Department of Medicine, Penn State Health Milton S. Hershey Medical Center, Hershey, PA 17033, United States. rvunnam@pennstatehealth.psu.edu

AIMS AND SCOPE

The primary aim of *World Journal of Clinical Cases* (WJCC, *World J Clin Cases*) is to provide scholars and readers from various fields of clinical medicine with a platform to publish high-quality clinical research articles and communicate their research findings online.

WJCC mainly publishes articles reporting research results and findings obtained in the field of clinical medicine and covering a wide range of topics, including case control studies, retrospective cohort studies, retrospective studies, clinical trials studies, observational studies, prospective studies, randomized controlled trials, randomized clinical trials, systematic reviews, meta-analysis, and case reports.

INDEXING/ABSTRACTING

The WJCC is now indexed in Science Citation Index Expanded (also known as SciSearch®), Journal Citation Reports/Science Edition, Scopus, PubMed, and PubMed Central. The 2020 Edition of Journal Citation Reports® cites the 2019 impact factor (IF) for WJCC as 1.013; IF without journal self cites: 0.991; Ranking: 120 among 165 journals in medicine, general and internal; and Quartile category: Q3. The WJCC's CiteScore for 2019 is 0.3 and Scopus CiteScore rank 2019: General Medicine is 394/529.

RESPONSIBLE EDITORS FOR THIS ISSUE

Production Editor: Yan-Xia Xing, Production Department Director: Yun-Xiaoqian Wu, Editorial Office Director: Jin-Lai Wang.

NAME OF JOURNAL

World Journal of Clinical Cases

ISSN

ISSN 2307-8960 (online)

LAUNCH DATE

April 16, 2013

FREQUENCY

Thrice Monthly

EDITORS-IN-CHIEF

Dennis A Bloomfield, Sandro Vento, Bao-Gan Peng

EDITORIAL BOARD MEMBERS

<https://www.wjgnet.com/2307-8960/editorialboard.htm>

PUBLICATION DATE

May 6, 2021

COPYRIGHT

© 2021 Baishideng Publishing Group Inc

INSTRUCTIONS TO AUTHORS

<https://www.wjgnet.com/bpg/gerinfo/204>

GUIDELINES FOR ETHICS DOCUMENTS

<https://www.wjgnet.com/bpg/GerInfo/287>

GUIDELINES FOR NON-NATIVE SPEAKERS OF ENGLISH

<https://www.wjgnet.com/bpg/gerinfo/240>

PUBLICATION ETHICS

<https://www.wjgnet.com/bpg/GerInfo/288>

PUBLICATION MISCONDUCT

<https://www.wjgnet.com/bpg/gerinfo/208>

ARTICLE PROCESSING CHARGE

<https://www.wjgnet.com/bpg/gerinfo/242>

STEPS FOR SUBMITTING MANUSCRIPTS

<https://www.wjgnet.com/bpg/GerInfo/239>

ONLINE SUBMISSION

<https://www.f6publishing.com>



Successful upgrade to cardiac resynchronization therapy for cardiac implantation-associated left subclavian vein occlusion: A case report

Jin-Yan Zhong, Xiao-Wei Zheng, Heng-Dong Li, Long-Fu Jiang

ORCID number: Jin-Yan Zhong 0000-0003-2678-7932; Xiao-Wei Zheng 0000-0001-7338-5579; Heng-Dong Li 0000-0003-4528-8434; Long-Fu Jiang 0000-0003-1934-5618.

Author contributions: Zhong JY was a major contributor in writing the manuscript; Zheng XW managed routine follow-up visits, performed the operation, collected the patient information; Zhong JY analyzed and interpreted the patient data regarding the heart disease; Li HD and Jiang LF were major contributors in performing the operation; all authors read and approved the final manuscript.

Supported by The Ningbo Natural Science Foundation of China, No. 2019A610342; and the Ningbo Health Branding Subject Fund, No. PPXK2018-01.

Informed consent statement: Informed written consent was obtained from the patient for publication of this report and any accompanying images.

Conflict-of-interest statement: The authors declare that they have no competing interests.

CARE Checklist (2016) statement: The authors have read the CARE Checklist (2016), and the

Jin-Yan Zhong, Heng-Dong Li, Long-Fu Jiang, Department of Cardiology, Ningbo Second Hospital, Ningbo 315010, Zhejiang Province, China

Xiao-Wei Zheng, Department of Geriatrics, Ningbo First Hospital, Ningbo 315010, Zhejiang Province, China

Corresponding author: Heng-Dong Li, MM, Doctor, Department of Cardiology, Ningbo Second Hospital, No. 41 Northwest Street, Ningbo 315010, Zhejiang Province, China. lhdhldhdd@163.com

Abstract

BACKGROUND

Subclavian vein stenosis or occlusion may be caused by a transvenous pacemaker, which makes the reimplantation of a new pacemaker lead difficult. Transvenous pacemaker lead implantation-related subclavian vein occlusion may present difficulty with regard to cardiac resynchronization therapy (CRT) upgrade.

CASE SUMMARY

We report the case of a 46-year-old man who was admitted with total subclavian vein occlusion caused by a permanent pacemaker that had been implanted 2 years previously. We successfully treated this patient with an upgrade to a CRT pacemaker by utilizing transferable interventional coronary and radiological techniques. The patient recovered uneventfully during the follow-up period.

CONCLUSION

CRT upgrade is still a viable technique for the treatment of subclavian vein obstruction caused by previous pacemaker implantation.

Key Words: Subclavian vein obstruction; Cardiac resynchronization; Therapy; Pacemaker; Venoplasty; Radiological techniques; Case report

©The Author(s) 2021. Published by Baishideng Publishing Group Inc. All rights reserved.

Core Tip: Subclavian vein stenosis or occlusion may be caused by a transvenous

manuscript was prepared and revised according to the CARE Checklist (2016).

Open-Access: This article is an open-access article that was selected by an in-house editor and fully peer-reviewed by external reviewers. It is distributed in accordance with the Creative Commons Attribution NonCommercial (CC BY-NC 4.0) license, which permits others to distribute, remix, adapt, build upon this work non-commercially, and license their derivative works on different terms, provided the original work is properly cited and the use is non-commercial. See: <http://creativecommons.org/licenses/by-nc/4.0/>

Manuscript source: Unsolicited manuscript

Specialty type: Cardiac and cardiovascular systems

Country/Territory of origin: China

Peer-review report's scientific quality classification

Grade A (Excellent): 0
Grade B (Very good): B
Grade C (Good): 0
Grade D (Fair): 0
Grade E (Poor): 0

Received: November 30, 2020

Peer-review started: November 30, 2020

First decision: December 24, 2020

Revised: January 12, 2021

Accepted: February 12, 2021

Article in press: February 12, 2021

Published online: May 6, 2021

P-Reviewer: Kaypakli O

S-Editor: Zhang H

L-Editor: Webster JR

P-Editor: Wang LL



pacemaker, which makes the reimplantation of a new pacemaker lead difficult. Transvenous pacemaker lead implantation-related subclavian vein obstruction may present difficulty with regard to cardiac resynchronization therapy (CRT) upgrade. We successfully treated a patient who was admitted with total subclavian vein occlusion caused by a permanent pacemaker that had been implanted 2 years previously, with an upgrade to a CRT pacemaker by utilizing transferable interventional coronary and radiological techniques.

Citation: Zhong JY, Zheng XW, Li HD, Jiang LF. Successful upgrade to cardiac resynchronization therapy for cardiac implantation-associated left subclavian vein occlusion: A case report. *World J Clin Cases* 2021; 9(13): 3157-3162

URL: <https://www.wjgnet.com/2307-8960/full/v9/i13/3157.htm>

DOI: <https://dx.doi.org/10.12998/wjcc.v9.i13.3157>

INTRODUCTION

Implantation of pacemakers is a widely adopted treatment for cardiac arrhythmia. However, pacemaker implantation is associated with some complications including heart failure, lead dislodgment, lead failure, pericarditis, infection, skin erosion, hematoma, venous thrombosis, and malfunction^[1]. While rare, these complications may occur long after the implantation procedure^[2]. In particular, the etiology of 15%-45% of cases of venous thrombosis is attributed to implantation of a transvenous pacemaker, depending on the study cohorts^[3,4]. One form of venous thrombosis, subclavian vein obstruction, can cause difficulty in the re-implantation of new pacemaker leads, when needed to upgrade a transvenous pacemaker to a cardiac resynchronization therapy (CRT)-P or CRT-D. We report a patient who developed total subclavian vein occlusion caused by a permanent pacemaker that had been implanted 2 years previously. We successfully treated this patient with a CRT-P through transferable interventional coronary and radiological techniques.

CASE PRESENTATION

Chief complaints

The 46-year-old man presented with dyspnea on exertion upon admission.

History of present illness

The patient who had congestive heart failure was diagnosed with high-degree atrioventricular blockage after treatment of a permanent pacemaker in DDD mode (Medtronic) on January 1, 2018.

History of past illness

He started having dyspnea on exertion from time to time about 6 mo ago.

Personal and family history

He denied any family diseases.

Physical examination

The patient's blood pressure was 86/60 mmHg, and his heart rate was 60 bpm with right ventricular pacing.

Laboratory examinations

The patient had an elevated level of N terminal pro brain natriuretic peptide of 1653 pg/mL, indicating heart failure, which was classified as class II-III according to the New York Heart Association (NYHA) Classification of Heart Failure.

Imaging examinations

Echocardiography showed impaired left ventricular (LV) systolic motion with a LV

ejection fraction of 33%, a ventricular septum thickness of 4 mm (indicating atrophy), and a LV diameter of 69 mm (indicating LV dilation). The left atrium was also dilated with severe mitral regurgitation and mild tricuspid regurgitation. The patient also had moderate pulmonary hypertension. The ventricular pacing rhythm with QRS duration > 170 ms was recorded in the 12-lead electrocardiogram. The patient was diagnosed with complete obstruction of the left subclavian vein due to two leads previously implanted as revealed by venography (Figure 1).

History of medications

The patient was previously given diuretics, vasodilators, sacubitril-valsartan sodium tablets, β -blockers, and spironolactone for treatment of heart failure, following the current heart failure treatment guidelines.

FINAL DIAGNOSIS

As coronary angiography showed no coronary disease, and no tachycardia or atrial fibrillation were observed by Holter monitoring, we proposed a CRT-P upgrade for treatment of heart failure.

TREATMENT

A 0.035-in Terumo wire (Terumo Corporation, Tokyo, Japan) was introduced *via* a left subclavian puncture, but we could not advance the wire through the occluded region, even after switching to a Radifocus guidewire (Terumo Corporation) and a 0.018-in V-18 control wire (Boston Scientific Corporation, Boston, MA, United States). We then decided to re-canalize the left subclavian vein through femoral vein access. The atrial lead was gently pulled back with a counterclockwise rotation and stabilized in the right atrium without any anchoring forces. Proximally cut lead portions and the Radifocus guidewire tip were bundled together with a suture firmly 6 times (Figure 2A). An 8 French sheath was inserted into the right femoral vein, and a goose-neck snare was advanced to the lower edge of the right atrium (Figure 2B). The atrial lead tip was then snared and pulled into the 8 French femoral vein sheath for final retrieval (Figure 2C). Following the atrial lead body, the Radifocus guidewire passed the lesion. A Finewire catheter was then advanced over the wire, and the Radifocus guidewire was replaced by a 0.018-in V-18 control wire to provide additional support for balloon inflation. Next, we performed balloon venoplasty in the left subclavian vein using a balloon of 4.0 mm \times 60 mm (Bantam, Wexford, Ireland) and a balloon of 8.0 mm \times 80 mm (Abbott, Santa Clara, CA, United States) (Figure 2D). With the 9 French short sheath supports, we used a stiffer guidewire (Terumo Corporation) simultaneously to deliver an 8 French long sheath past the obstruction. Following that, the LV lead (Medtronic, Inc. Minneapolis, MN, United States) was implanted successfully. Before the LV lead implantation procedure, we attempted to insert the selected secure lead (model 3830, Medtronic, Inc.) into the left bundle branch area to narrow the QRS duration. Unfortunately, the condition of the lead was unstable, and all parameters were abnormal. We then implanted the selected secure lead (model 3830, Medtronic, Inc.) in the right atrium. The rest of the procedure was completed without any difficulty, and the time of pacemaker implantation was 240 min (Figure 2E and F).

OUTCOME AND FOLLOW-UP

The leads were stable with normal parameters and a narrow QRS during a routine follow-up visit. Fortunately, visible blood flow was observed on enhanced computed tomography. The cardiac function in this patient was NYHA functional class I.

DISCUSSION

Subclavian vein stenosis/occlusion is a known complication associated with implantation of a transvenous pacemaker^[3]. In the present case, the patient developed

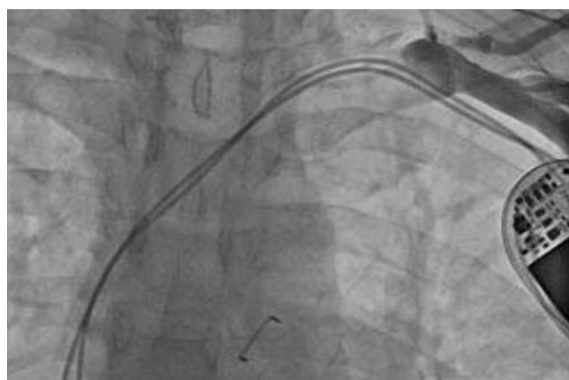

Figure 1 Venogram showing complete occlusion of the left subclavian vein.

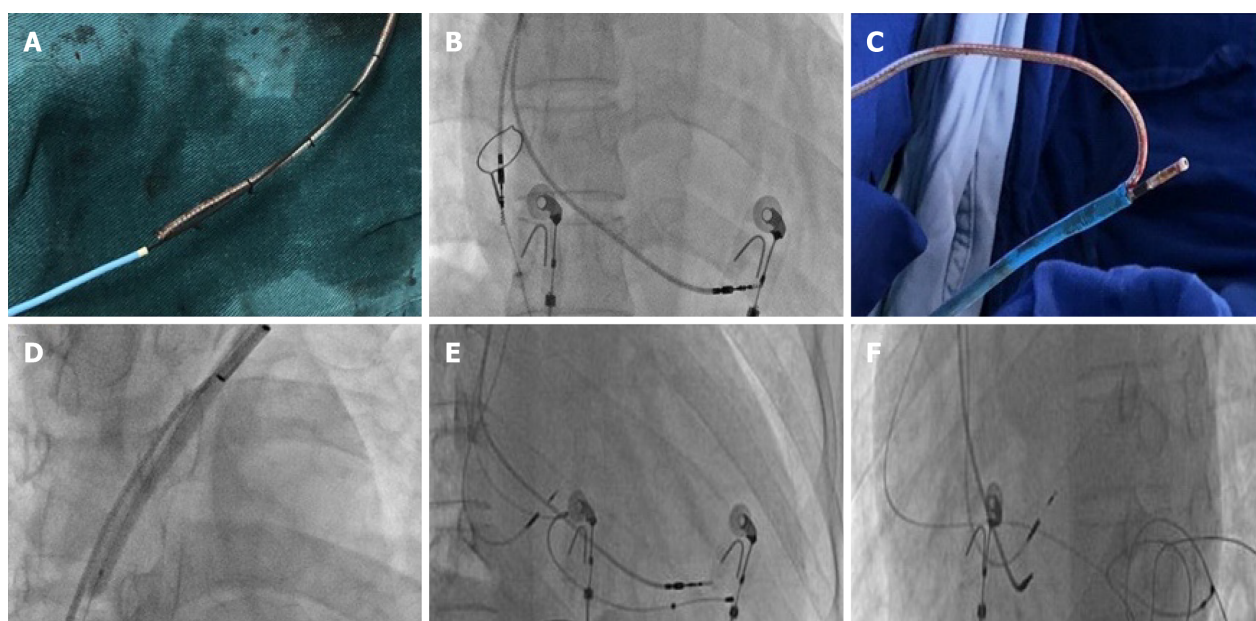


Figure 2 Cardiac resynchronization therapy pacemaker procedure. A: Proximally cut lead portions and a Radifocus guidewire tip were fixed with a suture, and the rest of the wire was covered by a Finecross catheter; B: The atrial lead tip captured in a goose-neck snare was positioned in the right atrium; C: The atrial lead was placed in the 8 French femoral vein sheath and removed from the right femoral vein; D: The balloon was dilated across the occlusion in the left subclavian vein; E and F: Intra-procedure fluoroscopy showed the location of the lead of the cardiac resynchronization therapy pacemaker.

subclavian vein obstruction likely due to endothelial disruption resulting from mechanical stress of the leads, which ultimately led to fibrosis and narrowing of the lumen. The management of pacemaker lead-induced subclavian vein obstruction includes medical, interventional, or surgical interventions. Surgical intervention has been the first-line treatment for patients with subclavian vein obstruction. However, in the past 20 years, endovascular reconstruction, which can minimize the risk of bleeding, has become more popular^[5].

In this patient, venography demonstrated total subclavian vein occlusion. Interventional procedures such as angioplasty and stenting were the primary choices for this patient. If visible blood flowed back to the right atrium, the passage of wires to the stenotic lesion would be recommended. Also, retrograde angioplasty from the femoral vein to pass the obstruction may be an option. Another choice could be to use a laser sheath as a lead extraction tool, as described by Pecha *et al*^[6] and Hasumi *et al*^[7]. However, a laser sheath is not enough in the vast majority of hospitals in China. For this patient, we finally fixed a Radifocus guidewire tip and proximally cut the lead portions instead of using a bulldog lead extender to pass the lesion and perform venoplasty.

Previously, Leacche *et al*^[8] reported that lead extraction alone could cause thrombosis and thus believed that it carried a high risk for subsequent re-occlusion with a low likelihood of sustaining patency. In another study performed with a cohort

of 28 patients who received treatment for pacemaker-related superior vena cava syndrome, the primary patency rates were 18% and 9% at 6 and 12 mo, respectively^[9]. The Heart Rhythm Society recommends that the entrapment of the pacemaker leads should be avoided prior to stent deployment^[10]. Previous studies reported that diagnosis of occlusive lesions with magnetic resonance angiography was accurate, which could be used to evaluate the outcome of patients with atherosclerosis and embolus^[11]. For this patient, the concern was that the pressure posed by the metallic stent on the wires could lead to malfunction of the pacemaker. Thus, instead of using stenting to remove the subclavian vein obstruction caused by the previously implanted leads, we used the CRT-P technique. We observed that the patient recovered uneventfully at least during the follow-up period. In consideration of the previous right ventricle lead, enhanced computed tomography was selected to evaluate the degree of subclavian vein stenosis, and visible blood flow was observed.

Limitations

This preliminary experience is limited to one case and difficult to generalize. The relatively short follow-up period cannot prejudice long-term outcomes in this patient.

CONCLUSION

This report demonstrates that CRT upgrade is still a viable technique for the treatment of subclavian vein obstruction caused by previous pacemaker implantation if appropriate additional technologies such as transferable interventional coronary and radiological techniques are available.

ACKNOWLEDGEMENTS

We appreciate the following authors' help on this study: Ye HH, Chen GF, Wu H, Peng XH, Shen JB, Zhuo SS, and Wang DJ.

REFERENCES

- 1 **Kirkfeldt RE**, Johansen JB, Nohr EA, Jørgensen OD, Nielsen JC. Complications after cardiac implantable electronic device implantations: an analysis of a complete, nationwide cohort in Denmark. *Eur Heart J* 2014; **35**: 1186-1194 [PMID: 24347317 DOI: 10.1093/eurheartj/ehu511]
- 2 **Laurent G**, Ricolfi F, Wolf JÉ. Venous stenting as a treatment for pacemaker-induced superior vena cava syndrome. *Arch Cardiovasc Dis* 2013; **106**: 624-626 [PMID: 23791590 DOI: 10.1016/j.acvd.2012.01.013]
- 3 **Spittell PC**, Hayes DL. Venous complications after insertion of a transvenous pacemaker. *Mayo Clin Proc* 1992; **67**: 258-265 [PMID: 1545594 DOI: 10.1016/s0025-6196(12)60103-7]
- 4 **Worley SJ**. Implant venoplasty: dilation of subclavian and coronary veins to facilitate device implantation: indications, frequency, methods, and complications. *J Cardiovasc Electrophysiol* 2008; **19**: 1004-1007 [PMID: 18554213 DOI: 10.1111/j.1540-8167.2008.01217.x]
- 5 **Madkaiker AN**, Krishna N, Jose R, Balasubramoniam KR, Murukan P, Baquero L, Varma PK. Superior Vena Cava Syndrome Caused by Pacemaker Leads. *Ann Thorac Surg* 2016; **101**: 2358-2361 [PMID: 27211943 DOI: 10.1016/j.athoracsur.2015.09.006]
- 6 **Pecha S**, Burger H, Castro L, Gosau N, Atlihan G, Willems S, Reichenspurner H, Hakmi S. The Bridge Occlusion Balloon for Venous Angioplasty in Superior Vena Cava Occlusion. *Braz J Cardiovasc Surg* 2019; **34**: 368-371 [PMID: 31310478 DOI: 10.21470/1678-9741-2018-0289]
- 7 **Hasumi E**, Fujiu K, Kojima T, Kinoshita O, Nawata K, Yamauchi H, Ono M, Komuro I. Novel extraction technique of retained pacemaker and defibrillator lead during heart transplantation. *PLoS One* 2018; **13**: e0203172 [PMID: 30188917 DOI: 10.1371/journal.pone.0203172]
- 8 **Leacche M**, Katsnelson Y, Arshad H, Mihaljevic T, Rawn JD, Sweeney MO, Byrne JG. Delayed presentation of totally avulsed right superior vena cava after extraction of permanent pacemaker lead. *Pacing Clin Electrophysiol* 2004; **27**: 262-263 [PMID: 14764184 DOI: 10.1111/j.1540-8159.2004.00424.x]
- 9 **Asif A**, Salman L, Carrillo RG, Garisto JD, Lopera G, Barakat U, Lenz O, Yevzlin A, Agarwal A, Gadalean F, Sachdeva B, Vachharajani TJ, Wu S, Maya ID, Abreo K. Patency rates for angioplasty in the treatment of pacemaker-induced central venous stenosis in hemodialysis patients: results of a multi-center study. *Semin Dial* 2009; **22**: 671-676 [PMID: 19799756 DOI: 10.1111/j.1525-139X.2009.00636.x]
- 10 **Wilkoﬀ BL**, Love CJ, Byrd CL, Bongiorno MG, Carrillo RG, Crossley GH 3rd, Epstein LM,

- Friedman RA, Kennergren CE, Mitkowski P, Schaerf RH, Wazni OM; Heart Rhythm Society; American Heart Association. Transvenous lead extraction: Heart Rhythm Society expert consensus on facilities, training, indications, and patient management: this document was endorsed by the American Heart Association (AHA). *Heart Rhythm* 2009; **6**: 1085-1104 [PMID: [19560098](#) DOI: [10.1016/j.hrthm.2009.05.020](#)]
- 11 **Razek AA**, Saad E, Soliman N, Elatta HA. Assessment of vascular disorders of the upper extremity with contrast-enhanced magnetic resonance angiography: pictorial review. *Jpn J Radiol* 2010; **28**: 87-94 [PMID: [20182842](#) DOI: [10.1007/s11604-009-0394-4](#)]



Published by **Baishideng Publishing Group Inc**
7041 Koll Center Parkway, Suite 160, Pleasanton, CA 94566, USA

Telephone: +1-925-3991568

E-mail: bpgoffice@wjgnet.com

Help Desk: <https://www.f6publishing.com/helpdesk>

<https://www.wjgnet.com>

