

World Journal of *Clinical Cases*

World J Clin Cases 2021 May 16; 9(14): 3227-3486



Contents

Thrice Monthly Volume 9 Number 14 May 16, 2021

MINIREVIEWS

- 3227 Non-invasive physical therapy as salvage measure for ischemic skin flap: A literature review
Zheng YH, Yin LQ, Xu HK, Gong X
- 3238 Prediction models for development of hepatocellular carcinoma in chronic hepatitis B patients
Guo J, Gao XS

ORIGINAL ARTICLE

Retrospective Cohort Study

- 3252 Burden of atrial fibrillation in patients with rheumatic diseases
Khan MZ, Patel K, Patel KA, Doshi R, Shah V, Adalja D, Waqar Z, Franklin S, Gupta N, Gul MH, Jesani S, Kutalek S, Figueredo V

Retrospective Study

- 3265 Observation of the effect of one-to-one education on high-risk cases of diabetic foot
Fu XJ, Hu SD, Peng YF, Zhou LY, Shu T, Song DD
- 3273 Pediatric Wilson disease presenting as acute liver failure: Prognostic indices
Fang WY, Abuduxikuer K, Shi P, Qiu YL, Zhao J, Li YC, Zhang XY, Wang NL, Xie XB, Lu Y, Knisely AS, Wang JS
- 3287 Positive psychological intervention for anxiety, depression and coping in subjects addicted to online games
Gao XJ, Sun JJ, Xiang M

SYSTEMATIC REVIEWS

- 3294 Cluster headache due to structural lesions: A systematic review of published cases
Long RJ, Zhu YS, Wang AP

META-ANALYSIS

- 3308 Comparison of smear cytology with liquid-based cytology in pancreatic lesions: A systematic review and meta-analysis
Zhang XH, Ma SY, Liu N, Wei ZC, Gao X, Hao YJ, Liu YX, Cai YQ, Wang JH

CASE REPORT

- 3320 Bronchial glomus tumor with calcification: A case report
Zhang Y, Zhang QP, Ji YQ, Xu J

- 3327** Acute flaccid paralysis and neurogenic respiratory failure associated with enterovirus D68 infection in children: Report of two cases
Zhang Y, Wang SY, Guo DZ, Pan SY, Lv Y
- 3334** Skeletal muscle metastases of hepatocellular carcinoma: A case report and literature review
Song Q, Sun XF, Wu XL, Dong Y, Wang L
- 3342** Bone cement implantation syndrome during hip replacement in a patient with pemphigus and Parkinson's disease: A case report
Zhou W, Zhang WJ, Zhao GQ, Li K
- 3350** Novel intergenic *KIF5B-MET* fusion variant in a patient with gastric cancer: A case report
Wu ZW, Sha Y, Chen Q, Hou J, Sun Y, Lu WK, Chen J, Yu LJ
- 3356** Recurrent perimesencephalic nonaneurysmal subarachnoid hemorrhage within a short period of time: A case report
Li J, Fang X, Yu FC, Du B
- 3365** Incremental value of three-dimensional and contrast echocardiography in the evaluation of endocardial fibroelastosis and multiple cardiovascular thrombi: A case report
Sun LJ, Li Y, Qiao W, Yu JH, Ren WD
- 3372** Floating elbow combining ipsilateral distal multiple segmental forearm fractures: A case report
Huang GH, Tang JA, Yang TY, Liu Y
- 3379** Acute cholangitis detected ectopic ampulla of Vater in the antrum incidentally: A case report
Lee HL, Fu CK
- 3385** Almitrine for COVID-19 critically ill patients – a vascular therapy for a pulmonary vascular disease: Three case reports
Huette P, Abou Arab O, Jounieaux V, Guilbart M, Belhout M, Haye G, Dupont H, Beyls C, Mahjoub Y
- 3394** Tenosynovial giant cell tumor involving the cervical spine: A case report
Zhu JH, Li M, Liang Y, Wu JH
- 3403** Primary bone anaplastic lymphoma kinase positive anaplastic large-cell lymphoma: A case report and review of the literature
Zheng W, Yin QQ, Hui TC, Wu WH, Wu QQ, Huang HJ, Chen MJ, Yan R, Huang YC, Pan HY
- 3411** Acute spontaneous thoracic epidural hematoma associated with intraspinal lymphangioma: A case report
Chia KJ, Lin LH, Sung MT, Su TM, Huang JF, Lee HL, Sung WW, Lee TH
- 3418** Change in neoadjuvant chemotherapy could alter the prognosis of patients with pancreatic adenocarcinoma: A case report
Meyer A, Carvalho BJ, Medeiros KA, Pipek LZ, Nascimento FS, Suzuki MO, Munhoz JV, Iuamoto LR, Carneiro-D'Albuquerque LA, Andraus W
- 3424** Laparoscopic cholecystectomy for gangrenous cholecystitis in around nineties: Two case reports
Inoue H, Ochiai T, Kubo H, Yamamoto Y, Morimura R, Ikoma H, Otsuji E

- 3432** Radiological insights of ectopic thyroid in the porta hepatis: A case report and review of the literature
Chooah O, Ding J, Fei JL, Xu FY, Yue T, Pu CL, Hu HJ
- 3442** Successful treatment of infantile hepatitis B with lamivudine: A case report
Zhang YT, Liu J, Pan XB, Gao YD, Hu YF, Lin L, Cheng HJ, Chen GY
- 3449** Pure large cell neuroendocrine carcinoma originating from the endometrium: A case report
Du R, Jiang F, Wang ZY, Kang YQ, Wang XY, Du Y
- 3458** Diabetic mastopathy in an elderly woman misdiagnosed as breast cancer: A case report and review of the literature
Chen XX, Shao SJ, Wan H
- 3466** Cronkhite-Canada syndrome with steroid dependency: A case report
Jiang D, Tang GD, Lai MY, Huang ZN, Liang ZH
- 3472** Extremely rare case of necrotizing gastritis in a patient with autoimmune hepatitis: A case report
Moon SK, Yoo JJ, Kim SG, Kim YS
- 3478** Paget's disease of bone: Report of 11 cases
Miao XY, Wang XL, Lyu ZH, Ba JM, Pei Y, Dou JT, Gu WJ, Du J, Guo QH, Chen K, Mu YM

ABOUT COVER

Editorial Board Member of *World Journal of Clinical Cases*, Nicola Montemurro, MD, PhD, Assistant Professor, Consultant Physician-Scientist, Neurosurgeon, Surgeon, Surgical Oncologist, Department of Translational Research and New Technologies in Medicine and Surgery, University of Pisa, Pisa 56126, Italy. nicola.montemurro@unipi.it

AIMS AND SCOPE

The primary aim of *World Journal of Clinical Cases* (WJCC, *World J Clin Cases*) is to provide scholars and readers from various fields of clinical medicine with a platform to publish high-quality clinical research articles and communicate their research findings online.

WJCC mainly publishes articles reporting research results and findings obtained in the field of clinical medicine and covering a wide range of topics, including case control studies, retrospective cohort studies, retrospective studies, clinical trials studies, observational studies, prospective studies, randomized controlled trials, randomized clinical trials, systematic reviews, meta-analysis, and case reports.

INDEXING/ABSTRACTING

The WJCC is now indexed in Science Citation Index Expanded (also known as SciSearch®), Journal Citation Reports/Science Edition, Scopus, PubMed, and PubMed Central. The 2020 Edition of Journal Citation Reports® cites the 2019 impact factor (IF) for WJCC as 1.013; IF without journal self cites: 0.991; Ranking: 120 among 165 journals in medicine, general and internal; and Quartile category: Q3. The WJCC's CiteScore for 2019 is 0.3 and Scopus CiteScore rank 2019: General Medicine is 394/529.

RESPONSIBLE EDITORS FOR THIS ISSUE

Production Editor: Jia-Hui Li; Production Department Director: Yun-Jie Ma; Editorial Office Director: Jin-Lei Wang.

NAME OF JOURNAL

World Journal of Clinical Cases

ISSN

ISSN 2307-8960 (online)

LAUNCH DATE

April 16, 2013

FREQUENCY

Thrice Monthly

EDITORS-IN-CHIEF

Dennis A Bloomfield, Sandro Vento, Bao-Gan Peng

EDITORIAL BOARD MEMBERS

<https://www.wjgnet.com/2307-8960/editorialboard.htm>

PUBLICATION DATE

May 16, 2021

COPYRIGHT

© 2021 Baishideng Publishing Group Inc

INSTRUCTIONS TO AUTHORS

<https://www.wjgnet.com/bpg/gerinfo/204>

GUIDELINES FOR ETHICS DOCUMENTS

<https://www.wjgnet.com/bpg/gerinfo/287>

GUIDELINES FOR NON-NATIVE SPEAKERS OF ENGLISH

<https://www.wjgnet.com/bpg/gerinfo/240>

PUBLICATION ETHICS

<https://www.wjgnet.com/bpg/gerinfo/288>

PUBLICATION MISCONDUCT

<https://www.wjgnet.com/bpg/gerinfo/208>

ARTICLE PROCESSING CHARGE

<https://www.wjgnet.com/bpg/gerinfo/242>

STEPS FOR SUBMITTING MANUSCRIPTS

<https://www.wjgnet.com/bpg/gerinfo/239>

ONLINE SUBMISSION

<https://www.f6publishing.com>



Laparoscopic cholecystectomy for gangrenous cholecystitis in around nineties: Two case reports

Hiroyuki Inoue, Toshiya Ochiai, Hidemasa Kubo, Yusuke Yamamoto, Ryo Morimura, Hisashi Ikoma, Eigo Otsuji

ORCID number: Hiroyuki Inoue 0000-0002-5879-9826; Toshiya Ochiai 0000-0002-6564-4048; Hidemasa Kubo 0000-0002-7294-5148; Yusuke Yamamoto 0000-0002-8740-8468; Ryo Morimura 0000-0002-5594-0943; Hisashi Ikoma 0000-0002-2647-6854; Eigo Otsuji 0000-0002-3260-8155.

Author contributions: Inoue H wrote the manuscript and got the figures; Inoue H and Ochiai T contributed to the discussion and interpretation of this manuscript; Otsuji E made the critical revision; all authors have read and approved the manuscript.

Informed consent statement: All study participants, or their legal guardian, provided informed written consent prior to study enrollment.

Conflict-of-interest statement: The authors declare that they have no conflict-of-interests.

CARE Checklist (2016) statement: The authors have read the CARE Checklist (2016), and the manuscript was prepared and revised according to the CARE Checklist (2016).

Open-Access: This article is an open-access article that was selected by an in-house editor and

Hiroyuki Inoue, Division of Digestive Surgery, Department of Surgery, Kyoto Prefectural University of Medicine, Kyoto 6028566, Japan

Toshiya Ochiai, Department of Surgery, North Medical Center Kyoto Prefectural University of Medicine, Kyoto 6292261, Japan

Hidemasa Kubo, Yusuke Yamamoto, Ryo Morimura, Hisashi Ikoma, Eigo Otsuji, Division of Digestive Surgery, Department of Surgery, Kyoto Prefectural University of Medicine, Kyoto 6028566, Japan

Corresponding author: Toshiya Ochiai, MD, PhD, Assistant Professor, Department of Surgery, North Medical Center Kyoto Prefectural University of Medicine, Kyoto 6292261, Japan. tochiai@koto.kpu-m.ac.jp

Abstract

BACKGROUND

Gangrenous cholecystitis is a form of acute cholecystitis which involves gangrenous alterations in the gallbladder wall and it often follows an acute and serious course. We herein report on two cases of very elderly people diagnosed early with gangrenous cholecystitis, who safely underwent laparoscopic cholecystectomy (LC) and both demonstrated a good outcome.

CASE SUMMARY

Case 1: An 89-year-old female. She underwent abdominal contrast-enhanced computed tomography (CECT) due to abdominal pain and diarrhea. Her gallbladder wall indicated the absence of contrast enhancement, thus leading to diagnosis of gangrenous cholecystitis and she therefore underwent LC. Although her gallbladder demonstrated diffuse necrosis and it was also partly perforated, she was able to be discharged without any serious complications. Case 2: A 91-year-old female. She made an emergency visit with a chief complaint of abdominal pain. Abdominal CECT revealed swelling of the gallbladder and an ambiguous continuity of the gallbladder wall. She was diagnosed with gangrenous cholecystitis and underwent LC. Her gallbladder had swelling and diffuse necrosis. Although her preoperative blood culture was positive, she showed a good outcome following surgery.

CONCLUSION

Although a definite diagnosis of gangrenous cholecystitis is difficult to make prior

fully peer-reviewed by external reviewers. It is distributed in accordance with the Creative Commons Attribution NonCommercial (CC BY-NC 4.0) license, which permits others to distribute, remix, adapt, build upon this work non-commercially, and license their derivative works on different terms, provided the original work is properly cited and the use is non-commercial. See: <http://creativecommons.org/licenses/by-nc/4.0/>

Manuscript source: Unsolicited manuscript

Specialty type: Surgery

Country/Territory of origin: Japan

Peer-review report's scientific quality classification

Grade A (Excellent): 0
Grade B (Very good): 0
Grade C (Good): 0
Grade D (Fair): 0
Grade E (Poor): 0

Received: December 31, 2020

Peer-review started: December 31, 2020

First decision: January 27, 2021

Revised: February 5, 2021

Accepted: March 17, 2021

Article in press: March 17, 2021

Published online: May 16, 2021

P-Reviewer: Bao Y

S-Editor: Liu M

L-Editor: A

P-Editor: Yuan YY



to surgery, if an early diagnosis can be made and appropriate treatment can be carried out, then even very elderly individuals may be discharged without major complications.

Key Words: Gangrenous cholecystitis; Laparoscopic cholecystectomy; Elderly people; Critical view of safety; Tokyo guidelines 2018; Case report

©The Author(s) 2021. Published by Baishideng Publishing Group Inc. All rights reserved.

Core Tip: Gangrenous cholecystitis is a form of acute cholecystitis which involves gangrenous alteration in the gallbladder wall and often follows acute and serious course. We report on two cases of very elderly people diagnosed with gangrenous cholecystitis, who safely underwent laparoscopic cholecystectomy and made good progress. If early diagnosis of gangrenous cholecystitis and an appropriate treatment method can be carried out, even very elderly individuals may be discharged without major complications. Our paper will be very informative and useful to the readers of World Journal of Clinical Cases in today's aging society, and will be frequently cited.

Citation: Inoue H, Ochiai T, Kubo H, Yamamoto Y, Morimura R, Ikoma H, Otsuji E. Laparoscopic cholecystectomy for gangrenous cholecystitis in around nineties: Two case reports. *World J Clin Cases* 2021; 9(14): 3424-3431

URL: <https://www.wjgnet.com/2307-8960/full/v9/i14/3424.htm>

DOI: <https://dx.doi.org/10.12998/wjcc.v9.i14.3424>

INTRODUCTION

Gangrenous cholecystitis is defined as cholecystitis involving necrosis and the bleeding of tissues after edematous alterations. The necrosis of tissues is said to be caused by adiemorrhysis of the arterial branches resulting from the oppression of the gallbladder wall due to an elevated biliary internal pressure. Early and appropriate treatment is desirable; however, making a preoperative diagnosis is often difficult. We herein report on two cases of very elderly people diagnosed early with gangrenous cholecystitis, who safely underwent LC and thereafter showed a good outcome.

CASE PRESENTATION

Chief complaints

Case 1: The subject was an 89-year-old female with a chief complaint of abdominal pain and diarrhea.

Case 2: The subject was a 91-year-old female with a chief complaint of right abdominal pain.

History of present illness

Case 1: While hospitalized for a left trochanteric fracture, she suddenly complained of abdominal pain and diarrhea.

Case 2: She visited a local doctor with a chief complaint of right abdominal pain. An abdominal ultrasound revealed swelling of the gallbladder at a local clinic and therefore she was referred to our hospital.

History of past illness

Case 1: She had a past history of Alzheimer's dementia and trochanteric fracture.

Case 2: She had a past history of hypertension, angina, and hyperlipidemia.

Personal and family history

Their family histories have nothing notable in both Case 1 and Case 2.

Physical examination

Case 1: Although there were no problems with her vital signs and her abdominal region was flat and soft, she experienced localized pressure pain in her right hypochondrium. She had no obvious rebound tenderness. The Case 2 was the same as the Case 1.

Laboratory examinations

Case 1: Blood biochemistry testing revealed substantial inflammation and elevated hepatic and biliary enzyme levels [C-reactive protein (CRP) 23.5 mg/dL, white blood cell (WBC) 11700/ μ L, neutrophils (Neut) 81.9%, alkaline phosphatase 535 IU/L].

Case 2: Blood biochemistry testing revealed substantial inflammation and elevated hepatic and biliary enzymes (CRP 15.9 mg/dL, WBC 8800/ μ L, Neut 87.5%, aspartate aminotransferase 117 IU/L, alanine aminotransferase 101 IU/L).

Imaging examinations

Case 1: An abdominal contrast-enhanced computed tomography (CECT) revealed significant swelling of her gallbladder and asymmetrical wall thickening (Figure 1). The gallbladder wall indicated parts with either poor or no contrast enhancement, with a partial failure of continuity of the mucosa.

Case 2: An abdominal CECT (Figure 2) revealed significant swelling of her gallbladder and ascites around her liver. There was asymmetrical gallbladder wall thickening and the continuity of part of the wall was ambiguous.

FINAL DIAGNOSIS

From the above, they were diagnosed with gangrenous cholecystitis and therefore underwent emergency surgery in both Case 1 and Case 2.

TREATMENT

Case 1: The surgery was carried out under laparoscopy using four ports. Inside the abdominal lumen, the omentum was attached around the gallbladder and a part of gallbladder wall was found to demonstrate necrosis. Fragile parts of the gallbladder wall had partially ruptured, thus causing bile to leak (Figure 3A and B). First, we took an approach from the gallbladder neck to identify the critical view of safety (CVS). Since inflammation was substantial and the overall gallbladder was thickened with a finding of necrosis, we believed that this approach was difficult. Therefore, we switched to subtotal cholecystectomy using the fundus first technique. Upon exfoliation from the base to the neck, we cut off the parts without necrosis using an autosuture to extract the specimen (Figure 3C-E).

Case 2: The laparoscopic surgery was performed as in Case 1. Inside the abdominal lumen, the gallbladder was very tense with diffuse necrosis, while the gallbladder wall was maintained without leaking bile (Figure 4A). We took an approach from the gallbladder neck, identified CVS and treated the biliary artery (Figure 4B). We then attempted to treat the cystic duct. Since bleeding was substantial and it was difficult to develop the view field, and the duct had thickened substantially due to inflammation, in the end, we chose to use the fundus first technique. Upon exfoliation from the base to the neck, we identified the cystic duct again, however, we deemed that it was difficult to treat it using an autosuture due to the substantial thickness of the duct. We performed double ligature/treatment using a looped absorbable monofilament suture, carried out subtotal cholecystectomy, and extracted the specimen (Figure 4C-E).

OUTCOME AND FOLLOW-UP

Case 1: The patient made good progress following surgery without any major

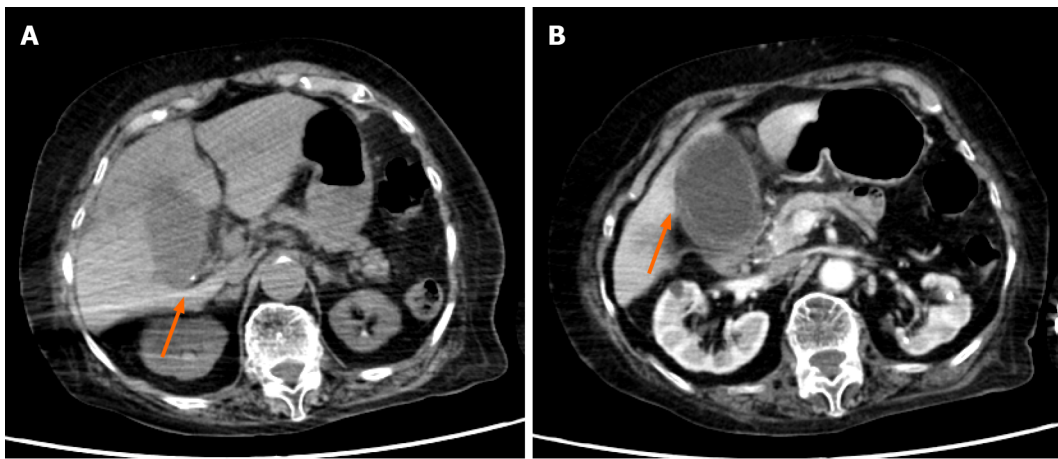


Figure 1 An abdominal contrast-enhanced computed tomography (Case 1). A: Small calculus in the gallbladder neck (arrow); B: Significant swelling of the gallbladder and asymmetrical wall thickening. The gallbladder wall indicated parts with either poor or no contrast enhancement (arrow), with a partial failure of continuity of the mucosa.

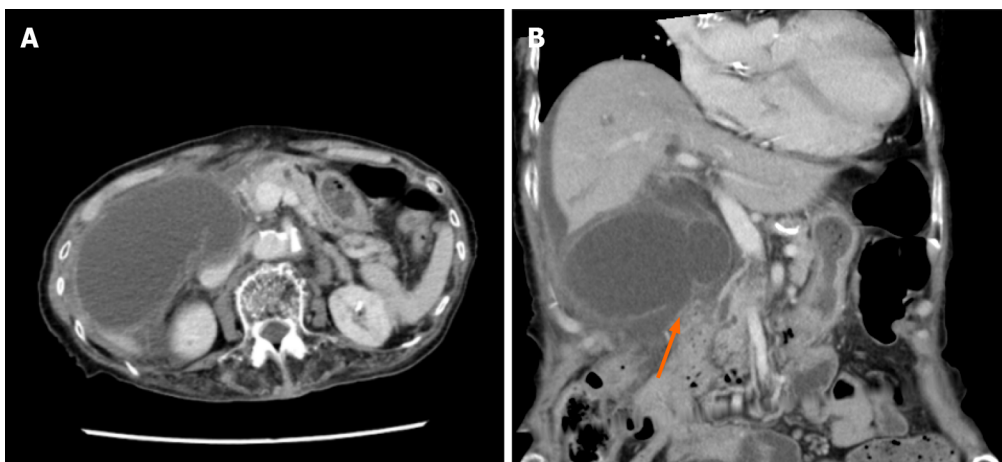


Figure 2 An abdominal contrast-enhanced computed tomography (Case 2). A: Significant swelling of the gallbladder. Ascites around the liver; B: There was asymmetrical gallbladder wall thickening and the continuity of part of the wall was ambiguous (arrow).

complications and she was discharged home on the 10th disease day. A histopathological examination revealed gangrenous alterations indicating necrosis of all layers and involving neutrophilic infiltration, bleeding, and the genesis of granulation tissue on the serosal side.

Case 2: She made good progress following surgery and was discharged home on the 10th disease day. A histopathological examination indicated necrosis of all layers with a background of edema and acute inflammatory cellular infiltration.

DISCUSSION

Ninety percent or more of acute cholecystitis cases are caused by gallstones in the gallbladder[1]. The mechanism of gallstone cholecystitis is as follows: Incarceration and occlusion of the gallstones in the cystic duct causes cholestasis in the gallbladder, leading to damage to the biliary mucosa and activation of inflammatory mediators[2]. On the other hand, cholecystitis sine concrement is caused by either: (1) Cholestasis in the gallbladder; or (2) Blood circulation disorder in the gallbladder wall due to biliary ischemia resulting from atherothrombosis and hyperlipidemia due to arteriosclerosis[3]. The advancement of acute cholecystitis resulting from these causes may lead to gangrenous cholecystitis. The gangrenous cholecystitis of Case 1 was thought to be attributed to the incarceration of the gallstone. Case 2 had a past history of diseases that can be a risk for atherothrombosis, such as hypertension and angina, and thus it

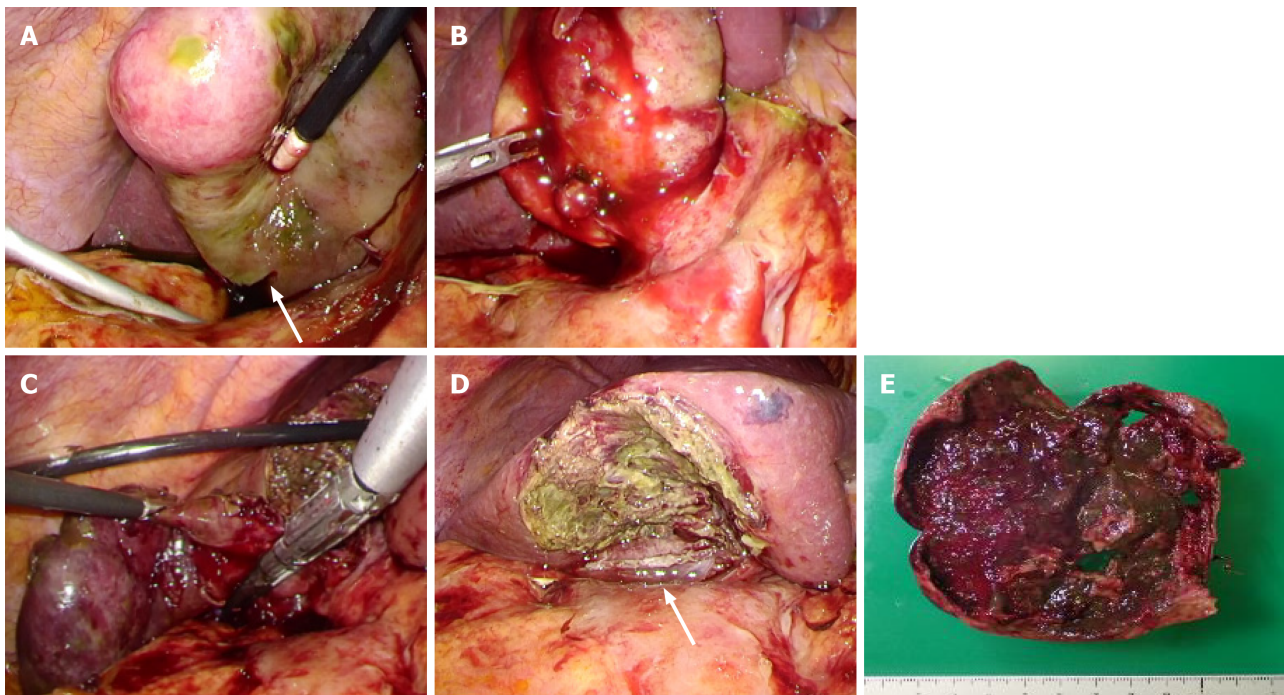


Figure 3 Surgical observations and surgical techniques (Case 1). A: Gallbladder necroses and a part thereof is perforated (arrow), with leaking of bile; B: Gallbladder neck had substantial inflammation; C: Upon exfoliation from the base to the neck of the gallbladder, we treated the neck using an autosuture; D: After subtotal resection of the gallbladder, the arrow is the amputation stump of the gallbladder neck; E: Resected specimen.

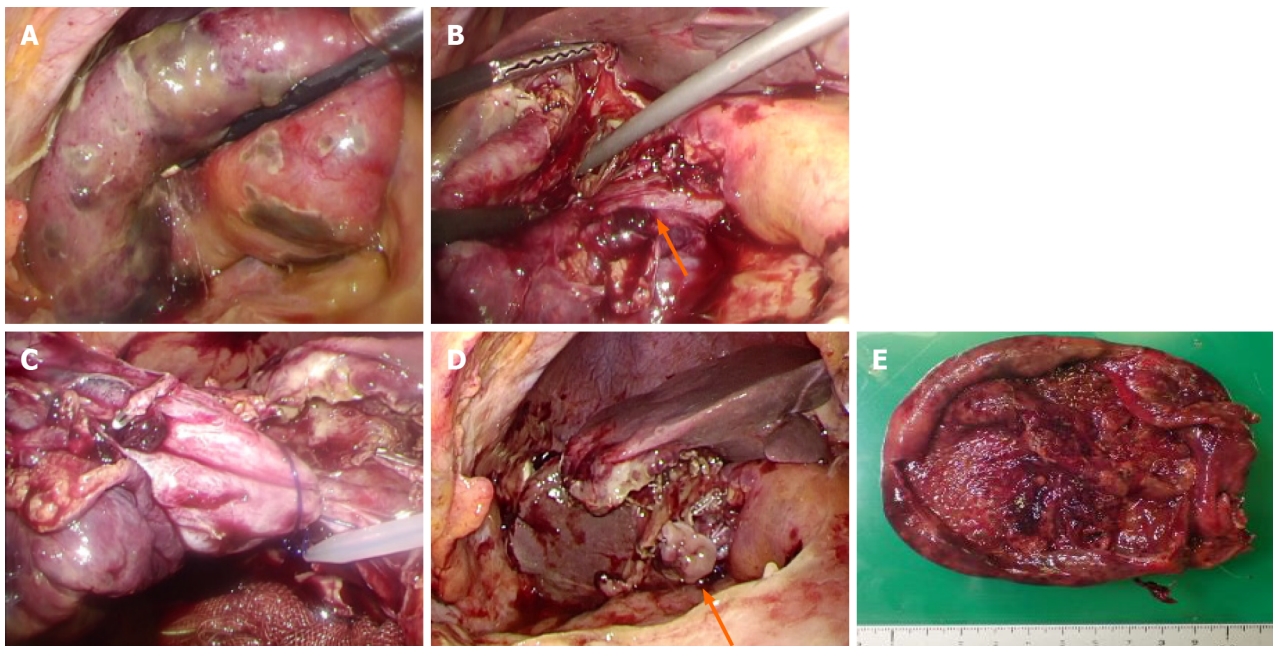


Figure 4 Surgical observations and surgical techniques (Case 2). A: The gallbladder had significant swelling and diffuse necrosis; B: The arrow is a cystic duct; C: For the cystic duct and gallbladder neck, we performed ligature/treatment using a looped absorbable monofilament suture; D: After subtotal resection of the gallbladder, the arrow is the amputation stump of the gallbladder neck; E: Resected specimen.

has a very high risk of developing cholecystitis sine concrement.

The Tokyo guidelines are thought to be useful for the diagnosis and treatment of acute cholecystitis. According to the Tokyo guidelines 2018 (TG18), abdominal ultrasonography is useful for diagnosing acute cholecystitis and defined as the first-choice imaging examination. Moreover, if a blood examination and abdominal ultrasonography cannot lead to a definite diagnosis, then abdominal CECT or abdominal MRI/MRCP is useful. On the other hand, abdominal CECT or abdominal MRI/MRCP is recommended for the diagnosis of gangrenous cholecystitis[4]. Since

they have better a diagnostic capability than abdominal ultrasonography, they should be performed if gangrenous cholecystitis is suspected. Gangrenous cholecystitis is characterized by the rarefaction of the gallbladder wall, poor enhancement of the gallbladder wall, elevated concentration of adipose tissue around the gallbladder, and the existence of gas in the gallbladder and gallbladder wall. This case also recognized rarefaction of the gallbladder wall, the poor enhancement of the gallbladder wall, and an elevated concentration of adipose tissue around the gallbladder.

In TG18, the treatment strategy is determined based on the treatment flow chart according to the severity classification as well as the underlying diseases and normal condition of the patient[5]. In other words, the Charlson comorbidity index (CCI) and American Society of Anesthesiologists physical status (ASA-PS) and other predictors are taken into consideration when determining the indications for surgery. Based on these guidelines, biliary drainage may be performed other than surgery for patients with high risk from surgery. We believe the guidelines allowed us to make a more suitable determination that in actual clinical practice. Both cases in this study had Grade II cholecystitis based on the severity criteria and had CCI one point and ASA-PS two points. Therefore, we chose surgery.

The first choice of surgery for acute cholecystitis is LC except if cancer is suspected[6]. It has been reported in randomized controlled trial and meta-analysis that LC has an equivalent treatment outcome with open cholecystectomy along with a "shorter postoperative admission duration," "lower incidence of complications," and "superiority in mortality and morbidity"[7-12]. On the other hand, it is said to cause more biliary tract damage due to anatomical misidentification compared to laparotomy, which is a problem associated with its introduction[13]. It is said to be essential to identify CVS to avoid biliary tract damage and safely conduct laparoscopic surgery[3,14]. Moreover, it is believed to be important to operate at the anterior Rouvier groove because the right hepatic artery and bile duct right branch are at the posterior Rouvier groove, to perform exfoliation and vessel treatment as close to the gallbladder as possible, and to perform exfoliation while being aware of the subserosa-inner layer, which is said to cause bleeding and damage less frequently[15]. However, for cholecystitis with severe local inflammation such as gangrenous cholecystitis, it is often difficult to perform LC perfectly according to the above procedure. In the above case, it is recommended to consider using laparoscopic coagulating shears, adding ports, the fundus first technique[16], subtotal cholecystectomy[17] and open conversion. If these also present with challenges, then we perform fundus first technique. If dissection is difficult, we treat such cases at the gallbladder neck and carry out subtotal cholecystectomy. We perform laparotomy if these approaches still cannot accomplish the surgery. In our cases, we could accomplish the surgery in accordance with the above methods. Acute cholecystitis is a disease we often encounter. The treatment strategy varies according to the severity. In particular, there are various approaches to the surgery. As a result, proficient techniques and appropriate determinations are required.

Recently, there has been an increasing number of cases of very elderly people who require surgery as in our cases. It has been reported that because very elderly people sometimes have a chief complaint which is difficult to understand or different from ordinary complaints, consultation or examination tend to be late and the diseases tend to become severe[18]. Since it is difficult to find out the past history and physical findings, blood examinations and imaging examinations are therefore recommended. In our cases, we were able to avoid vital complications by early examinations, a timely diagnosis, and treatment after identifying the symptoms. For surgery involving very elderly people, we believe appropriate and early diagnosis and treatment are necessary to avoid procedural accidents during surgery and postoperative complications.

CONCLUSION

We experienced two cases of very elderly people with gangrenous cholecystitis. Although a definite diagnosis of gangrenous cholecystitis is difficult to make prior to surgery, if an early diagnosis can be made and appropriate treatment methods can be carried out, then even very elderly people may be discharged without any major complications.

REFERENCES

- 1 **Strasberg SM.** Clinical practice. Acute calculous cholecystitis. *N Engl J Med* 2008; **358**: 2804-2811 [PMID: [18579815](#) DOI: [10.1056/NEJMcp0800929](#)]
- 2 **Akriviadis EA,** Hatzigavriel M, Kapnias D, Kiriimidis J, Markantas A, Garyfallos A. Treatment of biliary colic with diclofenac: a randomized, double-blind, placebo-controlled study. *Gastroenterology* 1997; **113**: 225-231 [PMID: [9207282](#) DOI: [10.1016/s0016-5085\(97\)70099-4](#)]
- 3 **Barie PS,** Eachempati SR. Acute acalculous cholecystitis. *Gastroenterol Clin North Am* 2010; **39**: 343-357, x [PMID: [20478490](#) DOI: [10.1016/j.gtc.2010.02.012](#)]
- 4 **Yokoe M,** Hata J, Takada T, Strasberg SM, Asbun HJ, Wakabayashi G, Kozaka K, Endo I, Deziel DJ, Miura F, Okamoto K, Hwang TL, Huang WS, Ker CG, Chen MF, Han HS, Yoon YS, Choi IS, Yoon DS, Noguchi Y, Shikata S, Ukai T, Higuchi R, Gabata T, Mori Y, Iwashita Y, Hibi T, Jagannath P, Jonas E, Liau KH, Derveniz C, Gouma DJ, Cherqui D, Belli G, Garden OJ, Giménez ME, de Santibañes E, Suzuki K, Umezawa A, Supe AN, Pitt HA, Singh H, Chan ACW, Lau WY, Teoh AYB, Honda G, Sugioka A, Asai K, Gomi H, Itoi T, Kiriya S, Yoshida M, Mayumi T, Matsumura N, Tokumura H, Kitano S, Hirata K, Inui K, Sumiyama Y, Yamamoto M. Tokyo Guidelines 2018: diagnostic criteria and severity grading of acute cholecystitis (with videos). *J Hepatobiliary Pancreat Sci* 2018; **25**: 41-54 [PMID: [29032636](#) DOI: [10.1002/jhbp.515](#)]
- 5 **Okamoto K,** Suzuki K, Takada T, Strasberg SM, Asbun HJ, Endo I, Iwashita Y, Hibi T, Pitt HA, Umezawa A, Asai K, Han HS, Hwang TL, Mori Y, Yoon YS, Huang WS, Belli G, Derveniz C, Yokoe M, Kiriya S, Itoi T, Jagannath P, Garden OJ, Miura F, Nakamura M, Horiguchi A, Wakabayashi G, Cherqui D, de Santibañes E, Shikata S, Noguchi Y, Ukai T, Higuchi R, Wada K, Honda G, Supe AN, Yoshida M, Mayumi T, Gouma DJ, Deziel DJ, Liau KH, Chen MF, Shiao K, Liu KH, Su CH, Chan ACW, Yoon DS, Choi IS, Jonas E, Chen XP, Fan ST, Ker CG, Giménez ME, Kitano S, Inomata M, Hirata K, Inui K, Sumiyama Y, Yamamoto M. Tokyo Guidelines 2018: flowchart for the management of acute cholecystitis. *J Hepatobiliary Pancreat Sci* 2018; **25**: 55-72 [PMID: [29045062](#) DOI: [10.1002/jhbp.516](#)]
- 6 **Wakabayashi G,** Iwashita Y, Hibi T, Takada T, Strasberg SM, Asbun HJ, Endo I, Umezawa A, Asai K, Suzuki K, Mori Y, Okamoto K, Pitt HA, Han HS, Hwang TL, Yoon YS, Yoon DS, Choi IS, Huang WS, Giménez ME, Garden OJ, Gouma DJ, Belli G, Derveniz C, Jagannath P, Chan ACW, Lau WY, Liu KH, Su CH, Misawa T, Nakamura M, Horiguchi A, Tagaya N, Fujioka S, Higuchi R, Shikata S, Noguchi Y, Ukai T, Yokoe M, Cherqui D, Honda G, Sugioka A, de Santibañes E, Supe AN, Tokumura H, Kimura T, Yoshida M, Mayumi T, Kitano S, Inomata M, Hirata K, Sumiyama Y, Inui K, Yamamoto M. Tokyo Guidelines 2018: surgical management of acute cholecystitis: safe steps in laparoscopic cholecystectomy for acute cholecystitis (with videos). *J Hepatobiliary Pancreat Sci* 2018; **25**: 73-86 [PMID: [29095575](#) DOI: [10.1002/jhbp.517](#)]
- 7 **Kiviluoto T,** Sirén J, Luukkonen P, Kivilaakso E. Randomised trial of laparoscopic vs open cholecystectomy for acute and gangrenous cholecystitis. *Lancet* 1998; **351**: 321-325 [PMID: [9652612](#) DOI: [10.1016/s0140-6736\(97\)08447-x](#)]
- 8 **Berggren U,** Gordh T, Grama D, Haglund U, Rastad J, Arvidsson D. Laparoscopic vs open cholecystectomy: hospitalization, sick leave, analgesia and trauma responses. *Br J Surg* 1994; **81**: 1362-1365 [PMID: [7953415](#) DOI: [10.1002/bjs.1800810936](#)]
- 9 **Zacks SL,** Sandler RS, Rutledge R, Brown RS Jr. A population-based cohort study comparing laparoscopic cholecystectomy and open cholecystectomy. *Am J Gastroenterol* 2002; **97**: 334-340 [PMID: [11866270](#) DOI: [10.1111/j.1572-0241.2002.05466.x](#)]
- 10 **Flowers JL,** Bailey RW, Scovill WA, Zucker KA. The Baltimore experience with laparoscopic management of acute cholecystitis. *Am J Surg* 1991; **161**: 388-392 [PMID: [1825764](#) DOI: [10.1016/0002-9610\(91\)90604-c](#)]
- 11 **Johansson M,** Thune A, Nelvin L, Stiernstam M, Westman B, Lundell L. Randomized clinical trial of open vs laparoscopic cholecystectomy in the treatment of acute cholecystitis. *Br J Surg* 2005; **92**: 44-49 [PMID: [15584058](#) DOI: [10.1002/bjs.4836](#)]
- 12 **Purkayastha S,** Tilney HS, Georgiou P, Athanasiou T, Tekkis PP, Darzi AW. Laparoscopic cholecystectomy vs mini-laparotomy cholecystectomy: a meta-analysis of randomised control trials. *Surg Endosc* 2007; **21**: 1294-1300 [PMID: [17516122](#) DOI: [10.1007/s00464-007-9210-3](#)]
- 13 **Zha Y,** Chen XR, Luo D, Jin Y. The prevention of major bile duct injuries in laparoscopic cholecystectomy: the experience with 13,000 patients in a single center. *Surg Laparosc Endosc Percutan Tech* 2010; **20**: 378-383 [PMID: [21150413](#) DOI: [10.1097/SLE.0b013e3182008efb](#)]
- 14 **Strasberg SM,** Brunt LM. Rationale and use of the critical view of safety in laparoscopic cholecystectomy. *J Am Coll Surg* 2010; **211**: 132-138 [PMID: [20610259](#) DOI: [10.1016/j.jamcollsurg.2010.02.053](#)]
- 15 **Honda G,** Hasegawa H, Umezawa A. Universal safe procedure of laparoscopic cholecystectomy standardized by exposing the inner layer of the subserosal layer (with video). *J Hepatobiliary Pancreat Sci* 2016; **23**: E14-E19 [PMID: [27515579](#) DOI: [10.1002/jhbp.382](#)]
- 16 **Tartaglia N,** Cianci P, Di Lascia A, Fersini A, Ambrosi A, Neri V. Laparoscopic antegrade cholecystectomy: a standard procedure? *Open Med (Wars)* 2016; **11**: 429-432 [PMID: [28352832](#) DOI: [10.1515/med-2016-0078](#)]
- 17 **Strasberg SM,** Pucci MJ, Brunt LM, Deziel DJ. Subtotal Cholecystectomy-"Fenestrating" vs "Reconstituting" Subtypes and the Prevention of Bile Duct Injury: Definition of the Optimal Procedure in Difficult Operative Conditions. *J Am Coll Surg* 2016; **222**: 89-96 [PMID: [26521077](#)]

DOI: [10.1016/j.jamcollsurg.2015.09.019](https://doi.org/10.1016/j.jamcollsurg.2015.09.019)

- 18 **Launay-Savary MV**, Rainfray M, Dubuisson V. Emergency gastrointestinal surgery in the elderly. *J Visc Surg* 2015; **152**: S73-S79 [PMID: [26522505](https://pubmed.ncbi.nlm.nih.gov/26522505/) DOI: [10.1016/j.jviscsurg.2015.09.016](https://doi.org/10.1016/j.jviscsurg.2015.09.016)]



Published by **Baishideng Publishing Group Inc**
7041 Koll Center Parkway, Suite 160, Pleasanton, CA 94566, USA

Telephone: +1-925-3991568

E-mail: bpgoffice@wjgnet.com

Help Desk: <https://www.f6publishing.com/helpdesk>

<https://www.wjgnet.com>

