

Microsoft Bing

国内版 国际版

Avascular Necrosis of the First Metatarsal Head in a Young Female

153

🔍

ALL IMAGES VIDEOS

28,000 Results Any time

Idiopathic Avascular Necrosis of First Metatarsal Head in ...

<https://pubmed.ncbi.nlm.nih.gov/28476399>

Idiopathic avascular necrosis of the first metatarsal head rarely occurs in pediatrics. The present case of avascular necrosis of the first metatarsal head occurred in a 13-year-old male who came to the clinic... +

Cited by: 1 Author: Young-Uk Kwon, Jang-Seok Choi, Gyu-Min ...

Publish Year: 2017

[PDF] Avascular Necrosis of the 1st Metatarsal Head

www.achot.cz/dwnld/0805_396.pdf

Idiopathic avascular necrosis of first metatarsophalangeal head in child is unique condition not described in literature in past extude one case.It seems to be part of avascular bone necrosis syndrome...

Avascular necrosis of the hallux metatarsal head

<https://pubmed.ncbi.nlm.nih.gov/11232399>

Avascular necrosis of the first metatarsal head is rare. Although idiopathic cases have been reported, AVN of the first metatarsal head is usually iatrogenic following surgical correction of hallux valgus usin...

Cited by: 64 Author: M E Easley, I P Kelly

Publish Year: 2000


Avascular necrosis - Symptoms and causes - Mayo Clinic

www.mayoclinic.org/diseases-conditions/

Osteonecrosis

Medical Condition

Bone death due to lack of blood supply



Healthy hip joint Necrotic hip joint

Death of bone tissue due to temporary or permanent loss of blood supply to the bones. Early stages have no symptoms, eventually, it may cause pain in the joints and limit physical activities.

🏠 Rare (Fewer than 200,000 cases per year in US)

🧪 Requires lab test or imaging

Avascular necrosis of the first metatarsal head in a young female a



ALL

IMAGES

VIDEOS

36,900 Results

Any time ▾

Open links in new tab



[PDF] [Avascular Necrosis of the 1st Metatarsal Head](#)

www.achot.cz/dwnld/0805_396.pdf

Idiopathic **avascular necrosis** of **first** metatarsophalangeal **head** in child is unique condition not described in literature in past exlude one **case**.It seems to be part of **avascular** bone **necrosis** syndromes, like Freiberg disease, Sever disease etc. and the same principles of treatment are appropriate in AVN of 1st MTT **head**.

[Avascular necrosis of the hallux metatarsal head](#)

<https://pubmed.ncbi.nlm.nih.gov/11232399>

Avascular necrosis of the first metatarsal head is rare. Although idiopathic cases have been reported, **AVN of the first metatarsal head** is usually iatrogenic following surgical correction of hallux valgus using a distal **metatarsal** osteotomy with or without lateral soft tissue release. A thorough und ...

Cited by: 65

Author: M E Easley, I P Kelly

Publish Year: 2000

PEOPLE ALSO ASK

Where does the second metatarsal head get its blood from?



Which is the most common joint affected by AVN?



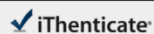What causes osteochondritis in the second metatarsal?



What causes sudden spontaneous AVN in the knee?



Feedback



61416_Auto_Edited -check.docx

Quotes Excluded
Bibliography Included

2%

Match Overview

1	Internet 29 words crawled on 14-Mar-2018 pdfs.semanticscholar.org	1%
2	Internet 23 words crawled on 17-Sep-2013 www.uptodate.com	1%
3	Internet 14 words crawled on 29-May-2015 eradiology.bdmc.harvard.edu	<1%

国内版

国际版

Avascular necrosis of the first metatarsal head in a young female a



ALL

IMAGES

VIDEOS

30,500 Results

Any time ▾

Freiberg Disease (Infraction): Practice Essentials ...

<https://emedicine.medscape.com/article/1236085>

May 28, 2021 · Freiberg disease is a form of avascular necrosis (AVN) in the metatarsal. [1] It was first described in 1914 by Alfred H Freiberg, who reported six cases of young women ...

Osteonecrosis in the Foot : JAAOS - Journal of the ...

<https://journals.lww.com/jaaos/fulltext/2007/04000/...>

Osteonecrosis, also referred to as avascular necrosis, refers to the death of cells within bone caused by a lack of circulation. It has been documented in bones throughout the body. In the foot, osteonecrosis is most commonly seen in the talus, the first and second metatarsals, and the navicular.

PEOPLE ALSO ASK

Why is AVN of the talus a rare complication?



What happens if you fracture the second metatarsal?



Where does the second metatarsal head get its blood from?



Is the second metatarsal affected by Freiberg's disease?



Feedback

Avascular Necrosis of the Metatarsal Head - Trip Database

<https://www.tripdatabase.com/search?criteria...> ▾

The surgical techniques for both first and lesser metatarsal reconstructions are described. Six patients were identified with average follow-up interval of 36 months (range, 6-66). Preoperative diagnoses included infection (1), fracture (1), and avascular necrosis (4). ...

Freiberg's disease | Genetic and Rare Diseases Information ...

<https://rarediseases.info.nih.gov/diseases/2380/freibergs-disease> ▾

May 14, 2015 · Common signs and symptoms of Freiberg's disease include pain and stiffness in the front of the foot, which often leads to a limp. People with this condition may also experience swelling, limited range of motion, and tenderness of the affected foot. Some people describe the sensation of walking on