



国内版 国际版

Anesthetic management of a child from the Qinghai Tibet Plateau w



ALL

IMAGES

VIDEOS

There are no results for **Anesthetic management of a child from the Qinghai Tibet Plateau with a double outlet right ventricle and severe polycythemia: a Case Report**

Check your spelling or try different keywords

Ref A: 1F147B2417814CD78F95F2264AB5BC42 Ref B: BJ1EDGE0515 Ref C: 2020-12-23T02:24:21Z

Microsoft Bing

国内版 国际版

Anesthetic management of a child with double outl

Chat with Bing

Sign in

ALL IMAGES VIDEOS

41,600 Results Any time Open links in new tab

(PDF) Anesthetic Management of a Unique Case of Double ...

<https://www.researchgate.net/publication/328192628...>

We report the case of a patient at 36 weeks of gestation, with a partially palliated double-outlet right ventricle and a Glenn shunt, who presented with severe dyspnea and worsening cyanosis.

Anesthetic management of tracheoesophageal fistula repair ...

<https://www.sciencedirect.com/science/article/pii/S095281801100314X>

Dec 01, 2011 · The anesthetic management of a neonate with a double-outlet right ventricle and associated tracheoesophageal fistula, who underwent repair of this fistula, is presented. 2. Case report. A 3.44 kg newborn boy was transferred to our ...

Cited by: 1 Author: Heather McClung, Rajeev Prasad, Roy S...

Publish Year: 2011

Anesthetic management for cesarean section in a patient ...

<https://springerplus.springeropen.com/articles/10.1186/s40064-016-2075-y>

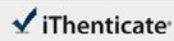
Apr 06, 2016 · We describe the anesthetic management for cesarean section in a pregnant woman with uncorrected double-outlet right ventricle. The anesthetic method, treatment of complications and lessons are discussed. A 28-year-old woman visited our emergency room for progressive dyspnea and recurrent hemoptysis at 30 weeks' gestation. Her New York Heart ...

Search Tools

Turn off Hover Translation (关闭翻译)

激活 Windows

转到“设置”以激活 Windows。



61438_Auto_Edited.docx

Quotes Excluded
Bibliography Excluded76%
SIMILAR

Name of Journal: *World Journal of Clinical Cases*

Manuscript NO: 61438

Manuscript Type: CASE REPORT

Anesthetic management of a child with double outlet right ventricle and severe polycythemia: a case report

Anesthesia of a DORV patient with severe polycythemia

Lingcan Tan, Weiyi Zhang, Yiding Zuo, Hongyang Chen, Chunling Jiang

Match Overview

Full

1	Internet 1475 words crawled on 21-Oct-2020 www.researchsquare.com	73%
2	Internet 17 words crawled on 29-Jan-2020 www.wjnet.com	1%
3	Internet 14 words crawled on 07-Oct-2020 publishing.bloob.core.windows.net	1%
4	Crossref 13 words Ingo Gottschalk, Judith S. Abel, Tina Menzel, Ulrike Herberg et al. "Prenatal diagnosis, associated findings and postnatal ...	1%
5	Crossref, Crossref Posted Content 12 words Lingcan Tan, Weiyi Zhang, Yiding Zuo, Hongyang Chen, Chunling Jiang. "Anesthetic Management of a Child From the	1%

激活 Windows
转到“设置”以激活 Windows。

国内版 国际版

Anesthetic management of a child with double outlet right ventricle



ALL IMAGES VIDEOS

42,400 Results

Any time ▾

(PDF) Anesthetic Management of a Unique Case of Double ...

<https://www.researchgate.net/publication/328192628...>



We report the case of a patient at 36 weeks of gestation, with a partially palliated **double-outlet right ventricle** and a Glenn shunt, who presented with severe dyspnea and worsening cyanosis.

Anesthetic management of tracheoesophageal fistula repair ...

<https://www.sciencedirect.com/science/article/pii/S095281801100314X>

Dec 01, 2011 · The **anesthetic management** of a neonate with a **double-outlet right ventricle** and associated tracheoesophageal fistula, who underwent repair of this fistula, is presented. 2. **Case report.** A 3.44 kg newborn boy was transferred to our hospital for further work-up of a cardiac anomaly.

Cited by: 1

Author: Heather McClung, Rajeev Prasad, Roy S...

Publish Year: 2011

[PDF] Anesthesia in Children with Congenital Heart Disease ...

ether.stanford.edu/library/pediatric_anesthesia...

Anesthesia In Children With Congenital Heart Disease Page 2 of 15 ... Polycythemia in older children
Single Ventricles Hypoplastic RV Double Outlet RV Transposition of the Great Arteries with an ASD or
VSD ... DORV Double outlet right ventricle. May be similar to ...

Anesthetic management for cesarean section in a patient ...

<https://springerplus.springeropen.com/articles/10.1186/s40064-016-2075-y> ▾

Apr 06, 2016 · We describe the **anesthetic management** for cesarean section in a pregnant woman with uncorrected **double-outlet right ventricle**. The **anesthetic method**, treatment of complications and lessons are discussed. A 28-year-old woman visited our emergency room for progressive dyspnea and recurrent hemoptysis at 30 weeks' gestation. Her New York Heart Association functional class was III–IV.

Cited by: 2

Author: Juan Gu, Yunxia Cai, Bin Liu, Sheng Lv

Publish Year: 2016

[PDF] Anesthetic management for cesarean section in a patient ...

<https://springerplus.springeropen.com/track/pdf/10.1186/s40064-016-2075-y>