

World Journal of *Clinical Cases*

World J Clin Cases 2021 April 26; 9(12): 2696-2950



Contents

Thrice Monthly Volume 9 Number 12 April 26, 2021

MINIREVIEWS

- 2696** Standardization of critical care management of non-critically ill patients with COVID-19
Wang CS, Gao Y, Kang K, Fei DS, Meng XL, Liu HT, Luo YP, Yang W, Dai QQ, Gao Y, Zhao MY, Yu KJ
- 2703** Mediastinal lymphadenopathy in COVID-19: A review of literature
Taweasedt PT, Surani S
- 2711** Polycystic ovary syndrome: Pathways and mechanisms for possible increased susceptibility to COVID-19
Ilias I, Goulas S, Zabuliene L

ORIGINAL ARTICLE

Clinical and Translational Research

- 2721** Circulating tumor cells with epithelial-mesenchymal transition markers as potential biomarkers for the diagnosis of lung cancer
Jiang SS, Mao CG, Feng YG, Jiang B, Tao SL, Tan QY, Deng B

Retrospective Study

- 2731** Management and implementation strategies of pre-screening triage in children during coronavirus disease 2019 pandemic in Guangzhou, China
Shi X, Cai YT, Cai X, Wen XL, Wang JY, Ma WC, Shen J, Wu JX, Liu HY, Sun J, He PQ, Lin Y, Zhao DY, Li PQ
- 2739** Clinicopathological features of superficial CD34-positive fibroblastic tumor
Ding L, Xu WJ, Tao XY, Zhang L, Cai ZG
- 2751** Application of a rapid exchange extension catheter technique in type B2/C nonocclusive coronary intervention *via* a transradial approach
Wang HC, Lu W, Gao ZH, Xie YN, Hao J, Liu JM

SYSTEMATIC REVIEWS

- 2763** Paradoxical relationship between proton pump inhibitors and COVID-19: A systematic review and meta-analysis
Zippi M, Fiorino S, Budriesi R, Micucci M, Corazza I, Pica R, de Biase D, Gallo CG, Hong W

META-ANALYSIS

- 2778** Predictive risk factors for recollapse of cemented vertebrae after percutaneous vertebroplasty: A meta-analysis
Ma YH, Tian ZS, Liu HC, Zhang BY, Zhu YH, Meng CY, Liu XJ, Zhu QS

CASE REPORT

- 2791** Malignant pheochromocytoma with cerebral and skull metastasis: A case report and literature review
Chen JC, Zhuang DZ, Luo C, Chen WQ
- 2801** Unresectable esophageal cancer treated with multiple chemotherapies in combination with chemoradiotherapy: A case report
Yura M, Koyanagi K, Hara A, Hayashi K, Tajima Y, Kaneko Y, Fujisaki H, Hirata A, Takano K, Hongo K, Yo K, Yoneyama K, Tamai Y, Dehari R, Nakagawa M
- 2811** Role of positron emission tomography in primary carcinoma ex pleomorphic adenoma of the bronchus: A case report
Yang CH, Liu NT, Huang TW
- 2816** Positive reverse transcription-polymerase chain reaction assay results in patients recovered from COVID-19: Report of two cases
Huang KX, He C, Yang YL, Huang D, Jiang ZX, Li BG, Liu H
- 2823** Laryngeal myxoma: A case report
Yu TT, Yu H, Cui Y, Liu W, Cui XY, Wang X
- 2830** Prostate stromal tumor with prostatic cysts after transurethral resection of the prostate: A case report
Zhao LW, Sun J, Wang YY, Hua RM, Tai SC, Wang K, Fan Y
- 2838** Intramuscular hematoma in rhabdomyolysis patients treated with low-molecular-weight heparin: Report of two cases
Yuan SY, Xie KF, Yang J
- 2845** Partial response to Chinese patent medicine Kangliu pill for adult glioblastoma: A case report and review of the literature
Sun G, Zhuang W, Lin QT, Wang LM, Zhen YH, Xi SY, Lin XL
- 2854** Behcet's disease manifesting as esophageal variceal bleeding: A case report
Xie WX, Jiang HT, Shi GQ, Yang LN, Wang H
- 2862** Successful endoscopic surgery for emphysematous pyelonephritis in a non-diabetic patient with autosomal dominant polycystic kidney disease: A case report
Jiang Y, Lo R, Lu ZQ, Cheng XB, Xiong L, Luo BF
- 2868** Robotically assisted removal of pelvic splenosis fifty-six years after splenectomy: A case report
Tognarelli A, Faggioni L, Erba AP, Faviana P, Durante J, Manassero F, Selli C
- 2874** Pulmonary alveolar proteinosis complicated with nocardiosis: A case report and review of the literature
Wu XK, Lin Q
- 2884** Detection of EGFR-SEPT14 fusion in cell-free DNA of a patient with advanced gastric cancer: A case report
Kim B, Kim Y, Park I, Cho JY, Lee KA

- 2890** Timing of convalescent plasma therapy-tips from curing a 100-year-old COVID-19 patient using convalescent plasma treatment: A case report
Liu B, Ren KK, Wang N, Xu XP, Wu J
- 2899** Torsades de pointes episode in a woman with high-grade fever and inflammatory activation: A case report
Qiu H, Li HW, Zhang SH, Zhou XG, Li WP
- 2908** Salivary duct carcinoma of the submandibular gland presenting a diagnostic challenge: A case report
Uchihashi T, Kodama S, Sugauchi A, Hiraoka S, Hirose K, Usami Y, Tanaka S, Kogo M
- 2916** Allogeneic hematopoietic stem cell transplantation in a 3-year-old boy with congenital pyruvate kinase deficiency: A case report
Ma ZY, Yang X
- 2923** Congenital bilateral cryptorchidism in an infant conceived after maternal breast cancer treatment: A case report
Hu WK, Liu J, Liu RX, Liu XW, Yin CH
- 2930** Sclerosing polycystic adenosis of the submandibular gland: Two case reports
Wu L, Wang Y, Hu CY, Huang CM
- 2937** Budd-Chiari syndrome associated with liver cirrhosis: A case report
Ye QB, Huang QF, Luo YC, Wen YL, Chen ZK, Wei AL
- 2944** Separated root tip formation associated with a fractured tubercle of dens evaginatus: A case report
Wu ZF, Lu LJ, Zheng HY, Tu Y, Shi Y, Zhou ZH, Fang LX, Fu BP

ABOUT COVER

Editorial Board Member of *World Journal of Clinical Cases*, Jing Liu, MD, PhD, Chief Doctor, Professor, Department of Neonatology and NICU, Beijing Chaoyang District Maternal and Child Healthcare Hospital, Beijing 100021, China. liujingbj@live.cn

AIMS AND SCOPE

The primary aim of *World Journal of Clinical Cases* (WJCC, *World J Clin Cases*) is to provide scholars and readers from various fields of clinical medicine with a platform to publish high-quality clinical research articles and communicate their research findings online.

WJCC mainly publishes articles reporting research results and findings obtained in the field of clinical medicine and covering a wide range of topics, including case control studies, retrospective cohort studies, retrospective studies, clinical trials studies, observational studies, prospective studies, randomized controlled trials, randomized clinical trials, systematic reviews, meta-analysis, and case reports.

INDEXING/ABSTRACTING

The WJCC is now indexed in Science Citation Index Expanded (also known as SciSearch®), Journal Citation Reports/Science Edition, Scopus, PubMed, and PubMed Central. The 2020 Edition of Journal Citation Reports® cites the 2019 impact factor (IF) for WJCC as 1.013; IF without journal self cites: 0.991; Ranking: 120 among 165 journals in medicine, general and internal; and Quartile category: Q3. The WJCC's CiteScore for 2019 is 0.3 and Scopus CiteScore rank 2019: General Medicine is 394/529.

RESPONSIBLE EDITORS FOR THIS ISSUE

Production Editor: Ji-Hong Lin; Production Department Director: Xiang Li; Editorial Office Director: Jin-Lai Wang.

NAME OF JOURNAL

World Journal of Clinical Cases

ISSN

ISSN 2307-8960 (online)

LAUNCH DATE

April 16, 2013

FREQUENCY

Thrice Monthly

EDITORS-IN-CHIEF

Dennis A Bloomfield, Sandro Vento, Bao-Gan Peng

EDITORIAL BOARD MEMBERS

<https://www.wjgnet.com/2307-8960/editorialboard.htm>

PUBLICATION DATE

April 26, 2021

COPYRIGHT

© 2021 Baishideng Publishing Group Inc

INSTRUCTIONS TO AUTHORS

<https://www.wjgnet.com/bpg/gerinfo/204>

GUIDELINES FOR ETHICS DOCUMENTS

<https://www.wjgnet.com/bpg/GerInfo/287>

GUIDELINES FOR NON-NATIVE SPEAKERS OF ENGLISH

<https://www.wjgnet.com/bpg/gerinfo/240>

PUBLICATION ETHICS

<https://www.wjgnet.com/bpg/GerInfo/288>

PUBLICATION MISCONDUCT

<https://www.wjgnet.com/bpg/gerinfo/208>

ARTICLE PROCESSING CHARGE

<https://www.wjgnet.com/bpg/gerinfo/242>

STEPS FOR SUBMITTING MANUSCRIPTS

<https://www.wjgnet.com/bpg/GerInfo/239>

ONLINE SUBMISSION

<https://www.f6publishing.com>



Torsades de pointes episode in a woman with high-grade fever and inflammatory activation: A case report

Hui Qiu, Hong-Wei Li, Shu-Hong Zhang, Xiao-Ge Zhou, Wei-Ping Li

ORCID number: Hui Qiu 0000-0002-1026-083X; Hong-Wei Li 0000-0001-5900-7088; Shu-Hong Zhang 0000-0001-8526-4002; Xiao-Ge Zhou 0000-0002-3942-7103; Wei-Ping Li 0000-0002-5534-5925.

Author contributions: Li WP and Qiu H conceived and designed the study; Qiu H was involved in data collection and analysis and drafting the article; Li HW participated in performance of the research; Zhang SH and Zhou XG performed the pathologic analyses and interpretation; Li WP revised the paper and had primary responsibility for final content; all authors issued final approval for the version to be submitted.

Supported by the Beijing Key Clinical Subject Program and Beijing Municipal Administration of Hospitals Incubating Program, No. PX2018002.

Informed consent statement: Informed written consent was obtained from the patient for publication of this report and any accompanying images.

Conflict-of-interest statement: The authors declare that they have no conflict of interest to disclose.

CARE Checklist (2016) statement: The authors have read the CARE Checklist (2016), and the

Hui Qiu, Hong-Wei Li, Wei-Ping Li, Department of Cardiology, Beijing Friendship Hospital, Capital Medical University, Beijing 100050, China

Shu-Hong Zhang, Xiao-Ge Zhou, Department of Pathology, Beijing Friendship Hospital, Capital Medical University, Beijing 100050, China

Corresponding author: Wei-Ping Li, MD, PhD, Chief Doctor, Professor, Department of Cardiology, Beijing Friendship Hospital, Capital Medical University, No. 95 Yong'an Road, Xicheng District, Beijing 100050, China. xueer09@163.com

Abstract

BACKGROUND

QT interval prolongation can induce torsades de pointes (TdP), a potentially fatal ventricular arrhythmia. Recently, an increasing number of non-cardiac drugs have been found to cause QT prolongation and/or TdP onset. Moreover, recent findings have demonstrated the key roles of systemic inflammatory activation and fever in promoting long-QT syndrome (LQTS) and TdP development.

CASE SUMMARY

A 30-year-old woman was admitted with a moderate to high-grade episodic fever for two weeks. The patient was administered with multiple antibiotics after hospitalization but still had repeating fever and markedly elevated C-reactive protein. Once after a high fever, the patient suddenly lost consciousness, and electrocardiogram (ECG) showed transient TdP onset after frequent premature ventricular contraction. The patient recovered sinus rhythm and consciousness spontaneously, and post-TdP ECG revealed a prolonged QTc interval of 560 ms. The patient's clinical manifestations and unresponsiveness to the antibiotics led to the final diagnosis of adult-onset Still's disease (AOSD). There was no evidence of cardiac involvement. After the AOSD diagnosis, discontinuation of antibiotics and immediate initiation of intravenous dexamethasone administration resulted in the normal temperature and QTc interval. The genetic analysis identified that the patient and her father had heterozygous mutations in *KCNH2* (c.1370C>T) and *AKAP9* (c.7725A>C). During the 2-year follow-up period, the patient had no recurrence of any arrhythmia and maintained normal QTc interval.

CONCLUSION

This case study highlights the risk of systemic inflammatory activation and antibiotic-induced TdP/LQTS onset. Genetic analysis should be considered to identify individuals at high risk of developing TdP.

manuscript was prepared and revised according to the CARE Checklist (2016).

Open-Access: This article is an open-access article that was selected by an in-house editor and fully peer-reviewed by external reviewers. It is distributed in accordance with the Creative Commons Attribution NonCommercial (CC BY-NC 4.0) license, which permits others to distribute, remix, adapt, build upon this work non-commercially, and license their derivative works on different terms, provided the original work is properly cited and the use is non-commercial. See: <http://creativecommons.org/licenses/by-nc/4.0/>

Manuscript source: Unsolicited manuscript

Specialty type: Cardiac and cardiovascular systems

Country/Territory of origin: China

Peer-review report's scientific quality classification

Grade A (Excellent): 0
Grade B (Very good): B
Grade C (Good): C, C
Grade D (Fair): 0
Grade E (Poor): 0

Received: January 1, 2021

Peer-review started: January 1, 2021

First decision: January 24, 2021

Revised: February 7, 2021

Accepted: February 24, 2021

Article in press: February 24, 2021

Published online: April 26, 2021

P-Reviewer: Gurzu S, Lazzerini PE

S-Editor: Zhang H

L-Editor: Wang TQ

P-Editor: Wu YXJ



Key Words: Torsades de pointes; Long QT syndrome; Adult-onset Still's disease; Antibiotics; Inflammation; Case report

©The Author(s) 2021. Published by Baishideng Publishing Group Inc. All rights reserved.

Core Tip: Torsades de pointes (TdP) is a life-threatening arrhythmia and may be caused by congenital long QT syndrome (cLQTS) or acquired LQTS (aLQTS). Meanwhile, aLQTS may share a similar genetic background with cLQTS. Here, we present a case of TdP episode during the combination of antibiotics for high-grade fever of unexplained origin before a confirmed diagnosis of adult-onset Still's disease (AOSD). This case study highlights the importance of early diagnosis of AOSD, the key role of systemic inflammatory activation, and the risk of antibiotic-induced TdP/LQTS onset. Genetic analysis should be considered to identify individuals at high risk of developing TdP.

Citation: Qiu H, Li HW, Zhang SH, Zhou XG, Li WP. Torsades de pointes episode in a woman with high-grade fever and inflammatory activation: A case report. *World J Clin Cases* 2021; 9(12): 2899-2907

URL: <https://www.wjgnet.com/2307-8960/full/v9/i12/2899.htm>

DOI: <https://dx.doi.org/10.12998/wjcc.v9.i12.2899>

INTRODUCTION

Torsades de pointes (TdP) is a rare but distinctive form of arrhythmia or polymorphic ventricular tachycardia characterized by the abnormal twisting of the QRS complex peaks around the isoelectric line. It has been well established that several pathological conditions and even drug toxicity can induce prolonged or abnormal repolarization (QT interval prolongation and/or abnormally twisted T or T/U wave morphology), resulting in TdP development, which in turn leads to ventricular fibrillation and sudden cardiac death. QT intervals represent the duration of the total action potential during the ventricular polarization and depolarization events. Essentially, long QT syndrome (LQTS) can be categorized as congenital (cLQTS) or acquired (aLQTS), and either of these can cause TdP pathogenesis. Recently, an increasing number of drugs, especially non-cardiac drugs that modulate cardiac repolarization, have been found to be associated with prolonged QT interval and occasional TdP onset^[1]. It has been revealed that both aLQTS and cLQTS may share similar genetic variants for their pathogenesis^[2-4]. In this context, the individual genetic background could be an important player, even in the presence of slight QT interval prolongation, because in association with appropriate pathogenic triggers, it may aggravate the life-threatening manifestations of aLQTS^[5]. Here, we present the case study of TdP episode in a 30-year-old woman who underwent multiple courses of antibiotic treatments for high-grade fever of unexplained origin until diagnosed with adult-onset Still's disease (AOSD), a rare systemic inflammatory disease with unknown etiology. The Yamaguchi criteria are the most popular of several proposed diagnostic criteria for AOSD, with fever of approximately 39 °C for at least a week, typical salmon colored rash, arthralgia or arthritis for at least 2 wk, and leukocytosis as major criteria, and sore throat, lymphadenopathy, liver dysfunction, negative rheumatoid factor, and antinuclear antibody as minor criteria^[6].

CASE PRESENTATION

Chief complaints

A 30-year-old woman was admitted with a moderate to high-grade fever (maximum of 40.5 °C) lasting for two weeks.

History of present illness

The patient complained of sore throat and skin rashes in the first three days and had

no shortness of breath, chest pain, cough, expectoration, hemoptysis, amaurosis, or arthralgia.

History of past illness

The patient had no considerable relevant medical history.

Personal and family history

The patient had no family history of either cardiovascular disease or sudden death.

Physical examination

On physical examination, the patient's body temperature was recorded 38.2 °C, heart rate was 115 beats per min, respiratory rate was 23 breaths per minute, and blood pressure was 90/60 mmHg. The cardiopulmonary examination was unremarkable.

Laboratory examinations

Initial laboratory tests showed moderate leukocytosis ($15.83 \times 10^9/L$) with predominant neutrophils (92.5%), anemia (hemoglobin 98 g/L), significantly elevated C-reactive protein (CRP, > 160 mg/L), erythrocyte sedimentation rate (95 mm/h), and serum ferritin (1362.7 ng/mL), and slightly elevated troponin I (0.116 ng/mL) along with normal creatine kinase-MB (CK-MB). Serum electrolyte examinations exhibited normal levels of potassium (3.74 mmol/L), sodium (133.1 mmol/L), and calcium (1.91 mmol/L). All relevant microbial cultures and specific antibody testing for infectious agents were also negative. An autoantibody panel including anti-nucleic acid, anti-double stranded deoxyribonucleic acid, anti-ENA, anti-neutrophil cytoplasmic, anti-rheumatoid factor, and anti-streptolysin O antibodies was tested negative. Cervical lymph node biopsy indicated symptoms of lymphocytic hyperplasia. The follow-up immunohistochemical analysis revealed that lymphocytic proliferation was mainly due to the T cell proliferation. Bone marrow puncture indicated that the proliferation of granulocytes was significantly active, and the proportions of intermediate and advanced granulocyte stages were significantly increased. Cellular morphology analysis suggested infection-associated reactive hyperplasia of the granulosa.

Imaging examinations

Abdominal ultrasonography exhibited the signs of splenomegaly. The 12-lead electrocardiogram (ECG) showed a regular sinus rhythm with a normal QTc of 440 ms. Transthoracic echocardiography demonstrated a normal cardiac structure and left ventricular ejection fraction of 71%. The chest X-ray examination suggested suspected pneumonia.

FINAL DIAGNOSIS

The patient was administered with multiple antibiotics including imipenem-cilastatin sodium, azithromycin, norvancomycin, moxifloxacin hydrochloride, and voriconazole within 2 wk, but still had repeating fever. During an episode of high fever and chills, the patient experienced palpitations. Immediate ECG examination indicated the presence of frequent premature ventricular contractions (PVCs) (Figure 1A). After 2 min, the patient suddenly lost consciousness, and ECG showed TdP onset at that point (Figure 1B). About 20 s later, she regained consciousness spontaneously, while post-TdP ECG revealed a sinus rhythm with a prolonged QTc interval of 560 ms (Figure 1C) and slightly reduced serum potassium level (3.50 mmol/L) compared to the previous serum test. The biochemical markers, including N-terminal pro-B-type natriuretic peptide, troponin I, CK-MB, aspartate aminotransferase, and alanine aminotransferase, were not elevated at this stage. However, CRP level remained extremely high (> 160 mg/L) when TdP occurred. Repeating episodes of PVCs were recorded immediately after infusion of linezolid to treat pneumonia, and that disappeared after initiating the treatment with intravenous lidocaine. Clinical manifestations of a spiking fever, skin rash, leukocytosis, elevated ferritin levels, splenomegaly, and unresponsiveness to multiple broad-spectrum antibiotics led to the final diagnosis of AOSD.

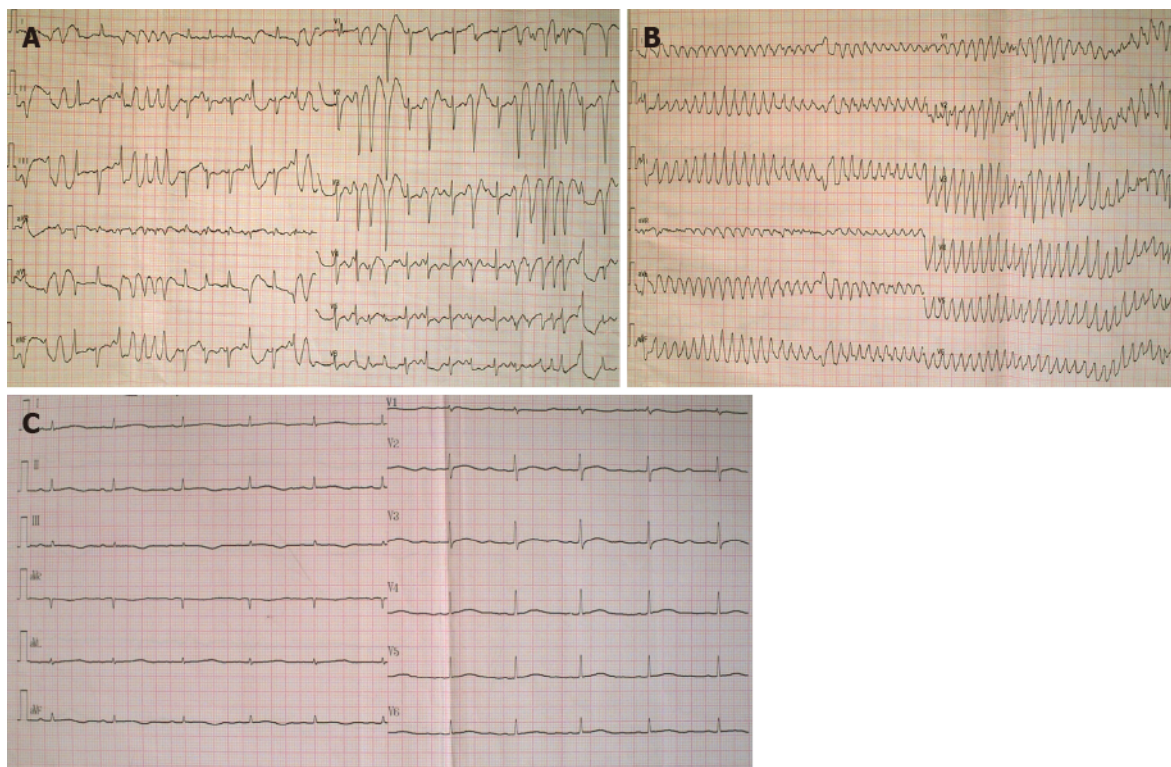


Figure 1 Electrocardiogram before and after Torsades de pointes. A: Electrocardiogram (ECG) exhibited frequent premature ventricular contractions (PVCs) during an attack of high fever and chills; B: ECG when the patient suddenly lost consciousness showed Torsades de pointes (TdP) after PVCs; C: ECG after TdP onset showed a sinus rhythm with a prolonged corrected QT interval of 560 ms.

TREATMENT

After the diagnosis of AOSD, all antibiotic therapies were stopped and intravenous dexamethasone (5 mg) administration was initiated once daily for two days, which helped quickly restore the normal body temperature and white blood cell count. Dexamethasone therapy exhibited rapid improvement of the elevated CRP level to the normal range (9 mg/L) in 5 d. The 24-h ambulatory ECG monitoring 2 d after the TdP episode exhibited a normal sinus rhythm and 25 ventricular premature beats. Moreover, the QTc interval was gradually shortened to the normal range (444 ms), and serious ventricular arrhythmia did not recur. Cardiac magnetic resonance imaging (CMRI) showed normal cardiac structure and function without early and late gadolinium enhancement. To further explore the possible mechanism underlying TdP onset, we performed the genetic testing with the patient's and her immediate family member's blood samples. Peripheral blood samples were collected from the patient, her mother, and her father. Total genomic DNA was extracted from peripheral blood samples of all subjects using a blood DNA extraction kit (TIANGEN, Beijing, China). Targeted gene capture sequencing was performed by MyGenostics (Beijing, China). Briefly, biotinylated capture probes were designed for the exons of 74 genes related to the cardiovascular system, and then sequencing was performed using Illumina HiSeq 2000 Next-Generation Sequencing platform, and the sequencing data were analyzed by a professional bioinformatics analyst (MyGenostics, Beijing, China). Clinically relevant genetic variants from the proband and parental samples were confirmed by Sanger sequencing. The genetic inheritance analysis further verified that the patient and her father, with a QTc interval of 490 ms, had heterozygous mutations in the genes *KCNH2* (c.1370C>T) and *AKAP9* (c.7725A>C), while her mother, with a normal QTc interval, had no relevant genetic mutations detected (Figures 2 and 3).

OUTCOME AND FOLLOW-UP

The patient was discharged 23 d after the admission without any further instructions to continue corticosteroid therapy. During the 2-year follow-up, the patient did not experience any sort of recurrence of arrhythmia and consistently maintained a normal

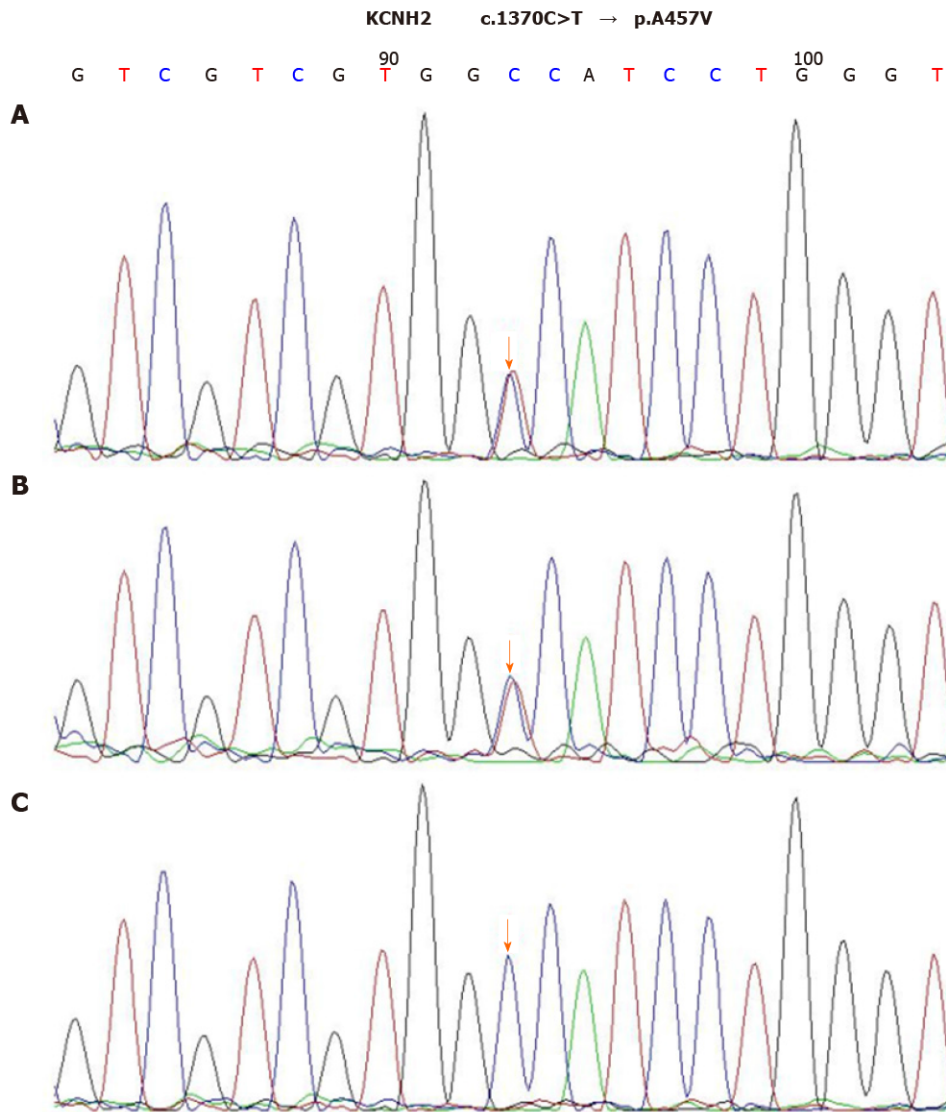


Figure 2 Sequence chromatograms of *KCNH2*. A and B: The patient and her father had a heterozygous mutation of c.1370C>T (orange arrow); C: Her mother had no relevant genetic mutations detected (orange arrow).

QTc interval.

DISCUSSION

TdP is a rare form of fatal arrhythmia usually associated with prolonged QT interval syndrome. Here, we present a case of AOSD in a 30-year old female patient showing long QTc interval complicated with TdP. The key question that we attempted to address here is whether TdP could be induced by the involvement of myocardial dysfunction related to AOSD or the LQTS.

AOSD is a systemic inflammatory disorder presenting daily abruptly spiking fevers, leukocytosis, evanescent rash, and arthritis. It is a rare disease of unknown etiology, and its clinical presentation varies greatly from patient to patient. The diagnosis is mostly clinical and not based upon serology. The Yamaguchi criteria are the most popular of several proposed clinical diagnostic criteria for AOSD^[7]. Because of the serosal involvement, cardiac manifestations in AOSD are usually in the form of pericarditis, while myocarditis is rare^[8]. We confirmed that the patient in this report met Yamaguchi criteria for AOSD but had no clinical evidence of cardiac involvement otherwise because of her normal results of myocardial enzyme tests, ECG, and CMRI examinations. Therefore, LQTS was speculated to possibly cause the TdP onset.

LQTS, including cLQTS or aLQTS, is characterized by QT prolongation and T-wave abnormalities due to delayed ventricular repolarization. cLQTS is clinically

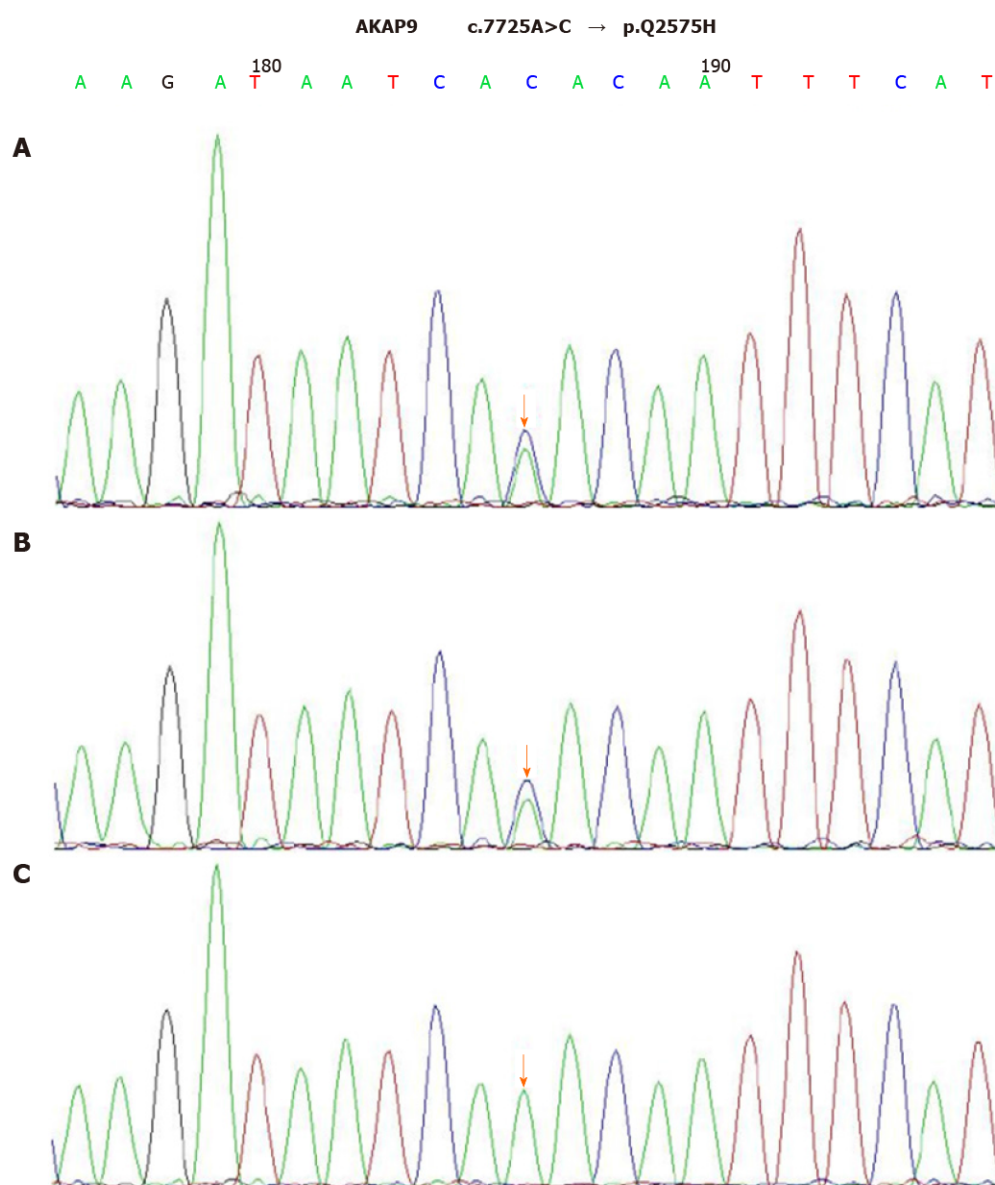


Figure 3 Sequence chromatograms of AKAP9. A and B: The patient and her father had a heterozygous mutation of c.7725A>C (orange arrow); C: Her mother had no relevant genetic mutations detected (orange arrow).

uncommon, estimated as 1:2500. It has been reported that this is a result of mutations in genes encoding or regulating cardiac ion channels. Clinically, cLQTS patients often first present recurring episodes of syncope and/or seizure, then subsequent ECG reveals prolonged QT interval. Clinical scoring systems in combination with genetic testing can be used to assist the precise diagnosis of cLQTS, particularly in cases of borderline QT intervals or equivocal clinical history. In this report, the patient had a normal baseline QT interval, and the cumulative LQTS risk score calculated using the 2011 LQTS diagnostic criteria was 1 point, which indicated a low probability of cLQTS^[8].

The common causes of aLQTS are side-reactions of QT-prolonging drugs, electrolyte disturbances, and bradyarrhythmias. Although rarely, some non-cardiac drugs such as antibiotics have recently been found to cause QT prolongation and/or TdP onset. In 2010 and 2019, two studies using the United States Food and Drug Administration Adverse Event Reporting System indicated macrolides, fluoroquinolones, and linezolid as TdP-inducing agents^[9,10]. Macrolides, fluoroquinolones, and the azole antifungal agents are well-known to prolong QT *via* blockade of the rapidly activating delayed rectifier potassium channel (hERG/IKr channel). The combined therapy of these QT-prolonging drugs, in this case, could increase the risk of TdP pathogenesis. There is increasing awareness of the impact of gender and gonadal steroids on human cardiac rhythm and episodes of arrhythmias. For example, women have been shown

to be more susceptible to develop TdP when using drugs that alter ventricular repolarization^[11-13]. In addition, both clinical and experimental data implicated gonadal steroids (estradiol and testosterone) as determinants of gender-related differences in repolarization. Notably, estradiol is considered to promote QTc lengthening, while progesterone and testosterone shorten QTc. Prolonged repolarization, transmural dispersion, and early after-depolarizations are critical factors for the induction of TdP. Together, these factors can establish pathogenically preferred conditions predisposing females a greater risk for proarrhythmic effects of drugs^[14,15]. It is now becoming evident that sex hormones play an important role in cardiac repolarization and the maintenance of QT interval.

Another striking feature of this case is the combination of systemic inflammatory activation and episodic high fever upon long QTc and TdP onset. An emerging body of evidence indicates systemic inflammation as a potential cause of aLQTS *via* cytokine-mediated changes in cardiomyocyte ion channels^[16,17]. Many basic experiments demonstrated that induction of inflammatory cytokines, mainly tumor necrosis factor- α (TNF- α), interleukin-1 (IL-1), and interleukin-6 (IL-6), can directly cause the dysfunction of several cardiac ion channels, particularly K⁺ channels, leading to ventricular action potential duration (APD) prolongation. TNF- α /TNFR1 system can impair hERG/IKr function mainly by stimulating reactive oxygen species production in cardiomyocytes^[18]. In excised papillary muscles, IL-1 modified electrical properties *via* lipid second messengers generated by cyclo-oxygenase and lipoxygenase pathways^[19]. Aromolaran *et al*^[20] reported that IL-6 inhibition of IKr and the resulting prolongation of APD were mediated *via* IL-6R and Janus kinase pathway activation, and that formed the basis for the observed clinical QT interval prolongation. In patients with elevated CRP levels under different inflammatory conditions, QTc prolongation remained a common pathological hallmark. Interestingly, CRP reduction was associated with significant QTc shortening, which might correlate with the decrease of IL-6 level^[16]. Unfortunately, cytokine levels were not measured in this case; however, significantly elevated CRP levels reflected systemic inflammatory activation. Besides these direct effects, systemic inflammation might also indirectly favor LQTS/TdP-axis by several additional mechanisms, including the induction of episodic fever and related temperature-mediated changes in the biophysical properties of cardiac ion channels, particularly the hERG-channel. It has been shown that febrile temperature facilitates the development of LQTS by enhancing hERG degradation through altered K⁺ dependence^[21,22]. Fever is more likely to induce LQTS in conditions where hERG function is partially compromised, such as hypokalemia that may promote proarrhythmic potential of IKr blockers and other conditions associated with prolonged ventricular repolarization^[23].

Genetic channelopathies involving pathogenic mutations in 17 different genes have been currently identified in clinically diagnosed LQTS. LQTS-causing mutations have a prevalence ratio of approximately 1:2000 in apparently healthy live births. Mutations can involve genes encoding the channel-protein itself or ion channel regulatory proteins, resulting in either loss-of-function of one of the K⁺ currents or gain-of-function of the Na⁺ or Ca²⁺ currents. LQT1 (KCNQ1, 30%-35%), LQT2 (KCNH2, 20%-25%), and LQT3 (SCN5A, 5%-10%) represent most of genotype-positive cases^[24,25]. A number of lines of evidence suggest that genomic variants may contribute to variable susceptibility to drug-induced TdP onset. An international collaborative study showed that one-third of the patients with aLQTS carry cLQTS-related gene mutations, especially those on KCNH2 being more common^[5]. The case in our report had compound heterozygous mutations in KCNH2 and AKAP9 genes. Notably, IKr and IKs are two important K⁺ currents participating in ventricular repolarization. KCNH2 mutations produce defective hERG protein, resulting in a decrease in IKr activity, while AKAP9 mutations with a low frequency (< 1%) disrupt its interaction with KCNQ1, reducing cAMP-stimulated phosphorylation of KCNQ1 and abolishing IKs upregulation. Therefore, we conclude that TdP with long QTc, in this case, could be associated with the patient's genetic background and the acquired triggering effects from sex, antibiotics, high-grade systemic inflammation, and fever.

Now, a novel and more comprehensive classification of cardiac channelopathies has been proposed, distinguishing the "classic" inherited forms, related to genetic mutations, from the acquired forms, including drug-induced and more recently recognized inflammatory and fever-induced cardiac channelopathies^[5]. Furthermore, multiple QT-prolonging factors are also concomitantly required to significantly disrupt ventricular repolarization. Besides specific inherited or acquired channelopathies, drugs, and inflammation, physiological (*e.g.*, age, sex, common polymorphisms, autonomic changes, and exercise) or pathological conditions (*e.g.*, electrolyte imbalances, heart diseases) may be superimposed in an intricate and often

unpredictable scenario inducing TdP^[26].

CONCLUSION

This case study highlights the risk of systemic inflammatory activation and antibiotic-induced TdP/LQTS onset. Genetic analysis should be considered to identify individuals at high risk of developing TdP.

REFERENCES

- 1 **Yap YG**, Camm AJ. Drug induced QT prolongation and torsades de pointes. *Heart* 2003; **89**: 1363-1372 [PMID: [14594906](#) DOI: [10.1136/heart.89.11.1363](#)]
- 2 **Donger C**, Denjoy I, Berthet M, Neyroud N, Cruaud C, Bennaceur M, Chivoret G, Schwartz K, Coumel P, Guicheney P. KVLQT1 C-terminal missense mutation causes a forme fruste long-QT syndrome. *Circulation* 1997; **96**: 2778-2781 [PMID: [9386136](#) DOI: [10.1161/01.cir.96.9.2778](#)]
- 3 **Makita N**, Horie M, Nakamura T, Ai T, Sasaki K, Yokoi H, Sakurai M, Sakuma I, Otani H, Sawa H, Kitabatake A. Drug-induced long-QT syndrome associated with a subclinical SCN5A mutation. *Circulation* 2002; **106**: 1269-1274 [PMID: [12208804](#) DOI: [10.1161/01.cir.0000027139.42087.b6](#)]
- 4 **Yang P**, Kanki H, Drolet B, Yang T, Wei J, Viswanathan PC, Hohnloser SH, Shimizu W, Schwartz PJ, Stanton M, Murray KT, Norris K, George AL Jr, Roden DM. Allelic variants in long-QT disease genes in patients with drug-associated torsades de pointes. *Circulation* 2002; **105**: 1943-1948 [PMID: [11997281](#) DOI: [10.1161/01.cir.0000014448.19052.4c](#)]
- 5 **Itoh H**, Crotti L, Aiba T, Spazzolini C, Denjoy I, Fressart V, Hayashi K, Nakajima T, Ohno S, Makiyama T, Wu J, Hasegawa K, Mastantuono E, Dagradi F, Pedrazzini M, Yamagishi M, Berthet M, Murakami Y, Shimizu W, Guicheney P, Schwartz PJ, Horie M. The genetics underlying acquired long QT syndrome: impact for genetic screening. *Eur Heart J* 2016; **37**: 1456-1464 [PMID: [26715165](#) DOI: [10.1093/eurheartj/ehv695](#)]
- 6 **Yamaguchi M**, Ohta A, Tsunematsu T, Kasukawa R, Mizushima Y, Kashiwagi H, Kashiwazaki S, Tanimoto K, Matsumoto Y, Ota T. Preliminary criteria for classification of adult Still's disease. *J Rheumatol* 1992; **19**: 424-430 [PMID: [1578458](#)]
- 7 **Zhao DB**, Dai SM, Liu XP, Xu H. Interstitial inflammation in visceral organs is a pathologic feature of adult-onset Still's disease. *Rheumatol Int* 2011; **31**: 923-927 [PMID: [19882158](#) DOI: [10.1007/s00296-009-1228-5](#)]
- 8 **Schwartz PJ**, Crotti L. QTc behavior during exercise and genetic testing for the long-QT syndrome. *Circulation* 2011; **124**: 2181-2184 [PMID: [22083145](#) DOI: [10.1161/CIRCULATIONAHA.111.062182](#)]
- 9 **Poluzzi E**, Raschi E, Motola D, Moretti U, De Ponti F. Antimicrobials and the risk of torsades de pointes: the contribution from data mining of the US FDA Adverse Event Reporting System. *Drug Saf* 2010; **33**: 303-314 [PMID: [20297862](#) DOI: [10.2165/11531850-000000000-00000](#)]
- 10 **Teng C**, Walter EA, Gaspar DKS, Obodozie-Ofoegbu OO, Frei CR. Torsades de pointes and QT prolongation Associations with Antibiotics: A Pharmacovigilance Study of the FDA Adverse Event Reporting System. *Int J Med Sci* 2019; **16**: 1018-1022 [PMID: [31341415](#) DOI: [10.7150/ijms.34141](#)]
- 11 **Moss AJ**, Schwartz PJ, Crampton RS, Tzivoni D, Locati EH, MacCluer J, Hall WJ, Weitzkamp L, Vincent GM, Garson A Jr. The long QT syndrome. Prospective longitudinal study of 328 families. *Circulation* 1991; **84**: 1136-1144 [PMID: [1884444](#) DOI: [10.1161/01.cir.84.3.1136](#)]
- 12 **Hashiba K**. Sex differences in phenotypic manifestation and gene transmission in the Romano-Ward syndrome. *Ann N Y Acad Sci* 1992; **644**: 142-156 [PMID: [1562113](#) DOI: [10.1111/j.1749-6632.1992.tb31008.x](#)]
- 13 **Lehmann MH**, Timothy KW, Frankovich D, Fromm BS, Keating M, Locati EH, Taggart RT, Towbin JA, Moss AJ, Schwartz PJ, Vincent GM. Age-gender influence on the rate-corrected QT interval and the QT-heart rate relation in families with genotypically characterized long QT syndrome. *J Am Coll Cardiol* 1997; **29**: 93-99 [PMID: [8996300](#) DOI: [10.1016/s0735-1097\(96\)00454-8](#)]
- 14 **Pham TV**, Rosen MR. Sex, hormones, and repolarization. *Cardiovasc Res* 2002; **53**: 740-751 [PMID: [11861044](#) DOI: [10.1016/s0008-6363\(01\)00429-1](#)]
- 15 **Salem JE**, Alexandre J, Bachelot A, Funck-Brentano C. Influence of steroid hormones on ventricular repolarization. *Pharmacol Ther* 2016; **167**: 38-47 [PMID: [27452340](#) DOI: [10.1016/j.pharmthera.2016.07.005](#)]
- 16 **Lazzerini PE**, Laghi-Pasini F, Bertolozzi I, Morozzi G, Lorenzini S, Simpatico A, Selvi E, Bacarelli MR, Finizola F, Vanni F, Lazaro D, Aromolaran A, El Sherif N, Boutjdir M, Capecchi PL. Systemic inflammation as a novel QT-prolonging risk factor in patients with torsades de pointes. *Heart* 2017; **103**: 1821-1829 [PMID: [28490617](#) DOI: [10.1136/heartjnl-2016-311079](#)]
- 17 **Lazzerini PE**, Capecchi PL, Laghi-Pasini F. Systemic inflammation and arrhythmic risk: lessons from rheumatoid arthritis. *Eur Heart J* 2017; **38**: 1717-1727 [PMID: [27252448](#) DOI: [10.1093/eurheartj/ehw208](#)]
- 18 **Wang J**, Wang H, Zhang Y, Gao H, Nattel S, Wang Z. Impairment of HERG K(+) channel function

- by tumor necrosis factor- α : role of reactive oxygen species as a mediator. *J Biol Chem* 2004; **279**: 13289-13292 [PMID: [14973143](#) DOI: [10.1074/jbc.C400025200](#)]
- 19 **Li YH**, Rozanski GJ. Effects of human recombinant interleukin-1 on electrical properties of guinea pig ventricular cells. *Cardiovasc Res* 1993; **27**: 525-530 [PMID: [8490954](#) DOI: [10.1093/cvr/27.3.525](#)]
- 20 **Aromolaran AS**, Srivastava U, Ali A, Chahine M, Lazaro D, El-Sherif N, Capecchi PL, Laghi-Pasini F, Lazzerini PE, Boutjdir M. Interleukin-6 inhibition of hERG underlies risk for acquired long QT in cardiac and systemic inflammation. *PLoS One* 2018; **13**: e0208321 [PMID: [30521586](#) DOI: [10.1371/journal.pone.0208321](#)]
- 21 **Zhao Y**, Wang T, Guo J, Yang T, Li W, Koichopolos J, Lamothe SM, Kang Y, Ma A, Zhang S. Febrile temperature facilitates hERG/IKr degradation through an altered K(+) dependence. *Heart Rhythm* 2016; **13**: 2004-2011 [PMID: [27321242](#) DOI: [10.1016/j.hrthm.2016.06.019](#)]
- 22 **Burashnikov A**, Shimizu W, Antzelevitch C. Fever accentuates transmural dispersion of repolarization and facilitates development of early afterdepolarizations and torsade de pointes under long-QT Conditions. *Circ Arrhythm Electrophysiol* 2008; **1**: 202-208 [PMID: [19649147](#) DOI: [10.1161/CIRCEP.107.691931](#)]
- 23 **Guo J**, Zhan S, Lees-Miller JP, Teng G, Duff HJ. Exaggerated block of hERG (KCNH2) and prolongation of action potential duration by erythromycin at temperatures between 37 degrees C and 42 degrees C. *Heart Rhythm* 2005; **2**: 860-866 [PMID: [16051125](#) DOI: [10.1016/j.hrthm.2005.04.029](#)]
- 24 **El-Sherif N**, Turitto G, Boutjdir M. Congenital Long QT syndrome and torsade de pointes. *Ann Noninvasive Electrocardiol* 2017; **22** [PMID: [28670758](#) DOI: [10.1111/anec.12481](#)]
- 25 **Lazzerini PE**, Capecchi PL, El-Sherif N, Laghi-Pasini F, Boutjdir M. Emerging Arrhythmic Risk of Autoimmune and Inflammatory Cardiac Channelopathies. *J Am Heart Assoc* 2018; **7**: e010595 [PMID: [30571503](#) DOI: [10.1161/JAHA.118.010595](#)]
- 26 **Roden DM**. Repolarization reserve: a moving target. *Circulation* 2008; **118**: 981-982 [PMID: [18765386](#) DOI: [10.1161/CIRCULATIONAHA.108.798918](#)]



Published by **Baishideng Publishing Group Inc**
7041 Koll Center Parkway, Suite 160, Pleasanton, CA 94566, USA

Telephone: +1-925-3991568

E-mail: bpgoffice@wjgnet.com

Help Desk: <https://www.f6publishing.com/helpdesk>

<https://www.wjgnet.com>

