

## HAEMOPTYSIS - A RARE PRESENTATION OF AORTIC ANE ...

<https://www.ncbi.nlm.nih.gov/pmc/articles/PMC2853042>

Haemoptysis in aortic aneurysm is very rare, caused by erosion of trachea by the aneurysm or rupture of aneurysm into the lung. A patient who presented with haemoptysis had a large mediastinal mass on X - Ray chest. CT Scan demonstrated a large aneurysm of ascending aorta and arch of aorta. The patient is VDRL Reactive.

Cited by: 3

Author: Girija Nair, Savita Jindal, Abhishek Chan...

Publish Year: 2008

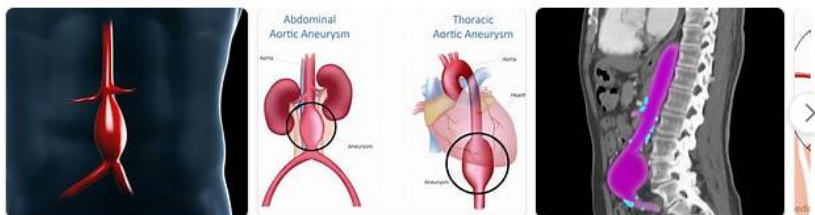
## Med Sci Exam 2 Flashcards | Quizlet

<https://quizlet.com/535257043/med-sci-exam-2-flash-cards> ▾

symptoms- dyspnea cough, hemoptysis, extrapulmonary symptoms (ex: joint pain) interstitial lung disease. ... clinical present: dyspnea, pleuritic chest pain, hemoptysis, palpitations, leg edema/pain, tachypnea ... abdominal aortic aneurysm. Presentation - Ruptured-Triad - hypotension, shooting abdominal or back pain, and a pulsatile abdominal ...

## Images of Pheochromocytoma With Abdominal Aortic Aneur...

<bing.com/images>



See all images >

### PEOPLE ALSO ASK

What are the symptoms of an abdominal aortic aneurysm? ▾

 [Add the Give with Bing extension](#)

Any time •

<https://www.researchgate.net/publication/258205245>.

We report a rare case of coexistent pheochromocytoma and abdominal aortic aneurysm (AAA). The patient was a 72-year-old man who presented to the Emergency Department with severe dyspnea and

<https://pubs.asahq.org/anesthesiology/article/115/...> •

THORACOABDOMINAL aortic aneurysm (TAAA) repair presents a challenging and complex task for both the surgeon and anesthesiologist. Historically, morbidity and mortality for TAAA repair has been high, an

Cited by: 15

Author: Stephen B Vaughn, Scott A LeMaire, Charlie

Cited by: 15  
Publish Year: 2013

[bing.com/images](http://bing.com/images)

[See all images >](#)

<https://www.sciencedirect.com/science/article/pii/S1561881117300901>

**Dec 01, 2017:** The symptoms of **aortic aneurysm** are chest pain, **dyspnea**, congestive heart failure by dilation of aortic root and aortic regurgitation, cerebral infarction by thromboembolism, renal infarction,...

**Author:** Mayank Gupta, Vijay Garg, Vinesh Pati. **Publish Year:** 2017

Author's address: *Department of Psychology, University of York, York YO1 5DD, UK*

Published Year: 2017

<https://www.ahajournals.org/doi/10.1161/CIR.0b013e3181d4739e>

Abdominal aortic aneurysm (AAA): aneurysm involving the infradiaphragmatic abdominal aorta. Aortic dissection (AoD): disruption of the media layer of the aorta with bleeding within and along the wall of the

Cited by: 16

Author: Loren E. Hiratzka, George L. Bakris, Joshua

Cited by: 1641  
Publish Year: 2010

#### PEOPLE ALSO ASK

What are the symptoms of an abdominal aortic aneurysm?

Are thoracic aortic aneurysms asymptomatic?

What are symptoms of hypertensive aneurysm?

How is an aortic aneurysm lined with thrombus?

### Feedback

<https://www.sciencedirect.com/science/article/pii/S1873959810700302>

Jun 01, 2010 - **Case Report** An 81-year-old man presented at our emergency depart- ment with sudden onset of shortness of breath and dys- pnea 1 hour previously. He stated that he had not choked before...

<https://medicalcasereports.biomedcentral.com/> ...

Jul 18, 2008 · Mycobacterium tuberculosis may cause a large variety of clinical presentations due to its ability to disseminate by contiguity or hematogenously. Tuberculosis may remain undiagnosed for years.

<https://stanfordhealthcare.org/.../abdominal-aortic-aneurysm/symptoms.html>

Most people with abdominal aortic aneurysms don't have symptoms. But symptoms may occur if the aneurysm gets bigger and puts pressure on surrounding organs. The most common symptom is general

<https://emedicine.medscape.com/article/424904-clinical>

Apr 02, 2021 - The most common complication of AAAs is rupture with life-threatening hemorrhage manifesting as pain and hypotension. The triad of abdominal pain, hypotension, and

<https://www.symptoma.com/en/ddx/aortic-aneurysm...> -

We report a case of fatal massive retroperitoneal hemorrhage caused by the rupture of an abdominal aortic aneurysm (AAA) in which postmortem computed tomography (PMCT) and [ncbi.nlm.nih.gov](http://ncbi.nlm.nih.gov).

29-Apr-2021 01:47PM
1634 words • 33 matches • 11 sources
FAO

iThenticate®
61518\_Auto\_EditedC.docx
Quotes Included: 23%  
Bibliography Included: 0%

**Name of Journal:** *World Journal of Clinical Cases*

**Manuscript NO:** 61518

**Manuscript Type:** CASE REPORT

**Pheochromocytoma with abdominal aortic aneurysm presenting as recurrent dyspnea, hemoptysis, and hypotension: A case report**

Zhao HY *et al.* Pheochromocytoma presenting as dyspnea, hemoptysis, hypotension

Hai-Yang Zhao, Yong-Zhen Zhao, Yu-Mei Jia, Xue Mei, Shu-Bin Guo

**Abstract**

**BACKGROUND**

Pheochromocytomas are rare endocrine tumors with various clinical manifestations, few of them might present with profound, life-threatening conditions.

**CASE SUMMARY**

**Match Overview**

1	Crossref 93 words Whiteside, B. C., J. K. Praeger, O. G. Mustafa, K. M. Schult e, P. A. Hopkins, J. A. Gilbert, A. M. McGregor, and S. J. ...	5%
2	Internet 87 words crawled on 21-Sep-2020 journals.lww.com	5%
3	Crossref 70 words Christina Matadaj, Jadelis Giquei, Ricardo Martinez Ruiz "Concomitant elective resection of pheochromocytoma i ...	4%
4	Internet 49 words crawled on 07-Oct-2020 ispublishing.blob.core.windows.net	3%
5	Crossref 26 words Renhua Wu, Nanwei Tong, Xinlei Chen, Shishi Xu, Fang Zhang, Lichi Tang, Yunwei Zhang "Pheochromocytoma i ...	2%
6	Internet 17 words crawled on 22-Mar-2019 academic.oup.com	1%
7	Internet 16 words crawled on 20-Jul-2010 lib.braininfo.pl	1%
8	Internet 15 words www.ncbi.nlm.nih.gov	1%

PAGE: 1 OF 7

Text Only Report

国内版 国际版

Pheochromocytoma with abdominal aortic aneurysm presenting as



ALL IMAGES VIDEOS

52,900 Results Any time ▾

### (PDF) Concomitant elective resection of pheochromocytoma ...

<https://www.researchgate.net/publication/258205245...>

We report a rare case of coexistent pheochromocytoma and abdominal aortic aneurysm (AAA). The patient was a 72-year-old man who presented to the Emergency Department with severe dyspnea and ...

### Case Scenario | Anesthesiology | American Society of ...

<https://pubs.asahq.org/anesthesiology/article/115/5/1093/12863/Case-Scenario...> ▾

THORACOABDOMINAL aortic aneurysm (TAAA) repair presents a challenging and complex task for both the surgeon and anesthesiologist. Historically, morbidity and mortality for TAAA repair has been high, and is both surgeon- and institution-dependent. However, the TAAA complication rate has improved significantly in the past decade via research, improved surgical technique, and perioperative ...

Cited by: 15 Author: Stephen B Vaughn, Scott A LeMaire, Cha...

Publish Year: 2011

#### PEOPLE ALSO ASK

Are thoracic aortic aneurysms asymptomatic? ▾

What is abdominal aortic aneurysm? ▾

What causes chest pain after an aortic aneurysm? ▾

Can an aortic aneurysm cause internal bleeding? ▾

Feedback

### Ruptured Aortic Aneurysm Presenting as a Stridor ...

<https://www.sciencedirect.com/science/article/pii/S1873959810700302>

Jun 01, 2010 · Case Report An 81-year-old man presented at our emergency department with sudden onset of shortness of breath and dyspnea 1 hour previously. He stated that he had not choked before arrival at our emergency department, did not have a sore throat, cough, hemoptysis, fever, body weight loss, history of asthma or recent chest trauma, and did ...

Author: Feng Lin, Chang-Chih Chen, Chang-C... Publish Year: 2010