



ALL

IMAGES

VIDEOS

245,000 Results

Any time ▾

Open links in new tab



Granular cell tumors, also called **Abrikossof's tumors**, were originally described by Abrikossof A in 1926. The first case of a pancreatic granular cell tumor was described in 1975 and only 6 cases have been reported. We describe a case of granular cell tumor in the pancreas showing pancreatic duct obstruction.

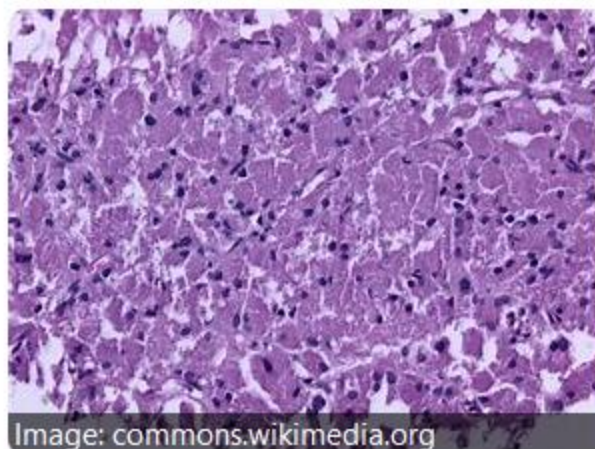


Image: commons.wikimedia.org

**Author:** Atsushi Kanno, Kennichi Satoh, Morihisa Hirota, Shin Hamada, Jun Umino, Hiromichi Itoh, Atsushi Masa...

**Cited by:** 9

**Publish Year:** 2010

[Granular cell tumor of the pancreas: A case report and ...](#)

► [pubmed.ncbi.nlm.nih.gov/21160931/](https://pubmed.ncbi.nlm.nih.gov/21160931/)

## Granular cell tumor

Granular cell tumor is a tumor that can develop on any skin or mucosal surface, but occurs on the tongue 40% of the time. It is also known as Abrikossoff's tumor, Granular cell myoblastoma, Granular cell nerve sheath tumor, and Granular cell schwannoma. Granular cell tumors affect females more often than males.



Wikipedia

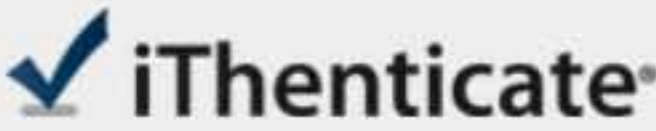Data from: Wikipedia

[Suggest an edit](#)

Was this helpful?

Search Tools

[Turn off Hover Translation \(关闭取词\)](#)



**Name of Journal:** *World Journal of Clinical Cases*

**Manuscript NO:** 61560

**Manuscript Type:** CASE REPORT

**Particular tumor of the pancreas:** A case report and review literature

Zhu MH *et al.* Particular tumor of the pancreas

Ming-Hui Zhu, Chang-Fu Nie

Match Overview

1 **Internet** 29 words  
crawled on 17-Jan-2021  
[www.wjgnet.com](http://www.wjgnet.com)

2%



ALL

IMAGES

VIDEOS



Add the Give with Bing extension &gt;

2,190,000 Results

Any time ▾

## Squamous Cell Carcinoma of the Pancreas: A Case Report ...

<https://pubmed.ncbi.nlm.nih.gov/27785278>

Primary squamous cell carcinoma (SCC) of the **pancreas** is an extremely rare **tumor** with the normal **pancreas** being entirely devoid of squamous cells. It, however, has been noted that during inflammatory episodes, squamous metaplasia of ductal columnar cells has been observed; however, transformation to ...

Cited by: 6

Author: Alan Brijbassie, Edward Stelow, Vanessa ...

Publish Year: 2014

## Search Tools

[Turn off Hover Translation \(关闭取词\)](#)

## Laparoscopic enucleation of Frantz's tumor of the pancreas ...

<https://pubmed.ncbi.nlm.nih.gov/33796288>

Presentation of **case**: The present study describes a 32-year-old female patient in whom a preoperative imaging diagnosis confirmed a mass in the junction of the **pancreas'** body and tail. Based on the anamnesis, the preoperative diagnosis, and the patient's general status, the decision was made to performed laparoscopic enucleation of the ...

## Images of Particular tumor of the pancreas A Case report An...

<bing.com/images>