


World Journal of *Clinical Cases*

World J Clin Cases 2021 April 16; 9(11): 2419-2695



MINIREVIEWS

- 2419 Current status of radical laparoscopy for treating hepatocellular carcinoma with portal hypertension
Shen ZF, Liang X

ORIGINAL ARTICLE**Retrospective Cohort Study**

- 2433 Impact of type 2 diabetes on adenoma detection in screening colonoscopies performed in disparate populations
Joseph DF, Li E, Stanley III SL, Zhu YC, Li XN, Yang J, Ottaviano LF, Bucobo JC, Buscaglia JM, Miller JD, Veluvolu R, Follen M, Grossman EB

- 2446 Early colonoscopy and urgent contrast enhanced computed tomography for colonic diverticular bleeding reduces risk of rebleeding
Ochi M, Kamoshida T, Hamano Y, Ohkawara A, Ohkawara H, Kakinoki N, Yamaguchi Y, Hirai S, Yanaka A

Retrospective Study

- 2458 Relationship between mismatch repair protein, *RAS*, *BRAF*, *PIK3CA* gene expression and clinicopathological characteristics in elderly colorectal cancer patients
Fan JZ, Wang GF, Cheng XB, Dong ZH, Chen X, Deng YJ, Song X

Clinical Trials Study

- 2469 Possible effect of blonanserin on gambling disorder: A clinical study protocol and a case report
Shiina A, Hasegawa T, Iyo M

Observational Study

- 2478 Parents' experience of caring for children with type 1 diabetes in mainland China: A qualitative study
Tong HJ, Qiu F, Fan L
- 2487 Differences in dietary habits of people with vs without irritable bowel syndrome and their association with symptom and psychological status: A pilot study
Meng Q, Qin G, Yao SK, Fan GH, Dong F, Tan C

SCIENTOMETRICS

- 2503 Prognostic nomograms for predicting overall survival and cause-specific survival of signet ring cell carcinoma in colorectal cancer patients
Kou FR, Zhang YZ, Xu WR

CASE REPORT

- 2519** Cerebellar artery infarction with sudden hearing loss and vertigo as initial symptoms: A case report
Wang XL, Sun M, Wang XP
- 2524** Three-dimensional-printed custom-made patellar endoprosthesis for recurrent giant cell tumor of the patella: A case report and review of the literature
Wang J, Zhou Y, Wang YT, Min L, Zhang YQ, Lu MX, Tang F, Luo Y, Zhang YH, Zhang XL, Tu CQ
- 2533** Gastrointestinal-type chemotherapy prolongs survival in an atypical primary ovarian mucinous carcinoma: A case report
Wang Q, Niu XY, Feng H, Wu J, Gao W, Zhang ZX, Zou YW, Zhang BY, Wang HJ
- 2542** Neoadjuvant chemoradiotherapy followed by laparoscopic distal gastrectomy in advanced gastric cancer: A case report and review of literature
Liu ZN, Wang YK, Li ZY
- 2555** Extraosseous spinal epidural plasmocytoma associated with multiple myeloma: Two case reports
Cui JF, Sun LL, Liu H, Gao CP
- 2562** Endoscopic diagnosis of early-stage primary esophageal small cell carcinoma: Report of two cases
Er LM, Ding Y, Sun XF, Ma WQ, Yuan L, Zheng XL, An NN, Wu ML
- 2569** Nemaline myopathy with dilated cardiomyopathy and severe heart failure: A case report
Wang Q, Hu F
- 2576** Immunoglobulin D- λ/λ biclonal multiple myeloma: A case report
He QL, Meng SS, Yang JN, Wang HC, Li YM, Li YX, Lin XH
- 2584** Point-of-care ultrasound for the early diagnosis of emphysematous pyelonephritis: A case report and literature review
Xing ZX, Yang H, Zhang W, Wang Y, Wang CS, Chen T, Chen HJ
- 2595** Minimally invasive treatment of forearm double fracture in adult using Acumed forearm intramedullary nail: A case report
Liu JC, Huang BZ, Ding J, Mu XJ, Li YL, Piao CD
- 2602** *Klebsiella pneumoniae* infection secondary to spontaneous renal rupture that presents only as fever: A case report
Zhang CG, Duan M, Zhang XY, Wang Y, Wu S, Feng LL, Song LL, Chen XY
- 2611** Eltrombopag-related renal vein thromboembolism in a patient with immune thrombocytopenia: A case report
Wu C, Zhou XM, Liu XD
- 2619** *Cryptococcus* infection with asymptomatic diffuse pulmonary disease in an immunocompetent patient: A case report
Li Y, Fang L, Chang FQ, Xu FZ, Zhang YB

- 2627** Triple administration of osimertinib followed by chemotherapy for advanced lung adenocarcinoma: A case report
Hu XY, Fei YC, Zhou WC, Zhu JM, Lv DL
- 2634** Anesthetic management of a child with double outlet right ventricle and severe polycythemia: A case report
Tan LC, Zhang WY, Zuo YD, Chen HY, Jiang CL
- 2641** Combined immune checkpoint inhibitors of CTLA4 and PD-1 for hepatic melanoma of unknown primary origin: A case report
Cheng AC, Lin YJ, Chiu SH, Shih YL
- 2649** Cholangiojejunostomy for multiple biliary ducts in living donor liver transplantation: A case report
Xiao F, Sun LY, Wei L, Zeng ZG, Qu W, Liu Y, Zhang HM, Zhu ZJ
- 2655** Surgical therapy for hemangioma of the azygos vein arch under thoracoscopy: A case report
Wang ZX, Yang LL, Xu ZN, Lv PY, Wang Y
- 2662** Calcium pyrophosphate deposition disease of the temporomandibular joint invading the middle cranial fossa: Two case reports
Tang T, Han FG
- 2671** Rare histological subtype of invasive micropapillary carcinoma in the ampulla of Vater: A case report
Noguchi H, Higashi M, Idichi T, Kurahara H, Mataka Y, Tasaki T, Kitazono I, Ohtsuka T, Tanimoto A
- 2679** Contrast-enhanced ultrasound using SonoVue mixed with oral gastrointestinal contrast agent to evaluate esophageal hiatal hernia: Report of three cases and a literature review
Wang JY, Luo Y, Wang WY, Zheng SC, He L, Xie CY, Peng L
- 2688** Melatonin for an obese child with MC4R gene variant showing epilepsy and disordered sleep: A case report
Ge WR, Wan L, Yang G

ABOUT COVER

Editorial Board Member of *World Journal of Clinical Cases*, Hong-Tao Xu, MD, PhD, Chief Physician, Professor, Department of Pathology, The First Affiliated Hospital and College of Basic Medical Sciences of China Medical University, Shenyang 110001, Liaoning Province, China. xuht@cmu.edu.cn

AIMS AND SCOPE

The primary aim of *World Journal of Clinical Cases* (WJCC, *World J Clin Cases*) is to provide scholars and readers from various fields of clinical medicine with a platform to publish high-quality clinical research articles and communicate their research findings online.

WJCC mainly publishes articles reporting research results and findings obtained in the field of clinical medicine and covering a wide range of topics, including case control studies, retrospective cohort studies, retrospective studies, clinical trials studies, observational studies, prospective studies, randomized controlled trials, randomized clinical trials, systematic reviews, meta-analysis, and case reports.

INDEXING/ABSTRACTING

The WJCC is now indexed in Science Citation Index Expanded (also known as SciSearch®), Journal Citation Reports/Science Edition, Scopus, PubMed, and PubMed Central. The 2020 Edition of Journal Citation Reports® cites the 2019 impact factor (IF) for WJCC as 1.013; IF without journal self cites: 0.991; Ranking: 120 among 165 journals in medicine, general and internal; and Quartile category: Q3. The WJCC's CiteScore for 2019 is 0.3 and Scopus CiteScore rank 2019: General Medicine is 394/529.

RESPONSIBLE EDITORS FOR THIS ISSUE

Production Editor: Jia-Hui Li; Production Department Director: Yu-Jie Ma; Editorial Office Director: Jin-Li Wang.

NAME OF JOURNAL

World Journal of Clinical Cases

ISSN

ISSN 2307-8960 (online)

LAUNCH DATE

April 16, 2013

FREQUENCY

Thrice Monthly

EDITORS-IN-CHIEF

Dennis A Bloomfield, Sandro Vento, Bao-Gan Peng

EDITORIAL BOARD MEMBERS

<https://www.wjgnet.com/2307-8960/editorialboard.htm>

PUBLICATION DATE

April 16, 2021

COPYRIGHT

© 2021 Baishideng Publishing Group Inc

INSTRUCTIONS TO AUTHORS

<https://www.wjgnet.com/bpg/gerinfo/204>

GUIDELINES FOR ETHICS DOCUMENTS

<https://www.wjgnet.com/bpg/GerInfo/287>

GUIDELINES FOR NON-NATIVE SPEAKERS OF ENGLISH

<https://www.wjgnet.com/bpg/gerinfo/240>

PUBLICATION ETHICS

<https://www.wjgnet.com/bpg/GerInfo/288>

PUBLICATION MISCONDUCT

<https://www.wjgnet.com/bpg/gerinfo/208>

ARTICLE PROCESSING CHARGE

<https://www.wjgnet.com/bpg/gerinfo/242>

STEPS FOR SUBMITTING MANUSCRIPTS

<https://www.wjgnet.com/bpg/GerInfo/239>

ONLINE SUBMISSION

<https://www.f6publishing.com>

Cholangiojejunostomy for multiple biliary ducts in living donor liver transplantation: A case report

Fei Xiao, Li-Ying Sun, Lin Wei, Zhi-Gui Zeng, Wei Qu, Ying Liu, Hai-Ming Zhang, Zhi-Jun Zhu

ORCID number: Fei Xiao 0000-0001-9904-7746; Li-Ying Sun 0000-0003-1101-7994; Lin Wei 0000-0002-0435-3829; Zhi-Gui Zeng 0000-0003-1457-7495; Wei Qu 0000-0002-4484-5940; Ying Liu 0000-0001-9087-899X; Hai-Ming Zhang 0000-0003-4629-3913; Zhi-Jun Zhu 0000-0001-7031-2083.

Author contributions: Zhu ZJ, Sun LY, and Wei L contributed to study design; Zeng ZG, Qu W, and Liu Y contributed to data collection; Xiao F and Zhang HM contributed to data analysis and writing.

Supported by Capital's Funds for Health Improvement and Research, No. 2020-1-2024.

Informed consent statement: The patient provided informed verbal consent prior to study enrollment.

Conflict-of-interest statement: There are no conflicts of interest in relation to this report.

CARE Checklist (2016) statement: The authors have read the CARE Checklist (2016), and the manuscript was prepared and revised according to the CARE Checklist (2016).

Open-Access: This article is an open-access article that was selected by an in-house editor and fully peer-reviewed by external reviewers. It is distributed in accordance with the Creative

Fei Xiao, Liver Transplantation Center, National Clinical Research Center for Digestive Diseases, Beijing Friendship Hospital, Capital Medical University, Beijing 100050, China

Fei Xiao, Department of Organ Transplantation, Liao Cheng People's Hospital, Liaocheng 252000, Shandong Province, China

Li-Ying Sun, Zhi-Jun Zhu, Clinical Center for Pediatric Liver Transplantation, Capital Medical University, Beijing 100050, China

Li-Ying Sun, Zhi-Jun Zhu, Beijing Key Laboratory of Tolerance Induction and Organ Protection in Transplantation, Capital Medical University, Beijing 100050, China

Li-Ying Sun, Department of Intensive Care Unit, Beijing Friendship Hospital, Capital Medical University, Beijing 100050, China

Lin Wei, Zhi-Gui Zeng, Wei Qu, Ying Liu, Hai-Ming Zhang, Zhi-Jun Zhu, Liver Transplantation Center, National Clinical Research Center for Digestive Diseases, Capital Medical University, Beijing 100050, China

Corresponding author: Zhi-Jun Zhu, MD, PhD, Chief Doctor, Surgeon, Liver Transplantation Center, National Clinical Research Center for Digestive Diseases, Capital Medical University, No. 95 Yong'an Road, Xicheng District, Beijing 100050, China. zhu-zhijun@outlook.com

Abstract

BACKGROUND

Laparoscopic living donor hepatectomy (LLDH) has been successfully carried out in several transplant centers. Biliary reconstruction is key in living donor liver transplantation (LDLT). Reliable biliary reconstruction can effectively prevent postoperative biliary stricture and leakage. Although preoperative magnetic resonance cholangiopancreatography and intraoperative indocyanine green cholangiography have been shown to be helpful in determining optimal division points, biliary variability and limitations associated with LLDH, multiple biliary tracts are often encountered during surgery, which inhibits biliary reconstruction. A reliable cholangiojejunostomy for multiple biliary ducts has been utilized in LDLT. This procedure provides a reference for multiple biliary reconstructions after LLDH.

CASE SUMMARY

A 2-year-old girl diagnosed with ornithine transcarbamylase deficiency required

Commons Attribution
NonCommercial (CC BY-NC 4.0)
license, which permits others to
distribute, remix, adapt, build
upon this work non-commercially,
and license their derivative works
on different terms, provided the
original work is properly cited and
the use is non-commercial. See: <http://creativecommons.org/licenses/by-nc/4.0/>

Manuscript source: Unsolicited
manuscript

Specialty type: Medicine, research
and experimental

Country/Territory of origin: China

**Peer-review report's scientific
quality classification**

Grade A (Excellent): 0
Grade B (Very good): 0
Grade C (Good): C, C
Grade D (Fair): 0
Grade E (Poor): 0

Received: December 12, 2020

Peer-review started: December 12,
2020

First decision: December 24, 2020

Revised: December 26, 2020

Accepted: January 27, 2021

Article in press: January 27, 2021

Published online: April 16, 2021

P-Reviewer: Qiao Z, Sintusek P

S-Editor: Zhang L

L-Editor: Webster JR

P-Editor: Wang LL



liver transplantation. Due to the scarcity of deceased donors, she was put on the waiting list for LDLT. Her father was a suitable donor; however, after a rigorous evaluation, preoperative magnetic resonance cholangiopancreatography examination of the donor indicated the possibility of multivessel variation in the biliary tract. Therefore, a laparoscopic left lateral section was performed on the donor, which met the estimated graft-to-recipient weight ratio. Under intraoperative indocyanine green cholangiography, 4 biliary tracts were confirmed in the graft. It was difficult to reform the intrahepatic bile ducts due to their openings of more than 5 mm. A reliable cholangiojejunostomy was, therefore, utilized: Suture of the jejunum to the adjacent liver was performed around the bile duct openings with 6/0 absorbable sutures. At the last follow-up (1 year after surgery), the patient was complication-free.

CONCLUSION

Intrahepatic cholangiojejunostomy is reliable for multiple biliary ducts after LLDH in LDLT.

Key Words: Cholangiojejunostomy; Living donor liver transplantation; Laparoscopic left lateral section; Multiple biliary ducts; Treatment; Case report

©The Author(s) 2021. Published by Baishideng Publishing Group Inc. All rights reserved.

Core Tip: A patient diagnosed with ornithine transcarbamylase deficiency required liver transplant surgery. After developing a binding surgical plan, we decided to perform a living-donor liver transplantation, using a laparoscopic donor liver resection. However, multiple biliary tracts were observed. We used “Plug-in” anastomosis for cholangiojejunostomy and received satisfactory results.

Citation: Xiao F, Sun LY, Wei L, Zeng ZG, Qu W, Liu Y, Zhang HM, Zhu ZJ. Cholangiojejunostomy for multiple biliary ducts in living donor liver transplantation: A case report. *World J Clin Cases* 2021; 9(11): 2649-2654

URL: <https://www.wjgnet.com/2307-8960/full/v9/i11/2649.htm>

DOI: <https://dx.doi.org/10.12998/wjcc.v9.i11.2649>

INTRODUCTION

Biliary anastomosis is key in living donor liver transplantation (LDLT), with biliary complications varying from 5% to 40%. Biliary leaks and strictures are common complications. According to research, biliary complication rates of up to 53.7%, with anastomotic strictures occupying 41.5% of the complications^[1,2] were reported. Depending on laparoscopic surgical skills of resident surgeons, laparoscopic living donor hepatectomy (LLDH) has been performed in some transplant centers^[3]. Due to biliary anatomic variations and laparoscopic surgical limitations^[4], multiple hepatic duct orifices are often seen during surgery. A technical problem of bile duct reconstruction during LDLT, is caused by multiple biliary ducts that receive a poor blood supply from both donor and recipient^[5]. The impact of various graft biliary orifices on biliary complications in the recipient have not been established^[6]. The results of those receiving grafts with a single or paired bile ducts were compared in recent research. It was observed that living donor grafts with 2 biliary ducts are safe and have no negative influence on biliary complication rates after 1-year of follow-up^[7]. At another center, multiple anastomoses were performed during surgery. At a median follow-up of 36 mo, the biliary complication rate was 16.9%, greater than that with one biliary duct^[8]. This study describes cholangiojejunostomy for multiple biliary ducts during LDLT.

CASE PRESENTATION

Chief complaints

A 2-year-old girl was admitted to our center with complaints of hyperammonemia and lethargy for 4 mo.

History of present illness

For four months, the patient had experienced lethargy and intermittent abdominal pain. After seeing doctors in local hospitals, she was diagnosed with hyperammonemia. However, the disease could not be cured at local hospitals, therefore, she gradually developed liver failure.

History of past illness

The patient had no significant medical history and chronic diseases were denied.

Personal and family history

No significant personal and family medical history.

Physical examination

According to her physical examination, confusion, disorientation, and amnesia were noted. Muscular rigidity, nystagmus, overt hepatic encephalopathy and Grade III hepatic disease were also observed.

Laboratory examinations

Genetic testing revealed ornithine transcarbamylase deficiency (OTCD). Laboratory examinations upon admission revealed blood NH₃ level of 153 µmol/L, alanine aminotransferase (83 U/L), albumin (24.9 g/L), total bilirubin (4.8 µmol/L), direct bilirubin (0.5 µmol/L) and creatinine (4.3 µmol/L). Her prothrombin time was 19.50 s compared to the normalized ratio of 1.52.

Imaging examinations

Abdominal ultrasonography and computed tomography were unremarkable. Magnetic resonance cholangiopancreatography (MRCP) examination of the donor indicated the possibility of multivessel variation in the biliary tract (Figure 1).

FINAL DIAGNOSIS

Based on the above findings, OTCD was diagnosed.

TREATMENT

OTCD is a metabolic disease, protein diet restriction and medications that stimulate the removal of nitrogen from the body may prevent progression of the disease. Unfortunately, these measures cannot prevent the emergence of hyperammonemia and metabolic encephalopathy; thus, liver transplantation is indicated. Due to the scarcity of deceased donors, we proposed a laparoscopic left lateral sectionectomy in donors for liver transplantation among children. The liver graft includes the left lateral section (segments 2 and 3 based on Couinaud's classification), left branch of the hepatic artery and left portal branch, left bile duct, and left hepatic vein. Preoperative MRCP evaluation of donor biliary anatomy indicated bile duct variations (Figure 1). Intraoperative indocyanine green near-infrared fluorescence cholangiography was routinely performed (Figure 2A), and 4 biliary tracts were confirmed in the graft (Figure 2B), which inhibited bile duct reconstruction. The intrahepatic bile ducts cannot be joined because the gap between the two openings was too large. Suture of the jejunum to the nearby liver was performed around the bile duct opening with 6/0 absorbable sutures (Figure 2C). Surgical procedures were successfully completed after 6 h.

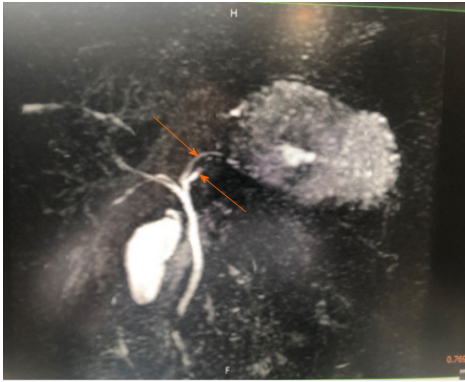


Figure 1 Preoperative magnetic resonance cholangiopancreatography evaluation of donor biliary anatomy indicated bile duct variations.

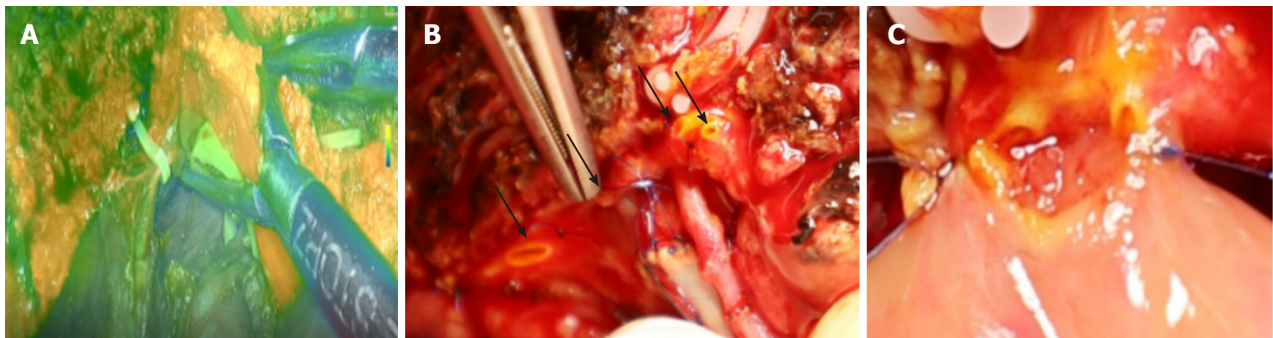


Figure 2 Fluorescence cholangiography. A: Intraoperative indocyanine green near-infrared fluorescence cholangiography was routinely performed; B: 4 biliary tracts were confirmed in the graft which inhibited bile duct reconstruction; C: The intrahepatic bile ducts cannot be joined as the gap between the two openings was too large. Suture of the jejunum to the nearby liver was performed around the bile duct opening with 6/0 absorbable sutures.

OUTCOME AND FOLLOW-UP

Ten days after surgery, the levels of serum total bilirubin, direct bilirubin, and alkaline phosphatase were close to normal. The absence of bile leakage within 1 wk necessitated the removal of the abdominal drainage tube and antibiotic prophylaxis (Sulbactam and Cefoperazone) was used 8 d after surgery. One year after surgery, there was no anastomotic stricture or cholangitis.

DISCUSSION

Cherqui *et al*^[9] indicated the feasibility of laparoscopic left lateral sectionectomy in pediatric LDLT. The laparoscopic approach can be used as normal practice for harvesting left lateral lobe liver grafts^[10]. A meta-analysis revealed that LLDH is a secure and efficient option for LDLT, which enhances the donors' perioperative results compared with open living donor hepatectomy^[11]. However, this technique is hampered by bile duct complications, especially in LLDH. Multiple factors lead to bile duct complications. One of the most important reasons is that LLDH can cause multiple bile ducts, which are a problem for the cholangiojejunostomy. Common biliary complications include stricture, leakage, obstruction, and stone formation. Deka *et al*^[12] revealed that the length of the left hepatic duct varied from 1.2 mm to 30.36 mm with a median value of 6.83 mm, which shows that the length of the left hepatic duct in half of the patients varied from 1.2 mm to 6.83 mm. Moreover, preoperative MRCP and direct intraoperative vision decides the division of the bile duct. However, it is not sufficient to determine the optimal cut-off point by these procedures as it is difficult to identify the left hepatic duct by direct vision and real-time positioning is impossible by preoperative MRCP. Hence, the surgeon may inadvertently cut too much to the left, to ensure that there is sufficient safety distance on the donor side, and sacrifice part of the length of the bile duct using Hemlok to cut the bile duct, leading to multiple orifices in the graft side.

Four bile ducts were found during surgery, thereby, making the duct-to-duct bile duct reconstruction impossible. Therefore, hepaticojejunostomy was considered. However, it is difficult to reconstruct the biliary tract with multiple orifice anastomoses, and the incidence of biliary stenosis and bile leakage are higher than normal^[13]. The pelvic anastomosis of multiple bile ducts adjacent to the hepatic duct stump, can effectively solve the problem of postoperative anastomotic stenosis. However, complications such as bile leakage are higher. Adjacent bile ducts subjected to plastic surgery have changed the physiological direction of the bile duct. The portal vein is compressed by biliary dilatation within the confines of the Glisson sheath, which leads to portal hypertension and persistent cholestasis, and increases the risk of cholangitis and septic events in the postoperative period. We used a “Plug-in” technique for bile duct anastomosis. Suture of the jejunum to the nearby liver was performed around the bile duct openings with intermittent 6/0 absorbable sutures. The jejunum was anastomosed with the liver tissue around the bile duct, and multiple bile duct openings were embedded in the jejunum. During the procedure, the anterior wall of the jejunum should be sutured as close as possible to the liver tissue above the anterior wall of the bile duct, in order to improve the migration of the jejunal mucosa through the liver section to the bile duct. To ensure suturing of the anastomosis, it is necessary to determine the position of each needle, especially during posterior wall anastomosis, to prevent the suture needle from penetrating the portal vein. Intermittent suture of the front wall of the anastomosis requires the inversion of the intestinal mucosa into the anastomosis, which is one of the important measures for preventing biliary leakage. Another key operation in the anastomosis is that the stitch length of the anastomotic suture and the tension of the knot is uniform. The needle can be inserted deeper when suturing, and the knot should not be too tight to prevent splitting the liver tissue. During the anastomosis, suture, traction and ligation should be gentle to avoid tearing the jejunum.

CONCLUSION

Laparoscopic living donor hepatectomy can be used in living donor liver transplantation but can lead to an increase in the number of bile ducts. The “Plug-in” cholangiojejunostomy for multiple biliary ducts is a reliable anastomosis technique.

REFERENCES

- 1 **Abu-Gazala S**, Olthoff KM, Goldberg DS, Shaked A, Abt PL. En Bloc Hilar Dissection of the Right Hepatic Artery in Continuity with the Bile Duct: a Technique to Reduce Biliary Complications After Adult Living-Donor Liver Transplantation. *J Gastrointest Surg* 2016; **20**: 765-771 [PMID: 26676929 DOI: 10.1007/s11605-015-3047-1]
- 2 **Rhu J**, Kim JM, Choi GS, David Kwon CH, Joh JW. Impact of Extra-anatomical Hepatic Artery Reconstruction During Living Donor Liver Transplantation on Biliary Complications and Graft and Patient Survival. *Transplantation* 2019; **103**: 1893-1902 [PMID: 30747851 DOI: 10.1097/TP.0000000000002601]
- 3 **Li H**, Wei Y, Li B. Total laparoscopic living donor right hemihepatectomy: first case in China mainland and literature review. *Surg Endosc* 2016; **30**: 4622-4623 [PMID: 26895910 DOI: 10.1007/s00464-016-4750-z]
- 4 **Wybourn CA**, Kitsis RM, Baker TA, Degner B, Sarker S, Luchette FA. Laparoscopic cholecystectomy for biliary dyskinesia: Which patients have long term benefit? *Surgery* 2013; **154**: 761-7; discussion 767 [PMID: 24074413 DOI: 10.1016/j.surg.2013.04.044]
- 5 **Chok KS**, Lo CM. Biliary complications in right lobe living donor liver transplantation. *Hepatol Int* 2016; **10**: 553-558 [PMID: 26932842 DOI: 10.1007/s12072-016-9710-0]
- 6 **Nakamura T**, Iida T, Ushigome H, Osaka M, Masuda K, Matsuyama T, Harada S, Nobori S, Yoshimura N. Risk Factors and Management for Biliary Complications Following Adult Living-Donor Liver Transplantation. *Ann Transplant* 2017; **22**: 671-676 [PMID: 29114099 DOI: 10.12659/aot.905485]
- 7 **Kollmann D**, Goldaracena N, Sapisochin G, Linares I, Selzner N, Hansen BE, Bhat M, Cattral MS, Greig PD, Lilly L, McGilvray ID, Ghanekar A, Grant DR, Selzner M. Living Donor Liver Transplantation Using Selected Grafts With 2 Bile Ducts Compared With 1 Bile Duct Does Not Impact Patient Outcome. *Liver Transpl* 2018; **24**: 1512-1522 [PMID: 30264930 DOI: 10.1002/lt.25197]
- 8 **Bhangui P**, Saha S. The high-end range of biliary reconstruction in living donor liver transplant. *Curr Opin Organ Transplant* 2019; **24**: 623-630 [PMID: 31397730 DOI: 10.1097/MOT.0000000000000693]

- 9 **Cherqui D**, Soubrane O, Husson E, Barshasz E, Vignaux O, Ghimouz M, Branchereau S, Chardot C, Gauthier F, Fagniez PL, Houssin D. Laparoscopic living donor hepatectomy for liver transplantation in children. *Lancet* 2002; **359**: 392-396 [PMID: [11844509](#) DOI: [10.1016/S0140-6736\(02\)07598-0](#)]
- 10 **Kim KH**, Jung DH, Park KM, Lee YJ, Kim DY, Kim KM, Lee SG. Comparison of open and laparoscopic live donor left lateral sectionectomy. *Br J Surg* 2011; **98**: 1302-1308 [PMID: [21717424](#) DOI: [10.1002/bjs.7601](#)]
- 11 **Xu J**, Hu C, Cao HL, Zhang ML, Ye S, Zheng SS, Wang WL. Meta-Analysis of Laparoscopic vs Open Hepatectomy for Live Liver Donors. *PLoS One* 2016; **11**: e0165319 [PMID: [27788201](#) DOI: [10.1371/journal.pone.0165319](#)]
- 12 **Deka P**, Islam M, Jindal D, Kumar N, Arora A, Negi SS. Analysis of biliary anatomy according to different classification systems. *Indian J Gastroenterol* 2014; **33**: 23-30 [PMID: [24006122](#) DOI: [10.1007/s12664-013-0371-9](#)]
- 13 **Jarnagin WR**, Fong Y, DeMatteo RP, Gonen M, Burke EC, Bodniewicz BS J, Youssef BA M, Klimstra D, Blumgart LH. Staging, resectability, and outcome in 225 patients with hilar cholangiocarcinoma. *Ann Surg* 2001; **234**: 507-517; discussion 517 [PMID: [11573044](#) DOI: [10.1097/0000658-200110000-00010](#)]



Published by **Baishideng Publishing Group Inc**
7041 Koll Center Parkway, Suite 160, Pleasanton, CA 94566, USA

Telephone: +1-925-3991568

E-mail: bpgoffice@wjgnet.com

Help Desk: <https://www.f6publishing.com/helpdesk>

<https://www.wjgnet.com>

