


World Journal of *Clinical Cases*

World J Clin Cases 2021 April 16; 9(11): 2419-2695



MINIREVIEWS

- 2419** Current status of radical laparoscopy for treating hepatocellular carcinoma with portal hypertension
Shen ZF, Liang X

ORIGINAL ARTICLE

Retrospective Cohort Study

- 2433** Impact of type 2 diabetes on adenoma detection in screening colonoscopies performed in disparate populations
Joseph DF, Li E, Stanley III SL, Zhu YC, Li XN, Yang J, Ottaviano LF, Bucobo JC, Buscaglia JM, Miller JD, Veluvolu R, Follen M, Grossman EB

- 2446** Early colonoscopy and urgent contrast enhanced computed tomography for colonic diverticular bleeding reduces risk of rebleeding
Ochi M, Kamoshida T, Hamano Y, Ohkawara A, Ohkawara H, Kakinoki N, Yamaguchi Y, Hirai S, Yanaka A

Retrospective Study

- 2458** Relationship between mismatch repair protein, *RAS*, *BRAF*, *PIK3CA* gene expression and clinicopathological characteristics in elderly colorectal cancer patients
Fan JZ, Wang GF, Cheng XB, Dong ZH, Chen X, Deng YJ, Song X

Clinical Trials Study

- 2469** Possible effect of blonanserin on gambling disorder: A clinical study protocol and a case report
Shiina A, Hasegawa T, Iyo M

Observational Study

- 2478** Parents' experience of caring for children with type 1 diabetes in mainland China: A qualitative study
Tong HJ, Qiu F, Fan L
- 2487** Differences in dietary habits of people with vs without irritable bowel syndrome and their association with symptom and psychological status: A pilot study
Meng Q, Qin G, Yao SK, Fan GH, Dong F, Tan C

SCIENTOMETRICS

- 2503** Prognostic nomograms for predicting overall survival and cause-specific survival of signet ring cell carcinoma in colorectal cancer patients
Kou FR, Zhang YZ, Xu WR

CASE REPORT

- 2519** Cerebellar artery infarction with sudden hearing loss and vertigo as initial symptoms: A case report
Wang XL, Sun M, Wang XP
- 2524** Three-dimensional-printed custom-made patellar endoprosthesis for recurrent giant cell tumor of the patella: A case report and review of the literature
Wang J, Zhou Y, Wang YT, Min L, Zhang YQ, Lu MX, Tang F, Luo Y, Zhang YH, Zhang XL, Tu CQ
- 2533** Gastrointestinal-type chemotherapy prolongs survival in an atypical primary ovarian mucinous carcinoma: A case report
Wang Q, Niu XY, Feng H, Wu J, Gao W, Zhang ZX, Zou YW, Zhang BY, Wang HJ
- 2542** Neoadjuvant chemoradiotherapy followed by laparoscopic distal gastrectomy in advanced gastric cancer: A case report and review of literature
Liu ZN, Wang YK, Li ZY
- 2555** Extraosseous spinal epidural plasmocytoma associated with multiple myeloma: Two case reports
Cui JF, Sun LL, Liu H, Gao CP
- 2562** Endoscopic diagnosis of early-stage primary esophageal small cell carcinoma: Report of two cases
Er LM, Ding Y, Sun XF, Ma WQ, Yuan L, Zheng XL, An NN, Wu ML
- 2569** Nemaline myopathy with dilated cardiomyopathy and severe heart failure: A case report
Wang Q, Hu F
- 2576** Immunoglobulin D- λ/λ biclonal multiple myeloma: A case report
He QL, Meng SS, Yang JN, Wang HC, Li YM, Li YX, Lin XH
- 2584** Point-of-care ultrasound for the early diagnosis of emphysematous pyelonephritis: A case report and literature review
Xing ZX, Yang H, Zhang W, Wang Y, Wang CS, Chen T, Chen HJ
- 2595** Minimally invasive treatment of forearm double fracture in adult using Acumed forearm intramedullary nail: A case report
Liu JC, Huang BZ, Ding J, Mu XJ, Li YL, Piao CD
- 2602** *Klebsiella pneumoniae* infection secondary to spontaneous renal rupture that presents only as fever: A case report
Zhang CG, Duan M, Zhang XY, Wang Y, Wu S, Feng LL, Song LL, Chen XY
- 2611** Eltrombopag-related renal vein thromboembolism in a patient with immune thrombocytopenia: A case report
Wu C, Zhou XM, Liu XD
- 2619** *Cryptococcus* infection with asymptomatic diffuse pulmonary disease in an immunocompetent patient: A case report
Li Y, Fang L, Chang FQ, Xu FZ, Zhang YB

- 2627** Triple administration of osimertinib followed by chemotherapy for advanced lung adenocarcinoma: A case report
Hu XY, Fei YC, Zhou WC, Zhu JM, Lv DL
- 2634** Anesthetic management of a child with double outlet right ventricle and severe polycythemia: A case report
Tan LC, Zhang WY, Zuo YD, Chen HY, Jiang CL
- 2641** Combined immune checkpoint inhibitors of CTLA4 and PD-1 for hepatic melanoma of unknown primary origin: A case report
Cheng AC, Lin YJ, Chiu SH, Shih YL
- 2649** Cholangiojejunostomy for multiple biliary ducts in living donor liver transplantation: A case report
Xiao F, Sun LY, Wei L, Zeng ZG, Qu W, Liu Y, Zhang HM, Zhu ZJ
- 2655** Surgical therapy for hemangioma of the azygos vein arch under thoracoscopy: A case report
Wang ZX, Yang LL, Xu ZN, Lv PY, Wang Y
- 2662** Calcium pyrophosphate deposition disease of the temporomandibular joint invading the middle cranial fossa: Two case reports
Tang T, Han FG
- 2671** Rare histological subtype of invasive micropapillary carcinoma in the ampulla of Vater: A case report
Noguchi H, Higashi M, Idichi T, Kurahara H, Mataka Y, Tasaki T, Kitazono I, Ohtsuka T, Tanimoto A
- 2679** Contrast-enhanced ultrasound using SonoVue mixed with oral gastrointestinal contrast agent to evaluate esophageal hiatal hernia: Report of three cases and a literature review
Wang JY, Luo Y, Wang WY, Zheng SC, He L, Xie CY, Peng L
- 2688** Melatonin for an obese child with MC4R gene variant showing epilepsy and disordered sleep: A case report
Ge WR, Wan L, Yang G

ABOUT COVER

Editorial Board Member of *World Journal of Clinical Cases*, Hong-Tao Xu, MD, PhD, Chief Physician, Professor, Department of Pathology, The First Affiliated Hospital and College of Basic Medical Sciences of China Medical University, Shenyang 110001, Liaoning Province, China. xuht@cmu.edu.cn

AIMS AND SCOPE

The primary aim of *World Journal of Clinical Cases* (WJCC, *World J Clin Cases*) is to provide scholars and readers from various fields of clinical medicine with a platform to publish high-quality clinical research articles and communicate their research findings online.

WJCC mainly publishes articles reporting research results and findings obtained in the field of clinical medicine and covering a wide range of topics, including case control studies, retrospective cohort studies, retrospective studies, clinical trials studies, observational studies, prospective studies, randomized controlled trials, randomized clinical trials, systematic reviews, meta-analysis, and case reports.

INDEXING/ABSTRACTING

The WJCC is now indexed in Science Citation Index Expanded (also known as SciSearch®), Journal Citation Reports/Science Edition, Scopus, PubMed, and PubMed Central. The 2020 Edition of Journal Citation Reports® cites the 2019 impact factor (IF) for WJCC as 1.013; IF without journal self cites: 0.991; Ranking: 120 among 165 journals in medicine, general and internal; and Quartile category: Q3. The WJCC's CiteScore for 2019 is 0.3 and Scopus CiteScore rank 2019: General Medicine is 394/529.

RESPONSIBLE EDITORS FOR THIS ISSUE

Production Editor: Jia-Hui Li; Production Department Director: Yun-Jie Ma; Editorial Office Director: Jin-Li Wang.

NAME OF JOURNAL

World Journal of Clinical Cases

ISSN

ISSN 2307-8960 (online)

LAUNCH DATE

April 16, 2013

FREQUENCY

Thrice Monthly

EDITORS-IN-CHIEF

Dennis A Bloomfield, Sandro Vento, Bao-Gan Peng

EDITORIAL BOARD MEMBERS

<https://www.wjnet.com/2307-8960/editorialboard.htm>

PUBLICATION DATE

April 16, 2021

COPYRIGHT

© 2021 Baishideng Publishing Group Inc

INSTRUCTIONS TO AUTHORS

<https://www.wjnet.com/bpg/gerinfo/204>

GUIDELINES FOR ETHICS DOCUMENTS

<https://www.wjnet.com/bpg/GerInfo/287>

GUIDELINES FOR NON-NATIVE SPEAKERS OF ENGLISH

<https://www.wjnet.com/bpg/gerinfo/240>

PUBLICATION ETHICS

<https://www.wjnet.com/bpg/GerInfo/288>

PUBLICATION MISCONDUCT

<https://www.wjnet.com/bpg/gerinfo/208>

ARTICLE PROCESSING CHARGE

<https://www.wjnet.com/bpg/gerinfo/242>

STEPS FOR SUBMITTING MANUSCRIPTS

<https://www.wjnet.com/bpg/GerInfo/239>

ONLINE SUBMISSION

<https://www.f6publishing.com>



Melatonin for an obese child with *MC4R* gene variant showing epilepsy and disordered sleep: A case report

Wen-Rong Ge, Lin Wan, Guang Yang

ORCID number: Wen-Rong Ge 0000-0002-1843-7302; Lin Wan 0000-0002-2409-3497; Guang Yang 0000-0001-8622-2146.

Author contributions: Ge WR, Wan L and Y G designed the research study; Ge WR and Wan L performed the research; Ge WR contributed to the analytic tools; Ge WR analyzed the data and wrote the manuscript; All authors have read and approved the final manuscript.

Supported by National Natural Science Foundation of China, No. 81671279; and Big Data and Artificial Intelligence Research and Development Project of the Chinese PLA General Hospital, No. 2019MBD-004.

Informed consent statement: The family were informed of the purpose of the study and provided written informed consent for the publication of this article. The study was conducted in accordance with the Declaration of Helsinki, and approved by the ethics committee of the First Medical Center of the PLA General Hospital (Beijing, China).

Conflict-of-interest statement: The authors declare that the research was conducted in the absence of any commercial or financial relationships that could be

Wen-Rong Ge, Department of Pediatrics, Beijing Friendship Hospital, Capital Medical University, Beijing 100000, China

Lin Wan, Guang Yang, Department of Pediatrics, The First Medical Center of Chinese PLA General Hospital, Beijing 100853, China

Corresponding author: Guang Yang, PhD, Professor, Department of Pediatrics, The First Medical Center of Chinese PLA General Hospital, No. 28 Fuxing Road, Haidian District, Beijing 100853, China. yangguang74@301hospital.com.cn

Abstract

BACKGROUND

Abnormalities in the *melanocortin receptor 4 (MC4R)* gene often lead to obesity, but are rarely associated with other conditions such as epilepsy and sleep disorder.

CASE SUMMARY

Here, we present a case of a male obese child with a heterozygous variant in *MC4R* (c.494G>A, p.Arg165Gln) inherited from his father, who presented with disordered sleep and abnormal facial movements. Examination through melatonin rhythm testing and electroencephalography led to a diagnosis of sleep disorder and epilepsy, as his melatonin rhythm was markedly distorted and the electroencephalography revealed epileptic discharges. He received treatment with an antiepileptic drug; however, the therapy was ineffective and the sleep disorder appeared to be deteriorating. Subsequently, we initiated adjuvant treatment with melatonin. Upon re-examination, his body mass index had decreased, the sleep disturbance had resolved, and his seizures were well controlled. Electroencephalography review was normal, and a typical melatonin rhythm was restored.

CONCLUSION

We concluded that, in addition to causing obesity, abnormalities in the *MC4R* gene may contribute to the development of sleep disorders and epilepsy, and that melatonin can be used as an adjuvant therapy to alleviate these symptoms.

Key Words: Melanocortin receptor 4; Obesity; Sleep disorders; Epilepsy; Melatonin; Case report

©The Author(s) 2021. Published by Baishideng Publishing Group Inc. All rights reserved.

construed as a potential conflict of interest.

CARE Checklist (2016) statement:

The authors have read the CARE Checklist (2016), and the manuscript was prepared and revised according to the CARE Checklist (2016).

Open-Access: This article is an open-access article that was selected by an in-house editor and fully peer-reviewed by external reviewers. It is distributed in accordance with the Creative Commons Attribution NonCommercial (CC BY-NC 4.0) license, which permits others to distribute, remix, adapt, build upon this work non-commercially, and license their derivative works on different terms, provided the original work is properly cited and the use is non-commercial. See: <http://creativecommons.org/licenses/by-nc/4.0/>

Manuscript source: Unsolicited manuscript

Specialty type: Medicine, research and experimental

Country/Territory of origin: China

Peer-review report's scientific quality classification

Grade A (Excellent): 0
Grade B (Very good): B
Grade C (Good): 0
Grade D (Fair): 0
Grade E (Poor): 0

Received: December 18, 2020

Peer-review started: December 18, 2020

First decision: January 17, 2021

Revised: January 18, 2021

Accepted: February 1, 2021

Article in press: February 1, 2021

Published online: April 16, 2021

P-Reviewer: Jiang XP

S-Editor: Gao CC

L-Editor: Filipodia

P-Editor: Liu JH



Core Tip: Numerous reports suggest that abnormalities of the *melanocortin receptor 4* (*MC4R*) gene may cause obesity, but are rarely associated with other conditions. The case presented in our manuscript involved a male obese child with a heterozygous variant in *MC4R* (c.494G>A, p.Arg165Gln) inherited from his father, who presented with epilepsy, sleep disorder and his melatonin rhythm was markedly distorted. This is the first report of the combination of these symptoms in a patient with an *MC4R* variant. Antiepileptic drug was ineffective and the sleep disorder appeared to be deteriorating. The use of melatonin relieved all his symptoms, and even the electroencephalography review was normal, and a typical melatonin rhythm was restored. We hope that our experience can help the early diagnosis and treatment of this condition.

Citation: Ge WR, Wan L, Yang G. Melatonin for an obese child with *MC4R* gene variant showing epilepsy and disordered sleep: A case report. *World J Clin Cases* 2021; 9(11): 2688-2695

URL: <https://www.wjgnet.com/2307-8960/full/v9/i11/2688.htm>

DOI: <https://dx.doi.org/10.12998/wjcc.v9.i11.2688>

INTRODUCTION

Melanocortin receptor 4 (MC4R), a key contributor to the regulation of energy balance and body weight in mammals, influences energy metabolism by sensing external signals that regulating appetite, as well as the activity of the autonomic nervous system and nervous endocrine system^[1]. Numerous reports suggest that abnormalities of the *MC4R* gene may cause obesity^[1-3]. Furthermore, MC4R is the receptor for melatonin; some studies have demonstrated that melatonin can act on the MC4R in the hypothalamus to generate a physiological sensation of satiety, thereby influencing appetite^[4]. Melatonin is also involved in sleep and epilepsy; patients with epilepsy are characterized by an increased phase shift of melatonin release. Melatonin can improve sleep disorder in children with epilepsy, resulting in statistically significant decreases in sleep latency and wakefulness after sleep onset^[5,6].

Here, we present a case of a clinically obese child with a variant in the *MC4R* gene, who had abnormal melatonin rhythms, sleep disturbances, and seizures.

CASE PRESENTATION

Chief complaints

A 7-year-old male patient with the chief complaint of obesity, seizure, and sleep disorder.

History of present illness

The case was a 7-year-old male patient, who presented in June 2018 with pain in both lower extremities, with no obvious cause. On presentation, the pain in the extremities was dull, mainly in the patient's calves, and did not significantly differ before and after exercise. He did not have walking difficulties and his gait was normal. He attended his local hospital, where he was diagnosed with "growth pain; malnutrition," and was prescribed an orally administered live *Bifidobacterium* preparation and calcium. His food intake increased substantially, accompanied by a marked increase in weight. Nighttime sleep, characterized by ease of waking and nightmares (2-3 times/night) and accompanied by physical movements, was simultaneously disordered. Moreover, he did not fall asleep until late at night (23:00 h) and awoke early in the morning (06:00 h), and took excessive naps during the daytime (4-5 times/d). Nevertheless, the lower extremity pain had improved, whereas he complained of gradual weakness of both lower limbs, fatigue, and activity intolerance, which was noticeable when he descended the stairs. He also had intermittent dizziness, with oculogyric crisis and tongue extension, which subsided after approximately 1-2 min, without losing consciousness. The patient was unaware of the oculogyric crisis and tongue extension. His cognition did not show an abnormality,

tests of Wechsler Intelligence Scale for Children were normal (IQ: 103) and he continued to attend school normally.

He was first admitted to our hospital in August 2018. Examination through electroencephalography (EEG) revealed a small number of paroxysmal high-wave amplitude (4-5 Hz) slow waves during waking and sleep periods; spikes were visible in the left front and central areas (Figure 1A). Magnetic resonance imaging of the brain showed normal findings. His height and weight were 125 cm and 36.4 kg, respectively, with a Rohrer index of 186.37 (Rohrer index > 156 indicates obesity; 140-156 is overweight); he was diagnosed with obesity and epilepsy. Levetiracetam was administered orally and the dose was gradually increased to 1000 mg (41.1 mg/kg). Treatment significantly relieved the weakness of both lower limbs. However, occasional dizziness, binocular oculogyric crisis, and involuntary tongue extension continued. EEG re-examination at our hospital in January 2019 revealed occasional, sporadic, moderate amplitude spikes in the left frontal area during sleep (Figure 1B). The parents of the patient reported that his weight remained significantly increased and his sleep disorder had deteriorated; he fell asleep at 00:00 h and awoke at 06:00 h, had nightmares (3-4 times/night) accompanied by involuntary limb movements, and napped 5-6 times/d. He was subsequently admitted to our department.

History of past illness

The case had an unremarkable medical history.

Personal and family history

The patient was born at term, with a birth weight of 3 kg. Growth and development prior to the onset of symptoms were normal and there was no obvious obesity. The patient was born through spontaneous delivery and had a normal Apgar score. There were no abnormalities noted during the perinatal period. His father was also obese, with height, weight, and body mass index of 173 cm, 88 kg, and 29 (> 97th percentile), respectively. However, he had no history or family history of sleep disorder or epilepsy.

Physical examination

At admission, his height, weight, and Rohrer index were 127 cm, 38.3 kg, and 186.98, respectively.

Laboratory examinations

Saliva samples were collected at 8:00, 12:00, 16:00 and 22:00 respectively, using non-cotton collection devices to avoid any interference with the assay result of salivary melatonin. Melatonin analyses were carried out using liquid chromatography tandem mass spectrometry as previously described^[7]. Peripheral blood samples were collected at 0:00, 8:00 and 16:00, and plasma adrenocorticotrophic hormone (ACTH) and cortisol levels were detected by using radioimmunological methods.

Testing showed that the melatonin secretion rhythm was reversed. There were no significant abnormalities in adrenocorticotrophic hormone (ACTH), cortisol concentration and rhythm, blood biochemistry, or thyroid hormones (Table 1).

Sequencing was conducted by Findrare genetic-testing companies. Briefly, peripheral blood samples of the proband and his parents were prepared using the IDT xGenExomeResearchPanel V1.0 (Integrated DNA Technologies, Coralville, IA, United States). Sequencing was performed using paired-end, 100-cycle chemistry on the Illumina HiSeq or NextSeq (Illumina, San Diego, CA, United States). The original data of genome sequencing were mapped to the human genome (UCSC h19 human genome assembly), the acquired variation was annotated, and the genetic variation was further screened according to the clinical phenotype. We used the American College of Medical Genetics guidelines for variant interpretation in order to classify the variants. The pathogenic or suspected pathogenic variants associated with clinical phenotypes were verified by Sanger sequencing. Based on the American College of Medical Genetics guidelines, we revealed a heterozygous likely pathogenic point variant, c.494G>A (p.Arg165Gln) in the *MC4R* gene, originating from the father. Sorting intolerant from tolerant and polymorphism phenotyping analysis predicted that the variant was harmful and associated with obesity (Figure 2).

Table 1 Laboratory test results before and after melatonin treatment

Factor	Time (normal as reference)	Before melatonin treatment	After melatonin treatment (7 mo later)
Melatonin (pg/mL)	8:00 (< 5)	10.56 ^a ↑	23.414 ^a ↑
	12:00 (< 5)	2.86	10.677 ^a ↑
	16:00 (< 5)	3.935	4.261
	22:00 (> 10)	4.107 ^a ↓	464.298
ACTH (pmol/L)	0:00 (0-8.7)	3.04	1.46
	8:00 (2.31-18)	8.75	2.66
	16:00 (1.7-16.7)	4.35	4.08
Cortisol (nmol/L)	0:00 (0-165.7)	25.7	82.66
	8:00 (98.7-797.5)	431.52	101.28
	16:00 (85.3-495.6)	223.87	131.95
Triglyceride (mmol/L)		0.79	0.95
Total triiodothyronine (pmol/L)		6.11	6.14
Total tetraiodothyronine (pmol/L)		13.74	14.54
Thyroid-stimulating hormone (mU/L)		3.13	3.05
Cholesterol (mmol/L)		4.54	2.97
Blood glucose (mmol/L)		4.5	4.22
Rorher index		186.98 ^a ↑	186.52 ^a ↑

ACTH: Adrenocorticotrophic hormone.

^a*P* < 0.05.

FINAL DIAGNOSIS

The final diagnosis was obesity, epilepsy and sleep disorder, which was based on physical, imaging, and laboratory examinations.

TREATMENT

Based on this result, we added oral melatonin (Puritan's Pride, Inc., Oakdale, NY, United States) 3 mg, once per night to the treatment.

OUTCOME AND FOLLOW-UP

Upon re-examination in August 2019 (following 7 mo of treatment with melatonin), his food intake had decreased, and the sleep disorder was relieved. He fell asleep at 21:00 h and awoke at 07:00 h, and the occurrence of nightmares with involuntary limb movement was decreased to approximately once per night, with daytime naps reduced to 2-3 times/d. Height and weight were 132 cm and 42.9 kg, respectively, with a Rohrer index of 186.52. Furthermore, his melatonin rhythm was significantly improved compared with the previous results (Figure 3). There were no abnormalities in ACTH, cortisol concentration and rhythm, blood biochemistry, or thyroid hormones (Table 1), and the EEG showed the absence of epileptic discharges (Figure 1C).

DISCUSSION

The *MC4R* gene is associated with energy metabolism. Abnormalities in *MC4R* can cause severe obesity in humans and animals, with variants in this gene being one of the most common monogenic causes of obesity^[4]. Farooqi *et al*^[8] detected this mutation

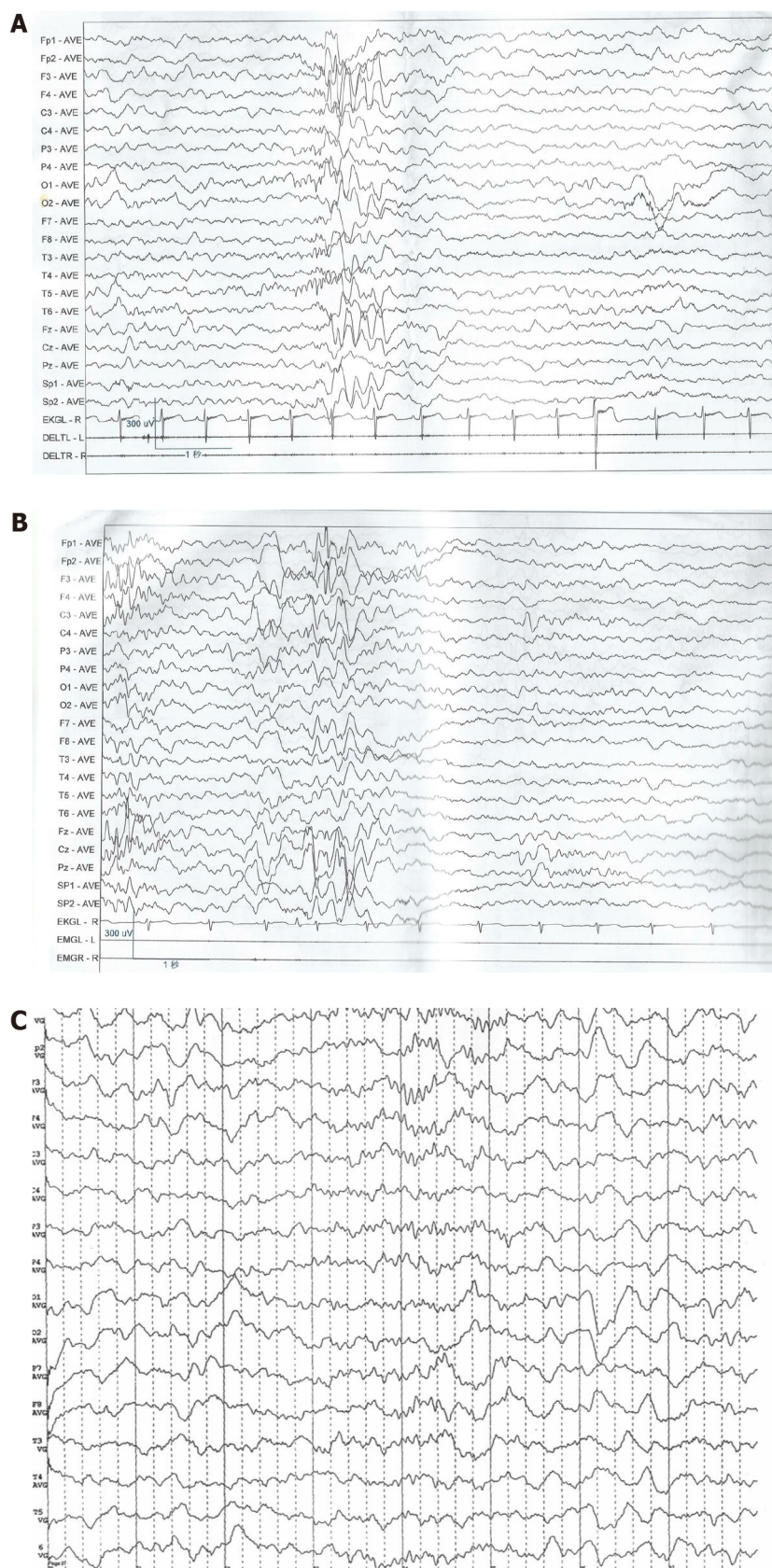


Figure 1 Electroencephalography results. A: First visit; B: After treatment with levetiracetam for 4 mo; C: After combined treatment with levetiracetam and melatonin for 7 mo.

when they sequenced the *MC4R* gene of 243 unrelated American patients with severe early-onset obesity (all patients developed severe obesity before the age of 10 years). In addition, Thearle *et al.*^[9] found that 40 of 4537 American obese children of Indian origin carried a *MC4R* (c.494G>A, p.Arg165Gln) heterozygous mutation, and *in vitro*

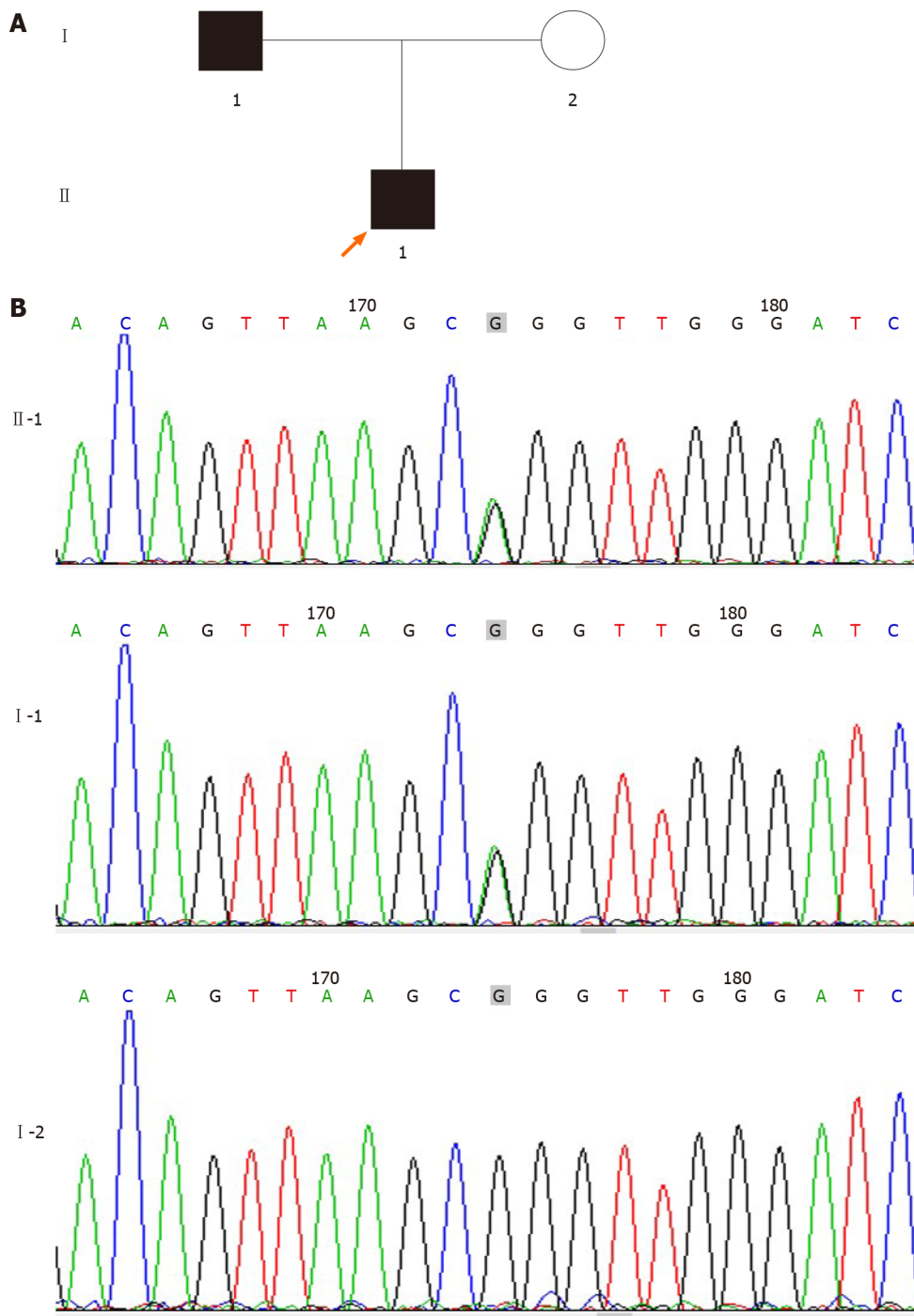


Figure 2 Pedigree of family and sequencing results of the pathogenic variant in the *melanocortin receptor 4* gene. A: Pedigree of family with pathogenic variant in the *melanocortin receptor 4* (*MC4R*) gene; B: Gene variant site. Chromatogram generated by Sanger sequencing (*MC4R*) c.494G>A (p.Arg165Gln); heterozygous variation, paternal.

investigation showed that all the above variations could lead to partial loss of function^[9]. Of note, the association of this pathogenic variant with obesity has been recorded in the Human Gene Mutation Database; the population frequency of the Genome Aggregation Database was 7/246068, while that of the East Asian population of the Genome Aggregation Database was 1/17234.

In the present case, both father and son were obese and had a mutated *MC4R* gene. In the last examination, the Rohrer index of the patient was 186.52 and the body mass index of his father was 29. The father did not have epilepsy or sleep disorder. However, we think that these conditions were caused by incomplete penetrance of the epilepsy/disordered sleep phenotypes and/or possible other genetic variants, present in the son but not in the father, that may influence the effects of the *MC4R* variant. The melatonin rhythm was also clearly disrupted in this child, with low melatonin levels at

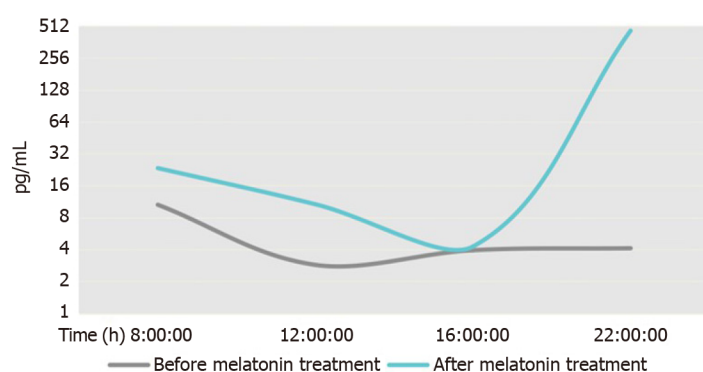


Figure 3 Chart showing melatonin concentration rhythms.

night, which increased during daytime. This was accompanied by multiple naps during daytime, difficulty in sleeping at night, early awakening in the morning, and other obvious sleep disorders. His epilepsy occurred as focal episodes, with abnormal EEG findings. Hence, the diagnosis of the patient was clear; however, he continued to experience seizures after 6 mo of treatment with simple antiepileptic drugs. EEG review showed that waves associated with epilepsy remained, and there was no noticeable improvement in sleep disturbance.

A *MC4R* gene defect was previously reported in only one case of a child with a marked sleep disorder and obesity^[10], suggesting that sleep disorder in that child was caused by a narrowing of the airway due to obesity. However, our findings indicate that the symptoms observed in the present case more closely resembled those of a rapid eye movement sleep disorder, described as frequent nightmares and associated body movements, which may have been caused by abnormal levels of melatonin^[11]. In addition, the study conducted by Goni *et al*^[12] showed that the *MC4R* gene and the *melatonin receptor 1B* gene had a clear interaction. Therefore, we hypothesized that the sleep disorders of the patient were related to abnormalities in the *MC4R* gene. Moreover, there is evidence of an association of abnormal *MC4R* gene expression and refractory epilepsy^[13]. Furthermore, *MC4R* can act on Kir7.1, a potassium export channel, which is normally expressed as an inhibitor of potassium influx. This potassium channel can act on hypothalamic neurons, and its abnormal function may cause epilepsy^[14]; however, there are no cases reported thus far.

Ayça *et al*^[15] confirmed the role of melatonin in regulating circadian rhythms and sleep-waking patterns. Moreover, melatonin can also act on *MC4R*. For example, one study found that zebrafish fed with different concentrations of melatonin showed a significant increase in the expression of *MC4R* after 10 d compared with untreated zebrafish^[4]. Numerous experimental reports demonstrated that melatonin is closely associated with epilepsy, and abnormal levels of melatonin can lead to epilepsy^[5,6]. The anti-convulsive effects of melatonin have been demonstrated in numerous animal experiments^[16]. Nevertheless, at present, it is mainly used for the treatment of sleep disorders, with only a few studies administering it as adjuvant treatment along with antiepileptic drugs.

Previous studies have shown that sleep disorders, abnormal melatonin rhythm, and abnormality in Kir7.1 may contribute to epilepsy. Whether the combination of these three factors exacerbates the condition is unclear. However, according to previous literature^[5,14], melatonin exerts a positive effect in the regulation of sleep disorders and epilepsy; hence, we administered melatonin in this patient. Fortunately, following the administration of melatonin, his epilepsy resolved, the sleep disorder was corrected, and the abnormal melatonin rhythm was rectified. Furthermore, his Rohrer index was slightly reduced. Nevertheless, considering the severe obesity of this patient, we concluded that treatment with melatonin contributed to the control of his obesity.

CONCLUSION

In conclusion, we hypothesized that the occurrence of obesity and abnormal melatonin in this patient was associated with the *MC4R* gene variant, and these abnormalities led to disordered sleep and epilepsy. This is the first report of the combination of these symptoms in a patient with an *MC4R* variant. Furthermore, in our patient, adjuvant therapy with melatonin exerted a clear curative effect on these symptoms. Therefore,

we propose that it is necessary to conduct genetic examination, particularly of the MC4R gene, to identify the etiology in children presenting with obesity, sleep disorders, and epilepsy.

REFERENCES

- 1 **Adamska-Patrano E**, Goscik J, Czajkowski P, Maliszewska K, Ciborowski M, Golonko A, Wawrusiewicz-Kurylonek N, Citko A, Waszczeniuk M, Kretowski A, Gorska M. The MC4R genetic variants are associated with lower visceral fat accumulation and higher postprandial relative increase in carbohydrate utilization in humans. *Eur J Nutr* 2019; **58**: 2929-2941 [PMID: [30945034](#) DOI: [10.1007/s00394-019-01955-0](#)]
- 2 **Kim JH**, Choi JH. Pathophysiology and clinical characteristics of hypothalamic obesity in children and adolescents. *Ann Pediatr Endocrinol Metab* 2013; **18**: 161-167 [PMID: [24904871](#) DOI: [10.6065/apem.2013.18.4.161](#)]
- 3 **Kühnen P**, Clément K, Wiegand S, Blankenstein O, Gottesdiener K, Martini LL, Mai K, Blume-Peytavi U, Grüters A, Krude H. Proopiomelanocortin Deficiency Treated with a Melanocortin-4 Receptor Agonist. *N Engl J Med* 2016; **375**: 240-246 [PMID: [27468060](#) DOI: [10.1056/NEJMoa1512693](#)]
- 4 **Piccinetti CC**, Miglierini B, Olivotto I, Simoniello MP, Giorgini E, Carnevali O. Melatonin and peripheral circuitries: insights on appetite and metabolism in Danio rerio. *Zebrafish* 2013; **10**: 275-282 [PMID: [23682835](#) DOI: [10.1089/zeb.2012.0844](#)]
- 5 **Paprocka J**, Kijonka M, Pęcka M, Sokół M. Melatonin in Epilepsy: A New Mathematical Model of Diurnal Secretion. *Int J Endocrinol* 2016; **2016**: 3861461 [PMID: [27478439](#) DOI: [10.1155/2016/3861461](#)]
- 6 **Jain SV**, Horn PS, Simakajornboon N, Beebe DW, Holland K, Byars AW, Glauser TA. Melatonin improves sleep in children with epilepsy: a randomized, double-blind, crossover study. *Sleep Med* 2015; **16**: 637-644 [PMID: [25862116](#) DOI: [10.1016/j.sleep.2015.01.005](#)]
- 7 **Jensen MA**, Hansen AM, Abrahamsson P, Nørgaard AW. Development and evaluation of a liquid chromatography tandem mass spectrometry method for simultaneous determination of salivary melatonin, cortisol and testosterone. *J Chromatogr B Analyt Technol Biomed Life Sci* 2011; **879**: 2527-2532 [PMID: [21803007](#) DOI: [10.1016/j.jchromb.2011.07.005](#)]
- 8 **Farooqi IS**, Yeo GS, Keogh JM, Aminian S, Jebb SA, Butler G, Cheetham T, O'Rahilly S. Dominant and recessive inheritance of morbid obesity associated with melanocortin 4 receptor deficiency. *J Clin Invest* 2000; **106**: 271-279 [PMID: [10903343](#) DOI: [10.1172/JCI9397](#)]
- 9 **Thearle MS**, Muller YL, Hanson RL, Mullins M, Abdussamad M, Tran J, Knowler WC, Bogardus C, Krakoff J, Baier LJ. Greater impact of melanocortin-4 receptor deficiency on rates of growth and risk of type 2 diabetes during childhood compared with adulthood in Pima Indians. *Diabetes* 2012; **61**: 250-257 [PMID: [22106157](#) DOI: [10.2337/db11-0708](#)]
- 10 **Pillai S**, Nandalike K, Kogelman Y, Muzumdar R, Balk SJ, Arens R. Severe obstructive sleep apnea in a child with melanocortin-4 receptor deficiency. *J Clin Sleep Med* 2014; **10**: 99-101 [PMID: [24426828](#) DOI: [10.5664/jcsm.3374](#)]
- 11 **Dauvilliers Y**, Schenck CH, Postuma RB, Iranzo A, Luppi PH, Plazzi G, Montplaisir J, Boeve B. REM sleep behaviour disorder. *Nat Rev Dis Primers* 2018; **4**: 19 [PMID: [30166532](#) DOI: [10.1038/s41572-018-0016-5](#)]
- 12 **Goni L**, Cuervo M, Milagro FI, Martínez JA. Gene-Gene Interplay and Gene-Diet Interactions Involving the MTNR1B rs10830963 Variant with Body Weight Loss. *J Nutrigenet Nutrigenomics* 2014; **7**: 232-242 [PMID: [25870980](#) DOI: [10.1159/000380951](#)]
- 13 **Liu X**, Ou S, Xu T, Liu S, Yuan J, Huang H, Qin L, Yang H, Chen L, Tan X, Chen Y. New differentially expressed genes and differential DNA methylation underlying refractory epilepsy. *Oncotarget* 2016; **7**: 87402-87416 [PMID: [27903967](#) DOI: [10.18632/oncotarget.13642](#)]
- 14 **Litt MJ**, Cone RD, Ghamari-Langroudi M. Characterization of MC4R Regulation of the Kir7.1 Channel Using the Tl⁺ Flux Assay. *Methods Mol Biol* 2018; **1684**: 211-222 [PMID: [29058194](#) DOI: [10.1007/978-1-4939-7362-0_16](#)]
- 15 **Ayça S**, Aksoy HU, Taştan İ, Polat M. Levels of Melatonin in Continuous Spikes and Waves During Sleep. *J Child Neurol* 2019; **34**: 309-312 [PMID: [30761941](#) DOI: [10.1177/0883073819828580](#)]
- 16 **Banach M**, Gurdziel E, Jędrych M, Borowicz KK. Melatonin in experimental seizures and epilepsy. *Pharmacol Rep* 2011; **63**: 1-11 [PMID: [21441606](#) DOI: [10.1016/s1734-1140\(11\)70393-0](#)]



Published by **Baishideng Publishing Group Inc**
7041 Koll Center Parkway, Suite 160, Pleasanton, CA 94566, USA

Telephone: +1-925-3991568

E-mail: bpgoffice@wjgnet.com

Help Desk: <https://www.f6publishing.com/helpdesk>

<https://www.wjgnet.com>

