

World Journal of *Radiology*

World J Radiol 2021 April 28; 13(4): 75-101



EVIDENCE REVIEW

- 75 Discrepancies in the clinical and radiological profiles of COVID-19: A case-based discussion and review of literature

Kumar H, Fernandez CJ, Kolpattil S, Munavvar M, Pappachan JM

MINIREVIEWS

- 94 Cardio-thoracic imaging and COVID-19 in the pediatric population: A narrative review

Ferrero P, Piazza I

ABOUT COVER

Editorial Board Member of *World Journal of Radiology*, Mohamed R Nough, MD, Assistant Professor, Department of Radiology, Faculty of Medicine, Alexandria University, Alexandria 21568, Egypt. mohamed.nough@alexmed.edu.eg

AIMS AND SCOPE

The primary aim of *World Journal of Radiology* (WJR, *World J Radiol*) is to provide scholars and readers from various fields of radiology with a platform to publish high-quality basic and clinical research articles and communicate their research findings online.

WJR mainly publishes articles reporting research results and findings obtained in the field of radiology and covering a wide range of topics including state of the art information on cardiopulmonary imaging, gastrointestinal imaging, genitourinary imaging, musculoskeletal imaging, neuroradiology/head and neck imaging, nuclear medicine and molecular imaging, pediatric imaging, vascular and interventional radiology, and women's imaging.

INDEXING/ABSTRACTING

The WJR is now abstracted and indexed in Emerging Sources Citation Index (Web of Science), PubMed, PubMed Central, China National Knowledge Infrastructure (CNKI), China Science and Technology Journal Database (CSTJ), and Superstar Journals Database.

RESPONSIBLE EDITORS FOR THIS ISSUE

Production Editor: *Ying-Yi Yuan*, Production Department Director: *Yun-Xiao Jian Wu*, Editorial Office Director: *Jia-Ping Yan*.

NAME OF JOURNAL

World Journal of Radiology

ISSN

ISSN 1949-8470 (online)

LAUNCH DATE

January 31, 2009

FREQUENCY

Monthly

EDITORS-IN-CHIEF

Venkatesh Mani

EDITORIAL BOARD MEMBERS

<https://www.wjgnet.com/1949-8470/editorialboard.htm>

PUBLICATION DATE

April 28, 2021

COPYRIGHT

© 2021 Baishideng Publishing Group Inc

INSTRUCTIONS TO AUTHORS

<https://www.wjgnet.com/bpg/gerinfo/204>

GUIDELINES FOR ETHICS DOCUMENTS

<https://www.wjgnet.com/bpg/gerinfo/287>

GUIDELINES FOR NON-NATIVE SPEAKERS OF ENGLISH

<https://www.wjgnet.com/bpg/gerinfo/240>

PUBLICATION ETHICS

<https://www.wjgnet.com/bpg/gerinfo/288>

PUBLICATION MISCONDUCT

<https://www.wjgnet.com/bpg/gerinfo/208>

ARTICLE PROCESSING CHARGE

<https://www.wjgnet.com/bpg/gerinfo/242>

STEPS FOR SUBMITTING MANUSCRIPTS

<https://www.wjgnet.com/bpg/gerinfo/239>

ONLINE SUBMISSION

<https://www.f6publishing.com>



Cardio-thoracic imaging and COVID-19 in the pediatric population: A narrative review

Paolo Ferrero, Isabelle Piazza

ORCID number: Paolo Ferrero 0000-0001-7967-7417; Isabelle Piazza 0000-0002-1316-8107.

Author contributions: Ferrero P wrote the paper; Piazza I performed and collected the data.

Conflict-of-interest statement: Authors declare no conflict of interests for this article.

Open-Access: This article is an open-access article that was selected by an in-house editor and fully peer-reviewed by external reviewers. It is distributed in accordance with the Creative Commons Attribution NonCommercial (CC BY-NC 4.0) license, which permits others to distribute, remix, adapt, build upon this work non-commercially, and license their derivative works on different terms, provided the original work is properly cited and the use is non-commercial. See: <http://creativecommons.org/licenses/by-nc/4.0/>

Manuscript source: Invited manuscript

Specialty type: Radiology, nuclear medicine and medical imaging

Country/Territory of origin: Italy

Peer-review report's scientific quality classification

Paolo Ferrero, ACHD Unit–Pediatric and Adult Congenital Heart Centre, IRCCS-Policlinico San Donato, San Donato Milanese 20097, Milan, Italy

Isabelle Piazza, Department of Emergency Medicine, ASST Papa Giovanni XXIII, Bergamo 24127, Italy

Corresponding author: Paolo Ferrero, FESC, MD, ACHD Unit–Pediatric and Adult Congenital Heart Centre, IRCCS-Policlinico San Donato, Via Morandi 30, San Donato Milanese 20097, Milan, Italy. ferrerop41@gmail.com

Abstract

Worldwide experience about coronavirus disease 2019 (COVID-19) pandemics suggests that symptomatic disease is significantly less frequent in the pediatric age range. Nevertheless, multi-system inflammatory syndrome has been consistently reported in children and has been associated with severe acute respiratory syndrome coronavirus 2 exposure. In this paper we give an overview of the multimodality chest imaging of pediatric patients with suspected COVID-19, focusing on relevant differences with adults.

Key Words: COVID-19; Radiology; Imaging; Chest; Pediatric; SARS-CoV-2

©The Author(s) 2021. Published by Baishideng Publishing Group Inc. All rights reserved.

Core Tip: Although the pattern of lung involvement of coronavirus disease 2019 in children reproduces the pathology described in the general population, traditional imaging modalities have several limitations in this age group. Specific and unique findings are mainly related to the occurrence of multi-system inflammatory syndrome which is a peculiar complication reproducibly reported in the pediatric population. This syndrome is characterized by occurrence of atypical symptoms as compared with presentation in adult and multimodality imaging approach has to be contemplated.

Citation: Ferrero P, Piazza I. Cardio-thoracic imaging and COVID-19 in the pediatric population: A narrative review. *World J Radiol* 2021; 13(4): 94-101

URL: <https://www.wjgnet.com/1949-8470/full/v13/i4/94.htm>

DOI: <https://dx.doi.org/10.4329/wjr.v13.i4.94>

Grade A (Excellent): 0
 Grade B (Very good): B, B
 Grade C (Good): 0
 Grade D (Fair): D, D
 Grade E (Poor): 0

Received: January 21, 2021
Peer-review started: January 21, 2021
First decision: February 12, 2021
Revised: February 19, 2021
Accepted: April 13, 2021
Article in press: April 13, 2021
Published online: April 28, 2021

P-Reviewer: He YF,
 Papazafiropoulou A
S-Editor: Fan JR
L-Editor: A
P-Editor: Yuan YY



INTRODUCTION

Coronavirus disease 2019 (COVID-19) in its most frequent clinical manifestation causes a respiratory syndrome, due to a single stranded RNA beta coronavirus infection, that may results in acute respiratory distress syndrome. Due to the clinical association of this new virus with the onset of a respiratory syndrome it has been named severe acute respiratory syndrome coronavirus 2 (SARS-CoV-2). However, it has been shown that many organs and tissues, including heart, vessels, and brain may be involved in SARS-CoV-2. Furthermore COVID-19 has been repeatedly reported in the pediatric population. Among the 962 million people infected worldwide so far, the pediatric age group constitute less than 2%. Overall atypical and asymptomatic infections are more frequent in children. This might be due to a lower exposure or less susceptible lung barrier due to immature angiotensin enzyme-2 receptors^[1,2].

Likewise in adults, COVID-19 in infants is characterized by a background of inflammatory activation that may involve different tissues and organs in different phases. In those area particularly hit by the virus during the first pandemic phase, we observed a surge of mucocutaneous inflammatory syndrome resembling Kawasaki disease^[3,4]. This condition has been subsequently named multisystem inflammatory syndrome in children (MIS-C) associated with COVID-19^[5,6].

The proteus clinical presentation of COVID-19 in children together with the possible occurrence of MIS-C prompt a different diagnostic approach in this age group as compared to adults. (Table 1) Differently from the general population data about image findings in pediatric COVID-19 are scant and sometimes conflictual.

We aim to provide an overview of peculiarity of thoracic diagnostic algorithm in the pediatric age group, focusing relevant differences with adults.

METHODS

For this narrative review the following keywords: COVID-19, SARS-CoV-2, radiology, imaging and pediatric in different combinations. Papers were screened accordingly to the information provided in the abstract. Only manuscripts written in English and focused on the thoracic district were deemed eligible for inclusion. Within the pediatric age group we did not consider any specific limit of range and all papers dealing with patients younger than 18 years were included point of view papers and editorials were also excluded. Additional data were retrieved from the references of individual papers, whenever appropriate.

Pathophysiology

Several pathophysiologic issues have been advocated to explain differences in clinical presentation of pediatric patients. In particular, an association between SARS-CoV-2 infection and a multi systemic inflammatory syndrome has been consistently reported^[7-10]. Diagnostic criteria of MIS-C include fever, hypotension, evidence of cardiac or other end-organ injury together with at least two of the following: maculopapular rash, non purulent conjunctivitis, mucocutaneous inflammation and gastrointestinal symptoms^[6].

This particular presentation, characterized by multi organ inflammation rather than severe respiratory syndrome, may be due to a different immune system reactivity and a more immature and different distribution of angiotensin-converting enzyme II receptor, which is the entry receptor for the virus. The association of syndromes and the degree of lung maturity can further contribute to modulate the clinical presentation. As far as the thoracic involvement is concerned, coronary involvement is a rare peculiar feature of MIS-C sharing the clinical and anatomic presentation with Kawasaki disease^[4].

Characteristics of chest X-ray changes in pediatric COVID-19

Although the concept that radiological manifestations of COVID-19 vary among different age group, information about sensitivity, specificity and characteristic findings of chest X-ray in the pediatric population are limited and conflicting^[11].

Chest X-ray may be negative in more than 1/3 of patients in the pediatric group age. Reported sensitivity of chest X-ray vary from 25% to 69%^[12].

Commonly encountered chest X-ray abnormalities are consolidations and ground glass opacities (GGO), differently from the adult variant, peribronchial thickening is more frequent in this clinical setting (60% to 80%)^[13]. Peribronchial thickening is however aspecific and can be seen in other variant of viral pneumonia in children,

Table 1 Differences of coronavirus disease 2019 relevant characteristics between adult and pediatric population

	Adults	Pediatric age group
Epidemiology	97%-98% of 962 million (worldwide)	About 2% < 18 yr
Clinical presentation	Respiratory symptoms frequent	Respiratory symptoms not frequent
	Multisystem inflammatory toxic syndrome not frequent	Multisystem inflammatory toxic syndrome typical (MIS-C)
Pleuro-pericardial involvement	Not frequent	Frequent
Myocardial dysfunction	Not frequent	Frequent in the context of MIS-C
Chest X-RAY	Routinely done, good sensitivity	Low sensitivity
	GGO sub-pleural	GGO sub-pleural basal
	Nodular consolidation	Nodular consolidation not frequent
	Peri-bronchial thickening not frequent	Peri-bronchial thickening frequent
	Pleural effusion rare	Pleural effusion possible
CT	High sensitivity	Good sensitivity, performed only in selected cases
	GGO sub-pleural	GGO sub-pleural basal
	Nodular consolidation	Nodular consolidation not frequent
	Peri-bronchial thickening not frequent	Peri-bronchial thickening frequent
	Pleural effusion rare	Pleural effusion possible
Suggested screening modality	Low-dose CT	Bed-side echo

MIS-C: Multisystem inflammatory syndrome in children; GGO: Ground glass opacities; CT: Computer tomography.

while hyperinflation, which is another recognized hallmark, was not reported. Reason for chest X-ray low sensitivity is the higher prevalence of lower density, smaller size and basal opacities, obscured by the diaphragm and hepatic dome^[11].

Halo sign, which is deemed to be highly specific of COVID-19, has been observed also in 50% of pediatric cases in a published series, while other finding such as crazy paving pattern or organizing pneumonia pattern, which have been reported as typical in adult with COVID-19, were not consistently reported in pediatric series^[13,14].

Finally, pleural effusion is a rare manifestation of COVID-19 in adults and is almost uniquely seen in the pediatric age range being associated with involvement of other serous cavities in patients with MIS-C.

Computer tomography

Although computer tomography (CT) has a much higher sensitivity likewise chest X-ray, according to some reports, pediatric patients are three time more likely to have normal CT scan as compared to adult. However, pooling together literature data, percentage of negative CT is very variable, ranging between 10% and 30%^[15,16].

In adults, several series have found that COVID-19 typically presents with peripheral and posterior GGO^[17,18]. Opacities may present in a confluent fashion or as more delimited scattered round opacities (so called 'crazy paving pattern'). Other peculiar findings typical of organizing pneumonia are 'halo sign' or 'reversal halo sign'^[19].

It has been hypothesized that the predominant localization of radiological findings at the periphery of the lung and the presence of enlargement of the vessel feeding the involved lung area (feeding vessel sign) may be explained by the inflammatory involvement of small vessels^[20]. Based on these pathogenetic models, standardized reporting methodologies have been devised providing also a ranking of suspicious according to the presence of cluster of signs^[19]. However application of diagnostic CT scores based on adult cohorts resulted in low probability of the disease in the pediatric population^[11]. According to this background, utilization of low dose CT as screening tool in children with laboratory inconclusive findings is controversial.

As compared to adults, pediatric series show a lower total number of pulmonary lesions and smaller size of them. Bilateral GGO confirmed to be the most common finding accounting for almost 90% of the positive scans^[16,21]. Likewise general population GGO may present different stage of consolidation (halo sign) in 50% of cases. As previously discussed about chest X-ray, peribronchial and broncho-vascular thickening

are more common in children^[22,23].

Role of thoracic ultrasounds

Lung ultrasounds (LUS) is consistently used in the diagnostic process of different lung diseases in both adults and children^[24,25].

Among patients with suspected or ascertained COVID-19, elementary ultrasonographic findings in the context of lung injury are: Normal lung sliding, B lines, that are perpendicular hyperechogenic streaks due to loss of aerated space, subpleural nodules, pleural effusion. Clusters of these signs have been described in association with different probability and severity of the disease^[26]. Evidences about diagnostic accuracy in patient with COVID-19 in the pediatric age group is limited to small series. According to these data LUS, although less sensitive than CT, is more sensitive than chest X-ray^[27]. In the largest multi-center cohort of 40 children with suspected COVID-19 undergoing LUS, the diagnosis of pulmonary involvement was done in 10 out of 12 patients with positive CT findings, in seven of whom chest X-ray was normal^[28].

Common findings were: A line in 72%, various pattern of B line in 27%, while parenchymal nodular consolidation were more rare as compared with adults (10%)^[28].

As previously mentioned, clusters of inflammatory syndrome associated with SARS-CoV-2 (MIS-C) have been consistently reported. Even though these patients usually present without respiratory symptoms, LUS showed loss of aeration or pleural effusion in all of them in a small case series^[29].

Despite these limited data, use of LUS in this clinical setting might be advocated since it allow early and repeated bedside assessment avoiding X-ray exposure and patient transport in the imaging department, which might potentially increase the risk of virus spread.

Additional specific image modalities

Coagulation disorders have been recognized as a major complication of COVID-19 significantly affecting the prognosis^[30]. In this context the ventilation/perfusion single photon emission computed tomography, either as single modality or combined with computed tomography (V/Q SPECT) can be used in selected case to diagnose pulmonary embolism in case of iodinated medium allergy or to integrate CT images. In the pediatric population clinically relevant pulmonary embolism are rarely reported therefore the need to exclude this complication is far less compelling^[31]. Furthermore radionuclide exposure and the risk of infection spread across different departments, deeply limits the room for this diagnostic resource in the clinical practice.

Multimodal cardiovascular imaging

Since the first COVID-19 outbreak, different degree of myocardial injury have been reported^[32-34]. Biomarker evidence of myocardial injury has been associated with a higher mortality risk in COVID-19 patients^[35]. Although typical clinical presentation of COVID-19 in the pediatric age group is rare, association of MIS-C with SARS-CoV-2 exposure has been reproducibly observed. This syndrome, originally labelled as Kawasaki-like, is characterized by various degree of myocardial and coronary inflammatory involvement^[3,4,36]. Even-though clinical manifestation of this syndrome is extremely variable abdominal and gastrointestinal symptoms are key diagnostic features, being present in up to 80%, while cardiovascular involvement may go initially unrecognized^[37]. Although abdominal imaging is not the focus of this review, it has to be highlighted that ultrasound of this district is usually the first diagnostic exam performed, furthermore cardiovascular involvement and abdominal imaging are strictly related. Abdominal anechoic space and hepatomegaly are the most frequent findings. In one study screening abdominal echo was able to disclose associated pleuro-pericardial effusion and cardiomegalia in almost 37% and 12% of case, respectively^[5]. From the practical point of view, given the high incidence of gastrointestinal symptoms in children with COVID-19 related MIS-C, abdominal screening echo may help in differentiate this condition from other abdominal urgencies^[31,38,39].

Trans-thoracic echo has a high diagnostic sensitivity in the acute phase by demonstrating ventricular dysfunction and coronary remodeling^[40]. Consistently with echocardiographic diagnostic criteria in typical complete Kawasaki syndrome, coronary size is standardized according to the deviation from the median in the general population with the same body surface area (z score)^[41]. Cardiac depression, although sometimes severe at presentation, requiring inotropic or even mechanical circulatory support, recovers in around 70% of cases^[7]. Nevertheless, given the limited knowledge about the virus pathogenicity and natural history of the disease in the long term, echocar-

diographic follow up at one month and one year, in patients with documented cardiac or coronary involvement (z score > 25), is recommended.

Cardiac CT scan can provide accurate evaluation of the coronary artery anatomy and may be considered in patients with difficult acoustic windows or with extensive coronary involvement. Cardiac magnetic resonance imaging may be useful during the initial hospitalization or approximately 3 mo post-acute illness to evaluate ventricular function and myocardial characteristics including edema, diffuse fibrosis, and scar by myocardial late gadolinium enhancement^[42,43].

Differences of COVID-19 crucial characteristics between adult and children

Table 1 summarizes main differences in COVID-19 that are relevant in planning the diagnostic algorithm. We considered the following nosological variables: Epidemiology, pathophysiology, natural history, image sensitivity.

So far about 96 million COVID-19 cases have been reported, of whom only less than 2% occurred in patients less than 18 years old. Furthermore, as compared with adult cohorts, fewer patients have a severe or critical course (6% *vs* 20%)^[1].

Distribution of rate of hospitalization displays a cluster in the age group lower than two years and higher than 10 d. Although infants younger than two years rarely present pneumonia, admission is motivated by poor tolerance of fever. As far as the diagnostic algorithm is concerned, although lung involvement in SARS-CoV-2 infection in the pediatric age range may largely reproduce those reported in the general population, sensitivity of chest X-ray is significantly lower. As a consequence traditional chest imaging is a poor screening test in children with suspected COVID-19. On the other hand, fast bedside ultrasound screening has a high diagnostic yield as may easily disclose multi organ involvement consistent with the infection.

CONCLUSION

COVID-19 pandemics has prompted worldwide rapid reorganization of imaging departments. While the incidence of clinically relevant COVID-19 in pediatric population was previously deemed very low, the observation of a late peak of SARS-CoV-2 related disease in this age group prompted the development of specific management algorithms (**Figure 1**).

Knowledge about imaging diagnostic findings has significant grown, however significant differences in the pathophysiology and clinical presentation in children as compared with adults must be taken into account. Observational data indicate that both chest X-ray and CT have a lower diagnostic yield and can show peculiar findings, such as broncovascular thickening and pleuro-pericardial effusion, in pediatric patients. The thoracic echo may have a relevant role in the diagnostic algorithm in order to screen and monitor lung involvement as well as specific features of MIS-C in this clinical setting. Furthermore, X-ray exposure and risk of virus spread during patient transport should be taken into account when considering repeated traditional imaging.

This review is based mainly on small case series with heterogeneous populations and sometimes contradictory conclusion about findings and appropriateness of the various diagnostic tools. This limitation does not allow to pool together the data and to provide general recommendation with a sufficient grade of evidence.

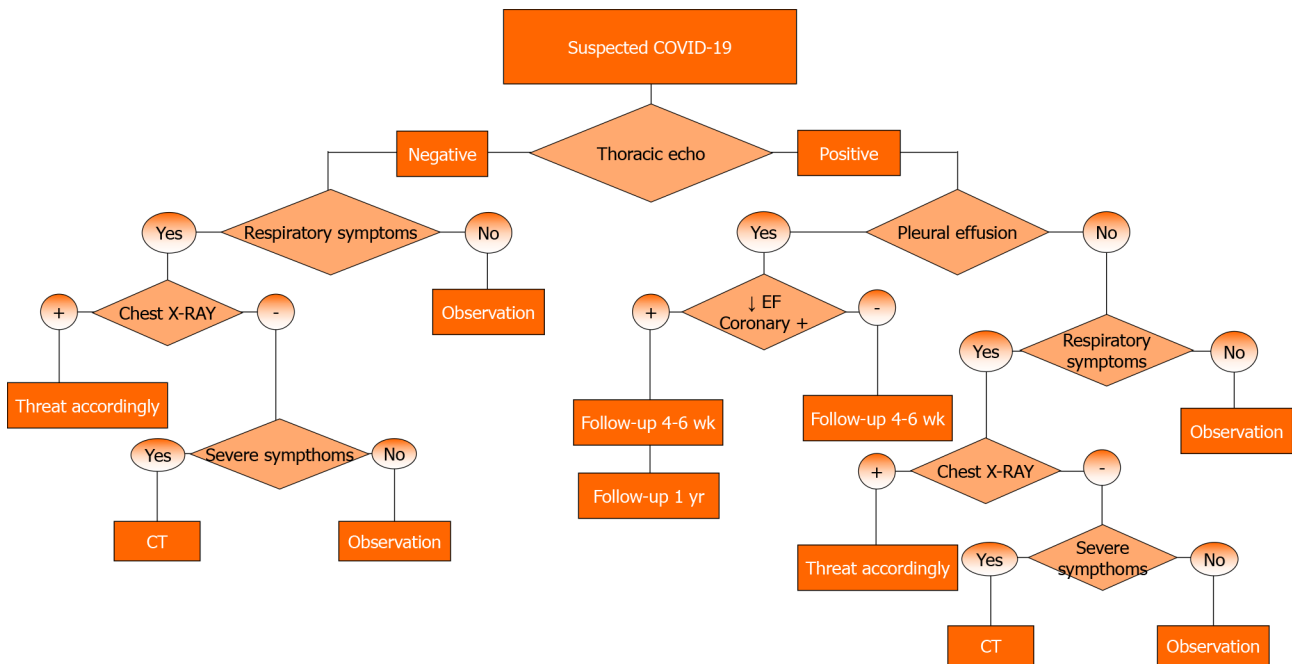


Figure 1 Proposed multimodal diagnostic algorithm. COVID-19: Coronavirus disease 2019; CT: Computer tomography.

REFERENCES

- Dong Y**, Mo X, Hu Y, Qi X, Jiang F, Jiang Z, Tong S. Epidemiology of COVID-19 Among Children in China. *Pediatrics* 2020; **145** [PMID: 32179660 DOI: 10.1542/peds.2020-0702]
- Chan JF**, Yuan S, Kok KH, To KK, Chu H, Yang J, Xing F, Liu J, Yip CC, Poon RW, Tsoi HW, Lo SK, Chan KH, Poon VK, Chan WM, Ip JD, Cai JP, Cheng VC, Chen H, Hui CK, Yuen KY. A familial cluster of pneumonia associated with the 2019 novel coronavirus indicating person-to-person transmission: a study of a family cluster. *Lancet* 2020; **395**: 514-523 [PMID: 31986261 DOI: 10.1016/S0140-6736(20)30154-9]
- Verdoni L**, Mazza A, Gervasoni A, Martelli L, Ruggeri M, Ciuffreda M, Bonanomi E, D'Antiga L. An outbreak of severe Kawasaki-like disease at the Italian epicentre of the SARS-CoV-2 epidemic: an observational cohort study. *Lancet* 2020; **395**: 1771-1778 [PMID: 32410760 DOI: 10.1016/S0140-6736(20)31103-X]
- Ferrero P**, Piazza I, Bonino C, Ciuffreda M. Patterns of myocardial involvement in children during COVID-19 pandemic: Early experience from northern Italy. *Ann Pediatr Cardiol* 2020; **13**: 230-233 [PMID: 32863659 DOI: 10.4103/apc.APC_77_20]
- Blumfield E**, Levin TL, Kurian J, Lee EY, Liszewski MC. Imaging Findings in Multisystem Inflammatory Syndrome in Children (MIS-C) Associated With Coronavirus Disease (COVID-19). *AJR Am J Roentgenol* 2021; **216**: 507-517 [PMID: 32755212 DOI: 10.2214/AJR.20.24032]
- New York City Department of Health**. 2020 Health Advisory #16: Updated Reporting. Requirements for Multisystem Inflammatory Syndrome in Children Associated with COVID-19 2020. [cited 27 May 2020]. Available from: <https://www1.nyc.gov/assets/doh/downloads/pdf/han/advisory/2020/covid-19-providers-mis-c.pdf>.
- Belhadj Z**, Méot M, Bajolle F, Khraiche D, Legendre A, Abakka S, Auriau J, Grimaud M, Oualha M, Beghetti M, Wacker J, Ovaert C, Hascoet S, Selegny M, Malekzadeh-Milani S, Maltret A, Bosser G, Giroux N, Bonnemains L, Bordet J, Di Filippo S, Mauran P, Falcon-Eicher S, Thambo JB, Lefort B, Moceri P, Houyel L, Renolleau S, Bonnet D. Acute Heart Failure in Multisystem Inflammatory Syndrome in Children in the Context of Global SARS-CoV-2 Pandemic. *Circulation* 2020; **142**: 429-436 [PMID: 32418446 DOI: 10.1161/CIRCULATIONAHA.120.048360]
- Riphagen S**, Gomez X, Gonzalez-Martinez C, Wilkinson N, Theocharis P. Hyperinflammatory shock in children during COVID-19 pandemic. *Lancet* 2020; **395**: 1607-1608 [PMID: 32386565 DOI: 10.1016/S0140-6736(20)31094-1]
- Blondiaux E**, Parisot P, Redheuil A, Tzaroukian L, Levy Y, Sileo C, Schnuriger A, Lorrot M, Guedj R, Ducou le Pointe H. Cardiac MRI in Children with Multisystem Inflammatory Syndrome Associated with COVID-19. *Radiology* 2020; **297**: E283-E288 [PMID: 32515676 DOI: 10.1148/radiol.202022288]
- New York State Department of Health website**. Childhood inflammatory disease relat-ed to COVID-19: overview & stats. 2020. [cited 27 May 2020]. Available from: <https://profiles.health.ny.gov/#5.05/42.84/-75.88>.
- Bayramoglu Z**, Canipek E, Comert RG, Gasimli N, Kaba O, Sari Yanartaş M, Hançerli Torun S, Somer A, Erturk SM. Imaging Features of Pediatric COVID-19 on Chest Radiography and Chest CT:

- A Retrospective, Single-Center Study. *Acad Radiol* 2021; **28**: 18-27 [PMID: [33067091](#) DOI: [10.1016/j.acra.2020.10.002](#)]
- 12 **Choi H**, Qi X, Yoon SH, Park SJ, Lee KH, Kim JY, Lee YK, Ko H, Kim KH, Park CM, Kim YH, Lei J, Hong JH, Kim H, Hwang EJ, Yoo SJ, Nam JG, Lee CH, Goo JM. Erratum: Extension of Coronavirus Disease 2019 (COVID-19) on Chest CT and Implications for Chest Radiograph Interpretation. *Radiol Cardiothorac Imaging* 2020; **2**: e204001 [PMID: [33779627](#) DOI: [10.1148/ryct.2020204001](#)]
- 13 **Wong HYF**, Lam HYS, Fong AH, Leung ST, Chin TW, Lo CSY, Lui MM, Lee JCY, Chiu KW, Chung TW, Lee EYP, Wan EYF, Hung IFN, Lam TPW, Kuo MD, Ng MY. Frequency and Distribution of Chest Radiographic Findings in Patients Positive for COVID-19. *Radiology* 2020; **296**: E72-E78 [PMID: [32216717](#) DOI: [10.1148/radiol.2020201160](#)]
- 14 **Oterino Serrano C**, Alonso E, Andrés M, Buitrago NM, Pérez Vigara A, Parrón Pajares M, Cuesta López E, Garzón Moll G, Martín Espin I, Bueno Barriocanal M, De Ceano-Vivas la Calle M, Calvo Rey C, Bret-Zurita M. Pediatric chest x-ray in covid-19 infection. *Eur J Radiol* 2020; **131**: 109236 [PMID: [32932176](#) DOI: [10.1016/j.ejrad.2020.109236](#)]
- 15 **Nino G**, Zember J, Sanchez-Jacob R, Gutierrez MJ, Sharma K, Linguraru MG. Pediatric lung imaging features of COVID-19: A systematic review and meta-analysis. *Pediatr Pulmonol* 2021; **56**: 252-263 [PMID: [32926572](#) DOI: [10.1002/ppul.25070](#)]
- 16 **Caro-Dominguez P**, Shelmerdine SC, Toso S, Secinaro A, Toma P, Damasio MB, Navallas M, Rianza-Martin L, Gomez-Pastrana D, Ghadimi Mahani M, Desoky SM, Ugas Charcape CF, Almanza-Aranda J, Ucar ME, Lovrenski J, Gorkem SB, Alexopoulou E, Ciet P, van Schuppen J, Ducou le Pointe H, Goo HW, Kellenberger CJ, Raissaki M, Owens CM, Hirsch FW, van Rijn RR; Collaborators of the European Society of Paediatric Radiology Cardiothoracic Task Force. Thoracic imaging of coronavirus disease 2019 (COVID-19) in children: a series of 91 cases. *Pediatr Radiol* 2020; **50**: 1354-1368 [PMID: [32749530](#) DOI: [10.1007/s00247-020-04747-5](#)]
- 17 **D'Andrea A**, Radmilovic J, Carbone A, Forni A, Tagliamonte E, Riegler L, Liccardo B, Crescibene F, Sirignano C, Esposito G, Bossone E. Multimodality imaging in COVID-19 patients: A key role from diagnosis to prognosis. *World J Radiol* 2020; **12**: 261-271 [PMID: [33362917](#) DOI: [10.4329/wjr.v12.i11.261](#)]
- 18 **Landete P**, Quezada Loaiza CA, Aldave-Orzaiz B, Muñoz SH, Maldonado A, Zamora E, Sam Cerna AC, Del Cerro E, Alonso RC, Couñago F. Clinical features and radiological manifestations of COVID-19 disease. *World J Radiol* 2020; **12**: 247-260 [PMID: [33362916](#) DOI: [10.4329/wjr.v12.i11.247](#)]
- 19 **Salehi S**, Abedi A, Balakrishnan S, Gholamrezanezhad A. Coronavirus Disease 2019 (COVID-19): A Systematic Review of Imaging Findings in 919 Patients. *AJR Am J Roentgenol* 2020; **215**: 87-93 [PMID: [32174129](#) DOI: [10.2214/AJR.20.23034](#)]
- 20 **Magro C**, Mulvey JJ, Berlin D, Nuovo G, Salvatore S, Harp J, Baxter-Stoltzfus A, Laurence J. Complement associated microvascular injury and thrombosis in the pathogenesis of severe COVID-19 infection: A report of five cases. *Transl Res* 2020; **220**: 1-13 [PMID: [32299776](#) DOI: [10.1016/j.trsl.2020.04.007](#)]
- 21 **Steinberger S**, Lin B, Bernheim A, Chung M, Gao Y, Xie Z, Zhao T, Xia J, Mei X, Little BP. CT Features of Coronavirus Disease (COVID-19) in 30 Pediatric Patients. *AJR Am J Roentgenol* 2020; **215**: 1303-1311 [PMID: [32442030](#) DOI: [10.2214/AJR.20.23145](#)]
- 22 **Chen A**, Huang J, Liao Y, Liu Z, Chen D, Yang C, Yang R, Wei X. Differences in Clinical and Imaging Presentation of Pediatric Patients with COVID-19 in Comparison with Adults. *Radiol Cardiothorac Imaging* 2020; **2**: e200117 [PMID: [33778567](#) DOI: [10.1148/ryct.2020200117](#)]
- 23 **Foust AM**, Phillips GS, Chun WC, Daltro P, Das KM, Garcia-Peña P, Kilborn T, Winant AJ, Lee EY. International Expert Consensus Statement on Chest Imaging in Pediatric COVID-19 Patient Management: Imaging Findings, Imaging Study Reporting and Imaging Study Recommendations. *Radiol Cardiothorac Imaging* 2020; **2**: e200214. [PMID: [33778577](#) DOI: [10.1148/ryct.2020200214](#)]
- 24 **Jones BP**, Tay ET, Elikashvili I, Sanders JE, Paul AZ, Nelson BP, Spina LA, Tsung JW. Feasibility and Safety of Substituting Lung Ultrasonography for Chest Radiography When Diagnosing Pneumonia in Children: A Randomized Controlled Trial. *Chest* 2016; **150**: 131-138 [PMID: [26923626](#) DOI: [10.1016/j.chest.2016.02.643](#)]
- 25 **Vazquez Martínez JL**, Pérez-Caballero Macarrón C, Coca Pérez A, Tapia Moreno R, Otheo de Tejada E. Short report - Usefulness of point-of-care ultrasound in pediatric SARS-CoV-2 infection. *Eur Rev Med Pharmacol Sci* 2020; **24**: 7801-7803 [PMID: [32744707](#) DOI: [10.26355/eurrev_202007_22284](#)]
- 26 **Soldati G**, Smargiassi A, Inchingolo R, Buonsenso D, Perrone T, Briganti DF, Perlini S, Torri E, Mariani A, Mossolani EE, Tursi F, Mento F, Demi L. Proposal for International Standardization of the Use of Lung Ultrasound for Patients With COVID-19: A Simple, Quantitative, Reproducible Method. *J Ultrasound Med* 2020; **39**: 1413-1419 [PMID: [32227492](#) DOI: [10.1002/jum.15285](#)]
- 27 **Musolino AM**, Supino MC, Buonsenso D, Ferro V, Valentini P, Magistrelli A, Lombardi MH, Romani L, D'Argenio P, Campana A; Roman Lung Ultrasound Study Team for Pediatric COVID-19 (ROMULUS COVID Team). Lung Ultrasound in Children with COVID-19: Preliminary Findings. *Ultrasound Med Biol* 2020; **46**: 2094-2098 [PMID: [32409232](#) DOI: [10.1016/j.ultrasmedbio.2020.04.026](#)]
- 28 **Hizal M**, Aykac K, Yayla BCC, Yilmaz A, Altun D, Akkaya HE, Bayhan GI, Kurt ANC, Karakaya J, Ozsurekci Y, Ceyhan M. Diagnostic value of lung ultrasonography in children with COVID-19.

- Pediatr Pulmonol* 2020 [PMID: 33085218 DOI: 10.1002/ppul.25127]
- 29 **Guitart C**, Suárez R, Girona M, Bobillo-Perez S, Hernández L, Balaguer M, Cambra FJ, Jordan I; KIDS-Corona study group; Kids Corona Platform. Lung ultrasound findings in pediatric patients with COVID-19. *Eur J Pediatr* 2021; **180**: 1117-1123 [PMID: 33089388 DOI: 10.1007/s00431-020-03839-6]
 - 30 **Poissy J**, Goutay J, Caplan M, Parmentier E, Duburcq T, Lassalle F, Jeanpierre E, Rauch A, Labreuche J, Susen S; Lille ICU Haemostasis COVID-19 Group. Pulmonary Embolism in Patients With COVID-19: Awareness of an Increased Prevalence. *Circulation* 2020; **142**: 184-186 [PMID: 32330083 DOI: 10.1161/CIRCULATIONAHA.120.047430]
 - 31 **Girona-Alarcon M**, Bobillo-Perez S, Sole-Ribalta A, Hernandez L, Guitart C, Suarez R, Balaguer M, Cambra FJ, Jordan I; KIDS-Corona study group; Kids Corona Platform. The different manifestations of COVID-19 in adults and children: a cohort study in an intensive care unit. *BMC Infect Dis* 2021; **21**: 87 [PMID: 33472588 DOI: 10.1186/s12879-021-05786-5]
 - 32 **Wang T**, Du Z, Zhu F, Cao Z, An Y, Gao Y, Jiang B. Comorbidities and multi-organ injuries in the treatment of COVID-19. *Lancet* 2020; **395**: e52 [PMID: 32171074 DOI: 10.1016/S0140-6736(20)30558-4]
 - 33 **Inciardi RM**, Lupi L, Zaccone G, Italia L, Raffo M, Tomasoni D, Cani DS, Cerini M, Farina D, Gavazzi E, Maroldi R, Adamo M, Ammirati E, Sinagra G, Lombardi CM, Metra M. Cardiac Involvement in a Patient With Coronavirus Disease 2019 (COVID-19). *JAMA Cardiol* 2020; **5**: 819-824 [PMID: 32219357 DOI: 10.1001/jamacardio.2020.1096]
 - 34 **Gnecchi M**, Moretti F, Bassi EM, Leonardi S, Totaro R, Perotti L, Zuccaro V, Perlini S, Preda L, Baldanti F, Bruno R, Visconti LO. Myocarditis in a 16-year-old boy positive for SARS-CoV-2. *Lancet* 2020; **395**: e116 [PMID: 32593338 DOI: 10.1016/S0140-6736(20)31307-6]
 - 35 **Nie SF**, Yu M, Xie T, Yang F, Wang HB, Wang ZH, Li M, Gao XL, Lv BJ, Wang SJ, Zhang XB, He SL, Qiu ZH, Liao YH, Zhou ZH, Cheng X. Cardiac Troponin I Is an Independent Predictor for Mortality in Hospitalized Patients With COVID-19. *Circulation* 2020; **142**: 608-610 [PMID: 32539541 DOI: 10.1161/CIRCULATIONAHA.120.048789]
 - 36 **Wacker J**, Malaspinas I, Aggoun Y, Bordessoule A, Vallée JP, Beghetti M. Coronary artery dilatation in a child with hyperinflammatory syndrome with SARS-CoV-2-positive serology. *Eur Heart J* 2020; **41**: 3103 [PMID: 32620946 DOI: 10.1093/eurheartj/ehaa536]
 - 37 **Hameed S**, Elbaaly H, Reid CEL, Santos RMF, Shivamurthy V, Wong J, Jogeesvaran KH. Spectrum of Imaging Findings at Chest Radiography, US, CT, and MRI in Multisystem Inflammatory Syndrome in Children Associated with COVID-19. *Radiology* 2021; **298**: E1-E10 [PMID: 32584166 DOI: 10.1148/radiol.2020202543]
 - 38 **Revzin MV**, Raza S, Warshawsky R, D'Agostino C, Srivastava NC, Bader AS, Malhotra A, Patel RD, Chen K, Kyriakakos C, Pellerito JS. Multisystem Imaging Manifestations of COVID-19, Part 1: Viral Pathogenesis and Pulmonary and Vascular System Complications. *Radiographics* 2020; **40**: 1574-1599 [PMID: 33001783 DOI: 10.1148/rg.2020200149]
 - 39 **Revzin MV**, Raza S, Srivastava NC, Warshawsky R, D'Agostino C, Malhotra A, Bader AS, Patel RD, Chen K, Kyriakakos C, Pellerito JS. Multisystem Imaging Manifestations of COVID-19, Part 2: From Cardiac Complications to Pediatric Manifestations. *Radiographics* 2020; **40**: 1866-1892 [PMID: 33136488 DOI: 10.1148/rg.2020200195]
 - 40 **Rodriguez-Gonzalez M**, Rodríguez-Campoy P, Sánchez-Códez M, Gutiérrez-Rosa I, Castellano-Martínez A, Rodríguez-Benítez A. New onset severe right ventricular failure associated with COVID-19 in a young infant without previous heart disease. *Cardiol Young* 2020; **30**: 1346-1349 [PMID: 32600496 DOI: 10.1017/S1047951120001857]
 - 41 **Valverde I**, Singh Y, Sanchez-de-Toledo J, Theocharis P, Chikermane A, Di Filippo S, Kucińska B, Mannarino S, Tamariz-Martel A, Gutierrez-Laraya F, Soda G, Vandekerckhove K, Gonzalez-Barlatay F, McMahon CJ, Marcora S, Napoleone CP, Duong P, Tuo G, Deri A, Nepali G, Ilina M, Ciliberti P, Miller O; AEPC COVID-19 Rapid Response Team*. Acute Cardiovascular Manifestations in 286 Children With Multisystem Inflammatory Syndrome Associated With COVID-19 Infection in Europe. *Circulation* 2021; **143**: 21-32 [PMID: 33166189 DOI: 10.1161/CIRCULATIONAHA.120.050065]
 - 42 **Alsaied T**, Tremoulet AH, Burns JC, Saidi A, Dionne A, Lang SM, Newburger JW, de Ferranti S, Friedman KG. Review of Cardiac Involvement in Multisystem Inflammatory Syndrome in Children. *Circulation* 2021; **143**: 78-88 [PMID: 33166178 DOI: 10.1161/CIRCULATIONAHA.120.049836]
 - 43 **Prieto LM**, Toral B, LLorente A, Coca D, Blázquez-Gamero D. Cardiovascular magnetic resonance imaging in children with pediatric inflammatory multisystem syndrome temporally associated with SARS-CoV-2 and heart dysfunction. *Clin Microbiol Infect* 2020 [PMID: 33049415 DOI: 10.1016/j.cmi.2020.10.005]



Published by **Baishideng Publishing Group Inc**
7041 Koll Center Parkway, Suite 160, Pleasanton, CA 94566, USA

Telephone: +1-925-3991568

E-mail: bpgoffice@wjgnet.com

Help Desk: <https://www.f6publishing.com/helpdesk>

<https://www.wjgnet.com>

