

World Journal of *Clinical Cases*

World J Clin Cases 2021 May 26; 9(15): 3487-3795



Contents

Thrice Monthly Volume 9 Number 15 May 26, 2021

OPINION REVIEW

- 3487 COVID-19 combined with liver injury: Current challenges and management
Deng ML, Chen YJ, Yang ML, Liu YW, Chen H, Tang XQ, Yang XF

MINIREVIEWS

- 3498 Cholesterol gallstones: Focusing on the role of interstitial Cajal-like cells
Fu BB, Zhao JN, Wu SD, Fan Y
- 3506 Association of hidradenitis suppurativa with Crohn's disease
Zhang M, Chen QD, Xu HX, Xu YM, Chen HJ, Yang BL
- 3517 Surgical treatment of hepatocellular carcinoma in the era of COVID-19 pandemic: A comprehensive review of current recommendations
Fancellu A, Sanna V, Scognamiglio F, Feo CF, Vidili G, Nigri G, Porcu A

ORIGINAL ARTICLE

Retrospective Cohort Study

- 3531 Critical prognostic value of the log odds of negative lymph nodes/tumor size in rectal cancer patients
Xie JB, Pang YS, Li X, Wu XT
- 3546 Effectiveness of adjunctive corticosteroid therapy in patients with severe COVID-19: A retrospective cohort study
Xiong B, He LM, Qin YY, Du H, Zhan Z, Zhou YH, Chen YK, Zhang A

Retrospective Study

- 3559 Multifactor study of efficacy and recurrence in laparoscopic surgery for inguinal hernia
Chen WL, Deng QQ, Xu W, Luo M
- 3567 Ultrasound-guided, direct suprainguinal injection for fascia iliaca block for total hip arthroplasty: A retrospective study
Wang YL, Liu YQ, Ni H, Zhang XL, Ding L, Tong F, Chen HY, Zhang XH, Kong MJ
- 3576 Changes in endoscopic patterns before and during COVID-19 outbreak: Experience at a single tertiary center in Korean
Kim KH, Kim SB, Kim TN

Observational Study

- 3586 Cleansing efficacy and safety of bowel preparation protocol using sodium picosulfate/magnesium citrate considering subjective experiences: An observational study
Liu FX, Wang L, Yan WJ, Zou LC, Cao YA, Lin XC

- 3597** Clinically significant endoscopic findings in patients of dyspepsia with no warning symptoms: A cross-sectional study

Mao LQ, Wang SS, Zhou YL, Chen L, Yu LM, Li M, Lv B

META-ANALYSIS

- 3607** Effect of antifoaming agent on benign colorectal tumors in colonoscopy: A meta-analysis

Zhang H, Gong J, Ma LS, Jiang T, Zhang H

CASE REPORT

- 3623** Subchondral bone as a novel target for regenerative therapy of osteochondritis dissecans: A case report

Zhang SY, Xu HH, Xiao MM, Zhang JJ, Mao Q, He BJ, Tong PJ

- 3631** Progressive familial intrahepatic cholestasis — farnesoid X receptor deficiency due to *NR1H4* mutation: A case report

Czubkowski P, Thompson RJ, Jankowska I, Knisely AS, Finegold M, Parsons P, Cielecka-Kuszyk J, Strautnieks S, Pawłowska J, Bull LN

- 3637** Postoperative pain due to an occult spinal infection: A case report

Kerckhove MFV, Fiere V, Vieira TD, Bahroun S, Szadkowski M, d'Astorg H

- 3644** Combined cesarean delivery and repair of acute aortic dissection at 34 weeks of pregnancy during COVID-19 outbreak: A case report

Liu LW, Luo L, Li L, Li Y, Jin M, Zhu JM

- 3649** Brucellosis of unknown origin with haemophagocytic syndrome: A case report

Tian LH, Dong ZG, Chen XY, Huang LJ, Xiao PP

- 3655** Recalcitrant paradoxical pustular psoriasis induced by infliximab: Two case reports

Xia P, Li YH, Liu Z, Zhang X, Jiang Q, Zhou XY, Su W

- 3662** Needle tract seeding of papillary thyroid carcinoma after fine-needle capillary biopsy: A case report

Shi LH, Zhou L, Lei YJ, Xia L, Xie L

- 3668** Metachronous pulmonary and pancreatic metastases arising from sigmoid colon cancer: A case report

Yang J, Tang YC, Yin N, Liu W, Cao ZF, Li X, Zou X, Zhang ZX, Zhou J

- 3675** Infiltrating ductal breast carcinoma with monoclonal gammopathy of undetermined significance: A case report

Ma Y, Cui S, Yin YJ

- 3680** Roxadustat as treatment for a blood transfusion-dependent maintenance hemodialysis patient: A case report and review of literature

Fei M, Wen XQ, Yu ZL, Kang T, Wu WH, Ou ST

- 3689** Small bowel ulcer bleeding due to suspected clopidogrel use in a patient with clopidogrel resistance: A case report

Lee SH, Ryu DR, Lee SJ, Park SC, Cho BR, Lee SK, Choi SJ, Cho HS

- 3696** Recurrent abdominal pain due to small bowel volvulus after transabdominal preperitoneal hernioplasty: A case report and review of literature
Man Y, Li BS, Zhang X, Huang H, Wang YL
- 3704** Malignant giant cell tumor in the left upper arm soft tissue of an adolescent: A case report
Huang WP, Zhu LN, Li R, Li LM, Gao JB
- 3711** Anesthetic management of bilateral pheochromocytoma resection in Von Hippel-Lindau syndrome: A case report
Wang L, Feng Y, Jiang LY
- 3716** Sarcomatoid carcinoma of the pancreas — a rare tumor with an uncommon presentation and course: A case report and review of literature
Toledo PF, Berger Z, Carreño L, Cardenas G, Castillo J, Orellana O
- 3726** Fulminant amebic colitis in a patient with concomitant cytomegalovirus infection after systemic steroid therapy: A case report
Shijubou N, Sumi T, Kamada K, Sawai T, Yamada Y, Ikeda T, Nakata H, Mori Y, Chiba H
- 3733** Maisonneuve injury with no fibula fracture: A case report
Liu GP, Li JG, Gong X, Li JM
- 3741** Alopecia treatment using minimally manipulated human umbilical cord-derived mesenchymal stem cells: Three case reports and review of literature
Ahn H, Lee SY, Jung WJ, Lee KH
- 3752** Pheochromocytoma in a 49-year-old woman presenting with acute myocardial infarction: A case report
Wu HY, Cao YW, Gao TJ, Fu JL, Liang L
- 3758** Lymphangiomas associated with protein losing enteropathy: A case report
Ding XL, Yin XY, Yu YN, Chen YQ, Fu WW, Liu H
- 3765** *De novo* multiple primary carcinomas in a patient after liver transplantation: A case report
Rao W, Liu FG, Jiang YP, Xie M
- 3773** Contralateral hemopneumothorax after penetrating thoracic trauma: A case report
İşcan M
- 3779** Bilateral posterior scleritis presenting as acute primary angle closure: A case report
Wen C, Duan H
- 3787** Bilateral cerebral infarction in diabetic ketoacidosis and bilateral internal carotid artery occlusion: A case report and review of literature
Chen YC, Tsai SJ

ABOUT COVER

Editorial Board Member of *World Journal of Clinical Cases*, Wei Wang, MD, PhD, Associate Professor, Key Laboratory on Technology for Parasitic Disease Prevention and Control, Jiangsu Institute of Parasitic Diseases, Wuxi 214064, Jiangsu Province, China. wangwei@jipd.com

AIMS AND SCOPE

The primary aim of *World Journal of Clinical Cases* (WJCC, *World J Clin Cases*) is to provide scholars and readers from various fields of clinical medicine with a platform to publish high-quality clinical research articles and communicate their research findings online.

WJCC mainly publishes articles reporting research results and findings obtained in the field of clinical medicine and covering a wide range of topics, including case control studies, retrospective cohort studies, retrospective studies, clinical trials studies, observational studies, prospective studies, randomized controlled trials, randomized clinical trials, systematic reviews, meta-analysis, and case reports.

INDEXING/ABSTRACTING

The WJCC is now indexed in Science Citation Index Expanded (also known as SciSearch®), Journal Citation Reports/Science Edition, Scopus, PubMed, and PubMed Central. The 2020 Edition of Journal Citation Reports® cites the 2019 impact factor (IF) for WJCC as 1.013; IF without journal self cites: 0.991; Ranking: 120 among 165 journals in medicine, general and internal; and Quartile category: Q3. The WJCC's CiteScore for 2019 is 0.3 and Scopus CiteScore rank 2019: General Medicine is 394/529.

RESPONSIBLE EDITORS FOR THIS ISSUE

Production Editor: Ji-Hong Lin; Production Department Director: Xiang Li; Editorial Office Director: Jin-Lai Wang.

NAME OF JOURNAL

World Journal of Clinical Cases

ISSN

ISSN 2307-8960 (online)

LAUNCH DATE

April 16, 2013

FREQUENCY

Thrice Monthly

EDITORS-IN-CHIEF

Dennis A Bloomfield, Sandro Vento, Bao-Gan Peng

EDITORIAL BOARD MEMBERS

<https://www.wjgnet.com/2307-8960/editorialboard.htm>

PUBLICATION DATE

May 26, 2021

COPYRIGHT

© 2021 Baishideng Publishing Group Inc

INSTRUCTIONS TO AUTHORS

<https://www.wjgnet.com/bpg/gerinfo/204>

GUIDELINES FOR ETHICS DOCUMENTS

<https://www.wjgnet.com/bpg/GerInfo/287>

GUIDELINES FOR NON-NATIVE SPEAKERS OF ENGLISH

<https://www.wjgnet.com/bpg/gerinfo/240>

PUBLICATION ETHICS

<https://www.wjgnet.com/bpg/GerInfo/288>

PUBLICATION MISCONDUCT

<https://www.wjgnet.com/bpg/gerinfo/208>

ARTICLE PROCESSING CHARGE

<https://www.wjgnet.com/bpg/gerinfo/242>

STEPS FOR SUBMITTING MANUSCRIPTS

<https://www.wjgnet.com/bpg/GerInfo/239>

ONLINE SUBMISSION

<https://www.f6publishing.com>



Fulminant amebic colitis in a patient with concomitant cytomegalovirus infection after systemic steroid therapy: A case report

Naoki Shijubou, Toshiyuki Sumi, Koki Kamada, Takeyuki Sawai, Yuichi Yamada, Tatsuru Ikeda, Hisashi Nakata, Yuji Mori, Hirofumi Chiba

ORCID number: Naoki Shijubou 0000-0001-8005-1745; Toshiyuki Sumi 0000-0002-2540-5878; Koki Kamada 0000-0002-8838-0508; Takeyuki Sawai 0000-0002-3022-2232; Yuichi Yamada 0000-0002-9080-4496; Tatsuru Ikeda 0000-0001-8230-7169; Hisashi Nakata 0000-0003-3900-8117; Yuji Mori 0000-0002-2523-6752; Hirofumi Chiba 0000-0002-7033-3084.

Author contributions: All authors contributed equally to this work; writing, reviewing and editing.

Informed consent statement: Written permission for publication of this case report and the accompanying images was obtained from the patient's wife.

Conflict-of-interest statement: The authors declare that they have no conflict of interest.

CARE Checklist (2016) statement: The authors have read the CARE Checklist (2016), and the manuscript was prepared and revised according to the CARE Checklist (2016).

Open-Access: This article is an open-access article that was selected by an in-house editor and fully peer-reviewed by external

Naoki Shijubou, Toshiyuki Sumi, Koki Kamada, Yuichi Yamada, Hisashi Nakata, Yuji Mori, Department of Respiratory Medicine, Hakodate Goryoukaku Hospital, Hakodate 040-8611, Japan

Naoki Shijubou, Toshiyuki Sumi, Koki Kamada, Takeyuki Sawai, Hirofumi Chiba, Department of Respiratory Medicine and Allergology, Sapporo Medical University School of Medicine, Sapporo 060-8556, Japan

Tatsuru Ikeda, Department of Pathology and Diagnosis, Hakodate Goryoukaku Hospital, Hakodate 040-8611, Japan

Corresponding author: Naoki Shijubou, MD, Doctor, Department of Respiratory Medicine, Hakodate Goryoukaku Hospital, 38-3 Goryoukaku-Cho, Hakodate-shi, Hakodate 040-8611, Japan. shijubou.1229@gmail.com

Abstract

BACKGROUND

Amebic colitis is an infection caused by *Entamoeba histolytica* and most commonly observed in regions with poor sanitation. It is also seen as a sexually transmitted disease in developed countries. While amebic colitis usually has a chronic course with repeated exacerbations and remissions, it may also manifest as a fulminant form that rapidly progresses and leads to severe, life-threatening complications, such as intestinal perforation, peritonitis, and sepsis, that have a high mortality rate.

CASE SUMMARY

A 68-year-old man was admitted to our hospital with chest pain and acute dyspnea. He was diagnosed with acute coronary syndrome, acute heart failure, and bacterial pneumonia. His respiratory condition worsened despite receiving intensive care and intravenous antibiotics. On the fifth day of hospitalization, he was diagnosed with acute respiratory distress syndrome and was started on steroid therapy. He subsequently developed bloody stools and was diagnosed with cytomegalovirus (CMV) enterocolitis based on biopsy results and a peripheral blood CMV pp65 antigenemia test result. Although we started antiviral therapy with ganciclovir, which was successful in reducing his antigen titers, he

reviewers. It is distributed in accordance with the Creative Commons Attribution NonCommercial (CC BY-NC 4.0) license, which permits others to distribute, remix, adapt, build upon this work non-commercially, and license their derivative works on different terms, provided the original work is properly cited and the use is non-commercial. See: <http://creativecommons.org/licenses/by-nc/4.0/>

Manuscript source: Unsolicited manuscript

Specialty type: Medicine, research and experimental

Country/Territory of origin: Japan

Peer-review report's scientific quality classification

Grade A (Excellent): 0
Grade B (Very good): B, B, B
Grade C (Good): C, C, C
Grade D (Fair): 0
Grade E (Poor): 0

Received: January 6, 2021

Peer-review started: January 6, 2021

First decision: January 24, 2021

Revised: February 2, 2021

Accepted: March 20, 2021

Article in press: March 20, 2021

Published online: May 26, 2021

P-Reviewer: Cho YS, Meyer A, Zhang ZX

S-Editor: Fan JR

L-Editor: A

P-Editor: Wang LL



continued to have bloody diarrhea. Three weeks after initiation of ganciclovir therapy and six weeks after his admission, the patient died from intestinal perforation. We only posthumously diagnosed him with amebic colitis and CMV enterocolitis based on autopsy findings of transmural necrosis of the entire colon with massive ameba infiltration.

CONCLUSION

We urge clinicians to consider *Entamoeba histolytica* infection if severe colitis progresses after steroid therapy. Preemptive treatment is recommended then.

Key Words: Amebiasis; Intestinal; Colitis; Cytomegalovirus; Glucocorticoids; Perforation; Case report

©The Author(s) 2021. Published by Baishideng Publishing Group Inc. All rights reserved.

Core Tip: The fulminant form of amebic colitis leads to severe, life-threatening complications such as intestinal perforation, peritonitis, and sepsis. We missed the diagnosis in a patient on steroid therapy who had a positive cytomegalovirus antigen test result. A high index of suspicion for possible *Entamoeba histolytica* infection is required. This is particularly relevant in patients with severe colitis that progresses after steroid therapy. We recommend preemptive treatment, even without a definite diagnosis, because of the high mortality rate.

Citation: Shijubou N, Sumi T, Kamada K, Sawai T, Yamada Y, Ikeda T, Nakata H, Mori Y, Chiba H. Fulminant amebic colitis in a patient with concomitant cytomegalovirus infection after systemic steroid therapy: A case report. *World J Clin Cases* 2021; 9(15): 3726-3732

URL: <https://www.wjgnet.com/2307-8960/full/v9/i15/3726.htm>

DOI: <https://dx.doi.org/10.12998/wjcc.v9.i15.3726>

INTRODUCTION

Amebic colitis is an infection caused by the parasitic protozoan *Entamoeba histolytica* that is more commonly observed in regions with poor sanitation. There are 40000–74000 annual deaths worldwide due to invasive amebiasis[1]. Amebic colitis also occurs as a sexually transmitted disease in developed countries, with 7763 cases reported from the first week of 2007 to week 43 of 2016 in Japan[2].

Amebic colitis generally follows a chronic course of repeated exacerbations and remissions. In some cases, the fulminant form may progress rapidly and lead to severe, life-threatening complications such as intestinal perforation, peritonitis, and sepsis[3].

We report on a patient with fulminant amebic colitis that was only diagnosed on autopsy. The patient had been mistakenly treated for cytomegalovirus (CMV) enteritis, which developed during steroid pulse therapy for acute respiratory distress syndrome (ARDS). Clinicians need to be aware of this rare but critical colitis manifestation that is frequently fatal.

CASE PRESENTATION

Chief complaints

A 68-year-old Japanese man (height: 160 cm, weight: 75 kg) was admitted to our hospital with chest pain and acute dyspnea. He worked as a truck driver and had never traveled abroad.

History of present illness

The chest pain and dyspnea had started a few days previously and had worsened over time. The patient had not received treatment prior to admission.

History of past illness

The patient's medical history included type 2 diabetes mellitus and hypertension that were treated with oral metformin hydrochloride (750 mg daily) and valsartan (80 mg daily), respectively. His diabetes was poorly controlled, with a hemoglobin A1c of 7.7%.

Personal and family history

He denied a history of similar diseases in close relatives.

Physical examination

On auscultation, his heart sounds were normal with no murmur. Coarse crackles were heard in both lungs. No other abnormalities were detected.

Laboratory examinations

Laboratory data at the time of admission are shown in [Table 1](#). In summary, his white blood cell count and C-reactive protein levels were high. Myocardial enzymes lactate dehydrogenase and aspartate aminotransferase were elevated, and troponin-T was positive. An anti-human immunodeficiency virus (HIV) antibody test result was negative.

Imaging examinations

His chest radiography on admission showed consolidation in the right upper lobe and bilateral congestion ([Figure 1](#)).

FINAL DIAGNOSIS

Cardiac infarction and bacterial pneumonia.

TREATMENT

The patient immediately underwent percutaneous coronary intervention and was subsequently admitted to the intensive care unit. On admission to the intensive care unit, his oxygen saturation was 92% with a reservoir mask providing 10 L oxygen/min) and his respiratory rate was 30 breaths/min.

He was intubated and started on invasive mechanical ventilation because of progressive respiratory failure. Although he was treated with intravenous antibiotics (levofloxacin 500 mg daily and ampicillin/sulbactam 9 g daily), vasodilators, and diuretics, he developed progressive respiratory failure, even with a fraction of inspired oxygen of 80% and a positive end expiratory pressure of 15 cmH₂O under ventilatory control.

OUTCOME AND FOLLOW-UP

On the fifth day of hospitalization, the patient was diagnosed with ARDS. We initiated extracorporeal membrane oxygenation and administered intravenous methylprednisolone 1 g daily for three days. Consecutively, prednisolone 60 mg daily was started to treat the infiltration observed on chest radiography. His respiratory condition subsequently improved by day eight. On the same day, we found blood in the patient's stool. We attributed this to the dual antiplatelet therapy started after percutaneous coronary intervention and decided to monitor the patient closely.

His condition stabilized, and we were able to discontinue the extracorporeal membrane oxygenation on day 10 and extubate him on day 12. His prednisolone dose was tapered to 40 mg daily by day 17, after which his respiratory condition suddenly worsened. The patient had to be re-intubated on day 18, at which time we again started intravenous methylprednisolone 1 g daily for three days. His respiratory condition improved, and prednisolone was reduced to 100 mg daily on day 21 and subsequently tapered as follows: 100 mg daily for one week, 80 mg daily for one week, and 60 mg daily for two weeks.

His bloody diarrhea, which had started on day 8, progressively worsened and we decided to perform a colonoscopy on day 22. The examination revealed multiple large

Table 1 Laboratory findings on admission of a 68-year-old man with complaints of chest pain and acute dyspnea

Hematology		Biochemistry		Serology	
WBC	16000 cells/ μ L	Total protein	7.4 g/dL	CRP	18.38 mg/dL
Neutrophils	79.0%	Albumin	3.2 g/dL	Troponin-T	1.76 ng/mL
Lymphocytes	13.7%	Total bilirubin	1.1 mg/dL	NT-proBNP	4526 pg/mL
Eosinophils	0.1%	AST	137 U/L	Anti-HIV1/2 Ab	Negative
RBC	504×10^4 cells/ μ L	ALT	131 U/L		
Hemoglobin	15.0 g/dL	LDH	720 U/L		
Hematocrit	43.8%	ALP	392 U/L		
Platelets	36.2×10^4 / μ L	CK	348 U/L		
		CK-MB	3.2 ng/mL		
		BUN	20.5 mg/dL		
		Creatinine	1.10 mg/dL		
		Na	132 mEq/L		
		K	4.3 mEq/L		
		Cl	97 mEq/L		
		HbA1c (NGSP)	7.7%		

ALP: Alkaline phosphatase; ALT: Alanine aminotransferase; AST: Aspartate aminotransferase; BUN: Blood urea nitrogen; CK: Creatinine kinase; CK-MB: Creatinine kinase MB; Cl: Chloride; CRP: C-reactive protein; HbA1c: Glycosylated hemoglobin; K: Potassium; LDH: Lactate dehydrogenase; Na: Sodium; NGSP: National glycohemoglobin standardization program; NT-proBNP: N-terminal pro-brain natriuretic peptide; RBC: Red blood cells; WBC: White blood cells; HIV: Human immunodeficiency virus.

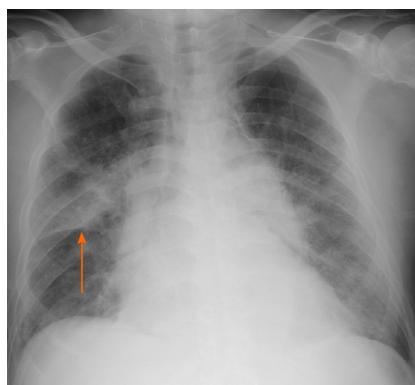


Figure 1 Chest radiography of a 68-year-old man with chest pain and acute dyspnea on admission. Chest radiography showing consolidation in the right upper lobe (arrow) and bilateral congestion.

ulcers in the sigmoid colon and rectum (Figure 2A and B). We biopsied one of the ulcers in the sigmoid colon, and the histopathological examination showed infiltration of neutrophils and lymphocytes as well as CMV-positive cells in the mucosa (Figure 2C and D). Based on these biopsy results and a CMV pp65 antigenemia (C7-HRP) test of the peripheral blood, which was positive in 20/50000 cells, we diagnosed the patient with CMV enterocolitis. We started treatment with ganciclovir (700 mg/d) on day 25.

Despite improved peripheral blood C7-HRP test results, the patient continued to have bloody diarrhea. On day 45, he complained of increasing abdominal pain. An abdominal computed tomography revealed free air, leading to the diagnosis of gastrointestinal perforation. Because of his poor general condition, surgical treatment was not considered. Unfortunately, the patient died the next day.

We performed an autopsy on the same day, where the pathologist noted full-thickness necrotic intestinal wall tissue throughout the entire colon (Figure 3A). We also detected severe infiltration of the necrotic tissue with ameba and a few CMV-

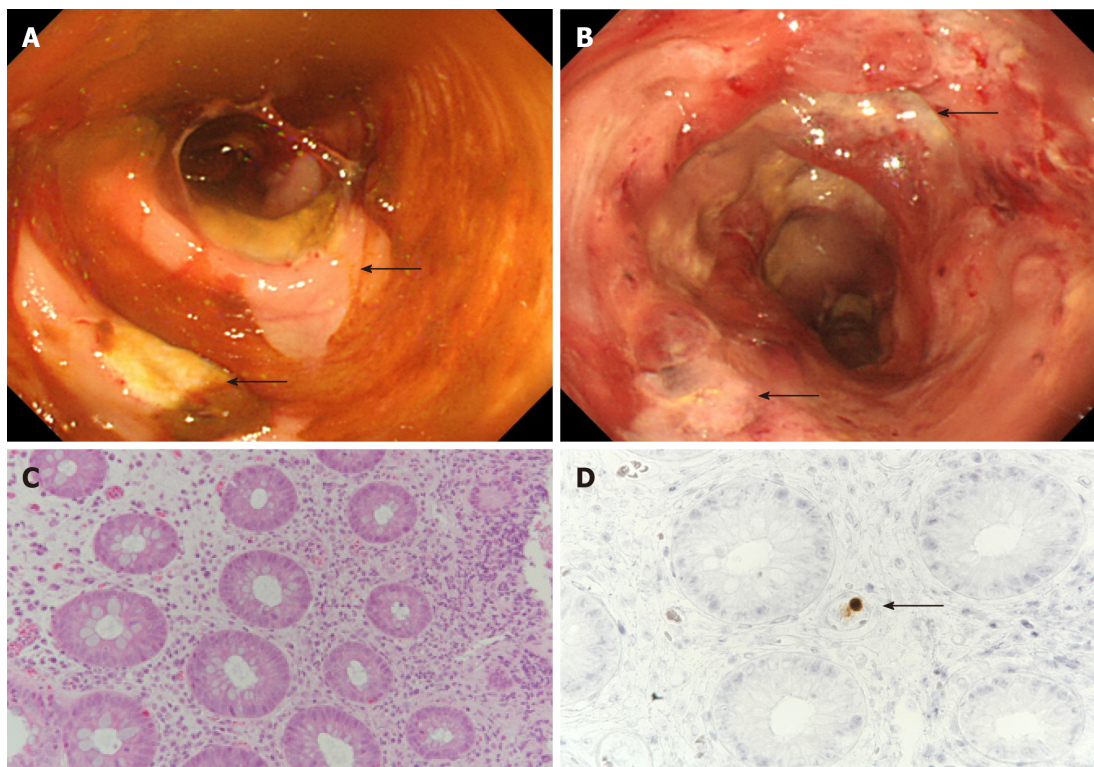


Figure 2 Colonoscopic and histopathological findings in a 68-year-old man who developed bloody diarrhea under glucocorticoid therapy.

A: Colonoscopy showing multiple large ulcers in the sigmoid colon (arrow) and active colitis throughout the colon; B: Colonoscopy also showing multiple large ulcers in the rectum (arrow); C: Neutrophilic and lymphocytic infiltration of the sigmoid colon's mucosal interstitium (hematoxylin and eosin stain, $\times 20$); D: Intranuclear inclusions of cytomegalovirus detected on immunohistochemical examination of the sigmoid colon's interstitium (arrow, $\times 20$).

positive cells in the colon (Figure 3B and C). We performed periodic acid-Schiff staining and detected *Entamoeba histolytica* trophozoites in the submucosa of the colon wall (Figure 3D).

DISCUSSION

We describe a patient with fulminant amebic colitis that progressed under steroid therapy. Initially, we had diagnosed the patient with CMV enterocolitis based on histopathological examination of a biopsy from one of several colon ulcers. However, despite starting ganciclovir and observing subsequent improvement of the peripheral blood antigenemia, the patient's colitis symptoms worsened. Eventually, we could only make a posthumous diagnosis of fulminant amebic colitis and CMV enterocolitis based on the autopsy findings.

We did not consider amebic colitis in our differential diagnosis when the bloody diarrhea developed and, therefore, did not screen the stool sample for *Entamoeba histolytica*. Amebic colitis is an infection caused by *Entamoeba histolytica* and is a common cause of diarrhea worldwide, being more prevalent in developing countries. In developed countries, amebic colitis is generally seen in migrants from endemic areas[4]. The majority of *Entamoeba histolytica* infections are asymptomatic, with 4%-10% of previously asymptomatic patients developing symptoms each year and 10% of infections causing amebic colitis[5-7].

Fulminant amebic colitis is associated with a high mortality rate in patients with immunosuppressive comorbidities, such as diabetes mellitus and chronic alcoholism[8]. Fulminant amoebic colitis has been reported in association with systemic steroid administration. Approximately 40% of patients with amebic colitis are initially misdiagnosed with inflammatory bowel disease and treated with steroids. There are reports of patients with asymptomatic amebic colitis who developed fulminant colitis after steroid administration[9]. As our patient was already immunosuppressed because of his diabetes mellitus, it is possible that he had subclinical amebic colitis, which only became apparent and progressed to the fulminant form after further immuno-suppression by the steroid pulse therapy. Amebic colitis should be

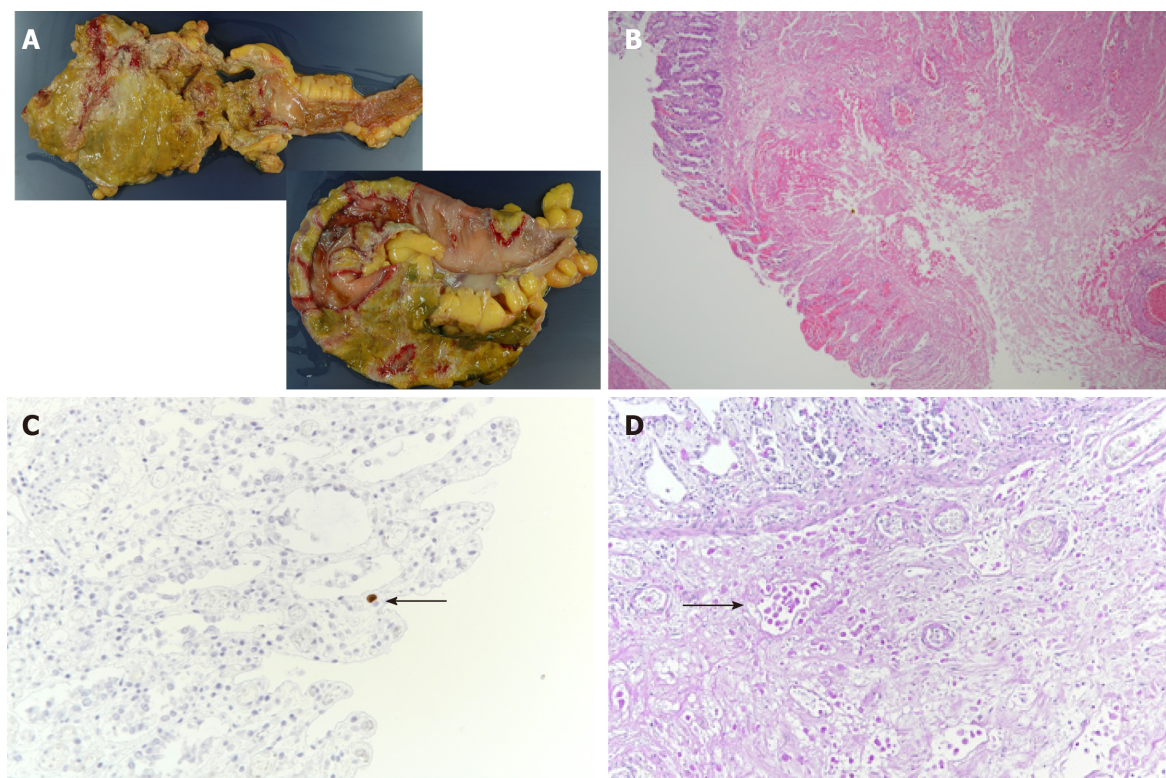


Figure 3 Macroscopic and histopathological findings during autopsy of a 68-year-old man who died after intestinal perforation. A: Macroscopic findings revealing transmural intestinal necrosis and a “ragged appearance” in the rectum, descending colon, and sigmoid colon; B: Histopathological findings showing full-thickness necrosis of the intestinal wall from the mucosa to the serosa. Furthermore, severe infiltration of the necrotic tissue with ameba is visible (hematoxylin and eosin stain, × 4); C: A few intranuclear cytomegalovirus inclusions can be detected on immunohistochemical examination of the sigmoid colon (arrow, × 40); D: *Entamoeba histolytica* trophozoites are visible in the submucosa (periodic acid–Schiff stain, arrow, × 20).

considered in the differential diagnosis when signs of colitis are exacerbated by steroid treatment.

Complications of amebic colitis and CMV enterocolitis are more frequently reported in HIV-infected patients than in non-HIV-infected patients[10]. We had performed a biopsy of one of the colon ulcers and initially diagnosed the patient with CMV enterocolitis. Although we initiated treatment with ganciclovir and could see an improvement in the C7-HRP test results, the patient’s colitis symptoms did not improve. The specificity of positive CMV antigenemia for diagnosing CMV colitis is high, and the progressive reduction of antigen titers is associated with therapeutic effects[11,12]. In our case, we should have considered amebic colitis because of the discrepancy between the successful lowering of the CMV antigen titers and the unabated colitis symptoms.

Amebic colitis perforation is typically associated with high a mortality rate of 50% despite aggressive surgical treatment. Early treatment with anti-amebic agents as well as earlier and more targeted surgery is needed to improve survival of these patients[13]. Consequently, we advocate for early, preemptive anti-amebic treatment in the case of severe colitis that is resistant to other therapies, even before the underlying cause has been identified. Next-generation sequencing is an unbiased and rapid diagnostic tool that can be helpful for accurate diagnosis and treatment. A study reported surgical cases of acute appendicitis in HIV-infected patients; the *E. histolytica* polymerase chain reaction test result was positive in 15.8% (9/57) of the appendiceal specimens. Of the resected specimens, only two tested positive for amoebic colitis; however, a higher diagnostic rate can be expected using a next-generation sequencer[14].

CONCLUSION

We urge clinicians to consider *Entamoeba histolytica* infection if severe colitis progresses after steroid therapy. We recommend preemptive treatment of patients with colitis, even without a definite diagnosis, because of its poor prognosis.

REFERENCES

- 1 **Stanley SL Jr.** Amoebiasis. *Lancet* 2003; **361**: 1025-1034 [PMID: [12660071](#) DOI: [10.1016/S0140-6736\(03\)12830-9](#)]
- 2 **National Institute of Infectious Diseases.** Amebiasis in Japan, week 1 of 2007-week 43 of 2016. *IASR* 2016; **37**: 239-240
- 3 **Adams EB, MacLeod IN.** Invasive amebiasis. I. Amebic dysentery and its complications. *Medicine (Baltimore)* 1977; **56**: 315-323 [PMID: [195178](#) DOI: [10.1097/00005792-197707000-00003](#)]
- 4 **Centers for Disease Control and Prevention (CDC).** Summary of notifiable diseases, United States, 1993. *MMWR Morb Mortal Wkly Rep* 1994; **42**: i-xviii; 1 [PMID: [9247368](#)]
- 5 **Haque R, Huston CD, Hughes M, Houpt E, Petri WA Jr.** Amebiasis. *N Engl J Med* 2003; **348**: 1565-1573 [PMID: [12700377](#) DOI: [10.1056/NEJMr022710](#)]
- 6 **Gathiram V, Jackson TF.** A longitudinal study of asymptomatic carriers of pathogenic zymodemes of *Entamoeba histolytica*. *S Afr Med J* 1987; **72**: 669-672 [PMID: [2891197](#)]
- 7 **Haque R, Ali IM, Sack RB, Farr BM, Ramakrishnan G, Petri WA Jr.** Amebiasis and mucosal IgA antibody against the *Entamoeba histolytica* adherence lectin in Bangladeshi children. *J Infect Dis* 2001; **183**: 1787-1793 [PMID: [11372032](#) DOI: [10.1086/320740](#)]
- 8 **Takahashi T, Gamboa-Dominguez A, Gomez-Mendez TJ, Remes JM, Rembis V, Martinez-Gonzalez D, Gutierrez-Saldivar J, Morales JC, Granados J, Sierra-Madero J.** Fulminant amebic colitis: analysis of 55 cases. *Dis Colon Rectum* 1997; **40**: 1362-1367 [PMID: [9369114](#) DOI: [10.1007/BF02050824](#)]
- 9 **Shirley DA, Moonah S.** Fulminant Amebic Colitis after Corticosteroid Therapy: A Systematic Review. *PLoS Negl Trop Dis* 2016; **10**: e0004879 [PMID: [27467600](#) DOI: [10.1371/journal.pntd.0004879](#)]
- 10 **Tsai HC, Lee SS, Wann SR, Chen YS, Chen ER, Yen CM, Liu YC.** Colon perforation with peritonitis in an acquired immunodeficiency syndrome patient due to cytomegalovirus and amoebic colitis. *J Formos Med Assoc* 2005; **104**: 839-842 [PMID: [16496064](#)]
- 11 **Chun J, Lee C, Kwon JE, Hwang SW, Kim SG, Kim JS, Jung HC, Im JP.** Usefulness of the cytomegalovirus antigenemia assay in patients with ulcerative colitis. *Intest Res* 2015; **13**: 50-59 [PMID: [25691843](#) DOI: [10.5217/ir.2015.13.1.50](#)]
- 12 **Lino K, Trizzotti N, Carvalho FR, Cosendey RI, Souza CF, Klumb EM, Silva AA, Almeida JR.** Pp65 antigenemia and cytomegalovirus diagnosis in patients with lupus nephritis: report of a series. *J Bras Nefrol* 2018; **40**: 44-52 [PMID: [29796586](#) DOI: [10.1590/2175-8239-JBN-3838](#)]
- 13 **Ozdogan M, Baykal A, Aran O.** Amebic perforation of the colon: rare and frequently fatal complication. *World J Surg* 2004; **28**: 926-929 [PMID: [15593469](#) DOI: [10.1007/s00268-004-7503-4](#)]
- 14 **Kobayashi T, Watanabe K, Yano H, Murata Y, Igari T, Nakada-Tsukui K, Yagita K, Nozaki T, Kaku M, Tsukada K, Gatanaga H, Kikuchi Y, Oka S.** Underestimated Amoebic Appendicitis among HIV-1-Infected Individuals in Japan. *J Clin Microbiol* 2017; **55**: 313-320 [PMID: [27847377](#) DOI: [10.1128/JCM.01757-16](#)]



Published by **Baishideng Publishing Group Inc**
7041 Koll Center Parkway, Suite 160, Pleasanton, CA 94566, USA

Telephone: +1-925-3991568

E-mail: bpgoffice@wjgnet.com

Help Desk: <https://www.f6publishing.com/helpdesk>

<https://www.wjgnet.com>

