

### [TAE Combined with Microwave Ablation in the Treatment of ...](#)

<https://europepmc.org/article/PPR/PPR189673> ▼

Jul 20, 2020 · After slight **treatment with TAE combined with ablation**, the **hemangioma** was mostly necrotic, and the volume was significantly reduced; at the very least, the **tumor** will not continue to grow rapidly and affect liver function, in line with the therapeutic purposes and concepts of benign **liver tumors**. **TAE combined with microwave ablation** is a safe and effective **minimally invasive treatment** for **hepatic hemangioma**.

**Author:** Yi-fu Feng, Xin-yi Chen, Jing-gang Mo, H... **Publish Year:** 2020

### [TAE Combined with Microwave Ablation in the Treatment of ...](#)

<https://www.researchsquare.com/article/rs-42707/v1> ▼

Then the patient was discharged from the hospital, and CT suggested that the **hepatic hemangioma** is significantly smaller two months after discharge. Because of COVID-19, the patient's CT examination was delayed. Conclusions: **TAE combined with microwave ablation** is a safe and effective **minimally invasive treatment** for **hepatic hemangioma**.

**Author:** Yi-fu Feng, Xin-yi Chen, Jing-gang Mo, H... **Publish Year:** 2020

### [Epithelioid hemangioma of the scapula treated with ...](#)

<https://www.sciencedirect.com/science/article/pii/S1017995X16300311>

Mar 01, 2018 · We **report** a rare **case** of bone EH occurring in the scapula, which was treated with a combination of chemoembolization and **microwave ablation**. To the best of our knowledge, this is the

Microsoft Bing

国内版 国际版

Minimally invasive treatment of hepatic hemangioma with transcat

Sign in

ALL

IMAGES

VIDEOS

12,200 Results Any time

TAE Combined with Microwave Ablation in the Treatment of ...

https://europepmc.org/article/PPR/PPR189673

Jul 20, 2020 - However, there are no reports of Transcatheter arterial embolization (TAE) combined with microwave ablation in the treatment of hepatic hemangiomas larger than 10 cm in diameter. Here, we report a case of hepatic hemangioma with diameter 10 cm treated successfully by TAE combined with microwave ablation.

Author: Yi-fu Feng, Xin-yi Chen, Jing-gang Mo... Publish Year: 2020

Search Tools

Turn off Hover Translation (关闭翻译)

Management of giant liver hemangioma.

https://www.alliedacademies.org/articles/...

Introduction

Literature Review

Surgical Approach

Discussion

Liver hemangiomas are congenital vascular malformations and are the most common benign liver tumors. Their prevalence varies from 5% to 20%. Most hemangiomas are asymptomatic, small (<4 cm) and often diagnosed incidentally on abdominal imaging studies. A hemangioma is qualified giant when having a diameter of more than 5 cm. Giant hemangiomas can become symptomatic and even may cause complications such as mechanical complications and coagulopathy [1]. Thereported studies dem...

See more on alliedacademies.org

Cited by: 2 Author: Abdolkader Boukerrouche

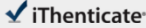
Publish Year: 2017

PEOPLE ALSO ASK

13-Jul-2021 01:05PM

2748 words • 19 matches • 3 sources

FAQ

 iThenticate®

62273\_Auto\_Edited.docx

Quotes Excluded  
Bibliography Excluded

83%  
(83/100)

1

**Name of Journal:** *World Journal of Clinical Cases*

**Manuscript NO:** 62273

**Manuscript Type:** CASE REPORT

Minimally invasive treatment of hepatic hemangioma with transcatheter arterial embolization combined with microwave ablation: A case report

Minimally invasive treatment of hepatic hemangioma

Lei-Zhi Wang, Kun-Peng Wang, Jing-Gang Mo, Guo-Yu Wang, Chong Jin, Hao Jiang, Yi-fu Feng

Match Overview

1

**Internet** 1959 words  
crawled on 21-Sep-2020  
[www.researchsquare.com](http://www.researchsquare.com)

70%

2

**Crossref Posted Content** 254 words  
Yu-fu Feng, Xin-yi Chen, Jing-gang Mo, Hai-ling Wu, Jian-yu Zhao, Chong Jin, Hao Jiang, Wang Kun-Peng, "TAE Combined w

9%

3

**Internet** 111 words  
crawled on 27-Oct-2020  
[publishing.blib.core.windows.net](http://publishing.blib.core.windows.net)

4%

1

2

PAGE: 1 OF 11

🔍

🔍

📊

🔍

🔄

Text-Only Report

国内版

国际版

Minimally invasive treatment of hepatic hemangioma with transcatheter



ALL

IMAGES

VIDEOS

12,200 Results

Any time ▾

## TAE Combined with Microwave Ablation in the Treatment of ...

<https://europepmc.org/article/PPR/PPR189673> ▾

Jul 20, 2020 - However, there are no reports of Transcatheter arterial embolization (TAE) combined with microwave ablation in the treatment of hepatic hemangiomas larger than 10 cm in diameter. Here, we report a case of hepatic hemangioma with diameter 10 cm treated successfully by TAE combined with microwave ablation.

Author: Yi-fu Feng, Xin-yi Chen, Jing-gang Mo,... Publish Year: 2020

## Management of giant liver hemangioma.

<https://www.alliedacademies.org/articles/...> ▾



Introduction

Literature Review

Surgical Approach

Discussion



**Liver hemangiomas** are congenital vascular malformations and are the most common benign **liver** tumors. Their prevalence varies from 5% to 20%. Most **hemangiomas** are asymptomatic, small (<4 cm) and often diagnosed incidentally on abdominal imaging studies. A **hemangioma** is qualified giant when having a diameter of more than 5 cm. Giant **hemangiomas** can become symptomatic and even may cause complications such as mechanical complications and coagulopathy [1]. The reported studies dem...

[See more on alliedacademies.org](https://www.alliedacademies.org)

Cited by: 2

Author: Abdelkader Boukerrouche

Publish Year: 2017

### PEOPLE ALSO ASK

Which is the best treatment for hepatic hemangiomas?



How long does it take to shrink hepatic hemangiomas tumor?



How long is the hospital stay for hepatic hemangiomas?



What is the mortality rate for giant hemangiomas?



Feedback