

World Journal of *Diabetes*

World J Diabetes 2021 August 15; 12(8): 1141-1362



EDITORIAL

- 1141 Clinical effects of antidiabetic drugs on psoriasis: The perspective of evidence-based medicine
Zhang MX, Zheng BY, Chen HX, Chien CW

REVIEW

- 1146 Gut microbiota as a target for prevention and treatment of type 2 diabetes: Mechanisms and dietary natural products
Xia F, Wen LP, Ge BC, Li YX, Li FP, Zhou BJ
- 1164 Current progress in metabolomics of gestational diabetes mellitus
Wang QY, You LH, Xiang LL, Zhu YT, Zeng Y
- 1187 Progress in treatment of type 2 diabetes by bariatric surgery
Jin ZL, Liu W
- 1200 Genetics of macrovascular complications in type 2 diabetes
Tonyan ZN, Nasykhova YA, Danilova MM, Glotov AS

MINIREVIEWS

- 1220 Place of intravitreal dexamethasone implant in the treatment armamentarium of diabetic macular edema
Karti O, Saatci AO
- 1233 Cardiac changes in infants of diabetic mothers
Al-Biltagi M, El razaky O, El Amrousy D
- 1248 Effect of inflammatory bowel disease treatments on patients with diabetes mellitus
Bower JAJ, O'Flynn L, Kakad R, Aldulaimi D
- 1255 Perioperative challenges in management of diabetic patients undergoing non-cardiac surgery
Galway U, Chahar P, Schmidt MT, Araujo-Duran JA, Shivakumar J, Turan A, Ruetzler K

ORIGINAL ARTICLE**Basic Study**

- 1267 Decabromodiphenyl ether causes insulin resistance and glucose and lipid metabolism disorders in mice
Alimu A, Abudureman H, Wang YZ, Li MY, Wang JS, Liu ZL

Case Control Study

- 1282 Clinical significance of serum miR-129-5p in patients with diabetes mellitus presenting macrovascular complications
He XY, Ou CL

Retrospective Study

- 1292** Association of β -cell function and insulin resistance with pediatric type 2 diabetes among Chinese children
Xu ZR, Du HW, Cui LW, Zheng RX, Li GM, Wei HY, Lu FY, Chen LL, Wu CS, Zhang SX, Zhang SL, Liu F, Zhang MY, Pei Z, Sun CJ, Wu J, Luo FH

Observational Study

- 1304** Polymorphisms in HIF-1 α gene are not associated with diabetic retinopathy in China
Liu YH, Guo C, Sun YQ, Li Q

SYSTEMATIC REVIEWS

- 1312** Which predictors could effect on remission of type 2 diabetes mellitus after the metabolic surgery: A general perspective of current studies?
Akkus G, Tetiker T
- 1325** What can we learn from β -cell failure biomarker application in diabetes in childhood? A systematic review
Calderón-Hernández MF, Altamirano-Bustamante NF, Revilla-Monsalve C, Mosquera-Andrade MB, Altamirano-Bustamante MM

ABOUT COVER

Editorial Board Member, Vaia D Raikou, PhD, Chief Doctor, Department of Nephrology, Doctors' Hospital, Athens 11257, Greece. vraikou@med.uoa.gr

AIMS AND SCOPE

The primary aim of *World Journal of Diabetes (WJD, World J Diabetes)* is to provide scholars and readers from various fields of diabetes with a platform to publish high-quality basic and clinical research articles and communicate their research findings online.

WJD mainly publishes articles reporting research results and findings obtained in the field of diabetes and covering a wide range of topics including risk factors for diabetes, diabetes complications, experimental diabetes mellitus, type 1 diabetes mellitus, type 2 diabetes mellitus, gestational diabetes, diabetic angiopathies, diabetic cardiomyopathies, diabetic coma, diabetic ketoacidosis, diabetic nephropathies, diabetic neuropathies, Donohue syndrome, fetal macrosomia, and prediabetic state.

INDEXING/ABSTRACTING

The *WJD* is now abstracted and indexed in Science Citation Index Expanded (SCIE, also known as SciSearch®), Current Contents/Clinical Medicine, Journal Citation Reports/Science Edition, PubMed, and PubMed Central. The 2021 Edition of Journal Citation Reports® cites the 2020 impact factor (IF) for *WJD* as 3.763; IF without journal self cites: 3.684; 5-year IF: 7.348; Journal Citation Indicator: 0.64□Ranking: 80 among 145 journals in endocrinology and metabolism; and Quartile category: Q3.

RESPONSIBLE EDITORS FOR THIS ISSUE

Production Editor: Lin-YuTong Wang; Production Department Director: Yu-Jie Ma; Editorial Office Director: Jia-Ping Yan.

NAME OF JOURNAL

World Journal of Diabetes

ISSN

ISSN 1948-9358 (online)

LAUNCH DATE

June 15, 2010

FREQUENCY

Monthly

EDITORS-IN-CHIEF

Timothy Koch

EDITORIAL BOARD MEMBERS

<https://www.wjnet.com/1948-9358/editorialboard.htm>

PUBLICATION DATE

August 15, 2021

COPYRIGHT

© 2021 Baishideng Publishing Group Inc

INSTRUCTIONS TO AUTHORS

<https://www.wjnet.com/bpg/gerinfo/204>

GUIDELINES FOR ETHICS DOCUMENTS

<https://www.wjnet.com/bpg/GerInfo/287>

GUIDELINES FOR NON-NATIVE SPEAKERS OF ENGLISH

<https://www.wjnet.com/bpg/gerinfo/240>

PUBLICATION ETHICS

<https://www.wjnet.com/bpg/GerInfo/288>

PUBLICATION MISCONDUCT

<https://www.wjnet.com/bpg/gerinfo/208>

ARTICLE PROCESSING CHARGE

<https://www.wjnet.com/bpg/gerinfo/242>

STEPS FOR SUBMITTING MANUSCRIPTS

<https://www.wjnet.com/bpg/GerInfo/239>

ONLINE SUBMISSION

<https://www.f6publishing.com>

Cardiac changes in infants of diabetic mothers

Mohammed Al-Biltagi, Osama El razaky, Doaa El Amrousy

ORCID number: Mohammed Al-Biltagi 0000-0002-7761-9536; Osama El Razaky 0000-0001-5045-0956; Doaa El Amrousy 0000-0001-7836-1170.

Author contributions: Al-Biltagi M had the idea, searched the topic, and wrote the manuscript draft; Al-Biltagi M, El Razaky O and El Amrousy D wrote and revised the manuscript; and all authors have read and approved the final manuscript.

Conflict-of-interest statement: The authors declare that they have no conflict of interests related to this article.

Open-Access: This article is an open-access article that was selected by an in-house editor and fully peer-reviewed by external reviewers. It is distributed in accordance with the Creative Commons Attribution NonCommercial (CC BY-NC 4.0) license, which permits others to distribute, remix, adapt, build upon this work non-commercially, and license their derivative works on different terms, provided the original work is properly cited and the use is non-commercial. See: <http://creativecommons.org/licenses/by-nc/4.0/>

Manuscript source: Invited manuscript

Specialty type: Cardiac and

Mohammed Al-Biltagi, Osama El razaky, Doaa El Amrousy, Department of Pediatrics, Faculty of Medicine, Tanta University, Tanta 35127, Egypt

Mohammed Al-Biltagi, Department of Pediatrics, University Medical Center, Arabian Gulf University, Manama 26671, Bahrain

Corresponding author: Mohammed Al-Biltagi, MD, PhD, Professor, Department of Pediatrics, Faculty of Medicine, Tanta University, Albahr Street, Tanta 35127, Egypt.
mbelrem@hotmail.com

Abstract

Diabetes mellitus (DM) is a systemic chronic metabolic disorder characterized by increased insulin resistance and/or β -cell defects. It affects all ages from the foetal life, neonates, childhood to late adulthood. Gestational diabetes is a critical risk factor for congenital heart diseases (CHDs). Moreover, the risk increases with low maternal education, high body mass index at conception, undiagnosed pre-gestational diabetes, inadequate antenatal care, improper diabetes control, and maternal smoking during pregnancy. Maternal DM significantly affects the foetal heart and foetal-placental circulation in both structure and function. Cardiac defects, myocardial hypertrophy are three times more prevalent in infants of diabetic mothers (IDMs). Antenatal evaluation of the cardiac function and structures can be performed with foetal electrocardiography and echocardiography. Postnatal cardiac evaluation can be performed with natal and postnatal electrocardiography and echocardiography, detection of early atherosclerotic changes by measuring aortic intima-media thickness, and retinal vascular changes by retinal photography. Ameliorating the effects of diabetes during pregnancy on the offspring depends mainly on pregestational and gestational diabetes prevention. However, other measures to reduce the risk, such as using medications, nutritional supplements, or probiotics, still need more research. This review discusses the mechanism of foetal sequels and the risk factors that increase the prevalence of CHDs in gestational DM, the various cardiac outcomes of gestational DM on the foetus and offspring, cardiac evaluation of foetuses and IDMs, and how to alleviate the consequences of gestational DM on the offspring.

Key Words: Gestational diabetes mellitus; Infants of diabetic mother; Hypertrophic cardiomyopathy; Congenital heart diseases; Echocardiography; Children

©The Author(s) 2021. Published by Baishideng Publishing Group Inc. All rights reserved.

cardiovascular systems

Country/Territory of origin: Egypt**Peer-review report's scientific quality classification**

Grade A (Excellent): 0

Grade B (Very good): 0

Grade C (Good): 0

Grade D (Fair): 0

Grade E (Poor): 0

Received: January 7, 2021**Peer-review started:** January 7, 2021**First decision:** May 3, 2021**Revised:** May 11, 2021**Accepted:** July 7, 2021**Article in press:** July 7, 2021**Published online:** August 15, 2021**P-Reviewer:** Papadopoulos KG**S-Editor:** Ma YJ**L-Editor:** A**P-Editor:** Ma YJ

Core Tip: Gestational diabetes mellitus (DM) has a significant impact on cardiac function and structure, both antenatally and postnatally, an effect that could persist till late adulthood. Therefore, prevention, early detection, and strict management of gestational DM could help to minimize the risk of cardiac disorders in the foetus, neonates, children, and even adults.

Citation: Al-Biltagi M, El razaky O, El Amrousy D. Cardiac changes in infants of diabetic mothers. *World J Diabetes* 2021; 12(8): 1233-1247

URL: <https://www.wjgnet.com/1948-9358/full/v12/i8/1233.htm>

DOI: <https://dx.doi.org/10.4239/wjd.v12.i8.1233>

INTRODUCTION

Diabetes mellitus (DM) is a systemic chronic metabolic disorder characterized by increased insulin resistance and/or β -cell defects. It is a microvascular disease that affects all ages, from foetal life to late adulthood. Diabetes during pregnancy could be a de novo that arises during pregnancy for the first time and could disappear or persist after delivery (gestational DM) or could start as pregestational, before the onset of pregnancy. The incidence of impaired glucose tolerance in pregnancy ranges between 3-10% and varies according to the average incidence of diabetes in the general population[1]. The risk of gestational diabetes increases with maternal overweight and obesity, advanced maternal age at conception (> 30 years), presence of glucosuria on more than two occasions, previous history of gestational diabetes, family history of type-2 DM, polycystic ovary syndrome, polyhydramnios, male foetus, multiple pregnancy, previous big baby (> 4 kg), ethnicity (non-white ancestry), lifestyle (physical inactivity before and during pregnancy), environmental (as cigarette smoking, persistent organic pollutants, and endocrine disruptors), and psychosocial factors (as depression in the first or second trimester)[2]. In a normal pregnancy, there is a 30% increase in basal endogenous glucose production (primarily hepatic) by the end of pregnancy despite the high fasting insulin levels. However, hypoglycaemia could occur in early pregnancy due to increased plasma volume (dilutional hypoglycaemia) and in late pregnancy due to increased glucose utilization. In addition, peripheral insulin sensitivity may decrease by approximately 50% by late gestation, which induces an increase in insulin secretion by 2-3-folds in women with normal glucose tolerance and may disturb the maternal amino acids and lipid metabolism[3, 4]. In gestational diabetes, β -cell dysfunction could occur because of the additional stress on β -cells due to excessive gestational weight gain and the uprising insulin resistance; or due to β -cells damage caused by autoantibodies against specific β -cell antigens. In gestational DM, the rate of insulin-stimulated glucose uptake is reduced by 54% compared to the normal pregnancy[5].

MECHANISM OF FOETAL AFFECTION IN GESTATIONAL DM

The foetal heart is targeted by the pre-existing and gestational maternal DM through complex multi-factorial pathogenesis that affects both the foetal heart and foetal-placental circulation in both structure and function. The severity of the foetal cardiac damage is related to the type of DM, the level of HbA1c in early pregnancy, and the degree and duration of hyperglycaemia and hyperketonaemia. Both hyperglycaemia and hyperketonaemia are toxic to the developing embryo inducing and modifying multiple biochemical and signal transduction pathways and increasing the production of excess free oxidative radicals. Hyperglycaemia also increases apoptosis and impairs autophagy, cell homeostasis, proliferation, and migration of neural crest cells, which are critical to the developing heart and brain[6,7]. The teratogenic effect of hyperglycaemia is prominent in the first six weeks of pregnancy (period of organogenesis), especially in mothers with pregestational diabetes, inducing diabetic fetopathy with glucose-mediated disturbances of left-right patterning, congenital cardiac malformations, foetal cardiomyopathy, foetal venous thrombosis, altered placental villi vascularization, and pathological foetal heart rates even with tight maternal glycaemic control[8]. Intrauterine chronic hyperglycaemia induces

reflex chronic foetal hyperinsulinemia that increases the total body weight and causes selective organomegaly because of hypertrophy of the insulin-sensitive tissues, including the heart and increased expression and affinity of insulin receptors[9] (Figure 1).

The effects of maternal DM are related to the metabolic derangements and the induction of epigenetic changes affecting the expression of specific placental genes in response to diabetes-induced chronic stress and inflammation. These effects have an essential role in the development of maternal diabetes-induced embryopathy[10]. Hypoglycaemia is a potential teratogen and a common complication during the management of gestational DM. It contributes to the development of diabetic embryopathy as it disrupts normal cardiogenesis and alters morphology, function, metabolism, and expression of specific proteins in the developing heart[11]. Maternal diabetes-induced placental vasculopathic abnormalities and the relative immaturity of the placenta cause a state of chronic foetal hypoxemia, which in turn causes compensatory polycythemia and changes in foetal circulation[12]. The foetal hyperinsulinemia present in gestational DM causes foetal macrosomia. In foetal macrosomia, there is an increase in the cardiac mass due to a larger mass of myocardial nuclei, increased cell number, and hypertrophy of myocardial fibres, which in turn induces underdeveloped foetal ventricular compliance and consequently diastolic dysfunction secondary to a thickened cardiac wall. The foetal macrosomia and the associated ventricular hypertrophy could occur very early, even before 20 wk of gestation. Moreover, accelerated growth of the foetal heart occurs in the second and third trimesters compared to foetuses of non-diabetic pregnancies[13].

RISK FACTORS THAT INCREASE THE PREVALENCE OF CONGENITAL HEART DISEASES IN GESTATIONAL DIABETES

Gestational diabetes per se is a significant risk factor to develop congenital heart diseases (CHD). Moreover, other factors may increase CHD risk in the infants of diabetic mothers (IDMs). Low maternal education (less than high school level) is an additional factor that increases CHD risk[14]. High body mass index (BMI) at conception and possibly undiagnosed pre-gestational diabetes are also significant risk factors that increase the risk of CHD in gestational diabetes[15]. Infants born to mothers with pregestational diabetes have higher risks of mortality and morbidity than gestational DM. In a cohort of two million births over 34-year, Øyen *et al*[15] found a four-times increase in the offspring risk of CHDs in maternal pre-gestational DM (both types 1 and 2). Gestational DM was only weakly associated with increased risk[16]. Inadequate antenatal care and improper diabetes control are also critical confounding factors, increasing the risk. Todorova *et al*[17] showed a strong association of the foetal abnormalities with higher glycated haemoglobin levels, especially in the first trimester of pregnancy. They also found that pregnancies with poor first trimester glycaemic control were more prone to the presence of foetal heart disease[18]. Studies had confirmed that women who have close monitoring and proper glycaemic control in a normal range at the time of conception and early in pregnancy had a markedly lower risk of having an infant with CHD than women with poor control. Maternal smoking during pregnancy may increase the risk of CHDs by itself. Moreover, maternal tobacco smoking and pregestational diabetes intensify the effects of each other on preterm birth and the risk of congenital anomalies, including CHDs[19]. On the other side, studies showed that early antenatal antioxidants administration (such as lipoic acid, vitamin C, and N-acetylcysteine) in diabetic mice was associated with decreased risk of CHDs[20].

EFFECT OF DIABETES ON THE HEART OF FOETUS AND OFFSPRING OF DIABETIC MOTHERS

DM, with its hyperglycaemic milieu before conception and during the first trimester, is associated with diabetic embryopathy in the developing foetus, as it affects the heart, the great vessels, and the neural tube[21]. Diabetic fetopathy is still a common clinical problem correlated with high neonatal morbidity and mortality. The foetal heart is more prone to the development of congenital malformations in both pre-existing and gestational DM. Cardiac defects and myocardial hypertrophy are three times more prevalent in the offspring of women with DM. Maternal DM significantly affects the

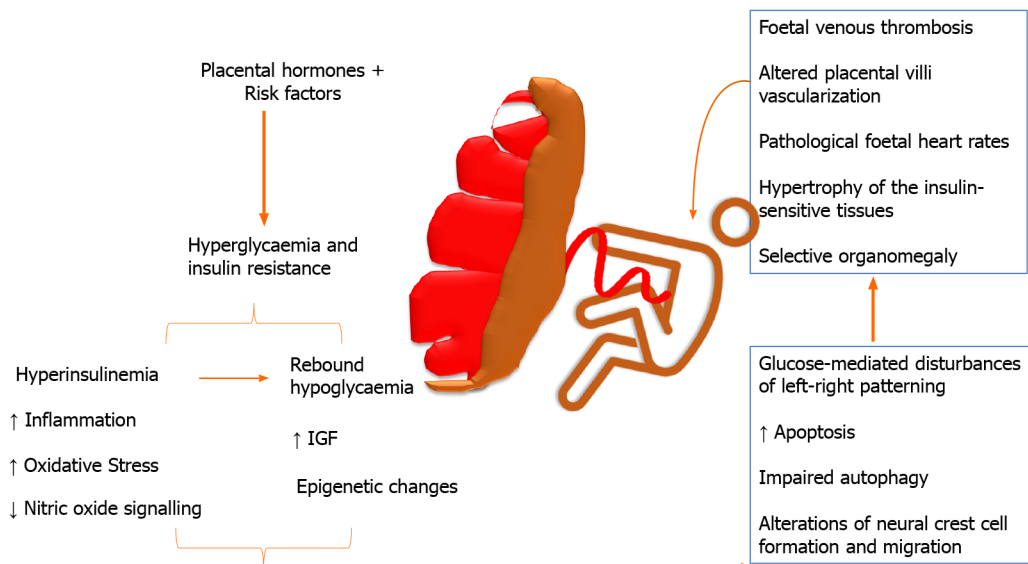


Figure 1 Possible mechanisms of foetal cardiac damage in gestational diabetes. IGF-I: insulin-like growth factor-I.

foetal heart and foetal-placental circulation in both structure and function and alters the placental villi vascularization with a wide range of cardiac anomalies ranging from small septal defects to major complex heart diseases. These effects on the foetal, neonatal, and child heart are summarized in [Table 1](#).

Gestational diabetes primarily affects placental circulation. Alteration of the placental development and subsequent vascular dysfunction occurs in six out of seven women with various diabetic severity. The typical placental changes in gestational diabetes include villous immaturity, villous fibrinoid necrosis, infarcts, intervillous thrombosis, increased syncytial knotting, chorangiosis, and increased angiogenesis. These placental changes cause uteroplacental circulation/maternal vascular mal perfusion. The types and effects of the dysfunction depend on how early in pregnancy hyperglycaemia occurs[24]. In addition to the pregnancy induced-hypercoagulability states, maternal hyperglycaemia increases the thrombogenic status. When combined with hyper coiling of the cord, it causes vascular stasis and ischemia resulting in thrombosis in the foetal vascular tree leading to foetal growth restriction and increased perinatal morbidity and mortality[25]. In addition, the umbilical vessels showed pathological changes in line with early atherosclerosis, including focal intimal thickening and glycogen accumulations in the intima and the media cells. The presence of a thin umbilical cord with a single umbilical artery is associated with increase adverse foetal outcome in gestational diabetes[26]. The associated foetal hypoxia contributes to increased erythropoiesis, polycythaemia and promotes catecholamines production, which causes hypertension and cardiac hypertrophy; and may contribute to the 20%–30% of stillbirth seen in poorly controlled diabetic pregnancies[27]. An altered response of the foetal autonomic nervous system to the metabolic stress in pregnancies with complicated gestational diabetes increases the mean foetal heart rate. It impairs the heart rate variability[28].

The main structural alteration in the foetus of a pregnant diabetic mother is myocardial hypertrophy which can lead to transient subaortic stenosis and occasionally causes congestive heart failure (CHF). Chronic foetal hyperinsulinemia causes foetal macrosomia and increases the cardiac mass due to a larger mass of myocardial nuclei, increased cell number, and hypertrophy of myocardial fibres secondary to an increase in the synthesis of proteins and fats, independent of the amount of glycogen deposition, resulting from the increased presence of insulin receptors in the foetal heart[29]. Hypertrophic cardiomyopathy (HCM) is the most common cardiac malformation in up to 40% of diabetic pregnancies. HCM is more common in pre-gestational DM than gestational DM. This myocardial hypertrophy is characterized by the thickening of the interventricular septum and ventricular walls. It is usually asymptomatic in the foetus but may present with systolic and diastolic dysfunction of the neonatal heart.

In addition, the left ventricular mass and contractility are increased with left ventricular outflow tract (LVOT) obstruction due to apposition of the anterior leaflet of the mitral valve to the interventricular septum during systole. As a result, cardiac

Table 1 The cardiac effect of Gestational Diabetes on the foetus, neonates as late effects**Foetal effects[22]**

Foetal-placental circulation in both structure and function and altered placental villi vascularization

Congenital cardiac malformations

Foetal cardiomyopathy

Foetal venous thrombosis

Pathological foetal heart rates

Diabetic fetopathy-associated heart failure

Single umbilical artery

Neonatal effects[22]

Cardiovascular maladaptation to extra-uterine life

Hypertrophic cardiomyopathy (adaptive hypertrophy)

Pericardial effusion (15%)

Intermittent or persistent bradycardia

Cardiomegaly

Simple congenital heart diseases:

Patent foramen ovale

Patent ductus arteriosus

Ventricular septal defect

Atrial septal defect

Aortic coarctation (Isolated)

Complex congenital heart diseases:

Tetralogy of Fallot

Aortic coarctation (when associated with other CHDs)

Persistent truncus arteriosus

Hypoplastic left ventricle.

Visceral heterotaxia

Single ventricle

Long term effects[23]

Increased rates of early-onset CVD from childhood to early adulthood (29% more than from non-diabetic mothers):

Overall CVD

Ischaemic heart disease

Cerebrovascular disease

Stroke

Heart failure

Atrial fibrillation

Hypertensive disease

Deep vein thrombosis

Pulmonary embolism

CHDs: Congenital heart diseases; CVD: Cardiovascular diseases.

output is significantly reduced, secondary to reduced stroke volume and is directly related to the degree of septal hypertrophy. Moreover, it may result in CHF in the immediate postnatal period (with tachypnoea, tachycardia, gallop rhythm and hepato-

megaly). However, this is uncommon and transient, and cardiac hypertrophy may disappear around 6-24 mo after birth[30]. This asymmetric septal thickening, with a disproportionally hypertrophic septum, is an anabolic result of foetal hyperinsulinemia triggered by maternal hyperglycaemia during the third trimester[31]. Therefore, we should rule out other causes of HCM (infections, other metabolic derangements, neurologic affections, syndromes).

Cardiovascular malformations are among the most common malformations in the IDMs, accounting for 3%-9% of diabetic pregnancies and about 2.5-10 times higher than observed in normal pregnancies. The highest relative risk for major cardiovascular defects occurs if the mother has gestational diabetes and develops insulin resistance in the 3rd trimester[31]. The reported complications incidence was 3.4% with maternal HbA1c levels lower than 8.5, and 22.4 % with HbA1c levels higher than 8.5%. Infants born to mothers with an HbA1c level of more than 10% in late pregnancy tend to have neonatal complications[32].

There is an increased risk of laterality and cardiac looping defects (heterotaxia), cardiac outflow tract anomalies, atrioventricular and membranous ventricular septal defects but no increased risk of muscular ventricular septal defects and atrial septal defects[21]. The most common cardiac defects that occur in foetuses of diabetic mothers include ventricular septal defect, transposition of great arteries (TGA), patent ductus arteriosus, aortic stenosis, pulmonary atresia, dextrocardia, and conotruncal defects (tetralogy of Fallot, truncus arteriosus and double outlet right ventricle)[33,34].

Immediately after delivery, the neonate starts a critical process to adapt to the extra-uterine life during the first 6 to 8 h of life, known as the transitional period. Changes in the cardiovascular system are the most important changes when the foetal bypass shunts close, and blood normally circulates[35]. Metabolic alterations of the intrauterine environment in gestational diabetes cause foetal cardiac dysfunctions that can persist after birth and impair neonatal transitional haemodynamics even in asymptomatic neonates[36]. They have a prolonged isometric contraction phase of right ventricle (RV) with elevated RV pre-ejection period (RVPEP)/RV ejection time (RVET) ratio (RVPEP/ RVET Ratio). This ratio correlates closely with pulmonary vascular resistance (PVR) and pulmonary artery diastolic pressure suggesting an abnormality of the transitional pulmonary circulation. The persistence of foetal circulation syndrome is found with a higher frequency in IDMs, leading to cardiorespiratory distress in the first 24 h of life. There is delayed closure of the ductus arteriosus and delayed postnatal decrease in pulmonary artery pressure in these neonates, causing right-to-left shunting through a patent ductus arteriosus and/or patent foramen oval, which could explain the increased frequency of respiratory disorders and the delay in the recovery of these infants. Cardiomegaly, venous congestion, hepatomegaly, and pleural effusion may be seen radiographically. It is not well understood why high pulmonary resistance persists. It could be related to hyperviscosity, hypoglycaemia, atypical respiratory distress syndrome, and/or idiopathically[37].

Primary pulmonary hypertension may be due to increased muscularization of small pulmonary arteries. It also associated with and aggravated by polycythaemia which is frequently present in these neonates[31]. The persistence of foetal shunts and decreased RV output in IDMs suggest that even those with reasonable gestational glycaemic control have impaired transitional haemodynamics[38]. Cardiomegaly could present in IDMs without hypertrophic cardiomyopathy due to persistent foetal circulation or transient increase in pulmonary pressure due to increased interstitial pulmonary fluids, which causes transient tachypnoea of the newborn (because of increased incidence of Caesarean section). Neonatal hypoglycaemia, which is more frequent in IDMs, could lead to cardiomegaly and electrocardiographic abnormalities [39]. Studies also showed that about 8% of IDMs have bradycardia[40]. The neonates should also be monitored for the possible occurrence of bradycardia because of using β eta-blockers like propranolol to treat symptomatic hypertrophic cardiomyopathy.

Gestational diabetes does not only affect the foetus or the neonates but could also affect the offspring till adulthood. Exposure to hyperglycaemia in utero may program future diseases risk *via* changes in critical developmental pathways because of altered gene expression. Current evidence suggests that atherosclerosis and cardiovascular risks begin in utero and are compounded by postnatal influences. According to some studies, maternal gestational diabetes, especially with a complicated pregnancy, induces the development of many recognised cardiovascular risk factors in their progeny with an adverse risk profile that persists into early adulthood. Increased rates of hypertension, hyperglycaemia, and overweight in young adults suggest that this group is at an increased risk of developing cardiac sequelae in later life (up to 40 years) [23].

CARDIAC EVALUATION OF FOETUSES AND IDMS

Antenatal evaluation

Foetal cardiac function evaluation provides essential information on the hemodynamic status and the cardiovascular adaptation of the foetus for different perinatal adverse effects. Foetal electrocardiography and echocardiography are non-invasive and simple procedures that could adequately evaluate the foetal cardiac structures and functions.

Foetal electrocardiography

The foetal electrocardiography (FECG) signal can be recorded invasively – directly from the foetal head during labour and non-invasively – indirectly from the electrodes placed on the maternal abdominal wall both during pregnancy and labour. Gestational DM has an evident effect on the foetal heart rate and rhythm. The alteration is slight but evident and reflects foetal welfare, and correlate with neonatal reactivity. Foetal heart rhythms can be recorded using a portable electrocardiography (ECG) device. Only cardiotocography (CTG) may allow detecting those slight but significant differences. Foetal ECG during delivery showed a significant ST depression which is more prevalent in foetuses of diabetic mothers during delivery than in foetuses of nondiabetic mothers. These changes are probably not indicating hypoxia but related to an altered ability of the myocardium to respond to labour stress. The presence of these changes could give meaningful information to predict moderate foetal acidaemia[41, 42].

Foetal echocardiography

Foetal echocardiography is a well-established, accurate, and safe technique. It is considered a part of the routine screening at 24 wk in prediabetic and diabetic women to rule out cardiac defects. The foetal cardiac structures can be defined with conventional transabdominal echocardiography at 16 to 18 wk of gestation with accurate segmental analysis of cardiac structures and blood flow across valves, shunts, and the ductus arteriosus. However, we can identify the cardiac structures as early as 12 wk of gestation using endovaginal echocardiographic probes with high-resolution transducers. Nevertheless, the optimum period to perform a screening examination is at 20-22 wk. At that time, the foetal cardiac structures can be defined more clearly with ultrasound screening in more than 90% of cases[43]. Foetal echocardiography is indicated in every case of gestational diabetes, especially in the presence of signs that increase the possibility of the presence of abnormal cardiac structures such as a persistent right umbilical vein, single umbilical artery, abnormal echogenic intracardiac foci, an aberrant right subclavian artery, or presence of foetal arrhythmia[44].

Foetal myocardial hypertrophy is reported in about 25%-30% of cases as a complication of gestational or pregestational maternal diabetes. Foetal echocardiography has a sensitivity of 90% and a specificity of 99.7%, with a positive predictive value of 90%[34]. Therefore, early detection of CHDs and evidence of HCM and foetal cardiac dysfunction that occur in foetuses of gestational diabetes will certainly direct rapid postnatal therapy and better supportive care for those neonates and prevent complications such as respiratory distress, sepsis, and hypoglycaemia[45].

Epicardial fat tissue (EFT) located between the myocardium and visceral pericardium is directly connected to the myocardium, share the same microcirculation, maintains the energy supply to the heart, serves as an anatomic barrier, and can secrete hormones, such as adiponectin and leptin. The thickness of EFT is related to obesity, hypertension, insulin resistance, and coronary artery disease. Foetal EFT values are increased in gestational DM cases. This increase can be detected even at 24 wk of gestation. In addition, foetal EFT values are positively correlated with HbA1c values and can be an early predictor for gestational DM diagnosis[46].

M-mode and 2-D echocardiography can illustrate cardiomegaly secondary to free wall hypertrophy (30%), asymmetric septal hypertrophy, and foetal ventricular walls thickness that simulates idiopathic hypertrophic subaortic stenosis and increases progressively with advancing gestation. Doppler imaging can detect foetal cardiac diastolic dysfunction, which is more observed in foetuses of women with pre-existing diabetes than those of women with well-controlled gestational diabetes[47,48]. However, fatal cases of HCM are observed in cases with diabetic fetopathy. In diabetic fetopathy, the affected neonates are macrosomic and suffer from respiratory distress due to delayed lung maturity, acidosis, hypoglycaemia, electrolyte imbalances, and polycythaemia. Severe hypertrophy of RV is associated with intrauterine HF and occasionally stillbirth.

Moreover, performing echocardiography in such cases can demonstrate cardiomegaly and increased thickness of RV, the interventricular septum, and LV free wall with disproportionate septal hypertrophy in about one-quarter of cases[49]. Tissue Doppler imaging (TDI) can elaborate on the presence of early foetal cardiac dysfunction, even in the absence of structural abnormalities. The ability to detect early cardiac dysfunction is valuable in monitoring and timing the delivery of complicated preterm pregnancy[50]. Two-dimensional speckle-tracking echocardiography (STE) could offer an additional benefit over conventional echocardiography to detect subclinical unfavourable changes in myocardial function in this population. Miranda *et al*[51] found biventricular diastolic and RV systolic dysfunction by deformation analysis using STE in the third trimester of pregnancy. In our experience with antenatal STE for fetuses of mothers with DM, deformation analysis using STE can detect signs of biventricular diastolic dysfunction and RV systolic dysfunction and consequently can offer added value to the conventional echocardiography to early detect the presence of subclinical myocardial function impairment in these fetuses.

POSTNATAL EVALUATION

Natal and postnatal ECG

IDMs are less able to respond physiologically to the stress of labour. On foetal ECG, they are more likely to demonstrate ST depression than infants of healthy mothers. Transient disturbances in glucose metabolism and electrolytes may result in quantifiable ECG changes. The postnatal hyperinsulinemia may induce hypoglycaemia and hypokalaemia, and consequently transient ECG changes that usually correct shortly. ECG may also show sinus tachycardia, long QTc, QT dispersion, changes in heart rate variability, a significant leftward shift of electrical axis, ST-T changes, and manifestations of left or biventricular hypertrophy[52,53]. The presence of elevated QT and QTc dispersions represents a high risk to develop arrhythmias in IDMs[54]. These initial ECG abnormalities observed in IDM usually disappear by six weeks of age if there is no associated CHD; a time coincides with the improvement of LV hypertrophy and correction of the metabolic derangements[55].

Postnatal echocardiography

Every IDM should have an echocardiographic examination in the first 1-2 d of life, when possible, to assess the cardiac function and the possible presence of structural malformations[56]. HCM is present in about 30% of IDMs. It is usually characterized by significant disproportionate hypertrophy, stiffness, and thickening of the interventricular septum and/or ventricular free walls with impaired relaxation and powerful but in-coordinate contraction. The impaired relaxation produces a reduction in the size of the ventricular chambers, causing transient hypertrophic subaortic stenosis with both systolic and diastolic dysfunction. Aortic outflow obstruction is aggravated by the anterior systolic motion of the mitral valve. Birth weight is the best predictor of hypertrophied IVS, especially in infants born to suboptimally controlled diabetic mothers. This condition may be asymptomatic but may present with respiratory distress, cardiomegaly, signs of poor cardiac output or even frank heart failure in about 5%-10% of cases[57]. Cardiac hypertrophy is best detected by 2-D and M-mode echocardiography (Figure 2, 3). Echocardiography shows hypertrophy of the ventricular septum, the right anterior wall, and LV posterior wall. The diabetic cardiomyopathy is benign, transient, and return gradually to normal size in the first months after birth compared to the infant of a non-diabetic mother, where HCM is usually progressive and associated with an awful prognosis. It usually resolves with the normalization of plasma insulin levels. The affected infants usually recover within 2 to 3 wk of supportive care, and echocardiographic findings show normalization within 6-12 mo[58]. The postnatal echocardiography can also evaluate the pulmonary pressure to rule out persistent foetal circulation, persistent ductus arteriosus, and other CHDs. The closure of ductus arteriosus and the postnatal decrease in pulmonary artery pressure are delayed in IDMs compared with infants of healthy mothers during the first days of life. The conotruncal abnormalities are the most common observed complex lesions in gestational DM, including transposition of the great arteries (TGA), tricuspid atresia (TvAtr), and truncus arteriosus (TA). Specifically, the frequency of TGA in live-born babies of mothers with pre-existing diabetes is 17 times more than in the average population[59]. Many of these cardiac defects present with respiratory distress. This finding is the reason that any IDM who also has respiratory distress must have an echocardiogram because CHF can result from obstructive or non-

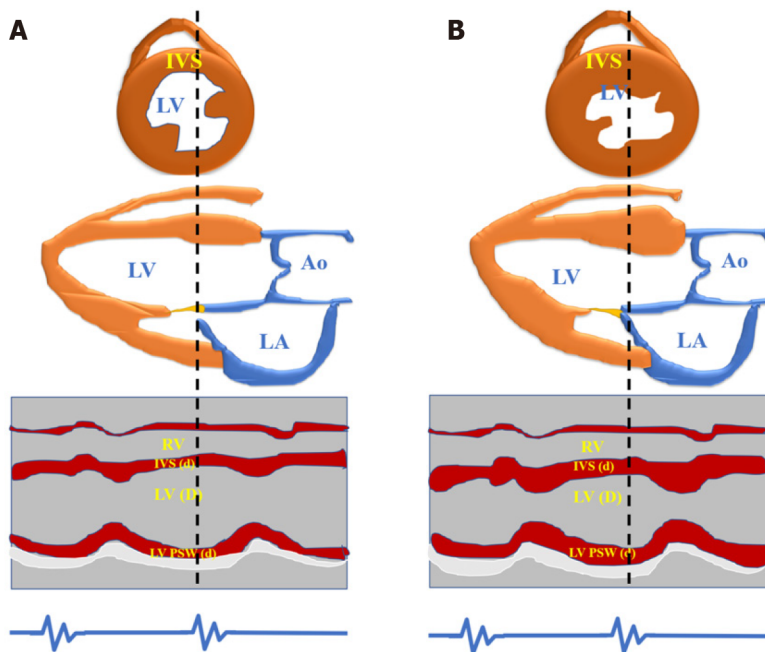


Figure 2 Diagrammatic representation of normal heart (A) and heart with left ventricular hypertrophy, anatomical, 2-D, and M-mode (B). IVS: Interventricular septum; LA: Left atrium; LV: Left ventricle; LV (D): Left ventricular diameter; LV PSW: Left ventricular posterior wall.

obstructive cardiomyopathy or other CHDs[60]. Impairment of the cardiac function can present even in the absence of structural changes. Al-Biltagi *et al*[1] found a significant deterioration of both systolic and diastolic functions measured by conventional echocardiography and TDI in IDMs with both pre-gestational and gestational diabetes. They also found significant impairment of the cardiac torsion using STE in these infants.

Aortic intima-media thickness

Atherosclerosis is a chronic progressive process. It starts from the arterial wall and proceeds to obstruct the lumen. In gestational diabetes, hyperstimulation of adipose tissue and the placental cells increases inflammatory cytokines production, which induces changes in the exposed tissues and endothelial cells. These changes initiate the early development of atherosclerotic changes even during the neonatal period[61]. Assessment of intima-media thickness (IMT) by B-mode ultrasonography helps detect early atherosclerotic changes in the blood vessels. Carotid arteries and aorta are preferable sites to detect these atherosclerotic changes. However, evaluation of the carotid arteries IMT is challenging and not accessible in neonates. Alternatively, aortic IMT is a more feasible and sensitive indicator for early atherosclerosis than carotid IMT in neonates[62]. Koklu *et al*[62] found that macrosomia is associated with increased lipid concentrations. These macrosomic IDMs have a significant higher aortic IMT with lipid alterations, findings that could be related to the development of the atherosclerotic process[63].

Meanwhile, Akcakus *et al*[63] found that macrosomic IDMs have a significantly higher aortic IMT and LV mass indexed for body surface area and birth weight with lipid alterations, which might play a role in the pathogenesis of atherosclerosis in adult life[64]. However, Atabek *et al*[64] found no differences in carotid IMT between IDM and infants of the healthy mothers indicating that the macrosomic IDMs are prone to HCM but not to atherosclerotic changes in the blood vessels. However, we must consider the small number involved in the study, the difficulty in measuring the carotid IMT in the neonate, the need for a linear probe, and that atherosclerotic lesions usually start in the abdominal aorta before the carotid arteries during the interpretation of their results[65]. Consequently, the aortic IMT is considered more superior to carotid IMT in subjects with a high risk for diabetes and hyperlipidaemia. However, due to the limited number of studies in IDMs, we still need more information about the standard and pathological range of aortic IMT in neonates. Nevertheless, the aortic IMT has excellent promise as a non-invasive, relatively inexpensive, reproducible tool to quantify cardiovascular risk in infants. It is also essential to study if the increase in aortic IMT measurements in IDMs persists into

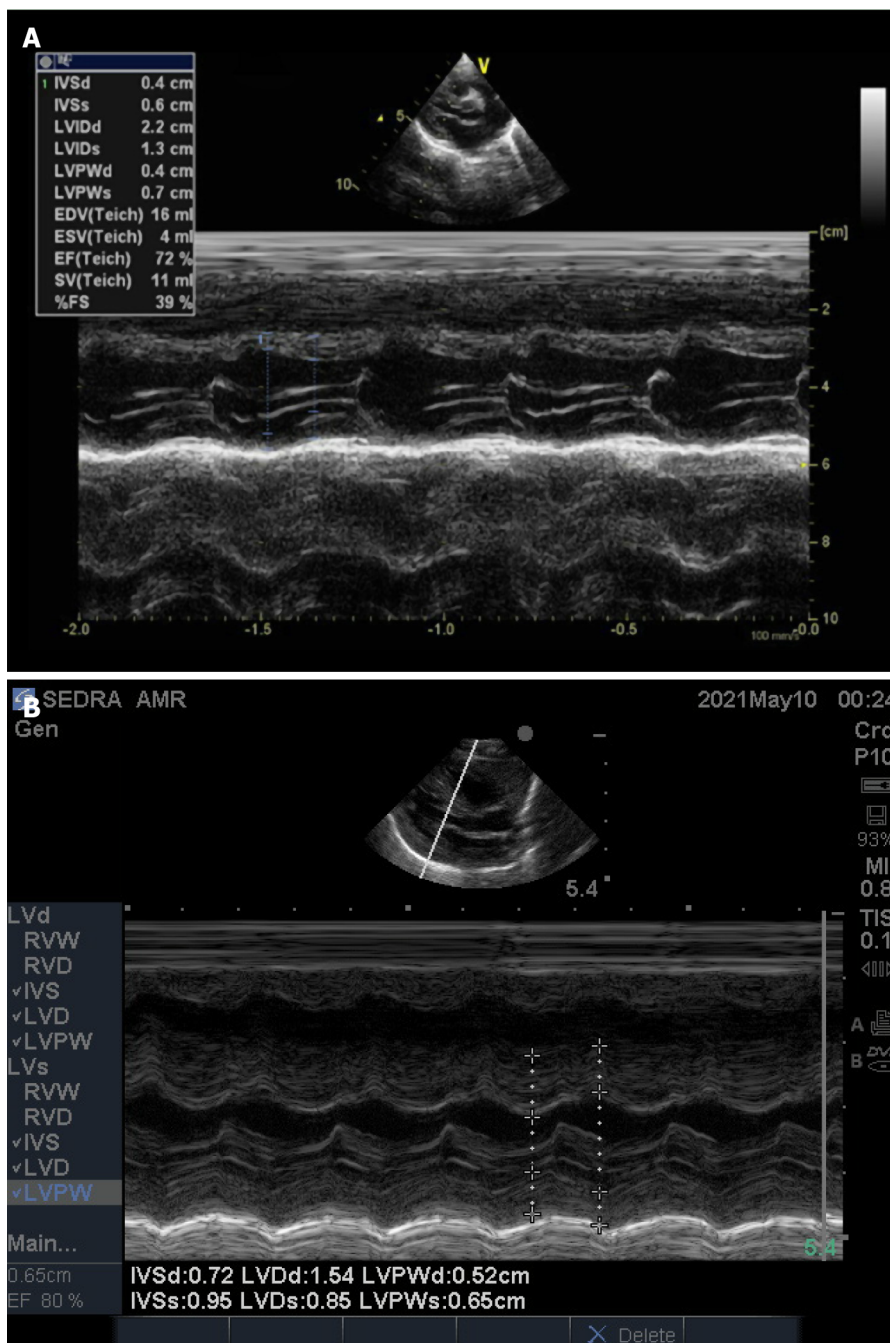


Figure 3 The figure showed normal 2-D and M-mode from a normal infant (A) and showed septal hypertrophy in an infant of a diabetic mother (B).

childhood and adulthood or whether postnatal influences attenuate these findings over time[66].

Retinal photography

It is always said, “The eye is the window of the body”; consequently, the retinal changes may reflect preclinical changes in the coronary and cerebral microcirculation. This finding explains why retinal photography is an additional hopeful option to evaluate the vasculature of IDMs during the neonatal period. It is already used in many countries to image the neonatal retina, especially in premature infants who frequently require routine screening for retinopathy of prematurity (ROP). Consequently, many centres use digital retinal photography as part of this screening process [65]. Opara *et al*[67] found that maternal diabetes was associated with a higher incidence of ROP. The strength of association increased with the increasing severity of ROP in preterm neonates less than 1500 mg. This association could be related to many factors linked to prematurity rather than vascular complications. However, there are

few studies concerning the early detection of atherosclerotic changes in IDMs using retinal photography. As retinal vessel photography is a validated research tool, it may be an ideal investigation to apply to IDMs in the neonatal period to assess their cardiovascular risk further. Potential drawbacks include infant discomfort and lack of access to specialized equipment and operators to produce images of sufficient quality to allow robust analyses of retinal vessels[68].

AMELIORATING THE EFFECTS OF DIABETES DURING PREGNANCY ON THE OFFSPRING

The best way to ameliorate the effect of gestational diabetes on the offspring is to prevent the development of diabetes itself. If not possible, we must strictly control the disease during pregnancy, aiming to achieve adequate glycaemic control and avoid harming the future offspring. Prevention of gestational diabetes could be attained through pre-pregnancy prevention of obesity, weight management, increased physical activity, and good nutritional strategies. The role of antenatal dietary supplementation with Myo-inositol (a derivative of secondary messengers involved in several signalling pathways, including the insulin pathway) in the prevention of gestational diabetes still unclear and needs more studies[69]. Although probiotics have a potentially beneficial role in glucose metabolism outside pregnancy, their role in preventing gestational diabetes is debatable. There is no firm evidence supporting the use of probiotics for the prevention of gestational DM[70]. Higher levels of physical activity both before and during early pregnancy seem to protect against the development of gestational diabetes[71]. Observational studies conducted in large population-based cohorts suggest that women who are the most active before pregnancy are less likely to have insulin-resistant in late pregnancy and have lower rates of gestational diabetes[72].

Optimizing screening for gestational diabetes in pregnant mothers by strictly following International Association of Diabetes and Pregnancy Study Groups (IADPSG) guidelines and recommendations on the diagnosis and classification of hyperglycaemia in pregnancy will significantly increase the number of women who are diagnosed with and treated for gestational DM[73]. Diagnosing and treating gestational diabetes can reduce perinatal complications, especially cardiovascular complication closely linked to strict glycaemic control. Nutritional management is the cornerstone of treatment. We can use Insulin, glyburide, and metformin to intensify the nutritional treatment. Since metformin has anti-cell growth and pro-apoptotic effects, there are persistent concerns over its use in early pregnancy. However, metformin may be chosen in selected cases, depending on the convenience and the cost[74]. Diet should ensure sufficient intake of micronutrients and macronutrients, including > 175 g of carbohydrates daily and minimizing the glycaemic excursions by intake of low- glycaemic-index carbohydrates and high fibres divided over several meals and snacks daily[75]. Foetal measurements support maternal glucose measurements in identifying pregnancies that need more intensification with a target to keep the fasting blood glucose ≤ 5.3 mmol/L, 1-h post-meal ≤ 7.8 mmol/L and 2-h post-meal 6.7 mmol/L[76].

After delivery, encouragement of breastfeeding can modify the risk in the IDMs. Breastfeeding has “dose-response” effects in reducing hypertension, insulin resistance, type 2 diabetes, dyslipidaemia, and obesity in IDMs. The beneficial effects of breastfeeding are mediated through the bioactive nutrients present only in the breast milk, the higher protein content, and the slower postnatal growth pattern compared to formula-fed infants. In addition, breastfeeding for six months or longer is associated with a significantly lower BMI, waist circumference, and visceral and subcutaneous adipose tissue at 6–13 years of age[77,78].

CONCLUSION

Gestational diabetes is a significant risk factor for CHDs. The risk increases in the presence of low maternal education, high BMI at conception, undiagnosed pregestational diabetes, inadequate antenatal care, improper diabetes control, and maternal smoking during pregnancy. Maternal DM significantly affects the foetal heart and foetal-placental circulation in both structure and function. CHDs, as well as myocardial hypertrophy, are three times more common in IDMs. Evaluation of the foetal cardiac structure and function can be performed using foetal electrocardio-

graphy and echocardiography. Postnatal cardiac evaluation can be performed by natal and postnatal electrocardiography, postnatal echocardiography, measuring aortic IMT, and retinal photography. Ameliorating the effects of gestational diabetes on the offspring depends mainly on pregestational and gestational diabetes prevention. However, other measures to reduce these effects, such as nutritional interventions, medications or probiotics, require more research.

REFERENCES

- 1 **Al-Biltagi M**, Tolba OA, Rowisha MA, Mahfouz Ael-S, Elewa MA. Speckle tracking and myocardial tissue imaging in infant of diabetic mother with gestational and pregestational diabetes. *Pediatr Cardiol* 2015; **36**: 445-453 [PMID: [25287219](#) DOI: [10.1007/s00246-014-1033-0](#)]
- 2 **McIntyre HD**, Catalano P, Zhang C, Desoye G, Mathiesen ER, Damm P. Gestational diabetes mellitus. *Nat Rev Dis Primers* 2019; **5**: 47 [PMID: [31296866](#) DOI: [10.1038/s41572-019-0098-8](#)]
- 3 **Catalano PM**, Tyzbir ED, Wolfe RR, Roman NM, Amini SB, Sims EA. Longitudinal changes in basal hepatic glucose production and suppression during insulin infusion in normal pregnant women. *Am J Obstet Gynecol* 1992; **167**: 913-919 [PMID: [1415425](#) DOI: [10.1016/s0002-9378\(12\)80011-1](#)]
- 4 **Catalano PM**, Tyzbir ED, Roman NM, Amini SB, Sims EA. Longitudinal changes in insulin release and insulin resistance in nonobese pregnant women. *Am J Obstet Gynecol* 1991; **165**: 1667-1672 [PMID: [1750458](#) DOI: [10.1016/0002-9378\(91\)90012-g](#)]
- 5 **Plows JF**, Stanley JL, Baker PN, Reynolds CM, Vickers MH. The Pathophysiology of Gestational Diabetes Mellitus. *Int J Mol Sci* 2018; **19** [PMID: [30373146](#) DOI: [10.3390/ijms19113342](#)]
- 6 **Kumar SD**, Dheen ST, Tay SS. Maternal diabetes induces congenital heart defects in mice by altering the expression of genes involved in cardiovascular development. *Cardiovasc Diabetol* 2007; **6**: 34 [PMID: [17967198](#) DOI: [10.1186/1475-2840-6-34](#)]
- 7 **Helle E**, Priest JR. Maternal Obesity and Diabetes Mellitus as Risk Factors for Congenital Heart Disease in the Offspring. *J Am Heart Assoc* 2020; **9**: e011541 [PMID: [32308111](#) DOI: [10.1161/JAHA.119.011541](#)]
- 8 **Corrigan N**, Brazil DP, McAuliffe F. Fetal cardiac effects of maternal hyperglycemia during pregnancy. *Birth Defects Res A Clin Mol Teratol* 2009; **85**: 523-530 [PMID: [19180650](#) DOI: [10.1002/bdra.20567](#)]
- 9 **Boucher J**, Kleinridders A, Kahn CR. Insulin receptor signaling in normal and insulin-resistant states. *Cold Spring Harb Perspect Biol* 2014; **6** [PMID: [24384568](#) DOI: [10.1101/cshperspect.a009191](#)]
- 10 **Radaelli T**, Varastehpour A, Catalano P, Hauguel-de Mouzon S. Gestational diabetes induces placental genes for chronic stress and inflammatory pathways. *Diabetes* 2003; **52**: 2951-2958 [PMID: [14633856](#) DOI: [10.2337/diabetes.52.12.2951](#)]
- 11 **Zhao Z**, Reece EA. New concepts in diabetic embryopathy. *Clin Lab Med* 2013; **33**: 207-233 [PMID: [23702113](#) DOI: [10.1016/j.cll.2013.03.017](#)]
- 12 **Lisowski LA**, Verheijen PM, De Smedt MM, Visser GH, Meijboom EJ. Altered fetal circulation in type-1 diabetic pregnancies. *Ultrasound Obstet Gynecol* 2003; **21**: 365-369 [PMID: [12704745](#) DOI: [10.1002/uog.88](#)]
- 13 **Schwartz R**, Gruppiso PA, Petzold K, Brambilla D, Hiilesmaa V, Teramo KA. Hyperinsulinemia and macrosomia in the fetus of the diabetic mother. *Diabetes Care* 1994; **17**: 640-648 [PMID: [7924772](#) DOI: [10.2337/diacare.17.7.640](#)]
- 14 **Dolk H**, McCullough N, Callaghan S, Casey F, Craig B, Given J, Loane M, Lagan BM, Bunting B, Boyle B, Dabir T. Risk factors for congenital heart disease: The Baby Hearts Study, a population-based case-control study. *PLoS One* 2020; **15**: e0227908 [PMID: [32092068](#) DOI: [10.1371/journal.pone.0227908](#)]
- 15 **Oyen N**, Diaz LJ, Leirgul E, Boyd HA, Priest J, Mathiesen ER, Quertermous T, Wohlfahrt J, Melbye M. Prepregnancy Diabetes and Offspring Risk of Congenital Heart Disease: A Nationwide Cohort Study. *Circulation* 2016; **133**: 2243-2253 [PMID: [27166384](#) DOI: [10.1161/CIRCULATIONAHA.115.017465](#)]
- 16 **Hunter LE**, Sharland GK. Maternal Gestational Diabetes and Fetal Congenital Heart Disease: An Observational Study. *J Preg Child Health* 2015; **2**: 132 [DOI: [10.4172/2376-127X.1000132](#)]
- 17 **Todorova K**, Mazneikova V, Ivanov S, Genova M. [The frequency of mild and severe fetal malformations in diabetic women with high values of glycosilated hemoglobin in early pregnancy]. *Akush Ginekol (Sofia)* 2005; **44**: 3-10 [PMID: [16028383](#)]
- 18 **Lisowski LA**, Verheijen PM, Copel JA, Kleinman CS, Wassink S, Visser GH, Meijboom EJ. Congenital heart disease in pregnancies complicated by maternal diabetes mellitus. An international clinical collaboration, literature review, and meta-analysis. *Herz* 2010; **35**: 19-26 [PMID: [20140785](#) DOI: [10.1007/s00059-010-3244-3](#)]
- 19 **Borsari L**, Malagoli C, Werler MM, Rothman KJ, Malavolti M, Rodolfi R, De Girolamo G, Nicolini F, Vinceti M. Joint Effect of Maternal Tobacco Smoking and Pregestational Diabetes on Preterm Births and Congenital Anomalies: A Population-Based Study in Northern Italy. *J Diabetes Res* 2018; **2018**: 2782741 [PMID: [30050951](#) DOI: [10.1155/2018/2782741](#)]
- 20 **Zhao Z**. Reevaluation of Antioxidative Strategies for Birth Defect Prevention in Diabetic Pregnancies. *J Biomol Res Ther* 2016; **5** [PMID: [28824831](#) DOI: [10.4172/2167-7956.1000145](#)]

- 21 **Basu M**, Garg V. Maternal hyperglycemia and fetal cardiac development: Clinical impact and underlying mechanisms. *Birth Defects Res* 2018; **110**: 1504-1516 [PMID: [30576094](#) DOI: [10.1002/bdr2.1435](#)]
- 22 **Al-Biltagi M**. Cardiovascular effects of diabetes mellitus in pediatric population. In: Research on Diabetes II. iConcept Press, Hong Kong, 2014
- 23 **Yu Y**, Arah OA, Liew Z, Cnattingius S, Olsen J, Sørensen HT, Qin G, Li J. Maternal diabetes during pregnancy and early onset of cardiovascular disease in offspring: population based cohort study with 40 years of follow-up. *BMJ* 2019; **367**: l6398 [PMID: [31801789](#) DOI: [10.1136/bmj.l6398](#)]
- 24 **Jarmuzek P**, Wielgos M, Bomba-Opon D. Placental pathologic changes in gestational diabetes mellitus. *Neuro Endocrinol Lett* 2015; **36**: 101-105 [PMID: [26071574](#)]
- 25 **Natarajan L**, Maheswari GU. Gestational hyperglycemia on diet and medication: impact on placental pathology and pregnancy outcomes. *Int J Reprod Contracept Obstet Gynecol* 2019; **8**: 3350-3356 [DOI: [10.18203/2320-1770.ijrcog20193564](#)]
- 26 **Lateef RH**. Adverse Effects of Gestational Diabetes Mellitus (GDM) on Measurements of the Umbilical Cord and its Vessels. *Pak J Biol Sci* 2015; **18**: 346-351
- 27 **Kitzmiller JL**. Sweet success with diabetes. The development of insulin therapy and glycemic control for pregnancy. *Diabetes Care* 1993; **16** Suppl 3: 107-121 [PMID: [8299468](#) DOI: [10.2337/diacare.16.3.107](#)]
- 28 **Fehlert E**, Willmann K, Fritsche L, Linder K, Mat-Husin H, Schleger F, Weiss M, Kiefer-Schmidt I, Brucker S, Häring HU, Preissl H, Fritsche A. Gestational diabetes alters the fetal heart rate variability during an oral glucose tolerance test: a fetal magnetocardiography study. *BJOG* 2017; **124**: 1891-1898 [PMID: [28029217](#) DOI: [10.1111/1471-0528.14474](#)]
- 29 **Pabis JS**, Schneider L, Stoll LF, Simoes MA. Heart changes in a fetus of a diabetic mother. *Trends Diabetes Metab* 2019; **2** [DOI: [10.15761/TDM.1000108](#)]
- 30 **Sardesai MG**, Gray AA, McGrath MM, Ford SE. Fetal hypertrophic cardiomyopathy in the fetus of a woman with diabetes. *Obstet Gynecol* 2001; **98**: 925-927 [PMID: [11704206](#) DOI: [10.1016/s0029-7844\(01\)01455-7](#)]
- 31 **Narchi H**, Kulaylat N. Heart disease in infants of diabetic mothers. *Images Paediatr Cardiol* 2000; **2**: 17-23 [PMID: [22368579](#)]
- 32 **Nold JL**, Georgieff MK. Infants of diabetic mothers. *Pediatr Clin North Am* 2004; **51**: 619-637, viii [PMID: [15157588](#) DOI: [10.1016/j.pcl.2004.01.003](#)]
- 33 **Wren C**, Birrell G, Hawthorne G. Cardiovascular malformations in infants of diabetic mothers. *Heart* 2003; **89**: 1217-1220 [PMID: [12975424](#) DOI: [10.1136/heart.89.10.1217](#)]
- 34 **Tabib A**, Shirzad N, Sheikhabaei S, Mohammadi S, Qorbani M, Haghpahan V, Abbasi F, Hasani-Ranjbar S, Baghaei-Tehrani R. Cardiac malformations in fetuses of gestational and pre gestational diabetic mothers. *Iran J Pediatr* 2013; **23**: 664-668 [PMID: [24910745](#)]
- 35 **Hugill K**, Meredith D. The road to life. Neonatal transitions to extra-uterine life. *Pract Midwife* 2016; **20**: 10-10-12-13 [PMID: [30462465](#)]
- 36 **Schierz IAM**, Pinello G, Piro E, Giuffrè M, La Placa S, Corsello G. Transitional hemodynamics in infants of diabetic mothers by targeted neonatal echocardiography, electrocardiography and peripheral flow study. *J Matern Fetal Neonatal Med* 2018; **31**: 1578-1585 [PMID: [28412852](#) DOI: [10.1080/14767058.2017.1320544](#)]
- 37 **Dunn V**, Nixon GW, Jaffe RB, Condon VR. Infants of diabetic mothers: radiographic manifestations. *AJR Am J Roentgenol* 1981; **137**: 123-128 [PMID: [6787862](#) DOI: [10.2214/ajr.137.1.123](#)]
- 38 **Katheria A**, Leone T. Altered transitional circulation in infants of diabetic mothers with strict antenatal obstetric management: a functional echocardiography study. *J Perinatol* 2012; **32**: 508-513 [PMID: [21960130](#) DOI: [10.1038/jp.2011.135](#)]
- 39 **Freyschuss U**, Gentz J, Noack G, Persson B. Circulatory adaptation in newborn infants of strictly controlled diabetic mothers. *Acta Paediatr Scand* 1982; **71**: 209-215 [PMID: [7136629](#) DOI: [10.1111/j.1651-2227.1982.tb09401.x](#)]
- 40 **Akbariasbagh P**, Shariat M, Akbariasbagh N, Ebrahim B. Cardiovascular Malformations in Infants of Diabetic Mothers: A Retrospective Case-Control Study. *Acta Med Iran* 2017; **55**: 103-108 [PMID: [28282706](#) DOI: [10.18203/2349-3291.ijcp20193712](#)]
- 41 **Yli BM**, Källén K, Khoury J, Stray-Pedersen B, Amer-Wählin I. Intrapartum cardiotocography (CTG) and ST-analysis of labor in diabetic patients. *J Perinat Med* 2011; **39**: 457-465 [PMID: [21604995](#) DOI: [10.1515/jpm.2011.046](#)]
- 42 **Yli BM**, Källén K, Stray-Pedersen B, Amer-Wählin I. Intrapartum fetal ECG and diabetes. *J Matern Fetal Neonatal Med* 2008; **21**: 231-238 [PMID: [18330818](#) DOI: [10.1080/14767050801924431](#)]
- 43 **Al-Biltagi MA**. Echocardiography in children with Down syndrome. *World J Clin Pediatr* 2013; **2**: 36-45 [PMID: [25254173](#) DOI: [10.5409/wjcp.v2.i4.36](#)]
- 44 **Narayanan M**, Elkayam U, Naqvi TZ. Echocardiography in Pregnancy: Part 2. *Curr Cardiol Rep* 2016; **18**: 90 [PMID: [27457084](#) DOI: [10.1007/s11886-016-0761-6](#)]
- 45 **Raafat, M.**, Aborizk, S., Saraya, M, Soliman HH. Role of fetal echocardiography in morphologic and functional assessment of fetal heart in diabetic mothers. *Egypt J Radiol Nucl Med* 2020; **51**: 84 [DOI: [10.1186/s43055-020-00207-0](#)]
- 46 **Aydin S**, Fatihoglu E. Fetal Epicardial Fat Thickness: Can It Serve as a Sonographic Screening Marker for Gestational Diabetes Mellitus? *J Med Ultrasound* 2020; **28**: 239-244 [PMID: [33659164](#) DOI: [10.4103/JMU.JMU_29_20](#)]
- 47 **Gilbert-Barness E**. Review: Metabolic cardiomyopathy and conduction system defects in children.

- Ann Clin Lab Sci* 2004; **34**: 15-34 [PMID: [15038665](#)]
- 48 **Fouda UM**, Abou ElKassem MM, Hefny SM, Fouda RM, Hashem AT. Role of fetal echocardiography in the evaluation of structure and function of fetal heart in diabetic pregnancies. *J Matern Fetal Neonatal Med* 2013; **26**: 571-575 [PMID: [23176302](#) DOI: [10.3109/14767058.2012.743521](#)]
 - 49 **Krautzig A**, Christoph J, Kattner E. [Heart failure caused by myocardial hypertrophy in diabetic fetopathy]. *Z Geburtshilfe Neonatol* 1999; **203**: 221-224 [PMID: [10596417](#)]
 - 50 **Bayoumy S**, Habib M, Abdelmageed R. Impact of maternal diabetes and obesity on fetal cardiac functions. *Egypt Heart J* 2020; **72**: 46 [PMID: [32737616](#) DOI: [10.1186/s43044-020-00077-x](#)]
 - 51 **Miranda JO**, Cerqueira RJ, Ramalho C, Areias JC, Henriques-Coelho T. Fetal Cardiac Function in Maternal Diabetes: A Conventional and Speckle-Tracking Echocardiographic Study. *J Am Soc Echocardiogr* 2018; **31**: 333-341 [PMID: [29246511](#) DOI: [10.1016/j.echo.2017.11.007](#)]
 - 52 **Bacharova L**, Krivosikova Z, Wsolova L, Gajdos M. Alterations in the QRS complex in the offspring of patients with metabolic syndrome and diabetes mellitus: early evidence of cardiovascular pathology. *J Electrocardiol* 2012; **45**: 244-251 [PMID: [22520960](#) DOI: [10.1016/j.jelectrocard.2012.02.004](#)]
 - 53 **Stern S**, Sclarowsky S. The ECG in diabetes mellitus. *Circulation* 2009; **120**: 1633-1636 [PMID: [19841309](#) DOI: [10.1161/CIRCULATIONAHA.109.897496](#)]
 - 54 **Arslan D**, Guvenc O, Cimen D, Ulu H, Oran B. Prolonged QT dispersion in the infants of diabetic mothers. *Pediatr Cardiol* 2014; **35**: 1052-1056 [PMID: [24740627](#) DOI: [10.1007/s00246-014-0897-3](#)]
 - 55 **Norton J**, Evans B, Sweeney M. Electrocardiographic changes in infants of diabetic mothers. *Pediatr Res* 1974; **8**: 353 [DOI: [10.1203/00006450-197404000-00078](#)]
 - 56 **Bogo MA**, Pabis JS, Bonchoski AB, Santos DCD, Pinto TJF, Simões MA, Silva JC, Pabis FC. Cardiomyopathy and cardiac function in fetuses and newborns of diabetic mothers. *J Pediatr (Rio J)* 2020 [PMID: [33176166](#) DOI: [10.1016/j.jpmed.2020.10.003](#)]
 - 57 **El-Ganzoury MM**, El-Masry SA, El-Farrash RA, Anwar M, Abd Ellatife RZ. Infants of diabetic mothers: echocardiographic measurements and cord blood IGF-I and IGFBP-1. *Pediatr Diabetes* 2012; **13**: 189-196 [PMID: [21933314](#) DOI: [10.1111/j.1399-5448.2011.00811.x](#)]
 - 58 **Sharma D**, Pandita A, Shastri S, Sharma P. Asymmetrical septal hypertrophy and hypertrophic cardiomyopathy in infant of diabetic mother: A reversible cardiomyopathy. *Med J DY Patil Univ* 2016; **9**: 257-60 [DOI: [10.4103/0975-2870.177679](#)]
 - 59 **Petropoulos AC**, Xudiyeva A, Ismaylova M. Congenital Heart Disease and Maternal Diabetes Mellitus. *Clin Diagn* 2016; **3**: 118 [DOI: [10.15344/2394-1499/2016/118](#)]
 - 60 **Deorari AK**, Saxena A, Singh M, Shrivastava S. Echocardiographic assessment of infants born to diabetic mothers. *Arch Dis Child* 1989; **64**: 721-724 [PMID: [2730127](#) DOI: [10.1136/adc.64.5.721](#)]
 - 61 **López Morales CM**, Brito Zurita OR, González Heredia R, Cruz López M, Méndez Padrón A, Matute Briseño JA. [Placental atherosclerosis and markers of endothelial dysfunction in infants born to mothers with gestational diabetes]. *Med Clin (Barc)* 2016; **147**: 95-100 [PMID: [27242015](#) DOI: [10.1016/j.medcli.2016.03.031](#)]
 - 62 **Koklu E**, Kurtoglu S, Akcakus M, Koklu S, Buyukkayhan D, Gumus H, Yikilmaz A. Increased aortic intima-media thickness is related to lipid profile in newborns with intrauterine growth restriction. *Horm Res* 2006; **65**: 269-275 [PMID: [16601348](#) DOI: [10.1159/000092536](#)]
 - 63 **Akcakus M**, Koklu E, Baykan A, Yikilmaz A, Coskun A, Gunes T, Kurtoglu S, Narin N. Macrosomic newborns of diabetic mothers are associated with increased aortic intima-media thickness and lipid concentrations. *Horm Res* 2007; **67**: 277-283 [PMID: [17191031](#) DOI: [10.1159/000098157](#)]
 - 64 **Atabek ME**, Çağan HH, Selver Eklioğlu B, Oran B. Absence of increase in carotid artery intima-media thickness in infants of diabetic mothers. *J Clin Res Pediatr Endocrinol* 2011; **3**: 144-148 [PMID: [21911328](#) DOI: [10.4274/jcrpe.v3i3.28](#)]
 - 65 **Marco LJ**, McCloskey K, Vuillermin PJ, Burgner D, Said J, Ponsonby AL. Cardiovascular disease risk in the offspring of diabetic women: the impact of the intrauterine environment. *Exp Diabetes Res* 2012; **2012**: 565160 [PMID: [23133443](#) DOI: [10.1155/2012/565160](#)]
 - 66 **Skilton MR**, Celermajer DS, Cosmi E, Crispi F, Gidding SS, Raitakari OT, Urbina EM. Natural History of Atherosclerosis and Abdominal Aortic Intima-Media Thickness: Rationale, Evidence, and Best Practice for Detection of Atherosclerosis in the Young. *J Clin Med* 2019; **8** [PMID: [31408952](#) DOI: [10.3390/jcm8081201](#)]
 - 67 **Opara CN**, Akintorin M, Byrd A, Cirignani N, Akintorin S, Soyemi K. Maternal diabetes mellitus as an independent risk factor for clinically significant retinopathy of prematurity severity in neonates less than 1500g. *PLoS One* 2020; **15**: e0236639 [PMID: [32745146](#) DOI: [10.1371/journal.pone.0236639](#)]
 - 68 **Dhaliwal CA**, Wright E, McIntosh N, Dhaliwal K, Fleck BW. Pain in neonates during screening for retinopathy of prematurity using binocular indirect ophthalmoscopy and wide-field digital retinal imaging: a randomised comparison. *Arch Dis Child Fetal Neonatal Ed* 2010; **95**: F146-F148 [PMID: [19815939](#) DOI: [10.1136/adc.2009.168971](#)]
 - 69 **Celentano C**, Matarrelli B, Mattei PA, Pavone G, Vitacolonna E, Liberati M. Myo-Inositol Supplementation to Prevent Gestational Diabetes Mellitus. *Curr Diab Rep* 2016; **16**: 30 [PMID: [26898405](#) DOI: [10.1007/s11892-016-0726-6](#)]
 - 70 **Callaway LK**, McIntyre HD, Barrett HL, Foxcroft K, Tremellen A, Lingwood BE, Tobin JM, Wilkinson S, Kothari A, Morrison M, O'Rourke P, Pelecanos A, Dekker Nitert M. Probiotics for the Prevention of Gestational Diabetes Mellitus in Overweight and Obese Women: Findings From the

- SPRING Double-Blind Randomized Controlled Trial. *Diabetes Care* 2019; **42**: 364-371 [PMID: 30659070 DOI: 10.2337/dc18-2248]
- 71 **Stewart A**, Malhotra A. Gestational diabetes and the neonate: challenges and solutions. *Res Rep Neonatol* 2015; **5**: 31-39 [DOI: 10.2147/RRN.S30971]
- 72 **Hopkins SA**, Artal R. The role of exercise in reducing the risks of gestational diabetes mellitus. *Womens Health (Lond)* 2013; **9**: 569-581 [PMID: 24161309 DOI: 10.2217/whe.13.52]
- 73 **International Association of Diabetes and Pregnancy Study Groups Consensus Panel**, Metzger BE, Gabbe SG, Persson B, Buchanan TA, Catalano PA, Damm P, Dyer AR, Leiva Ad, Hod M, Kitzmiller JL, Lowe LP, McIntyre HD, Oats JJ, Omori Y, Schmidt MI. International association of diabetes and pregnancy study groups recommendations on the diagnosis and classification of hyperglycemia in pregnancy. *Diabetes Care* 2010; **33**: 676-682 [PMID: 20190296 DOI: 10.2337/dc09-1848]
- 74 **Nguyen L**, Chan SY, Teo AKK. Metformin from mother to unborn child - Are there unwarranted effects? *EBioMedicine* 2018; **35**: 394-404 [PMID: 30166273 DOI: 10.1016/j.ebiom.2018.08.047]
- 75 **Rasmussen L**, Poulsen CW, Kampmann U, Smedegaard SB, Ovesen PG, Fuglsang J. Diet and Healthy Lifestyle in the Management of Gestational Diabetes Mellitus. *Nutrients* 2020; **12** [PMID: 33036170 DOI: 10.3390/nu12103050]
- 76 **Buchanan TA**, Xiang AH, Page KA. Gestational diabetes mellitus: risks and management during and after pregnancy. *Nat Rev Endocrinol* 2012; **8**: 639-649 [PMID: 22751341 DOI: 10.1038/nrendo.2012.96]
- 77 **Lanigan J**, Singhal A. Early nutrition and long-term health: a practical approach. *Proc Nutr Soc* 2009; **68**: 422-429 [PMID: 19698202 DOI: 10.1017/S002966510999019X]
- 78 **Crume TL**, Ogden L, Maligie M, Sheffield S, Bischoff KJ, McDuffie R, Daniels S, Hamman RF, Norris JM, Dabelea D. Long-term impact of neonatal breastfeeding on childhood adiposity and fat distribution among children exposed to diabetes in utero. *Diabetes Care* 2011; **34**: 641-645 [PMID: 21357361 DOI: 10.2337/dc10-1716]



Published by **Baishideng Publishing Group Inc**
7041 Koll Center Parkway, Suite 160, Pleasanton, CA 94566, USA

Telephone: +1-925-3991568

E-mail: bpgoffice@wjgnet.com

Help Desk: <https://www.f6publishing.com/helpdesk>

<https://www.wjgnet.com>

