

Actinic lichen planus: a presentation, deviant from the conventional

Anupama Ghosh, Anupam Das, Dhiraj Kumar, Ramesh Chandra Gharami

Anupama Ghosh, Anupam Das, Dhiraj Kumar, Ramesh Chandra Gharami, Department of Dermatology, Medical College and Hospital, Kolkata 700073, West Bengal, India

Author contributions: Ghosh A and Das A contributed equally to the diagnosis and work-up; all the authors wrote the article.

Correspondence to: Dr. Anupam Das, Department of Dermatology, Medical College and Hospital, Building-“Prerana”, 19, Phoolbagan, Kolkata 700073, West Bengal, India. anupamdasdr@gmail.com

Telephone: +91-94-33112113 Fax: +91-94-33112113

Received: October 10, 2013 Revised: November 14, 2013

Accepted: December 12, 2013

Published online: February 2, 2014

wjd.v3.i1.4

INTRODUCTION

Actinic lichen planus is a variant form of lichen planus located on light-exposed areas, occurring in children or young adults (dark skinned individuals) living in tropical countries. The presentation of the entity can be diverse and hereby, we report an interesting presentation.

CASE REPORT

A middle-aged lady presented to us with asymptomatic multiple red-brown papules and plaques over the face and nose for a duration of 2 years. The course of evolution of the lesion involved a mild burning sensation on sun-exposure 2 years back and 1-2 mo after that, she developed a few papules which gradually increased in number and some of them also coalesced to form small plaques (1.0-2.5 cm) which were erythematous to brownish in color with a history of summer exacerbation (Figure 1). No history of regular drug intake or similar lesions in the past or in the family. Scalp, oral and genital mucosa and nails were absolutely normal. Cosmetic concern prompted her to seek medical treatment. On the basis of the clinical presentation of the patient, we considered syringoma and mucinosis as a differential diagnosis and one of the lesions was subjected to biopsy for confirmation of our diagnosis.

To our utter surprise, on histopathological examination we found epidermal atrophy, basal cell layer degeneration, melanin incontinence and band-like infiltration of lymphocytes at the dermoepidermal junction, which clinched the diagnosis of a variety of actinic lichen planus (Figure 2). Photoprotection and an intramuscular injection of triamcinolone were advised. Marked improvement was seen after a single dose (Figure 3).

Abstract

Actinic lichen planus, a variant of lichen planus usually in people living in the tropics, presents as annular or discoid patches over the sun-exposed regions. We present here a case of actinic lichen planus with papules and plaques over the malar region and dorsum of nose - a rare presentation of this entity.

© 2014 Baishideng Publishing Group Co., Limited. All rights reserved.

Key words: Actinic; Lichen; Planus; Unusual; Presentation

Core tip: This is an interesting case of a young lady who presented with brown and erythematous papules and plaques. Clinically, no one thought of lichen planus in the differential diagnosis. It exemplifies the fact that a dermatological entity can be so diverse in its presentation and become a mystery for the clinician to diagnose.

Ghosh A, Das A, Kumar D, Gharami RC. Actinic lichen planus: a presentation, deviant from the conventional. *World J Dermatol* 2014; 3(1): 4-5 Available from: URL: <http://www.wjgnet.com/2218-6190/full/v3/i1/4.htm> DOI: <http://dx.doi.org/10.5314/wjd.v3.i1.4>

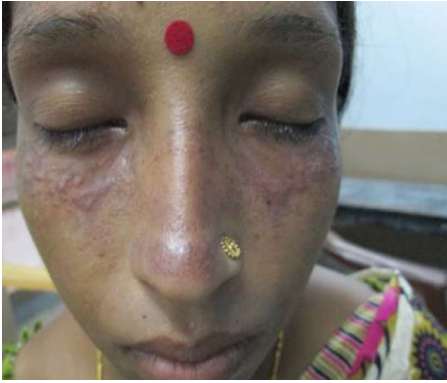

Figure 1 Multiple erythematous to brownish in color papules, coalescing to form plaques over the malar regions and nose.

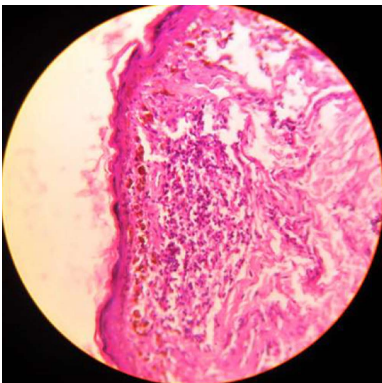


Figure 2 HPE showing epidermal atrophy, basal cell layer degeneration, pigment incontinence and band-like infiltration of lymphocytes at the dermoepidermal junction (HE, × 40).

DISCUSSION

Actinic lichen planus, also known as lichen planus subtropicus, lichenoid melanodermitis and lichen planus atrophicus annularis, mainly affects children and young adults of Middle-East, African or Indian origin. There are 3 clinical types: annular, pigmented and dyschromic^[1,2]. There is no sexual predilection and typical lesions are annular or discoid patches on sun exposed regions with a hyperpigmented center and a surrounding hypopigmented zone. Recurrent painful annular erythema on the face and hands in a 52 year old Japanese man have been reported, suggesting varied and atypical presentation of actinic lichen planus^[3]. It is treated with acitretin, topical corticosteroids^[4] and with cyclosporine^[5].

Uncommon morphology is the reason behind our purpose of reporting the case.

COMMENTS

Case characteristics

A middle-aged lady presented to us with asymptomatic multiple red-brown pap-

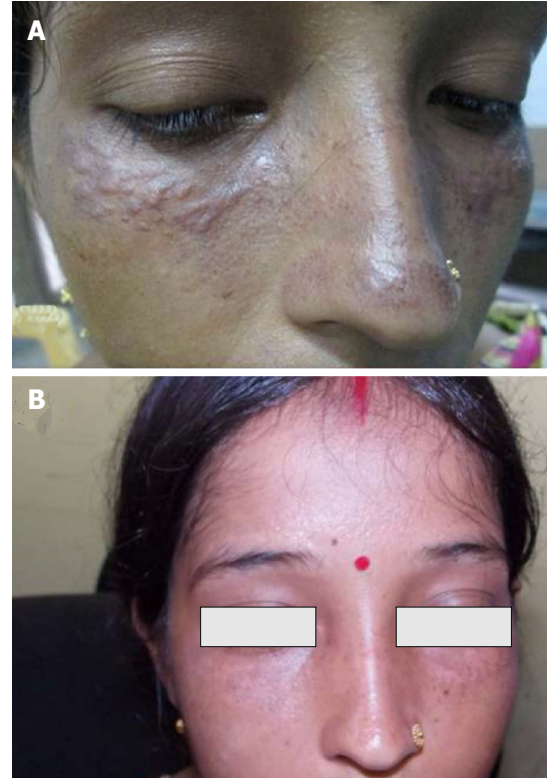

Figure 3 Showing pre-treatment photograph (A) and post-treatment photograph (B) following one intramuscular injection of triamcinolone.

ules and plaques over the face and nose for a duration of 2 years.

Clinical diagnosis

Syringoma and mucinosis.

Differential diagnosis

Syringoma, mucinosis, other deposition disorders, actinic lichen planus.

Peer review

This is an interesting case that has educative value.

REFERENCES

- 1 Denguezli M, Nouira R, Jomaa B. [Actinic lichen planus. An anatomoclinical study of 10 Tunisian cases]. *Ann Dermatol Venerol* 1994; **121**: 543-546 [PMID: 7755310]
- 2 Bouassida S, Boudaya S, Turki H, Gueriani H, Zahaf A. [Actinic lichen planus: 32 cases]. *Ann Dermatol Venerol* 1998; **125**: 408-413 [PMID: 9747296]
- 3 Dekio I, Matsuki S, Furumura M, Morita E, Morita A. Actinic lichen planus in a Japanese man: first case in the East Asian population. *Photodermatol Photoimmunol Photomed* 2010; **26**: 333-335 [PMID: 21140994 DOI: 10.1111/j.1600-0781.2010.00548.x]
- 4 Jansen T, Gambichler T, von Kobyletzki L, Altmeyer P. Lichen planus actinicus treated with acitretin and topical corticosteroids. *J Eur Acad Dermatol Venerol* 2002; **16**: 174-175 [PMID: 12046829 DOI: 10.1046/j.1468-3083.2002.00392_3.x]
- 5 Gallo L, Ayala F, Ayala F. Relapsing lichen actinicus successfully treated with cyclosporin. *J Eur Acad Dermatol Venerol* 2008; **22**: 370-371 [PMID: 18005120 DOI: 10.1111/j.1468-3083.2007.02325.x]

P- Reviewer: Chi CC S- Editor: Wen LL
L- Editor: Roemmele A E- Editor: Lu YJ





百世登
Baishideng®

Published by **Baishideng Publishing Group Co., Limited**

Flat C, 23/F., Lucky Plaza, 315-321 Lockhart Road,
Wanchai, Hong Kong, China

Fax: +852-31158812

Telephone: +852-58042046

E-mail: bpgoffice@wjgnet.com

<http://www.wjgnet.com>

