

Risk factors related to postoperative recurrence of dermatofibrosarcoma

[ALL](#) [IMAGES](#) [VIDEOS](#)

11,700 Results Any time ▾

Risk factors for distant metastasis of dermatofibrosarcoma ...

europepmc.org/articles/PMC4999380

Sept 01, 2016 - Introduction. **Dermatofibrosarcoma protuberans (DFSP)** is a tumor that develops in skin or subcutaneous tissue and is characterized by a protuberant growth pattern [1].DFSP often recurs locally after surgery, but rarely metastasizes to distant sites and is classified as a sarcoma of intermediate-grade malignancy [2-7]. DFSP sometimes appears with fibrosarcomatous transformation in a subset of ...

Cited by: 10 Author: Keiko Hayakawa, Seiichi Matsumoto, Kei...

Publish Year: 2016

Risk-stratified surveillance in dermatofibrosarcoma ...

<https://acsjournals.onlinelibrary.wiley.com/doi/full/10.1002/cnrc.31922>

This likely is driven by 2 main factors: margin status and the inclusion of patients with recurrent disease. First, although the majority of patients underwent R0 resection (65.5%), this was defined by the authors as clearance of a minimum of only 1 mm, with no further quantification provided.

Dermatofibrosarcoma
protuberans

Dermatofibrosarcoma protuberans is a rare locally aggressive malignant cutaneous soft tissue sarcoma. DFSP develops in the connective tissue cells in the middle layer of the skin. Estimates of the overall occurrence of DFSP in the United States are 0.8 to 4.5 cases per million persons per year. In the United States, DFSP accounts for between 1 and 6 percent of all soft tissue sarcomas and 18 percent of all cutaneous soft tissue sarcomas. In the Surveillance, Epidemiology and End Results tumor registry from 1992

国内版国际版

Microsoft Bing

Risk factors related to postoperative recurrence of dermatofibrosarc

Sign in

ALL

IMAGES

VIDEOS

Add the Gve with Bing extension >

54,200 Results

Any time ▾

Risk factors for distant metastasis of dermatofibrosarcoma ...

<https://link.springer.com/article/10.1007/s10195-016-0415-x>

Jun 11, 2016 - Dermatofibrosarcoma protuberans (DFSP) is a tumor that develops in skin or subcutaneous tissue and is characterized by a protuberant growth pattern []. DFSP often recurs locally after surgery, but rarely metastasizes to distant sites and is classified as a sarcoma of intermediate-grade malignancy [2-7]. DFSP sometimes appears with fibrosarcomatous transformation in a subset of ...

Cited by: 11 Author: Keiko Hayakawa, Seichi Matsumoto, Kei...

Publish Year: 2016 Estimated Reading Time: 8 mins

Risk factors for distant metastasis of dermatofibrosarcoma ...

europepmc.org/articles/PMC4999380

Sep 01, 2016 - Introduction. Dermatofibrosarcoma protuberans (DFSP) is a tumor that develops in skin or subcutaneous tissue and is characterized by a protuberant growth pattern []. DFSP often recurs locally after surgery, but rarely metastasizes to distant sites and is classified as a sarcoma of intermediate-grade malignancy [2-7]. DFSP sometimes appears with fibrosarcomatous transformation in a subset of ...

Cited by: 11 Author: Keiko Hayakawa, Seichi Matsumoto, Kei...

Publish Year: 2016

Rick-stratified surveillance in dermatofibrosarcoma

Search Tools

Turn off Hover Translation (关闭翻译)

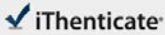
激活 Windows

转到“设置”以激活 Windows。

17-May-2021 08:35PM

4448 words • 7 matches • 4 sources

FAQ

iThenticate®

62563_Auto_Edited.docx

Quotes Excluded
Bibliography Excluded

3%
SIMILAR

9

Name of Journal: *World Journal of Clinical Cases*

Manuscript NO: 62563

Manuscript Type: ORIGINAL ARTICLE

Retrospective Study

Risk factors related to postoperative recurrence of dermatofibrosarcoma protuberans:
A retrospective research and literature review

postoperative recurrence of dermatofibrosarcoma protuberans

Jian-Xia Xiong, Tao Cai, Li Hu, Xiao-Li Chen, kun Huang, Ai-Jun Chen, Ping Wang

Match Overview

1

Internet 62 words
crawled on 07-Jul-2019
www.jcancer.org

1%

2

Crossref 26 words
Byung Jun Kim, Hyeonwoo Kim, Ung Sik Jin, Kyung Won Min, Haili Chang "Wide Local Excision for Dermatofibrosarcoma Protuberans: A Retrospective Study"

1%

3

Internet 18 words
crawled on 27-Oct-2020
<https://pubs.shing-blob.com/windows.net>

<1%

4

Internet 17 words
crawled on 17-Apr-2020
www.clinical-medicine.panafrican-med-journal.com

<1%

激活 Windows
转到“设置”以激活 Windows。

Page: 1 of 15

Text-Only Report

国内版 国际版

Risk factors related to postoperative recurrence of dermatofibrosarc



ALL IMAGES VIDEOS

54,000 Results

Any time ▾

[Risk factors for distant metastasis of dermatofibrosarcoma ...](#)

<https://link.springer.com/article/10.1007/s10195-016-0415-x> ▾

Jun 11, 2016 · Dermatofibrosarcoma protuberans (DFSP) is a tumor that develops in skin or subcutaneous tissue and is characterized by a protuberant growth pattern []. DFSP often recurs locally after surgery, but rarely metastasizes to distant sites and is classified as a sarcoma of intermediate-grade malignancy [2–7]. DFSP sometimes appears with fibrosarcomatous transformation in a subset of ...

Cited by: 11

Author: Keiko Hayakawa, Seiichi Matsumoto, Kei...

Publish Year: 2016

Estimated Reading Time: 8 mins

[Risk factors for distant metastasis of dermatofibrosarcoma ...](#)

europepmc.org/articles/PMC4999380

Sep 01, 2016 · Introduction. Dermatofibrosarcoma protuberans (DFSP) is a tumor that develops in skin or subcutaneous tissue and is characterized by a protuberant growth pattern []. DFSP often recurs locally after surgery, but rarely metastasizes to distant sites and is classified as a sarcoma of intermediate-grade malignancy [2–7]. DFSP sometimes appears with fibrosarcomatous transformation in a subset of ...

Cited by: 11

Author: Keiko Hayakawa, Seiichi Matsumoto, Kei...

Publish Year: 2016

[Risk-stratified surveillance in dermatofibrosarcoma ...](#)

<https://acsjournals.onlinelibrary.wiley.com/doi/full/10.1002/cncr.31922>

This likely is driven by 2 main factors: margin status and the inclusion of patients with recurrent disease. First, although the majority of patients underwent R0 resection (65.5%), this was defined by the authors as clearance of a minimum of only 1 mm, with no further quantification provided.

Cited by: 2

Author: Rebecca A. Gladdy, Rebecca A. Gladdy, ...

Publish Year: 2019

[Risk factors for distant metastasis of dermatofibrosarcoma ...](#)

<https://www.researchgate.net/publication/303918161...>

Dermatofibrosarcoma protuberans (DFSP) is a tumor of low malignant potential characterized by a high rate of local recurrence and a small, but definite, risk of metastasis. 14 A minority of cases ...

Estimated Reading Time: 4 mins