

Many intracranial dermoid cysts are asymptomatic and are found incidentally. Spontaneous, traumatic or iatrogenic rupture may occur, resulting in aseptic chemical meningitis. **Goldenhar syndrome** may be associated with dermoid cyst, due to their related embryological origin.

[Ruptured dermoid cyst | Radiology Case | Radiopaedia.org](#)

radiopaedia.org/cases/ruptured-dermoid-cyst-1

Was this helpful?

PEOPLE ALSO ASK

Are intracranial dermoids asymptomatic? ▾

What is a ruptured dermoid cyst? ▾

What is an Intracranial epidermoid cyst? ▾

What is the prevalence of dermoid cysts? ▾

Feedback

Traumatic rupture of an intracranial dermoid cyst ...

<https://www.sciencedirect.com/science/article/pii/S1930043315305422>

Jan 01, 2015 · Intracranial dermoid cysts are congenital tumors of ectodermal origin. Rupture of these cysts can occur spontaneously, but rupture in association with trauma is reported infrequently. The diagnosis of rupture is made by the presence of lipid (cholesterol) droplets in ...

Cited by: 5

Author: Raksha Ramlakhan, Sally Candy

Publish Year: 2015

Traumatic rupture of an intracranial dermoid cyst

<https://pubmed.ncbi.nlm.nih.gov/27408663>

Intracranial dermoid cysts are congenital tumors of ectodermal origin. Rupture of these cysts can occur spontaneously, but rupture in association with trauma is reported infrequently. The diagnosis of rupture is made by the presence of lipid (cholesterol) droplets in the subarachnoid spaces and ventricles.

60,000 Results

Any time ▾

Traumatic rupture of an intracranial dermoid cyst: Case ...<https://surgicalneurologyint.com/surgicalint-articles/traumatic-rupture-of-an-...> ▾

Very rarely, they present as spontaneous ruptures. Traumatic rupture of these dermoid cysts is an extremely rare event and only a handful of such cases have been ever reported. Case Description: A 47...

Traumatic rupture of an intracranial dermoid cyst ...<https://www.sciencedirect.com/science/article/pii/S1930043315305422>

Jan 01, 2015 - Intracranial dermoid cysts are congenital tumors of ectodermal origin. Rupture of these cysts can occur spontaneously, but rupture in association with trauma is reported infrequently. The...

Cited by: 5

Author: Raksha Ramlakhani, Sally Candy

Publish Year: 2015

PEOPLE ALSO ASK

Can a ruptured teratoma cause ovary rupture? ▾

What is an Intracranial epidermoid cyst? ▾

Can cystic ovarian teratoma be treated laparoscopically? ▾

What is the treatment for epidermoid cyst? ▾

Feedback

Ruptured intracranial dermoid cyst. - Abstract - Europe PMC<https://europepmc.org/article/PMC/PMC3246848> ▾

Jan 01, 2012 - Rupture of an intracranial dermoid cyst is a rare event with considerable associated morbidity and potential mortality. We present a case of intracranial rupture of a dermoid cystic tumor...

Cited by: 17

Author: M. Jordan Ray, David W. Barnett, George J. ...

Publish Year: 2012

Traumatic rupture of an intracranial dermoid cyst: Case ...https://www.researchgate.net/publication/250920953_Traumatic_rupture_of_an...

Traumatic rupture of an intracranial dermoid cyst is an extremely rare event and this is only the fourth

Dermoid cyst

A dermoid cyst is a teratoma of a cystic nature that contains an array of developmentally mature, solid tissues. It frequently consists of skin, hair follicles, and sweat glands, while other commonly found components include clumps of long hair, pockets of sebum, blood, fat, bone, nail, teeth, eyes, cartilage, and thyroid tissue.

W Wikipedia

People also search for[Branchial cleft cyst](#)[Polycystic Ovary Syndrome](#)[Thyroglossal cyst](#)[Fetus in fetu](#)[Endodermal sinus tumor](#)[See more ▾](#)

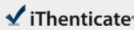
Data from: Wikipedia

[Suggest an edit](#)

21-Mar-2021 08:29PM

1943 words • 3 matches • 3 sources

FAQ

 iThenticate®

62637_Auto_Edited-check.docx

Quotes Excluded
Bibliography Excluded
4%
SMALL

Name of Journal: *World Journal of Clinical Cases*

Manuscript NO: 62637

Manuscript Type: CASE REPORT

Asymptomatic traumatic rupture of an intracranial dermoid cyst: A case report

Zhang MH *et al.* Rupture of an intracranial dermoid cyst

Mei-Hua Zhang, Qi Feng, Han-Lin Zhu, Heng Lu, Zhong-Xiang Ding, Bo Feng

Abstract

BACKGROUND

Previous studies reported that most of the intracranial dermoid cyst ruptures were spontaneous, and only a few were traumatic, with asymptomatic much rarer than the symptomatic ruptures. Hence, how to deal with the asymptomatic traumatic rupture of intracranial dermoid cyst remains a challenge in clinic.

CASE SUMMARY

Match Overview

1

Crossref 35 words
Stella Mouskou, Adriana Stamati, George Stakianos, Asterio Matama et al. "Ruptured intracranial dermoid cyst in a child..."

2%

2

Internet 13 words
crawled on 30-Sep-2020
[www.scribd.com](#)


1%

3

Internet 12 words
crawled on 21-Jul-2020
[www.thieme-connect.de](#)

1%

PAGE: 1 OF 8



Text-Only Report

59,800 Results

Any time ▾

Traumatic rupture of an intracranial dermoid cyst ...

<https://www.sciencedirect.com/science/article/pii/S1930043315305422>

Jan 01, 2015 · Intracranial dermoid cysts are congenital tumors of ectodermal origin. Rupture of these cysts can occur spontaneously, but rupture in association with trauma is reported infrequently. The diagnosis of rupture is made by the presence of lipid (cholesterol) droplets in ...

Cited by: 5

Author: Raksha Ramlakhan, Sally Candy

Publish Year: 2015

Traumatic rupture of an intracranial dermoid cyst.

<https://www.ncbi.nlm.nih.gov/pubmed/27408663>

Dec 03, 2015 · 1. Radiol Case Rep. 2015 Dec 3;10(1):1053. doi: 10.2484/rcr.v10i1.1053. eCollection 2015. Traumatic rupture of an intracranial dermoid cyst. Ramlakhan R, Candy S. Intracranial dermoid cysts are congenital tumors of ectodermal origin. Rupture of these cysts can occur spontaneously, but rupture in association with trauma is reported infrequently.

Cited by: 5

Author: Raksha Ramlakhan, Sally Candy

Publish Year: 2015

PEOPLE ALSO ASK

Are intracranial dermoids asymptomatic? ▾

What is a ruptured dermoid cyst? ▾

What is the prevalence of dermoid cysts? ▾

What is intracranial dermoid? ▾

[Feedback](#)

Traumatic rupture of an intracranial dermoid cyst ...

<https://www.sciencedirect.com/science/article/pii/S0967586807001038>

Apr 01, 2008 · The rupture of an intracranial dermoid cyst is a rare event, which typically occurs spontaneously. To date, only one case of the traumatic rupture of a dermoid cyst has been reported, and the patient in that case was managed conservatively. 3 The present paper reports the first case in