

Accidental transplantation of a kidney with a cystic renal ...

<https://pubmed.ncbi.nlm.nih.gov/16640518>

Transmission of cancer is a fatal risk in organ transplantation. We present a case of incidental renal carcinoma in a kidney obtained from a living donor. A 56-yr-old father was evaluated for donation for his 28-yr-old daughter. An MRT scan revealed two cysts in the right kidney. Right-sided donor n ...

Cited by: 19

Author: Michael Neipp, Anke Schwarz, Stefanie ...

Publish Year: 2006

Kidney Transplantation From Donors with Resectable Renal ...

<https://www.sciencedirect.com/science/article/pii/S0041134519310620>

Apr 01, 2020 · A donor with RCC and a tumor of <4 cm can donate a graft after an ex vivo partial nephrectomy. Case series have indicated that there is no recurrence of RCC in a graft after a partial nephrectomy up to 15 years after transplantation [, ,]. Moreover, Crepel et al have indicated an extraordinarily low risk of local recurrence or metastasis of ...

Author: Murat Sevmis, Sinasi Sevmis, Sema ...

Publish Year: 2020

PEOPLE ALSO ASK

Can you get a kidney transplant with a nephrectomy? ▾

Do you need a bladder catheter after kidney transplant? ▾

What is the procedure to remove a kidney from a donor? ▾

What to do after a partial nephrectomy? ▾

Feedback

Nephrectomy - National Kidney Foundation

<https://www.kidney.org/atoz/content/nephrectomy> ▾

Feb 03, 2017 · The risks of donor nephrectomy for kidney transplantation are very small. This is likely because almost all living donors undergo careful pre-op testing and evaluation to make sure they are healthy enough for surgery. Most studies report death rates for donor nephrectomy in the range of 1 or 2 per 10,000 donor surgeries.

[ALL](#) [IMAGES](#) [VIDEOS](#) [MAPS](#) [NEWS](#) [SHOPPING](#)

472,000 Results

Any time ▾

Kidney Transplantation From Donors with Resectable Renal ...<https://www.sciencedirect.com/science/article/pii/S0041134519310620>

Apr 01, 2020 · A **donor** with RCC and a tumor of <4 cm can donate a **graft after** an ex vivo partial **nephrectomy**. **Case** series have indicated that there is no recurrence of RCC in a **graft after** a partial...

Author: Murat Sevmis, Sinasi Sevmis, Sema Akt... **Publish Year:** 2020

Transplantation of a Kidney With a Renal Cell Carcinoma ...<https://www.sciencedirect.com/science/article/pii/S0041134507004587>

Jun 01, 2007 · Transmission of cancer from organ donors is considered to be a serious risk **after** solid organ transplantation. In fact, numerous cases have been described in which **donor**-derived malignance...

Cited by: 19 **Author:** A. Ghafari

Publish Year: 2007

PEOPLE ALSO ASK

Can you get a kidney transplant at Mayo Clinic? ▾

What is a living donor kidney transplant? ▾

What is the procedure for kidney transplant? ▾

What happens to your kidneys after a nephrectomy? ▾

[Feedback](#)**Transplantation of a Kidney With a Renal Cell Carcinoma ...**<https://www.researchgate.net/publication/6257430...>

Renal cell carcinoma (RCC) developing in a **renal** allograft either as a result of undetected presence within the **donor** organ or as a consequence of **de novo** development post transplantation is a ...

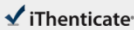
Incidental renal cell carcinoma presenting in a renal ...<https://www.ncbi.nlm.nih.gov/pmc/articles/PMC3423017>

A 57-year-old Asian man with end-stage **kidney** disease **due** to autosomal dominant polycystic **kidney** disease received a **living kidney graft** from his brother. Because of recurrent infection, chronic pain and...

24-Mar-2021 10:21PM

3474 words • 9 matches • 9 sources

FAQ

 iThenticate®

63003_Auto_Edited-check.docx

Quotes Excluded
Bibliography Excluded
4%
SMILCAT

Name of Journal: *World Journal of Clinical Cases*

Manuscript NO: 63003

Manuscript Type: CASE REPORT

Kidney re-transplantation after living donor graft nephrectomy due to *de novo* chromophobe renal cell carcinoma: A case report

Wang H *et al.* Re-transplantation after allograft nephrectomy for ChRCC

Hui Wang, Wen-Li Song, Wen-Juan Cai, Gang Feng, Ying-Xin Fu

Abstract

BACKGROUND

There are few reported cases of allograft nephrectomy due to malignancy followed by successful renal re-transplantation two years later. In this study, we report a patient who underwent kidney re-transplantation after living donor graft nephrectomy due to *de novo* chromophobe renal cell carcinoma (ChRCC) involving the allograft kidney.

Match Overview

1

Crossref 28 words
Hui Wang, Ying-Xin Fu, Wen-Li Song, Zhen Wang, Gang Feng, Jie Zhao, Ye-Qi Nian, Yu Cao "Human parvovirus B19-a

1%

2

Internet 20 words
crawled on 20-Oct-2020
journals.bnu.com

1%

3

Internet 14 words
crawled on 24-Jul-2020
www.mendei.com

<1%

4

Internet 14 words
crawled on 03-May-2020
www.unipoststory.svk.se/unin.tr

<1%

5

Crossref 12 words
Giordano Luciano, Paul Brookes, Eva Santos-Nunez, Nicol a Ferraon et al. "Alloproliferation after transplant failure: the ...

<1%

6

Internet 14 words
crawled on 30-May-2016
www.science.gov

<1%

7

Internet 12 words
crawled on 24-Dec-2017
top.uah.edu

<1%

8

Crossref 12 words
"Abstracts Poster", American Journal of Transplantation, 5/2
008

<1%

PAGE: 1 OF 13

Text-Only Report

国内版 国际版

Kidney re-transplantation after living donor graft nephrectomy due



ALL

IMAGES

VIDEOS

472,000 Results

Any time ▾

Kidney Transplantation From Donors with Resectable Renal ...

<https://www.sciencedirect.com/science/article/pii/S0041134519310620>

Apr 01, 2020 · A donor with RCC and a tumor of <4 cm can donate a graft after an ex vivo partial nephrectomy. Case series have indicated that there is no recurrence of RCC in a graft after a partial nephrectomy up to 15 years after transplantation [, ,]. Moreover, Crepel et al have indicated an extraordinarily low risk of local recurrence or metastasis of ...

Author: Murat Sevmis, Sinasi Sevmis, Sema ... Publish Year: 2020

Living donor renal transplantation with incidental renal ...

<https://pubmed.ncbi.nlm.nih.gov/25898787>

To report our series of cases with living donor kidney transplant by laparoscopic nephrectomy with incidental renal cell carcinomas (RCC) at the time of transplant. We performed a search of cases of renal allografts from living donors with incidental tumors which were confirmed as RCC in final patho ...

Transplantation of a Kidney With a Renal Cell Carcinoma ...

<https://www.researchgate.net/publication/6257430...>

Renal cell carcinoma (RCC) developing in a renal allograft either as a result of undetected presence within the donor organ or as a consequence of de novo development post transplantation is a ...

Living donor renal transplantation with incidental renal ...

<https://onlinelibrary.wiley.com/doi/abs/10.1111/tri.12594>

To report our series of cases with living donor kidney transplant by laparoscopic nephrectomy with incidental renal cell carcinomas (RCC) at the time of transplant. We performed a search of cases of renal allografts from living donors with incidental tumors which ...

Cited by: 13 Author: Jose A. Lugo-Baruqui, Giselle Guerra, Lin...

Publish Year: 2015

Transplantation of a Kidney With a Renal Cell Carcinoma ...

<https://www.sciencedirect.com/science/article/pii/S0041134507004587>

Jun 01, 2007 · Transmission of cancer is a serious risk in organ transplantation. We present a case of renal cell carcinoma (RCC) in a kidney obtained from a living donor. A 48-year-old mother was evaluated for donation to her 12-year-old daughter. Donor renal ultrasound, intravenous pyelography, and angiography were normal.