

[Large duct type invasive adenocarcinoma of the pancreas ...](#)

<https://pubmed.ncbi.nlm.nih.gov/22056954>

A morphological variant of pancreatic ductal adenocarcinoma forming large ductal elements, large duct type ductal adenocarcinoma, is documented and its clinicopathological features are studied. These tumors may have microcystic and papillary growth patterns that closely mimic the non-invasive cystic and papillary pancreatic tumors such as: intraductal papillary-mucinous neoplasia, including the oncocytic variant, mucinous cystic neoplasms, and ducts involved by pancreatic intraepithelial ...

[Large duct type invasive adenocarcinoma of the pancreas ...](#)

<https://www.nature.com/articles/modpathol2011181>

Nov 04, 2011 · In conclusion, it should be recognized that, some (8%) pancreatic ductal adenocarcinomas exhibit a large duct pattern that may microscopically mimic non-invasive pancreatic tumors characterized by...

Cited by: 24

Author: Pelin Bagci, Aleodor A. Andea, Olca Bas...

Publish Year: 2012

[\(PDF\) Large duct type invasive adenocarcinoma of the ...](#)

<https://www.researchgate.net/publication/51773424...>

pancreatic ductal adenocarcinomas exhibit a large duct pattern that may microscopically mimic non-invasive pancreatic tumors characterized by cystic and papillary patterns. They may be...

[Large duct type invasive adenocarcinoma of the pancreas ...](#)

<https://europepmc.org/article/MED/22056954> ▼

Nov 04, 2011 · These tumors may have microcystic and papillary growth patterns that closely mimic the non-invasive cystic and papillary pancreatic tumors such as: intraductal papillary-mucinous neoplasia, including the oncocytic variant, mucinous cystic neoplasms, and ducts involved by pancreatic intraepithelial neoplasia.

Cited by: 24

Author: Pelin Bagci, Aleodor A. Andea, Olca Bas...

Publish Year: 2012

[Ductal Adenocarcinoma of the Pancreas - ScienceDirect](#)

<https://www.sciencedirect.com/science/article/pii/S1875918111000997>

Jun 01, 2011 · Pancreatic ductal adenocarcinoma (PDAC) and its variants comprise between 80% and

Large duct type invasive adenocarcinoma of the pancreas ...<https://pubmed.ncbi.nlm.nih.gov/22056954>

A morphological variant of pancreatic ductal adenocarcinoma forming large ductal elements, large duct type ductal adenocarcinoma, is documented and its clinicopathological features are studied. These tumors may have microcystic and papillary growth patterns that closely mimic the non-invasive cystic and papillary pancreatic tumors such as: intraductal papillary-mucinous neoplasia, including the oncocytic variant, mucinous cystic neoplasms, and ducts involved by pancreatic ...

Cited by: 24 Author: Pelin Bagci, Aleodor A. Andea, Olca Bas ...

Publish Year: 2012

Large duct type invasive adenocarcinoma of the pancreas ...<https://www.nature.com/articles/modpathol2011181>

Large duct type ductal adenocarcinoma closely resembles non-invasive pancreatic tumors that have a cystic and/or papillary pattern, namely intraductal papillary mucinous neoplasia (including the ...

Cited by: 24 Author: Pelin Bagci, Aleodor A. Andea, Olca Bas ...

Publish Year: 2012

PEOPLE ALSO ASK

Search Tools


Turn off Hover Translation (关闭翻译)

激活 Windows
转到“设置”以激活 Windows。

07-May-2021 09:10PM

3516 words • 4 matches • 3 sources

FAQ

iThenticate®

63338-Manuscript-File-revision.docx

Quotes Excluded
Bibliography Excluded

2%
SIMILAR

Name of Journal: *World Journal of Gastroenterology*

Manuscript type: MINIREVIEW

Large-duct pattern invasive adenocarcinoma of the pancreas - a variant mimicking pancreatic cystic neoplasms: A minireview

Sato *et al.* Large-duct pattern invasive pancreatic cancer

Hiroki Sato, Andrew S. Liss, and Yusuke Mizukami

Match Overview

1

Crossref 31 words
Krishna C Patra, Nabeel Bardeesy, Yusuke Mizukami. "Diversity of Precursor Lesions For Pancreatic Cancer. The C..."

1%

2

Internet 25 words
crawled on 22-Apr-2016
www.ncbi.nlm.nih.gov

1%

3

Crossref 16 words
Seo Yeon Yoon, Sung Eun Rha, Eun Sun Jung, In Seok Lee. "Pancreas ductal adenocarcinoma with cystic features ..."

<1%

Page: 1 of 16

PDF

Text-Only Report

国内版 国际版

Large-duct pattern invasive adenocarcinoma of the pancreas—a vari

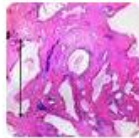

ALL IMAGES VIDEOS

11,900 Results Any time ▾

Large duct type invasive adenocarcinoma of the pancreas ...

<https://www.nature.com/articles/modpathol2011181>



Nov 04, 2011 · Large duct type ductal adenocarcinoma closely resembles non-invasive pancreatic tumors that have a cystic and/or papillary pattern, namely intraductal papillary mucinous neoplasia ...

Cited by: 24

Author: Pelin Bagci, Aleodor A. Andea, O...

Publish Year: 2012

(PDF) Large duct type invasive adenocarcinoma of the ...

<https://www.researchgate.net/publication/51773424...>



Nov 04, 2011 · These tumors may have microcystic and papillary growth patterns that closely mimic the non-invasive cystic and papillary pancreatic tumors such as: ...

Estimated Reading Time: 5 mins

PEOPLE ALSO ASK

What is pancreatic ductal adenocarcinoma? ▾

Can a pancreatic tumor mimic an adenocarcinoma? ▾

What are pancreatic cystic tumors? ▾

What are the three types of pancreatic neoplasms? ▾

Feedback

Large duct type invasive adenocarcinoma of the pancreas ...

<https://europepmc.org/article/MED/22056954> ▾

Nov 04, 2011 · These tumors may have microcystic and papillary growth patterns that closely mimic the non-invasive cystic and papillary pancreatic tumors such as: intraductal papillary-mucinous neoplasia, including the oncocytic variant, mucinous cystic neoplasms, and ducts involved by pancreatic intraepithelial neoplasia.

Cited by: 24

Author: Pelin Bagci, Aleodor A. Andea, Olca Bas...

Publish Year: 2012