

# World Journal of *Clinical Cases*

*World J Clin Cases* 2021 July 16; 9(20): 5352-5753



## Contents

Thrice Monthly Volume 9 Number 20 July 16, 2021

## EDITORIAL

- 5352 COVID-19: Considerations about immune suppression and biologicals at the time of SARS-CoV-2 pandemic

*Costanzo G, Cordeddu W, Chessa L, Del Giacco S, Firinu D*

## REVIEW

- 5358 Obesity in people with diabetes in COVID-19 times: Important considerations and precautions to be taken
- Alberti A, Schuelter-Trevisol F, Iser Betine PM, Traebert E, Freiburger V, Ventura L, Rezin GT, da Silva BB, Meneghetti Dallacosta F, Grigollo L, Dias P, Fin G, De Jesus JA, Pertille F, Rossoni C, Hur Soares B, Nodari Junior RJ, Comim CM*

- 5372 Revisiting delayed appendectomy in patients with acute appendicitis

*Li J*

## MINIREVIEWS

- 5391 Detection of short stature homeobox 2 and RAS-associated domain family 1 subtype A DNA methylation in interventional pulmonology

*Wu J, Li P*

- 5398 Borderline resectable pancreatic cancer and vascular resections in the era of neoadjuvant therapy

*Mikulic D, Mrzljak A*

- 5408 Esophageal manifestation in patients with scleroderma

*Voulgaris TA, Karamanolis GP*

- 5420 Exploration of transmission chain and prevention of the recurrence of coronavirus disease 2019 in Heilongjiang Province due to in-hospital transmission

*Chen Q, Gao Y, Wang CS, Kang K, Yu H, Zhao MY, Yu KJ*

- 5427 Role of gastrointestinal system on transmission and pathogenesis of SARS-CoV-2

*Simsek C, Erul E, Balaban HY*

## ORIGINAL ARTICLE

## Case Control Study

- 5435 Effects of nursing care in fast-track surgery on postoperative pain, psychological state, and patient satisfaction with nursing for glioma

*Deng YH, Yang YM, Ruan J, Mu L, Wang SQ*

## Retrospective Study

- 5442 Risk factors related to postoperative recurrence of dermatofibrosarcoma protuberans: A retrospective study and literature review

*Xiong JX, Cai T, Hu L, Chen XL, Huang K, Chen AJ, Wang P*

- 5453** Prediction of presence and severity of coronary artery disease using prediction for atherosclerotic cardiovascular disease risk in China scoring system

*Hong XL, Chen H, Li Y, Teeroovengadum HD, Fu GS, Zhang WB*

- 5462** Effects of angiotensin receptor blockers and angiotensin-converting enzyme inhibitors on COVID-19

*Li XL, Li T, Du QC, Yang L, He KL*

- 5470** Prognostic factors and its predictive value in patients with metastatic spinal cancer

*Gao QP, Yang DZ, Yuan ZB, Guo YX*

### Clinical Trials Study

- 5479** Prospective, randomized comparison of two supplemental oxygen methods during gastro-scopy with propofol mono-sedation in obese patients

*Shao LJZ, Hong FX, Liu FK, Wan L, Xue FS*

### SYSTEMATIC REVIEWS

- 5490** Herb-induced liver injury: Systematic review and meta-analysis

*Ballotin VR, Bigarella LG, Brandão ABM, Balbinot RA, Balbinot SS, Soldera J*

### META-ANALYSIS

- 5514** Type 2 diabetes mellitus increases liver transplant-free mortality in patients with cirrhosis: A systematic review and meta-analysis

*Liu ZJ, Yan YJ, Weng HL, Ding HG*

### CASE REPORT

- 5526** Duplication of 19q (13.2-13.31) associated with comitant esotropia: A case report

*Feng YL, Li ND*

- 5535** Multiple left ventricular myxomas combined with severe rheumatic valvular lesions: A case report

*Liu SZ, Hong Y, Huang KL, Li XP*

- 5540** Complete pathological response in locally advanced non-small-cell lung cancer patient: A case report

*Parisi E, Arpa D, Ghigi G, Micheletti S, Neri E, Tontini L, Pieri M, Romeo A*

- 5547** Successful reversal of ostomy 13 years after Hartmann procedure in a patient with colon cancer: A case report

*Huang W, Chen ZZ, Wei ZQ*

- 5556** Delayed papillary muscle rupture after radiofrequency catheter ablation: A case report

*Sun ZW, Wu BF, Ying X, Zhang BQ, Yao L, Zheng LR*

- 5562** Temporary coronary sinus pacing to improve ventricular dyssynchrony with cardiogenic shock: A case report

*Ju TR, Tseng H, Lin HT, Wang AL, Lee CC, Lai YC*

- 5568** Hemoglobin Fukuoka caused unexpected hemoglobin A<sub>1c</sub> results: A case report  
*Lin XP, Yuan QR, Niu SQ, Jiang X, Wu ZK, Luo ZF*
- 5575** Giant androgen-producing adrenocortical carcinoma with atrial flutter: A case report and review of the literature  
*Costache MF, Arhirii RE, Mogos SJ, Lupascu-Ursulescu C, Litcanu CI, Ciunanghel AI, Cucu C, Ghiciuc CM, Petris AO, Danila N*
- 5588** Can kissing cause paraquat poisoning: A case report and review of literature  
*Ly B, Han DF, Chen J, Zhao HB, Liu XL*
- 5594** Spinal dural arteriovenous fistula 8 years after lumbar discectomy surgery: A case report and review of literature  
*Ouyang Y, Qu Y, Dong RP, Kang MY, Yu T, Cheng XL, Zhao JW*
- 5605** Perianal superficial CD34-positive fibroblastic tumor: A case report  
*Long CY, Wang TL*
- 5611** Low-dose clozapine-related seizure: A case report and literature review  
*Le DS, Su H, Liao ZL, Yu EY*
- 5621** Rapid diagnosis of disseminated *Mycobacterium mucogenicum* infection in formalin-fixed, paraffin-embedded specimen using next-generation sequencing: A case report  
*Liu J, Lei ZY, Pang YH, Huang YX, Xu LJ, Zhu JY, Zheng JX, Yang XH, Lin BL, Gao ZL, Zhuo C*
- 5631** Cytomegalovirus colitis induced segmental colonic hypoganglionosis in an immunocompetent patient: A case report  
*Kim BS, Park SY, Kim DH, Kim NI, Yoon JH, Ju JK, Park CH, Kim HS, Choi SK*
- 5637** Primary extra-pancreatic pancreatic-type acinar cell carcinoma in the right perinephric space: A case report and review of literature  
*Wei YY, Li Y, Shi YJ, Li XT, Sun YS*
- 5647** Muscular atrophy and weakness in the lower extremities in Behçet's disease: A case report and review of literature  
*Kim KW, Cho JH*
- 5655** Novel technique of extracorporeal intrauterine morcellation after total laparoscopic hysterectomy: Three emblematic case reports  
*Macciò A, Sanna E, Lavra F, Calò P, Madeddu C*
- 5661** Rare isolated extra-hepatic bile duct injury: A case report  
*Zhao J, Dang YL, Lin JM, Hu CH, Yu ZY*
- 5668** Gelfoam embolization for distal, medium vessel injury during mechanical thrombectomy in acute stroke: A case report  
*Kang JY, Yi KS, Cha SH, Choi CH, Kim Y, Lee J, Cho BS*



- 5675** Oncocytic adrenocortical tumor with uncertain malignant potential in pediatric population: A case report and review of literature  
*Chen XC, Tang YM, Mao Y, Qin DR*
- 5683** Submucosal hematoma with a wide range of lesions, severe condition and atypical clinical symptoms: A case report  
*Liu L, Shen XJ, Xue LJ, Yao SK, Zhu JY*
- 5689** Chorioamnionitis caused by *Serratia marcescens* in a healthcare worker: A case report  
*Park SY, Kim MJ, Park S, Kim NI, Oh HH, Kim J*
- 5695** Endoscopic management of biliary ascariasis: A case report  
*Wang X, Lv YL, Cui SN, Zhu CH, Li Y, Pan YZ*
- 5701** Role of ranulas in early diagnosis of Sjögren's syndrome: A case report  
*Chen N, Zeng DS, Su YT*
- 5709** Sacral chondroblastoma — a rare location, a rare pathology: A case report and review of literature  
*Zheng BW, Niu HQ, Wang XB, Li J*
- 5717** Primary liver actinomycosis in a pediatric patient: A case report and literature review  
*Liang ZJ, Liang JK, Chen YP, Chen Z, Wang Y*
- 5724** Splenosis masquerading as gastric stromal tumor: A case report  
*Zheng HD, Xu JH, Sun YF*
- 5730** Hemorrhagic transformation of ischemic cerebral proliferative angiopathy: A case report  
*Xia Y, Yu XF, Ma ZJ, Sun ZW*
- 5737** Multidisciplinary team therapy for left giant adrenocortical carcinoma: A case report  
*Zhou Z, Luo HM, Tang J, Xu WJ, Wang BH, Peng XH, Tan H, Liu L, Long XY, Hong YD, Wu XB, Wang JP, Wang BQ, Xie HH, Fang Y, Luo Y, Li R, Wang Y*
- 5744** Histopathology and immunophenotyping of late onset cutaneous manifestations of COVID-19 in elderly patients: Three case reports  
*Mazzitelli M, Dastoli S, Mignogna C, Bennardo L, Lio E, Pelle MC, Trecarichi EM, Pereira BI, Nisticò SP, Torti C*

**CORRECTION**

- 5752** Corrigendum to "Probiotic mixture VSL#3: An overview of basic and clinical studies in chronic diseases"  
*Sang LX*

**ABOUT COVER**

Editorial Board Member of *World Journal of Clinical Cases*, Fan-Zheng Meng, MD, PhD, Director, Professor, Department of Pediatrics, The First hospital of Jilin University, Changchun 130021, Jilin Province, China. mengfanzheng1972@163.com

**AIMS AND SCOPE**

The primary aim of *World Journal of Clinical Cases* (WJCC, *World J Clin Cases*) is to provide scholars and readers from various fields of clinical medicine with a platform to publish high-quality clinical research articles and communicate their research findings online.

WJCC mainly publishes articles reporting research results and findings obtained in the field of clinical medicine and covering a wide range of topics, including case control studies, retrospective cohort studies, retrospective studies, clinical trials studies, observational studies, prospective studies, randomized controlled trials, randomized clinical trials, systematic reviews, meta-analysis, and case reports.

**INDEXING/ABSTRACTING**

The WJCC is now indexed in Science Citation Index Expanded (also known as SciSearch®), Journal Citation Reports/Science Edition, Scopus, PubMed, and PubMed Central. The 2021 Edition of Journal Citation Reports® cites the 2020 impact factor (IF) for WJCC as 1.337; IF without journal self cites: 1.301; 5-year IF: 1.742; Journal Citation Indicator: 0.33; Ranking: 119 among 169 journals in medicine, general and internal; and Quartile category: Q3. The WJCC's CiteScore for 2020 is 0.8 and Scopus CiteScore rank 2020: General Medicine is 493/793.

**RESPONSIBLE EDITORS FOR THIS ISSUE**

Production Editor: Jia-Hui Li; Production Department Director: Yu-Jie Ma; Editorial Office Director: Jin-Lei Wang.

**NAME OF JOURNAL**

*World Journal of Clinical Cases*

**ISSN**

ISSN 2307-8960 (online)

**LAUNCH DATE**

April 16, 2013

**FREQUENCY**

Thrice Monthly

**EDITORS-IN-CHIEF**

Dennis A Bloomfield, Sandro Vento, Bao-Gan Peng

**EDITORIAL BOARD MEMBERS**

<https://www.wjgnet.com/2307-8960/editorialboard.htm>

**PUBLICATION DATE**

July 16, 2021

**COPYRIGHT**

© 2021 Baishideng Publishing Group Inc

**INSTRUCTIONS TO AUTHORS**

<https://www.wjgnet.com/bpg/gerinfo/204>

**GUIDELINES FOR ETHICS DOCUMENTS**

<https://www.wjgnet.com/bpg/GerInfo/287>

**GUIDELINES FOR NON-NATIVE SPEAKERS OF ENGLISH**

<https://www.wjgnet.com/bpg/gerinfo/240>

**PUBLICATION ETHICS**

<https://www.wjgnet.com/bpg/GerInfo/288>

**PUBLICATION MISCONDUCT**

<https://www.wjgnet.com/bpg/gerinfo/208>

**ARTICLE PROCESSING CHARGE**

<https://www.wjgnet.com/bpg/gerinfo/242>

**STEPS FOR SUBMITTING MANUSCRIPTS**

<https://www.wjgnet.com/bpg/GerInfo/239>

**ONLINE SUBMISSION**

<https://www.f6publishing.com>



## Low-dose clozapine-related seizure: A case report and literature review

Dan-Sheng Le, Heng Su, Zheng-Luan Liao, En-Yan Yu

**ORCID number:** Dan-Sheng Le 0000-0001-9913-0929; Heng Su 0000-0003-0819-0059; Zheng-Luan Liao 0000-0002-6114-6682; En-Yan Yu 0000-0001-5594-4365.

**Author contributions:** Le DS conceived the central idea, analyzed clinical data and wrote the initial draft; all authors participated in clinical diagnosis and revised the manuscript.

**Informed consent statement:** Informed written consent was obtained from the patient for publication of this report and any accompanying images.

**Conflict-of-interest statement:** The authors declare that they have no conflict of interest.

**CARE Checklist (2016) statement:** The authors have read the CARE Checklist (2016), and the manuscript was prepared and revised according to the CARE Checklist (2016).

**Open-Access:** This article is an open-access article that was selected by an in-house editor and fully peer-reviewed by external reviewers. It is distributed in accordance with the Creative Commons Attribution NonCommercial (CC BY-NC 4.0) license, which permits others to distribute, remix, adapt, build

**Dan-Sheng Le**, The Second Clinical Medical College, Zhejiang Chinese Medicine University, Hangzhou 310051, Zhejiang Province, China

**Heng Su, Zheng-Luan Liao**, Department of Psychiatry, Zhejiang Provincial People's Hospital, Hangzhou 310000, Zhejiang Province, China

**En-Yan Yu**, Department of Psychiatry, The Cancer Hospital of the University of Chinese Academy of Sciences (Zhejiang Cancer Hospital), Institute of Basic Medicine and Cancer, Chinese Academy of Sciences, Hangzhou 310022, Zhejiang Province, China

**Corresponding author:** En-Yan Yu, MM, Chief Physician, Professor, Department of Psychiatry, The Cancer Hospital of the University of Chinese Academy of Sciences (Zhejiang Cancer Hospital), Institute of Basic Medicine and Cancer, Chinese Academy of Sciences, No. 1 East Banshan Road, Gongshu District, Hangzhou 310022, Zhejiang Province, China.  
[yuenyan@aliyun.com](mailto:yuenyan@aliyun.com)

### Abstract

#### BACKGROUND

Treatment-resistant schizophrenia is a severe form of schizophrenia characterized by poor response to at least two antipsychotic drugs and is typically treated with clozapine. However, clozapine lowers the epileptic threshold, leading to seizures, which are severe side effects of antipsychotics that result in multiple complications. Clozapine-related seizures are generally considered to be dose-dependent and especially rare in the low-dose (150-300 mg/d) clozapine treated population. Due to clinical rarity, little is known about its clinical characteristics and treatment.

#### CASE SUMMARY

A 62-year-old Chinese man with a 40-year history of treatment-resistant schizophrenia presented to the Emergency Department with symptoms of myoclonus, consciousness disturbance and vomiting after taking 125 mg clozapine. Upon admission, the patient had a suddenly generalized tonic-clonic seizure lasting for about half a minute with persistent disturbance of consciousness, fever, cough and bloody sputum, which was considered to be low-dose clozapine-related seizure. After antiepileptic and multiple anti-infection treatments, the patient was discharged without epileptic or psychotic symptoms.

#### CONCLUSION

Our aim is to highlight the early prevention and optimal treatment of clozapine-

upon this work non-commercially, and license their derivative works on different terms, provided the original work is properly cited and the use is non-commercial. See: <http://creativecommons.org/licenses/by-nc/4.0/>

**Manuscript source:** Unsolicited Manuscript

**Specialty type:** Psychiatry

**Country/Territory of origin:** China

**Peer-review report's scientific quality classification**

Grade A (Excellent): 0

Grade B (Very good): 0

Grade C (Good): C

Grade D (Fair): 0

Grade E (Poor): 0

**Received:** February 8, 2021

**Peer-review started:** February 8, 2021

**First decision:** March 27, 2021

**Revised:** April 7, 2021

**Accepted:** May 20, 2021

**Article in press:** May 20, 2021

**Published online:** July 16, 2021

**P-Reviewer:** Kai K

**S-Editor:** Ma YJ

**L-Editor:** Filipodia

**P-Editor:** Li JH



related seizure through case analysis and literature review.

**Key Words:** Seizure; Treatment-resistant schizophrenia; Antipsychotic; Antiepileptic; Electroconvulsive therapy; Case report

©The Author(s) 2021. Published by Baishideng Publishing Group Inc. All rights reserved.

**Core Tip:** Clozapine-related seizure is a serious adverse reactions of clozapine, which should be given more attention to its early prevention and optimal treatment. Clinical features, treatment options and factors that may contribute to the development of clozapine-related seizures were summarized through case analysis and literature review, and relevant cases published in the last 20 years were summarized and listed.

**Citation:** Le DS, Su H, Liao ZL, Yu EY. Low-dose clozapine-related seizure: A case report and literature review. *World J Clin Cases* 2021; 9(20): 5611-5620

**URL:** <https://www.wjgnet.com/2307-8960/full/v9/i20/5611.htm>

**DOI:** <https://dx.doi.org/10.12998/wjcc.v9.i20.5611>

## INTRODUCTION

Clozapine, the first officially marketed atypical antipsychotic, has a unique therapeutic effect on treatment-resistant schizophrenia (TRS)[1] that significantly improves patients' quality of life, reduces violent and impulsive behavior[2] and reduces suicide and mortality rates[2-4]. Notably, the incidence of clozapine-related seizure is up to 4%-6%[5,6], which is higher than that of other typical or atypical antipsychotics[7] and will lead to further complications and ultimately increased mortality.

Clozapine-related seizures are generally considered to be dose-dependent and are rare in people treated with conventional doses of clozapine (300-450 mg/d), and especially rare in the low-dose (150-300 mg/d) clozapine treated population. Due to clinical rarity, little is known about its clinical characteristics and treatment. Thus, we herein report a 62-year-old Chinese male who had schizophrenia with low-dose clozapine-related seizure followed by aspiration pneumonia. Previous clinical cases of clozapine-related seizure were identified in a database and carefully reviewed to identify the clinical features, treatment options and factors that may contribute to the development of this rare disease entity.

## CASE PRESENTATION

### Chief complaints

A 62-year-old Chinese male presented to the Emergency Department of our hospital with complaints of myoclonus, consciousness disturbance and vomiting for 1 h.

### History of present illness

In the absence of a caregiver, the patient was found lying unconscious with myoclonic movements, surrounded by vomit. The number of remaining tablets suggested 125 mg clozapine had been taken.

### History of past illness

According to medical history, the patient has had TRS for 40 years, presenting with hallucinations, delusions, splitting of thought and a weak response to olanzapine, risperidone and perphenazine. The patient has been regularly taking clozapine 62.5 mg/d and quetiapine 300 mg/d for the last 10 years, and the mental symptoms were well controlled.

### Personal and family history

The patient has been regularly taking clozapine 62.5 mg/d and quetiapine 300 mg/d for the last 10 years, and the mental symptoms were well controlled. No family history



of mental illness was reported.

### **Physical examination**

Upon admission, the patient had a generalized tonic-clonic seizure (GTCS) lasting for about half a minute with persistent consciousness disturbance, fever, cough and bloody sputum.

### **Laboratory examinations**

Emergency laboratory tests revealed a white cell count of  $10.11 \times 10^9/L$ , 89.3% of which were neutrophils, and a high-sensitivity C-reactive protein content of 4.8 mg/L; the sputum culture indicated the presence of gram-negative bacilli. The blood concentration of clozapine was higher than 1500 ng/mL (reference: 350-600 ng/mL) at the 24<sup>th</sup> h and the 48<sup>th</sup> h after last administration. No other obvious abnormalities were found upon cerebrospinal fluid examination.

On the 10<sup>th</sup> day of hospitalization, the blood concentration of clozapine was 153 ng/mL (reference = 350-600 ng/mL).

### **Imaging examinations**

Emergency chest computed tomography indicated bilateral pneumonia with bilateral pleural effusion (Figure 1), and no other obvious abnormalities were found upon cranial computed tomography.

On the 3<sup>rd</sup> day of hospitalization, electroencephalogram (EEG) showed slow-wave and no epileptiform discharges (Figure 2).

---

## **FINAL DIAGNOSIS**

Schizophrenia with low-dose clozapine-related seizure followed by aspiration pneumonia.

---

## **TREATMENT**

Treatment mainly included antiepileptic therapy, multiple anti-infection therapies, and psycholytic therapy under the premise of the patency of airway.

After admission, clozapine was discontinued immediately, and sodium valproate 1000 mg/d, diazepam 2.5 mg/d, quetiapine 300 mg/d, acyclovir 500 mg/d and cefoperazone 2000 mg/d were administered.

On the 5<sup>th</sup> day of hospitalization, the patient developed dyspnea with an oxygen saturation of 60%-70% and no significant improvement after sputum aspiration, which was considered as respiratory failure. Thus, immediate tracheal intubation and mechanical ventilatory support were performed, and the treatment regimens were adjusted as meropenem 2000 mg/d, capophenine 50 mg/d and levetiracetam 1000 mg/d in addition to atomization, phlegm reduction and enteral nutrition.

On the 11<sup>th</sup> day of hospitalization, psychotic symptoms were observed after extubation, hallucinations, and splitting of thought. Therefore, clozapine 25 mg/d (slowly increased to 62.5 mg over 2 wk) and quetiapine 300 mg/d were administered.

---

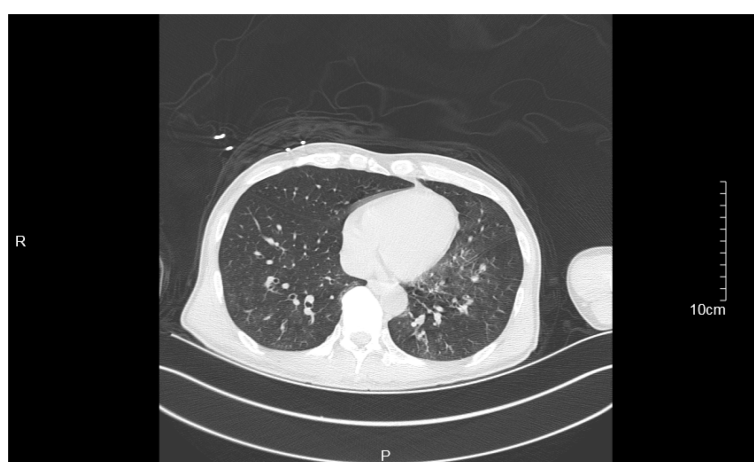## **OUTCOME AND FOLLOW-UP**

Eventually, the patient was discharged with no obvious seizures or psychotic symptoms and was satisfied with his treatment. After discharge, the patient took clozapine 62.5 mg/d and quetiapine 300 mg/d regularly under the supervision of a caregiver. During 3 mo of follow-up, the patient recovered well, and no exacerbations were detected.

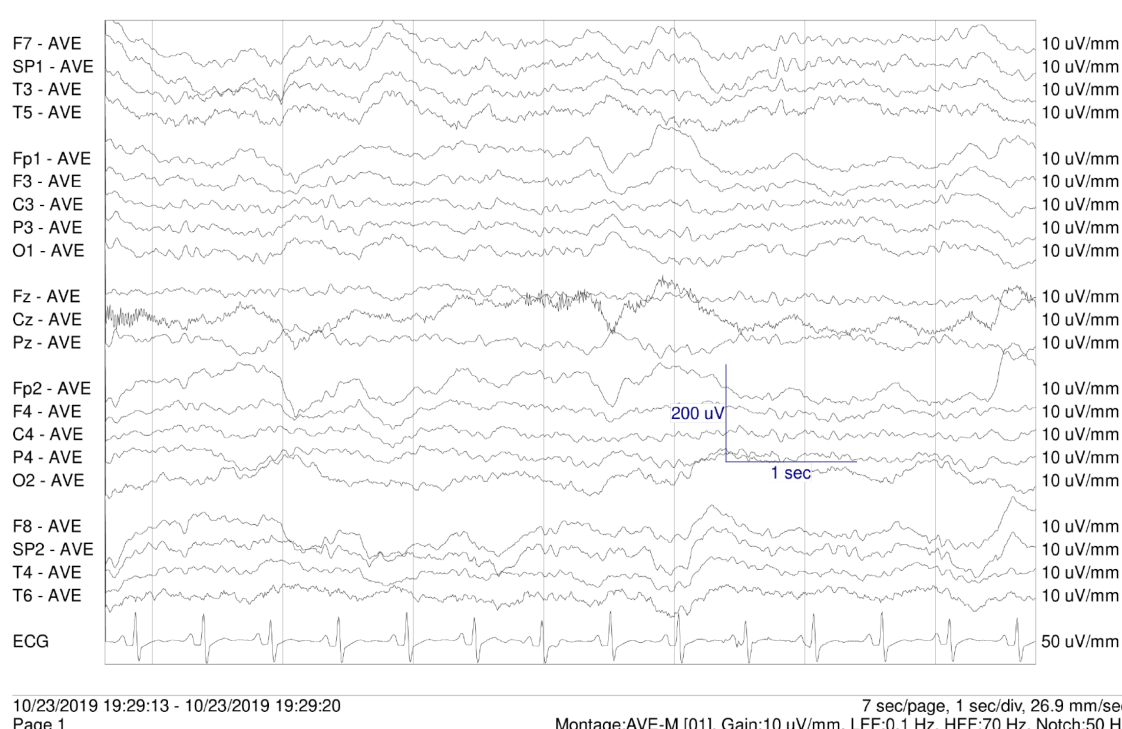
---

## **DISCUSSION**

Schizophrenia is a debilitating and heterogeneous mental disorder characterized by discordance between mental activity and the environment and manifests as a complex blend of positive and negative symptoms and cognitive impairment[8,9]. The lifetime



**Figure 1 Emergency chest computed tomography.** Emergency chest computed tomography indicated bilateral pneumonia with bilateral pleural effusion.



**Figure 2 Electroencephalogram on the 3<sup>rd</sup> day.** Electroencephalogram showed slow-wave and no epileptiform discharges.

suicide risk of patients with schizophrenia is 2 to 3 times higher than that in the general population[10], estimated to be about 5%[11], and life expectancy is about 20% less than that of the general population[12]. TRS, which is characterized by poor response to at least two antipsychotic drugs, is a severe form of schizophrenia that accounts for approximately one-third of all schizophrenia cases[13].

Clozapine not only has better effects on positive and negative symptoms and cognitive impairment than typical antipsychotics but also is associated with fewer adverse reactions[1,2]. Moreover, clozapine has unique therapeutic effects against TRS [1] that can significantly improve patients' quality of life, reduce violence and impulsive behaviors[2] and decrease the suicide rate and mortality[2-4]. However, the incidence of clozapine-related seizure is 4%-6%[5,6], which is higher than that of seizures related to typical antipsychotics[7]. Moreover, the uncertainty and unpredictability of epileptic seizures are closely related to negative emotions[14], which may result in the generation, maintenance or exacerbation of mental disorders[15].

In this case, EEG examinations were not performed in a timely manner, and no significant abnormalities were found in subsequent EEG reports. No psychometric scale results were reported, and the evaluation of therapeutic efficacy for schizo-

Table 1 Case reports of low-dose clozapine-related seizure

Ref.	Year	Gender	Age	Clozapine dose (mg/d)	Type of seizure
Haberfellner[31]	2002	Female	29	150	Myoclonus and GTCS
Praharaj <i>et al</i> [32]	2010	Male	38	250	Myoclonus
Horga <i>et al</i> [33]	2010	Male	15	300	GTCS
Park <i>et al</i> [34]	2014	Female	26	300	GTCS
Kikuchi <i>et al</i> [35]	2014	Female	24	300	Myoclonus
Grover <i>et al</i> [6]	2015	Male	54	200	GTCS
Bolu <i>et al</i> [29]	2017	Male	29	200	GTCS
Borah <i>et al</i> [30]	2019	Female	42	300	Jerky movement of limbs
		Male	63	275	GTCS
		Male	25	250	GTCS
		Female	34	225	GTCS
		Female	34	150	GTCS
		Female	22	300	Myoclonus
		Female	25	275	Myoclonus

GTCS: Generalized tonic-clonic seizure.

phrenia was based primarily on clinical presentation. This case does not prove a link between low-dose clozapine, seizure and pneumonia nor does it reflect the wider population. Therefore, a review of the previous literature and a summary of the published case reports is necessary.

The mechanism of clozapine-related seizure may be caused by the combined action of multiple receptors. Dopamine has been shown to reduce the excitability of the primary sensorimotor cortex in adult rats[16]. Clozapine may increase cortical excitability by reducing dopamine neurotransmission[16]. Serotonin receptors are expressed in almost all neural networks associated with seizure. Consumption of serotonin in the brain can enhance the excitability of neurons, reduce the seizure threshold and increase seizure frequency[17]. The antiepileptic effects of selective serotonin reuptake inhibitors have been demonstrated in controlled trials[18].

Clozapine-related seizure is widely considered as dose-dependent[6]. Standard titration of clozapine refers to starting at a dosage of 12.5-25 mg/d and increasing the dosage by 25-50 mg/d to reach a maintenance dosage of 300-400 mg/d after 2 wk[19]. This slow titration method can reduce the risk of seizure, but it may extend the treatment time or require the combination of clozapine with other drugs to control mental symptoms over time[19,20]. In contrast, the rapid increase regimen can quickly control psychiatric symptoms and reduce medical costs[19,21] but may lead to unnecessarily high drug doses that cause adverse drug reactions such as seizure. However, in some clinical trials, the rapid titration of clozapine was reported to be safe and effective and to be beneficial for aggressive or suicidal patients[19,22].

The dosage regimen of clozapine directly affects blood concentration. A study showed that the risk of seizure is 3% when the dose of clozapine does not exceed 300 mg/d, that the risk increases to 8% when the dose is 325 to 500 mg/d and that the risk is as high as 38% when the dose exceeds 500 mg/d[6]. The lower limit of the therapeutic range for clozapine serum levels is between 250 and 420 ng/mL, and the risk of seizure increases when the serum level is > 750 ng/mL[23] and increases significantly when the serum level exceeds 1300 ng/mL[24]. Moreover, for every 100 mg/d increase in daily dose of clozapine, the abnormal rate of EEG increases by 8%, and for every 100 mg/L increase in plasma level of clozapine, the rate increases by 12%[25]. However, the serum level is affected by age[23], gender[26], smoking status[23], caffeine use[27] and other factors, hence, neither the serum level nor the dose of clozapine could accurately predict the occurrence of seizure. In clinical practice, most practitioners take 600 mg/d as the safety threshold[5], but cases of clozapine-related seizure have also been reported in the low-dose (150-300 mg/d)[28] treatment group [29,30]. Literature was systematically retrieved from electronic databases (PubMed and

Table 2 Case reports of clozapine-related seizure published in last 20 years

Ref.	Year	Age	Gender	Dose of clozapine	Blood concentration of clozapine	Blood concentration of norclozapine	Type of seizure	EEG	Antiepileptic drugs	Further use of clozapine	Other psychiatric drugs
Usiskin <i>et al</i> [47]	2000	15	M	400 mg/ d	-	-	Myoclonus and GTCS	Bihemispheric epileptiform activity	Gabapentin 2100 mg/dClonazepam 2 mg/ d	300 mg/ d	Olanzapine 25 mg/ d
Navarro <i>et al</i> [48]	2001	23	F	200 mg/ d	-	-	GTCS	Bihemispheric epileptiform activity	Topiramate 200 mg/ d	200 mg/ d	-
Haberfellner [31]	2002	29	F	150 mg/ d	-	-	Myoclonus and GTCS	Paroxysmal generalized spikes	-	100 mg/ d	Haloperidol 10 mg/ d
Duggal <i>et al</i> [49]	2002	28	M	300 mg/ d	-	-	Stuttering	-	-	-	-
				425 mg/ d	-	-	GTCS	Generalized nonparoxysmal slowing and a photic convulsive response	Valproate 800 mg/ d	300 mg/ d	-
Foster <i>et al</i> [50]	2005	32	F	125 mg/ d	-	-	TCS	-	-	-	-
				237.5 mg/ d	-	-	TCS	-	Valproate 500 mg/ d	450 mg/ d	Citalopram 20 mg/ d
Begum <i>et al</i> [51]	2005	-	-	300 mg/ d	-	-	Myoclonus and stuttering	-	Valproate 400 mg/ d	300 mg/ d	-
Muzyk <i>et al</i> [52]	2010	20	M	600 mg/ d	-	-	Myoclonus and GTCS	-	Lamotrigine 200 mg/ d	550 mg/ d	Lithium 900 mg/ d
Praharaj <i>et al</i> [32]	2010	38	M	250 mg/ d	-	-	Myoclonus	Bilateral frontal theta waves and sharp-slow wave	Clonazepam 1000 mg/ d	250 mg/ d	-
Horga <i>et al</i> [33]	2010	15	M	350 mg/ d	-	-	Speech dysfluency and myoclonus	-	-	300 mg/ d	Clomipramine 225 mg/ d
				300 mg/ d	-	-	GTCS	Generalized andMultifocal paroxysmal epileptiform discharges	Sodium valproate 500 mg/ d	300 mg/ d	Clomipramine 225 mg/ d
Leung <i>et al</i> [53]	2014	52	F	450 mg/ d	1400 ng/ mL (36 h after the last dose)	606 ng/ mL (36 h after the last dose)	Myoclonus	-	-	225.5 mg/ d	-
Park <i>et al</i> [34]	2014	26	F	450 mg/ d	-	-	GTCS	-	-	300 mg/ d	-
				300 mg/ d	-	-	GTCS	No epileptiform discharge	Valproate 250 mg	Drug withdrawal	ECT, risperidone 6 mg/ d, escitalopram 15 mg/ d
Kikuchi <i>et al</i> [35]	2014	19-48	F (n = 12)	275-600 mg/ d	-	-	TCS and myoclonic (n =1) TCS (n = 1)	Spike and slow wave	Lamotrigine 150-300 mg/ d (n = 2) Valproate 400-800 mg/ d (	200-550 mg/ d	-

							Myoclonic ( <i>n</i> = 4)		<i>n</i> = 3)		
Grover <i>et al</i> [6]	2015	24-63	F ( <i>n</i> = 3) M ( <i>n</i> = 9)	150-600 mg/d	-	-	GTCS ( <i>n</i> = 12)	-	Lamotrigine ( <i>n</i> = 1) 1000 mg/d ( <i>n</i> = 3)	Valproate 150-600 mg/d	Haloperidol ( <i>n</i> = 1) Sertraline 75 mg/d ( <i>n</i> = 1)
Osborne <i>et al</i> [41]	2015	20	M	400 mg/d	140 ng/mL	130 ng/mL	Myoclonus	-	-	-	-
				400 mg/d	180 ng/mL	150 ng/mL	GTCS	-	Valproate 1000 mg/d	475 mg/d	-
Bolu <i>et al</i> [29]	2017	29	M	200 mg/d	-	-	TCS	Bilateral diffuse epileptic activity	Valproate 1000 mg/d	100 mg/d	-
Rachamallu <i>et al</i> [54]	2017	16	M	350 mg/d	-	-	Orofacial dyskinesia with perioral twitching	-	-	-	-
				400 mg/d	-	-	Stuttering	Several episodes of generalized spike	Valproate 1000 mg/d	450 mg/d	-
Borah <i>et al</i> [30]	2019	42	F	300 mg/d	-	-	Twitching and urinary incontinence	-	-	250 mg/d	Haloperidol 10 mg/d
Chochol <i>et al</i> [55]	2019	57	M	600 mg/d	866 ng/mL	301 ng/mL	Myoclonus and stuttering	Bilateral sharp waves and slow wave complexes	-	300 mg/d	Risperidone 1.5 mg/d, Risperidone 37.5 mg every 2 wk

EEG: Electroencephalogram; M: Male; F: Female; GTCS: Generalized tonic-clonic seizure; TCS: Tonic-clonic seizure; ECT: Electroconvulsive therapy.

Web of Science) to review cases of clozapine-related seizure published between 2000 and 2019. A total of 18 studies were included (Table 1)[6,29-35], eight of which reported 14 cases of low-dose clozapine-related seizure.

Antiepileptic drugs (AEDs) are widely used in the treatment of clozapine-related seizures. Some authors believe that the dose of clozapine should be reduced by 40%-50% when a seizure occurs for the first time and that AEDs should not be started until the second seizure is observed[36]. In clinical cases, dose reduction may lead to recurrence of psychiatric symptoms[37]. There are also studies suggesting that the continued use of clozapine is beneficial for patients and that AEDs starting at a dosage of 500 mg/d should be used[5]. However, the use of AEDs such as lamotrigine[38], levetiracetam[38] and topiramate[39] may increase the risk of mental illness through increasing central dopamine activity[40], and drug interactions may lead to other adverse reactions[24]. Thus, AEDs are not recommended as the main preventive agents before the occurrence of clozapine-related seizure[24].

Valproate, a broad-spectrum AED, is currently widely regarded as the first choice for the treatment of clozapine-related seizure and has a significant therapeutic effect on GTCS[5] and myoclonus[33,41]. Valproate is especially suitable for patients with affective disorders because of its emotional stabilization and antimania effects[42]. Interestingly, valproic acid can reduce clozapine plasma concentrations[5,25,41],



allowing patients to continue to use it safely. It also allows clozapine-treated patients to remain seizure-free.

Electroconvulsive therapy involves stimulation of the brain through electric currents and has been reported to increase the levels of dopamine and its metabolites[43]. Electroconvulsive therapy has been regarded as an effective treatment[44] for mental illness since the 1930s, and it can effectively reduce the frequency of seizures in patients that show insufficient responses to AEDs[45]. In addition, intracranial electroencephalographic monitoring has been found to have important clinical value in human experimental reports, and it may be used in the monitoring of drug-related seizures in the future[46]. Monitoring still has some potential safety risks that need to be further studied and reduced[46].

## CONCLUSION

This case demonstrates the clinical presentation of and effective treatments for low-dose clozapine-related seizure followed by aspiration pneumonia. We reviewed the associated literature to identify the influencing factors and summarized the research progress of clozapine-related seizure to potentially provide ideas for early clinical prevention and treatment (Table 2)[6,29-35,41,47-55]. Given the limited nature of case reports and the urgent clinical need, this field should be taken seriously and further studied.

## REFERENCES

- 1 **Schrader JM**, Irving CM, Octeau JC, Christian JA, Aballo TJ, Kareemo DJ, Conti J, Camberg JL, Lane JR, Javitch JA, Kovoov A. The differential actions of clozapine and other antipsychotic drugs on the translocation of dopamine D2 receptors to the cell surface. *J Biol Chem* 2019; **294**: 5604-5615 [PMID: 30670597 DOI: 10.1074/jbc.RA118.004682]
- 2 **Nucifora FC Jr**, Mihaljevic M, Lee BJ, Sawa A. Clozapine as a Model for Antipsychotic Development. *Neurotherapeutics* 2017; **14**: 750-761 [PMID: 28653280 DOI: 10.1007/s13311-017-0552-9]
- 3 **Taipale H**, Tanskanen A, Mehtälä J, Vattulainen P, Correll CU, Tiihonen J. 20-year follow-up study of physical morbidity and mortality in relationship to antipsychotic treatment in a nationwide cohort of 62,250 patients with schizophrenia (FIN20). *World Psychiatry* 2020; **19**: 61-68 [PMID: 31922669 DOI: 10.1002/wps.20699]
- 4 **Vermeulen JM**, van Rooijen G, van de Kerkhof MPJ, Sutherland AL, Correll CU, de Haan L. Clozapine and Long-Term Mortality Risk in Patients With Schizophrenia: A Systematic Review and Meta-analysis of Studies Lasting 1.1-12.5 Years. *Schizophr Bull* 2019; **45**: 315-329 [PMID: 29697804 DOI: 10.1093/schbul/sby052]
- 5 **Williams AM**, Park SH. Seizure associated with clozapine: incidence, etiology, and management. *CNS Drugs* 2015; **29**: 101-111 [PMID: 25537107 DOI: 10.1007/s40263-014-0222-y]
- 6 **Grover S**, Hazari N, Chakrabarti S, Avasthi A. Association of Clozapine with Seizures: A Brief Report Involving 222 Patients Prescribed Clozapine. *East Asian Arch Psychiatry* 2015; **25**: 73-78 [PMID: 26118746]
- 7 **Lertxundi U**, Hernandez R, Medrano J, Domingo-Echaburu S, García M, Aguirre C. Antipsychotics and seizures: higher risk with atypicals? *Seizure* 2013; **22**: 141-143 [PMID: 23146619 DOI: 10.1016/j.seizure.2012.10.009]
- 8 **Owen MJ**, Sawa A, Mortensen PB. Schizophrenia. *Lancet* 2016; **388**: 86-97 [PMID: 26777917 DOI: 10.1016/S0140-6736(15)01121-6]
- 9 **Schulz SC**, Murray A. Assessing cognitive impairment in patients with schizophrenia. *J Clin Psychiatry* 2016; **77** Suppl 2: 3-7 [PMID: 26919051 DOI: 10.4088/JCP.14074su1c.01]
- 10 **Brown S**, Kim M, Mitchell C, Inskip H. Twenty-five year mortality of a community cohort with schizophrenia. *Br J Psychiatry* 2010; **196**: 116-121 [PMID: 20118455 DOI: 10.1192/bjp.bp.109.067512]
- 11 **Hor K**, Taylor M. Suicide and schizophrenia: a systematic review of rates and risk factors. *J Psychopharmacol* 2010; **24**: 81-90 [PMID: 20923923 DOI: 10.1177/1359786810385490]
- 12 **Crump C**, Winkleby MA, Sundquist K, Sundquist J. Comorbidities and mortality in persons with schizophrenia: a Swedish national cohort study. *Am J Psychiatry* 2013; **170**: 324-333 [PMID: 23318474 DOI: 10.1176/appi.ajp.2012.12050599]
- 13 **Siskind D**, Siskind V, Kisely S. Clozapine Response Rates among People with Treatment-Resistant Schizophrenia: Data from a Systematic Review and Meta-Analysis. *Can J Psychiatry* 2017; **62**: 772-777 [PMID: 28655284 DOI: 10.1177/0706743717718167]
- 14 **Błaszczak B**, Czuczwar SJ. Epilepsy coexisting with depression. *Pharmacol Rep* 2016; **68**: 1084-1092 [PMID: 27634589 DOI: 10.1016/j.pharep.2016.06.011]

- 15 **Kovac S**, Walker MC. Recent advances in epilepsy. *J Neurol* 2014; **261**: 837-841 [PMID: [24590406](#) DOI: [10.1007/s00415-014-7294-y](#)]
- 16 **Hosp JA**, Hertler B, Atiemo CO, Luft AR. Dopaminergic modulation of receptive fields in rat sensorimotor cortex. *Neuroimage* 2011; **54**: 154-160 [PMID: [20643216](#) DOI: [10.1016/j.neuroimage.2010.07.029](#)]
- 17 **Pottoo FH**, Javed MN, Barkat MA, Alam MS, Nowshehri JA, Alshayban DM, Ansari MA. Estrogen and Serotonin: Complexity of Interactions and Implications for Epileptic Seizures and Epileptogenesis. *Curr Neuropsychopharmacol* 2019; **17**: 214-231 [PMID: [29956631](#) DOI: [10.2174/1570159X16666180628164432](#)]
- 18 **Alper K**, Schwartz KA, Kolts RL, Khan A. Seizure incidence in psychopharmacological clinical trials: an analysis of Food and Drug Administration (FDA) summary basis of approval reports. *Biol Psychiatry* 2007; **62**: 345-354 [PMID: [17223086](#) DOI: [10.1016/j.biopsych.2006.09.023](#)]
- 19 **Ifteni P**, Teodorescu A, Dima L, Burtea V. Rapid Titration of Clozapine in Schizophrenia and Bipolar Disorder. *Am J Ther* 2021; **28**: e224-e227 [PMID: [31567198](#) DOI: [10.1097/MJT.0000000000001073](#)]
- 20 **Lochhead JD**, Nelson MA, Schneider AL. Risks and Benefits of Rapid Clozapine Titration. *Ment Illn* 2016; **8**: 6457 [PMID: [27403276](#) DOI: [10.4081/mi.2016.6457](#)]
- 21 **Poyraz CA**, Özdemir A, Sağlam NG, Turan S, Poyraz BÇ, Tomruk N, Duran A. Rapid Clozapine Titration in Patients with Treatment Refractory Schizophrenia. *Psychiatr Q* 2016; **87**: 315-322 [PMID: [26433727](#) DOI: [10.1007/s11126-015-9394-y](#)]
- 22 **Ifteni P**, Correll CU, Nielsen J, Burtea V, Kane JM, Manu P. Rapid clozapine titration in treatment-refractory bipolar disorder. *J Affect Disord* 2014; **166**: 168-172 [PMID: [25012427](#) DOI: [10.1016/j.jad.2014.04.020](#)]
- 23 **Ulrich S**, Baumann B, Wolf R, Lehmann D, Peters B, Bogerts B, Meyer FP. Therapeutic drug monitoring of clozapine and relapse--a retrospective study of routine clinical data. *Int J Clin Pharmacol Ther* 2003; **41**: 3-13 [PMID: [12564740](#)]
- 24 **Caetano D**. Use of anticonvulsants as prophylaxis for seizures in patients on clozapine. *Australas Psychiatry* 2014; **22**: 78-83 [PMID: [23996793](#) DOI: [10.1177/1039856213502829](#)]
- 25 **Varma S**, Bishara D, Besag FM, Taylor D. Clozapine-related EEG changes and seizures: dose and plasma-level relationships. *Ther Adv Psychopharmacol* 2011; **1**: 47-66 [PMID: [23983927](#) DOI: [10.1177/2045125311405566](#)]
- 26 **Tang YL**, Mao P, Li FM, Li W, Chen Q, Jiang F, Cai ZJ, Mitchell PB. Gender, age, smoking behaviour and plasma clozapine concentrations in 193 Chinese inpatients with schizophrenia. *Br J Clin Pharmacol* 2007; **64**: 49-56 [PMID: [17298477](#)]
- 27 **Rajkumar AP**, Poonkuzhali B, Kuruvilla A, Jacob M, Jacob KS. Clinical predictors of serum clozapine levels in patients with treatment-resistant schizophrenia. *Int Clin Psychopharmacol* 2013; **28**: 50-56 [PMID: [23104241](#) DOI: [10.1097/YIC.0b013e32835ae9da](#)]
- 28 **Subramanian S**, Völm BA, Huband N. Clozapine dose for schizophrenia. *Cochrane Database Syst Rev* 2017; **6**: CD009555 [PMID: [28613395](#) DOI: [10.1002/14651858.CD009555.pub2](#)]
- 29 **Bolu A**, Akarsu S, Pan E, Aydemir E, Oznur T. Low-dose Clozapine-induced Seizure: A Case Report. *Clin Psychopharmacol Neurosci* 2017; **15**: 190-193 [PMID: [28449570](#) DOI: [10.9758/cpn.2017.15.2.190](#)]
- 30 **Borah AJ**, Kalita A, Dutta SK. Clozapine-induced seizure. *Indian J Pharmacol* 2019; **51**: 410-412 [PMID: [32029964](#) DOI: [10.4103/ijp.IJP\\_403\\_18](#)]
- 31 **Haberfellner EM**. Myoclonic and generalized tonic clonic seizures during combined treatment with low doses of clozapine and haloperidol. *Eur Psychiatry* 2002; **17**: 55-56 [PMID: [11918994](#)]
- 32 **Praharaj SK**, Venkatesh BG, Sarkhel S, Zia-ul-Haq M, Sinha VK. Clozapine-induced myoclonus: a case study and brief review. *Prog Neuropsychopharmacol Biol Psychiatry* 2010; **34**: 242-243 [PMID: [19833162](#) DOI: [10.1016/j.pnpbp.2009.10.006](#)]
- 33 **Horga G**, Horga A, Baeza I, Castro-Fornieles J, Lázaro L, Pons A. Drug-induced speech dysfluency and myoclonus preceding generalized tonic-clonic seizures in an adolescent male with schizophrenia. *J Child Adolesc Psychopharmacol* 2010; **20**: 233-234 [PMID: [20578939](#) DOI: [10.1089/cap.2009.0010](#)]
- 34 **Park S**, Lee MK. Successful electroconvulsive therapy and improvement of negative symptoms in refractory schizophrenia with clozapine-induced seizures: a case report. *Psychiatr Danub* 2014; **26**: 360-362 [PMID: [25377372](#)]
- 35 **Kikuchi YS**, Sato W, Ataka K, Yagisawa K, Omori Y, Kanbayashi T, Shimizu T. Clozapine-induced seizures, electroencephalography abnormalities, and clinical responses in Japanese patients with schizophrenia. *Neuropsychiatr Dis Treat* 2014; **10**: 1973-1978 [PMID: [25342906](#) DOI: [10.2147/NDT.S69784](#)]
- 36 **Wong J**, Delva N. Clozapine-induced seizures: recognition and treatment. *Can J Psychiatry* 2007; **52**: 457-463 [PMID: [17688010](#)]
- 37 **Murphy R**, Gallagher A, Sharma K, Ali T, Lewis E, Murray I, Hallahan B. Clozapine-induced stuttering: an estimate of prevalence in the west of Ireland. *Ther Adv Psychopharmacol* 2015; **5**: 232-236 [PMID: [26301079](#) DOI: [10.1177/2045125315590060](#)]
- 38 **Anzellotti F**, Franciotti R, Zhuzhuni H, D'Amico A, Thomas A, Onofri M. Nonepileptic seizures under levetiracetam therapy: a case report of forced normalization process. *Neuropsychiatr Dis Treat* 2014; **10**: 959-964 [PMID: [24926197](#) DOI: [10.2147/NDT.S60089](#)]
- 39 **Mula M**, Trimble MR. The importance of being seizure free: topiramate and psychopathology in epilepsy. *Epilepsy Behav* 2003; **4**: 430-434 [PMID: [12899865](#)]

- 40 **Kawakami Y**, Itoh Y. Forced Normalization: Antagonism Between Epilepsy and Psychosis. *Pediatr Neurol* 2017; **70**: 16-19 [PMID: [28460793](#) DOI: [10.1016/j.pediatrneurol.2017.02.007](#)]
- 41 **Osborne IJ**, McIvor RJ. Clozapine-induced myoclonus: a case report and review of the literature. *Ther Adv Psychopharmacol* 2015; **5**: 351-356 [PMID: [26834968](#) DOI: [10.1177/2045125315612015](#)]
- 42 **Brodtkorb E**, Mula M. Optimizing therapy of seizures in adult patients with psychiatric comorbidity. *Neurology* 2006; **67**: S39-S44 [PMID: [17190921](#)]
- 43 **Nikisch G**, Mathé AA. CSF monoamine metabolites and neuropeptides in depressed patients before and after electroconvulsive therapy. *Eur Psychiatry* 2008; **23**: 356-359 [PMID: [18455913](#) DOI: [10.1016/j.eurpsy.2008.03.003](#)]
- 44 **Stefanou MI**, Vittore D, Wolz I, Klingberg S, Wildgruber D. Recurrent Episodes of Paraphilic Behavior Possibly Associated With Olanzapine and Aripiprazole Treatment in a Patient With Schizophrenia. *Front Psychiatry* 2020; **11**: 318 [PMID: [32425825](#) DOI: [10.3389/fpsy.2020.00318](#)]
- 45 **Chi SH**, Jeong HG, Lee S, Oh SY, Kim SH. Effects of Psychotropic Drugs on Seizure Threshold during Electroconvulsive Therapy. *Psychiatry Investig* 2017; **14**: 647-655 [PMID: [29042890](#) DOI: [10.4306/pi.2017.14.5.647](#)]
- 46 **Cook MJ**, O'Brien TJ, Berkovic SF, Murphy M, Morokoff A, Fabinyi G, D'Souza W, Yerra R, Archer J, Litewka L, Hosking S, Lightfoot P, Ruedebusch V, Sheffield WD, Snyder D, Leyde K, Himes D. Prediction of seizure likelihood with a long-term, implanted seizure advisory system in patients with drug-resistant epilepsy: a first-in-man study. *Lancet Neurol* 2013; **12**: 563-571 [PMID: [23642342](#) DOI: [10.1016/S1474-4422\(13\)70075-9](#)]
- 47 **Usiskin SI**, Nicolson R, Lenane M, Rapoport JL. Gabapentin prophylaxis of clozapine-induced seizures. *Am J Psychiatry* 2000; **157**: 482-483 [PMID: [10698845](#)]
- 48 **Navarro V**, Pons A, Romero A, Bernardo M. Topiramate for clozapine-induced seizures. *Am J Psychiatry* 2001; **158**: 968-969 [PMID: [11384919](#)]
- 49 **Duggal HS**, Jagadheesan K, Nizamie SH. Clozapine-induced stuttering and seizures. *Am J Psychiatry* 2002; **159**: 315 [PMID: [11823281](#)]
- 50 **Foster R**, Olajide D. A case of clozapine-induced tonic-clonic seizures managed with valproate: implications for clinical care. *J Psychopharmacol* 2005; **19**: 93-96 [PMID: [15671134](#)]
- 51 **Begum M**. Clozapine-induced stuttering, facial tics and myoclonic seizures: a case report. *Aust N Z J Psychiatry* 2005; **39**: 202 [PMID: [15701074](#)]
- 52 **Muzyk A**, Gala G, Kahn DA. Use of lamotrigine in a patient with a clozapine-related seizure. *J Psychiatr Pract* 2010; **16**: 125-128 [PMID: [20511737](#) DOI: [10.1097/01.pra.0000369974.18274.e2](#)]
- 53 **Leung JG**, Nelson S, Takala CR, Gören JL. Infection and inflammation leading to clozapine toxicity and intensive care: a case series. *Ann Pharmacother* 2014; **48**: 801-805 [PMID: [24619948](#) DOI: [10.1177/1060028014526701](#)]
- 54 **Rachamalla V**, Haq A, Song MM, Aligeti M. Clozapine-Induced Microseizures, Orofacial Dyskinesia, and Speech Dysfluency in an Adolescent with Treatment Resistant Early Onset Schizophrenia on Concurrent Lithium Therapy. *Case Rep Psychiatry* 2017; **2017**: 7359095 [PMID: [28835863](#) DOI: [10.1155/2017/7359095](#)]
- 55 **Chochol MD**, Kataria L, O'Rourke MC, Lamotte G. Clozapine-Associated Myoclonus and Stuttering Secondary to Smoking Cessation and Drug Interaction: A Case Report. *J Clin Psychopharmacol* 2019; **39**: 275-277 [PMID: [30925500](#) DOI: [10.1097/JCP.0000000000001032](#)]



Published by **Baishideng Publishing Group Inc**  
7041 Koll Center Parkway, Suite 160, Pleasanton, CA 94566, USA

**Telephone:** +1-925-3991568

**E-mail:** [bpgoffice@wjgnet.com](mailto:bpgoffice@wjgnet.com)

**Help Desk:** <https://www.f6publishing.com/helpdesk>

<https://www.wjgnet.com>

