

RESPONSE:

We wish to re-submit the manuscript titled "Inverted Meckel's diverticulum diagnosed using capsule endoscopy." We would like to thank the reviewers and the editor for the positive and constructive comments and suggestions. The manuscript has benefited from these insightful suggestions. In the following pages, we have added the requested information based on your comments: a shorter title, suspicion signs of inverted Meckel's diverticulum via capsule endoscopy with a more detailed description and we changed the term tumor to bulge as suggested, the size in mm of the protruding lesion, arguments for diagnosis like the clinical suspicion by this presentation, clarified that the capsule endoscopy images correspond to an inverted Meckel's and corrected references.

We hope that the revisions in the manuscript and our accompanying responses will be sufficient to make our manuscript suitable for publication in World Journal of gastroenterology.

Sincerely,

Ismael El Hajra.

Title: Inverted Meckel's diverticulum diagnosed using capsule endoscopy.

Authors: Ismael El Hajra, Marta Calvo, Jose L Martinez Porras, Lucia Gomez-Pimpollo Garcia, Jose L Rodriguez, Carmen Leon, Jose L Calleja Panero.

Ismael El Hajra, Marta Calvo, Jose L Martinez Porras, Jose L Calleja Panero,
Department of Gastroenterology, Hospital Universitario Puerta de Hierro,
Majadahonda, Madrid 28222, Spain.

Lucia Gomez-Pimpollo Garcia, Department of Radiology, Hospital Universitario
Puerta de Hierro, Majadahonda, Madrid 28222, Spain.

Jose L Rodriguez, Department of Diagnostic Pathology Hospital Universitario
Puerta de Hierro, Majadahonda, Madrid 28222, Spain.

Carmen Leon, Department of Surgery, Hospital Universitario Puerta de Hierro,
Majadahonda, Madrid 28222, Spain.

Author contributions: El Hajra I and Calvo M contributed to the paper design, manuscript drafting and reviewed the literature; Martinez JL performed capsule endoscopy, interpretation and revision of the manuscript, Gomez-Pimpollo L contributed to analyzed and interpreted the imaging findings and revision of the manuscript; Rodriguez JL contributed to the pathological examination and revision of the manuscript; Leon C performed laparoscopic surgery and manuscript drafting, Calleja and Calvo M were responsible for the revision of the manuscript for

important intellectual content; all authors issued final approval for the version to be submitted.

Corresponding author:

Marta Calvo, Department of Gastroenterology, Hospital Puerta de Hierro, Calle Joaquín Rodrigo, 1, 28222 Majadahonda, Madrid, Spain.

Telephone:

calvo.marta@gmail.com

Word count: 1822

Conflicts of interest: The authors declare that they have no conflict of interest.

Funding: The authors received no funding for the conduct of the study.

Informed consent statement: The patient has provided permission to publish this paper, and the identity of the patient has been protected.

ABSTRACT

BACKGROUND

Meckel's diverticulum is a common asymptomatic congenital gastrointestinal anomaly. However, its presentation as an inverted Meckel's diverticulum is a rare complication of which few cases have been reported in the literature.

CASE SUMMARY

Here, we report the case of an 33-year-old men with an iron deficiency anemia without manifestation of gastrointestinal bleeding. An upper gastrointestinal endoscopy and total colonoscopy were performed, but no abnormalities were found within the observed area. Finally a capsule endoscopy was performed and offered us a clue to subsequently confirm the diagnosis of inverted Meckel's diverticulum with a TC scan. Laparoscopic intestinal resection surgery was performed. The final pathology report described a Meckel's diverticulum.

CONCLUSION

Since it is an uncommon disease and its clinical presentation is not specific, it may go undetected in capsule endoscopy. Successful diagnosis and treatment of this disease requires a high index of clinical suspicion.

Keywords: Inverted Meckel's diverticulum; Capsule endoscopy; Anemia study; Small bowel tumor.

Core tip: Inverted Meckel's diverticulum is an uncommon disease with a wide spectrum of accompanying non-specific symptoms. We present herein, a case of an iron deficiency anemia with a negative endoscopic study, in which capsule endoscopy played a key role to confirm the diagnosis of inverted Meckel's diverticulum. Since it is an uncommon disease with few cases described in the literature, this report aims to contribute more information concerning the clinical characteristics, radiological and capsule endoscopy findings of inverted Meckel's diverticulum that can help clinicians make the correct diagnosis.

INTRODUCTION

Meckel's diverticulum is a common congenital gastrointestinal anomaly which is a remanent of the omphalomesenteric duct [1]. It is often within 100 cm of the ileocecal valve and located in the antimesenteric surface of the ileum [2]. According to autopsy studies, this condition is found in 0.3-2% of the general population [3,4].

Patients with Meckel's diverticulum are usually asymptomatic. However, up to 6.4% develop complications that require surgery [5]. The most common complications are gastrointestinal bleeding in association with ectopic gastric and/or pancreatic mucosa, intestinal obstruction, intussusceptions, diverticulitis or volvulus. The inversion of the Meckel's diverticulum is a rare complication with a pathophysiology not clearly understood that can be a clinical challenge given its diagnostic difficulty. Moreover, the clinical presentation is nonspecific, the most frequent mode of presentation being intussusception, abdominal pain, anemia or gastrointestinal bleeding [6].

Although Meckel's diverticulum is the most common congenital anomaly of the small bowel, inversion or invagination of the diverticulum is a rare occurrence. To

date, there are only around one hundred cases in literature that demonstrate the presence of inverted Meckel's diverticulum.

Here we present the case of an iron deficiency anemia without manifestation of gastrointestinal bleeding, in which capsule endoscopy played a key role in the final diagnosis.

CASE PRESENTATION

Chief complaints

A 33-year-old male with no significant medical history presented to the emergency room with progressive weakness, easy fatigability and headache.

He had no evidence of lower or upper gastrointestinal bleeding and he reported no abdominal pain, nausea, vomiting, anorexia, fever or weight loss.

History of present illness

Patient's symptoms started a three weeks ago and had been worsened the last four days.

Physical examination

In the emergency room, the patient was clinically stable, with a normal temperature (36.7°C). The patient exhibited an oxygen saturation level of 97% while he was breathing ambient air. His blood pressure was 102/61 mm Hg and his heart rate 91 beats per minute. The patient was awake, alert, and fully oriented. Physical examination revealed signs of pallor and an absence of lymphadenopathy,

hepatosplenomegaly, bone tenderness or jaundice. Examination of the rectum revealed a few external hemorrhoids, but there was no blood or melena in the rectal vault; there were no skin tags, fissures or palpable masses.

Laboratory examinations

The initial laboratory findings showed low hemoglobin levels (7 g/dL), a white blood cell count of 11,250 per mm³, a platelet count of 221,000 per mm³ and a C-reactive protein of 1.31 mg/dL. Two pints of packed red blood cells were therefore transfused and the patient was admitted to the gastroenterology department. Electrocardiography (ECG) showed sinus rhythm at 93 beats per minute and the results of the patient's chest radiography were normal.

The patient's next blood test, showed a mean corpuscular volume of 72.5 fl, a mean corpuscular hemoglobin of 25.6 pg, and a reticulocyte count of 1%. The patient's iron level was 38 µg/dL, his ferritin level was 17 ng/mL and his transferrin saturation was 9%. The hemolysis study was negative. Hence, the patient's anemia was classified as iron deficiency anemia.

Endoscopy examinations

During this period, an upper gastrointestinal endoscopy and a colonoscopy were performed to study the patient's anemia. The colonoscopy revealed internal hemorrhoids without any other relevant findings while the upper gastrointestinal endoscopy showed no abnormalities. The patient remained stable and was discharged and the study was completed on an outpatient basis with oral iron treatment.

Further diagnostic work-up

During his visit to the outpatient clinic three weeks later, the patient remained anemic with a hemoglobin level of 8,8 g/dL. The anemia study was completed with a capsule endoscopy which revealed a lifted erosion and mild bulge in the ileum of approximately 8-9 mm in size (Fig. 1 and Fig. 2). These findings of appearance of a subepithelial bulge in the ileum suggested an inverted Meckel diverticulum. Normal intestinal mucosa was seen on the surface of the tumor with a longer small intestine transit time suggestive of Meckel's diverticulum. A technetium-99m pertechnetate radioisotope scintigraphy (Meckel's scan) was performed and was negative. The patient subsequently underwent an ultrasound examination, which revealed no pathological findings. Finally, an abdominal CT was performed and showed a central area of fat attenuation surrounded by a thick collar of soft tissue attenuation (Fig. 3) suggestive of inverted Meckel's diverticulum.

FINAL DIAGNOSIS AND TREATMENT

The patient was diagnosed with an inverted Meckel's diverticulum and underwent a laparoscopic surgery. A large intraluminal polyp-like mass in the mid-ileum was observed. The remainder of the small bowel was normal to the level of the ligament of Treitz. A segmentary resection of the small bowel with adequate margin was performed and side-to-side anastomosis was carried out using a stapling device.

On gross examination, the specimen consisted of a segmental resection of the small bowel of 8x4x2.6 cm with a sausage-shaped polypoid lesion.

Histological examination (Fig. 4) showed a polypoid lesion, with a central fatty and collagenous core lined with an intestinal type mucosa. A central area of ulceration was seen, with no presence of gastric or pancreatic heterotopia. The final pathology report described a Meckel's diverticulum.

The patient had an uneventful postoperative course and was discharged four days after surgery.

DISCUSSION

Meckel's diverticulum is the most common congenital anomaly in the gastrointestinal tract [1] and is often incidentally discovered during evaluations performed for other reasons as it is usually an asymptomatic condition. However, complications can occur in up to 6.4% of patients [7]. These are more frequent in the pediatric population and mainly involve bowel obstruction with or without intussusception, gastrointestinal hemorrhage, diverticulitis and Inflammation and Littre hernia (hernia involving the bowel segment bearing Meckel's) [7, 8].

Inverted Meckel's diverticulum is an unusual condition that is not yet clearly understood and there are no more than 100 cases reported in literature.

It has been proposed that the mechanism that could produce the inversion is an abnormal peristaltic movement around an ulceration or ectopic tissue. Nevertheless, no ectopic tissue was found in 41% of patients with inverted Meckel's diverticulum [6]. In this regard, tc-99m pertechnetate scintigraphy can help detect ectopic gastric mucosa and has been used for years as a diagnostic method for Meckel's diverticulum, especially in children, with a sensitivity of 92.1% and a specificity of

95.4% [9]. In adults, the sensitivity of this method is significantly less (54%) [10]. No cases of diagnosis of inverted Meckel's diverticulum by scintigraphy have been described, while there is even one case with gastric and pancreatic mucosa in the histopathological sample where the scintigraphy was negative [11]. Our patient's scintigraphy was negative. Therefore, this suggests that a negative scan does not preclude the presence of ectopic mucosa and the diagnosis of possible inverted Meckel's diverticulum.

This inversion of the Meckel's diverticulum can lead to a complete intussusception of the bowel or compromise blood flow to that bowel, ulceration and then gastrointestinal bleeding. The bleeding can also be explained by repetitive mechanical trauma to the mucosa from the reversible intussusception.

As in our patient, anemia or gastrointestinal bleeding are the most frequent clinical manifestations, found in up to 80% of patients [6]. This usually leads to an upper and lower gastrointestinal endoscopy where the cause of the bleeding cannot be found.

Other clinical manifestations which can occur are abdominal pain (68%) and intussusception (39%). The median age of presentation is 27.7, younger than reported in Meckel's diverticulum, which was 33, with a male to female ratio of approximately 2.33:1 [6]

Regarding the diagnostic tools, abdominal ultrasonography can contribute to the diagnosis, but often shows non-specific findings such as thickened intestinal wall, fluid filled target or distended loops of bowel [12, 13]. In our case abdominal ultrasonography revealed no pathological findings.

One of the most useful tools is a CT scan. It usually shows a thickened small intestinal wall, with an elongated, intraluminal, fat-attenuating lesion [14] as in our case. In the case of intussusceptions, a CT scan is especially useful as it can reveal the characteristic “target sign”. Inverted Meckel’s diverticulum is sometimes confused with a lipoma on CT scans because it also consists of macroscopic fatty tissue. However, in most cases, abdominal CT scans provide useful information for the diagnosis and treatment of inverted Meckel’s diverticulum [6].

Capsule endoscopy has recently been considered a useful diagnostic tool for diagnosing Meckel’s diverticulum [10, 15, 16]. However, the role of capsule endoscopy in the identification of Meckel’s diverticulum is not yet clear with only a few case reports and cases series available. Furthermore, in the case of inverted Meckel’s diverticulum, the information is very limited, with only two case reports [17, 18]. The capsule findings compatible with inverted Meckel’s diverticulum were described as an elevated lesion with normal mucosa [17] or as pedunculated polyp [18].

In our case, the capsule endoscopy images were similar (a subepithelial protruding lesion in the ileum with the presence of blood, hematin, ulcer or erosion) and offered us a clue to subsequently confirm the diagnosis of inverted Meckel’s diverticulum. In addition, the clinical suspicion due to the clinical characteristics such as the fact that he was a young man with anemia and a negative endoscopic study was of great importance for the diagnosis of inverted meckel’s diverticulum.

Regarding the risk of possible intestinal obstruction of the endoscopic capsule due to Meckel’s diverticulum, no events have been described.

Surgery is the treatment of choice for symptomatic Meckel's diverticulum. The general consensus is that it should be treated with resection. In the case of asymptomatic Meckel's diverticulum, there is some debate. Resection is generally recommended for patients younger than 40, diverticulum longer than 2 cm, diverticula with narrow necks, fibrous bands, ectopic gastric tissue, and/or when the diverticulum appears thickened and inflamed [4, 6, 19].

It is important to note that in cases of anemia without abdominal pain like that of our patient, it may take a long time for the patient to be diagnosed with inverted Meckel's diverticulum given that it is an unusual condition with a non-specific clinical presentation. Capsule endoscopy is usually performed in those patients with anemia with a normal upper and lower gastrointestinal endoscopy. However, if clinicians are unaware of the characteristics of this lesion, it may go undetected since it is an uncommon disease. Therefore, this report aims to contribute more information concerning the clinical characteristics, radiological findings and especially, the capsule endoscopy findings of inverted Meckel's diverticulum that can help clinicians suspect that this disease is present and enable them to establish a definitive diagnosis.

CONCLUSION

To date, inverted Meckel's diverticulum is a pathology that is still not completely well known, with few cases described in the literature. Its clinical presentation is not specific, its most frequent symptoms being anemia or lower gastrointestinal bleeding. Patients are often given an upper and lower gastrointestinal endoscopy which reveals no abnormalities and a subsequent capsule endoscopy. Therefore,

increased awareness of the disease and a greater understanding of the features of this lesion in capsule endoscopy findings could ultimately help clinicians make the correct diagnosis.

REFERENCES:

- 1) Sagar J, Kumar V, Shah DK. Meckel's diverticulum: a systematic review. J R Soc Med. 2006 Oct;99(10):501-5. doi: 10.1258/jrsm.99.10.501. Erratum in: J R Soc Med. 2007 Feb;100(2):69. PMID: 17021300; PMCID: PMC1592061.
- 2) Karadeniz Cakmak G, Emre AU, Tascilar O, Bektaş S, Uçan BH, Irkorucu O, Karakaya K, Ustundag Y, Comert M. Lipoma within inverted Meckel's diverticulum as a cause of recurrent partial intestinal obstruction and hemorrhage: a case report and review of literature. World J Gastroenterol. 2007 Feb 21;13(7):1141-3. doi: 10.3748/wjg.v13.i7.1141. PMID: 17373755; PMCID: PMC4146883.
- 3) WEINSTEIN EC, CAIN JC, REMINE WH. Meckel's diverticulum: 55 years of clinical and surgical experience. JAMA. 1962 Oct 20;182:251-3. doi: 10.1001/jama.1962.03050420027007. PMID: 13999637.
- 4) Park JJ, Wolff BG, Tollefson MK, Walsh EE, Larson DR. Meckel diverticulum: the Mayo Clinic experience with 1476 patients (1950-2002). Ann Surg 2005; 241: 529-533 [PMID: 15729078 DOI: 10.1097/01.sla.0000154270.14308.5f]
- 5) Cullen JJ, Kelly KA, Moir CR, Hodge DO, Zinsmeister AR, Melton LJ 3rd. Surgical management of Meckel's diverticulum. An epidemiologic, population-based

study. *Ann Surg* 1994; 220:564-8; discussion 568-9 [PMID: 7944666 DOI: 10.1016/0022-3468(95)90190-6]

6) Rashid OM, Ku JK, Nagahashi M, Yamada A, Takabe K. Inverted Meckel's diverticulum as a cause of occult lower gastrointestinal hemorrhage. *World J Gastroenterol*. 2012 Nov 14; 18(42):6155-9. doi: 10.3748/wjg.v18.i42.6155. PMID: 23155346; PMCID: PMC3496894.

7) Hansen CC, Søreide K. Systematic review of epidemiology, presentation, and management of Meckel's diverticulum in the 21st century. *Medicine (Baltimore)*. 2018 Aug;97(35):e12154. doi: 10.1097/MD.00000000000012154. PMID: 30170459; PMCID: PMC6392637.

8) Park JJ, Wolff BG, Tollefson MK, Walsh EE, Larson DR. Meckel diverticulum: the Mayo Clinic experience with 1476 patients (1950-2002). *Ann Surg*. 2005 Mar;241(3):529-33. doi: 10.1097/01.sla.0000154270.14308.5f. PMID: 15729078; PMCID: PMC1356994.

9) Hosseinnezhad T, Shariati F, Treglia G, Kakhki VR, Sadri K, Kianifar HR, Sadeghi R. ^{99m}Tc-Pertechnetate imaging for detection of ectopic gastric mucosa: a systematic review and meta-analysis of the pertinent literature. *Acta Gastroenterol Belg*. 2014 Sep;77(3):318-27. PMID: 25509203.

10) Krstic SN, Martinov JB, Sokic-Milutinovic AD, Milosavljevic TN, Krstic MN. Capsule endoscopy is useful diagnostic tool for diagnosing Meckel's diverticulum. *Eur J Gastroenterol Hepatol*. 2016 Jun;28(6):702-7. doi: 10.1097/MEG.0000000000000603. PMID: 26854797.

- 11) Dujardin M, de Beeck BO, Osteaux M. Inverted Meckel's diverticulum as a leading point for ileoileal intussusception in an adult: case report. *Abdom Imaging*. 2002 Sep-Oct;27(5):563-5. doi: 10.1007/s00261-001-0070-3. PMID: 12172999.
- 12) El-Dhuwaib Y, O'Shea S, Ammori BJ. Laparoscopic reduction of an ileoileal intussusception and resection of an inverted Meckel's diverticulum in an adult. *Surg Endosc*. 2003 Jul;17(7):1157. doi: 10.1007/s00464-002-4284-4. Epub 2003 May 6. PMID: 12728389.
- 13) Karahasanoglu T, Memisoglu K, Korman U, Tunckale A, Curgunlu A, Karter Y. Adult intussusception due to inverted Meckel's diverticulum: laparoscopic approach. *Surg Laparosc Endosc Percutan Tech*. 2003 Feb;13(1):39-41. doi: 10.1097/00129689-200302000-00009. PMID: 12598757.
- 14) Takagaki K, Osawa S, Ito T, Iwaizumi M, Hamaya Y, Tsukui H, Furuta T, Wada H, Baba S, Sugimoto K. Inverted Meckel's diverticulum preoperatively diagnosed using double-balloon enteroscopy. *World J Gastroenterol*. 2016 May 7;22(17):4416-20. doi: 10.3748/wjg.v22.i17.4416. PMID: 27158212; PMCID: PMC4853701.
- 15) Wu J, Huang Z, Wang Y, Tang Z, Lai L, Xue A, Huang Y. Clinical features of capsule endoscopy in 825 children: A single-center, retrospective cohort study. *Medicine (Baltimore)*. 2020 Oct 23;99(43):e22864. doi: 10.1097/MD.00000000000022864. PMID: 33120825; PMCID: PMC7581167.
- 16) Lin L, Liu K, Liu H, Wu J, Zhang Y. Capsule endoscopy as a diagnostic test for Meckel's diverticulum. *Scand J Gastroenterol*. 2019 Jan;54(1):122-127. doi: 10.1080/00365521.2018.1553353. Epub 2019 Jan 13. PMID: 30638099.

- 17) Ibuka T, Araki H, Sugiyama T, Takada J, Kubota M, Shirakami Y, Shiraki M, Shimizu M, Suzui N, Miyazaki T. [A case of an elderly patient with inverted Meckel's diverticulum with small intestinal bleeding detected using capsule and double-balloon endoscopies]. *Nihon Shokakibyo Gakkai Zasshi*. 2017;114(11):2005-2011. Japanese. doi: 10.11405/nisshoshi.114.2005. PMID: 29109349.
- 18) Payeras Capó MA, Ambrona Zafra D, Garrido Durán C. Inverted Meckel's diverticulum in an adult patient diagnosed via capsule endoscopy. *Rev Esp Enferm Dig*. 2018 Mar;110(3):210-211. doi: 10.17235/reed.2018.5347/2017. PMID: 29368940.
- 19) Lequet J, Menahem B, Alves A, Fohlen A, Mulliri A. Meckel's diverticulum in the adult. *J Visc Surg*. 2017 Sep;154(4):253-259. doi: 10.1016/j.jviscsurg.2017.06.006. Epub 2017 Jul 9. PMID: 28698005.

FIGURES:

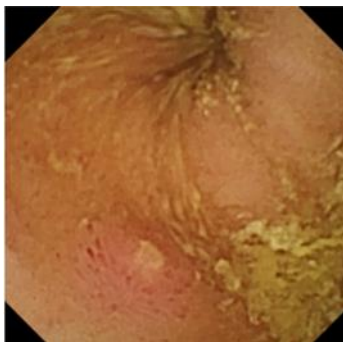


Fig. 1: Capsule endoscopy with protruding lesion with a depressed erosion at the tip suggestive of inverted Meckel's diverticulum.

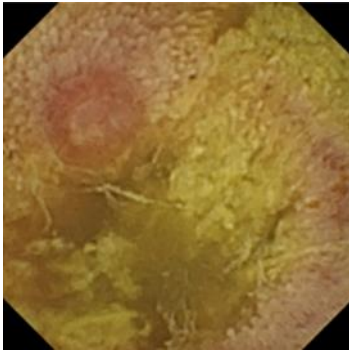


Fig. 2: Capsule endoscopy with protruding lesion suggestive of inverted Meckel's diverticulum.

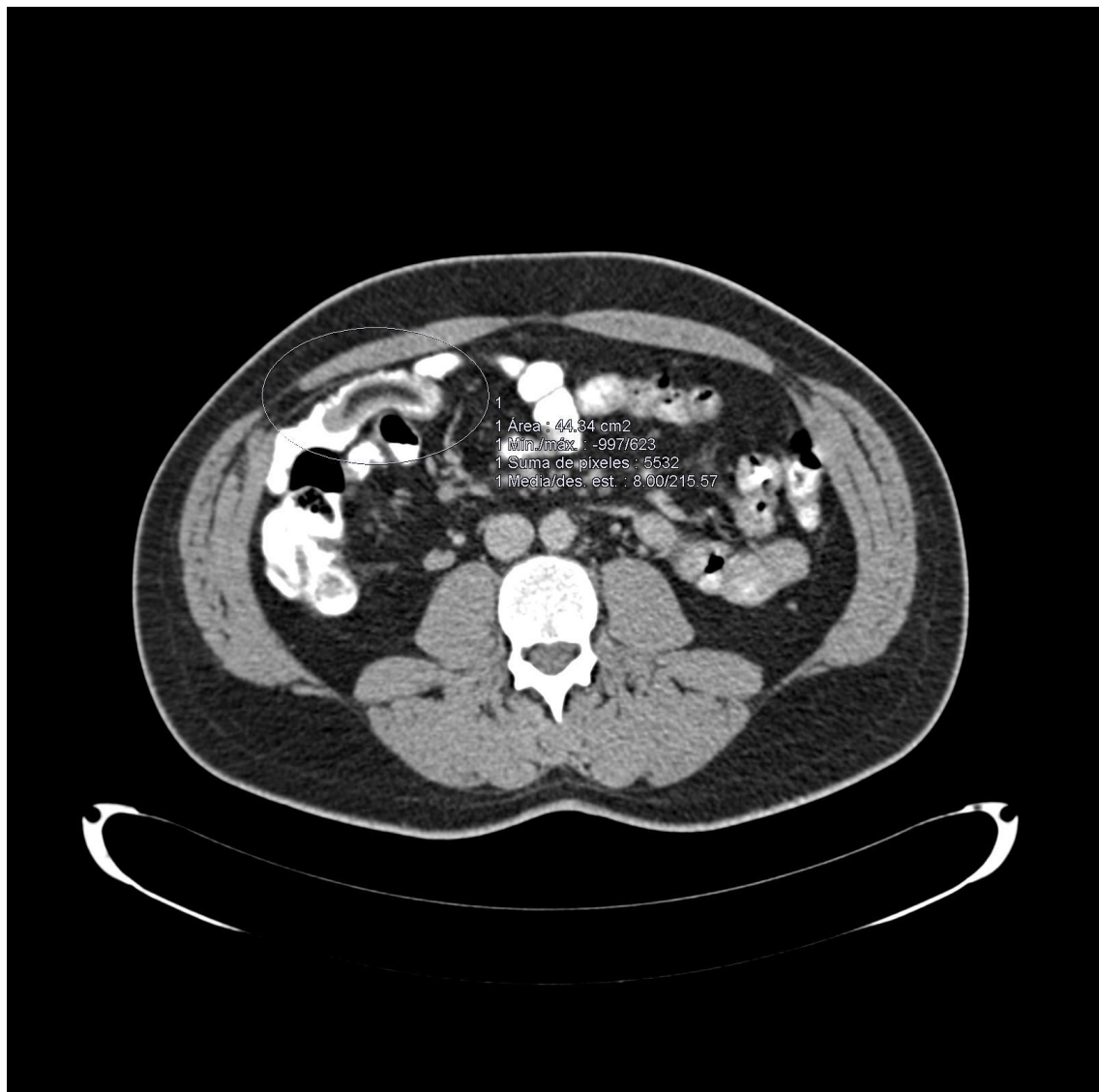

Fig. 3: Abdominal CT scan reveals a central area of fat attenuation surrounded by a thick collar of soft tissue attenuation suggestive of Meckel's Diverticulum.

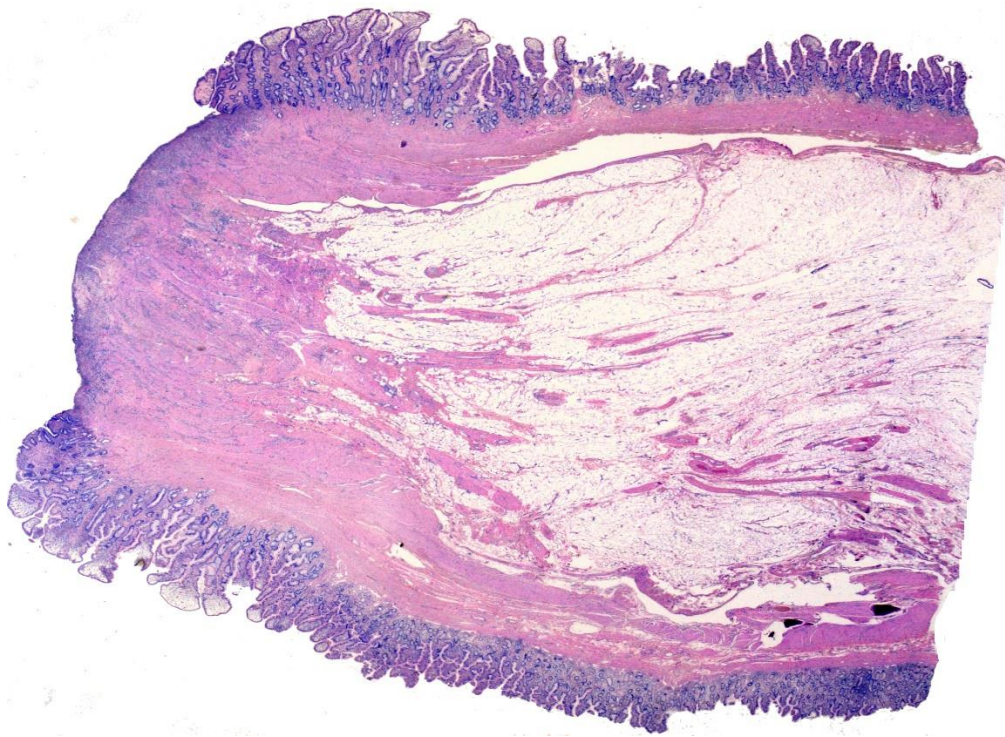


Fig. 4: Low power histologic examination of a polypoid lesion lined by an intestinal type mucosa with a central ulcerated area. No gastric or pancreatic heterotopic tissue can be found.