

# World Journal of *Clinical Cases*

*World J Clin Cases* 2022 January 7; 10(1): 1-396



### MINIREVIEWS

- 1 Omicron variant (B.1.1.529) of SARS-CoV-2: Mutation, infectivity, transmission, and vaccine resistance  
*Ren SY, Wang WB, Gao RD, Zhou AM*
- 12 Hepatitis B virus reactivation in rheumatoid arthritis  
*Wu YL, Ke J, Zhang BY, Zhao D*
- 23 Paradoxical role of interleukin-33/suppressor of tumorigenicity 2 in colorectal carcinogenesis: Progress and therapeutic potential  
*Huang F, Chen WY, Ma J, He XL, Wang JW*

### ORIGINAL ARTICLE

#### Case Control Study

- 35 Changes in rheumatoid arthritis under ultrasound before and after sinomenine injection  
*Huang YM, Zhuang Y, Tan ZM*
- 43 Benefits of multidisciplinary collaborative care team-based nursing services in treating pressure injury wounds in cerebral infarction patients  
*Gu YH, Wang X, Sun SS*

#### Retrospective Study

- 51 Outcomes and complications of open, laparoscopic, and hybrid giant ventral hernia repair  
*Yang S, Wang MG, Nie YS, Zhao XF, Liu J*
- 62 Surgical resection of intradural extramedullary tumors in the atlantoaxial spine *via* a posterior approach  
*Meng DH, Wang JQ, Yang KX, Chen WY, Pan C, Jiang H*
- 71 Vancomycin lavage for the incidence of acute surgical site infection following primary total hip arthroplasty and total knee arthroplasty  
*Duan MY, Zhang HZ*
- 79 Distribution of transient receptor potential vanilloid-1 channels in gastrointestinal tract of patients with morbid obesity  
*Atas U, Erin N, Tazegul G, Elpek GO, Yıldırım B*
- 91 Value of neutrophil-lymphocyte ratio in evaluating response to percutaneous catheter drainage in patients with acute pancreatitis  
*Gupta P, Das GC, Bansal A, Samanta J, Mandavdhare HS, Sharma V, Naseem S, Gupta V, Yadav TD, Dutta U, Varma N, Sandhu MS, Kochhar R*

- 104** Influence of overweight and obesity on the mortality of hospitalized patients with community-acquired pneumonia  
*Wang N, Liu BW, Ma CM, Yan Y, Su QW, Yin FZ*
- 117** Minimally invasive open reduction of greater tuberosity fractures by a modified suture bridge procedure  
*Kong LP, Yang JJ, Wang F, Liu FX, Yang YL*
- 128** Increased levels of lactate dehydrogenase and hypertension are associated with severe illness of COVID-19  
*Jin ZM, Shi JC, Zheng M, Chen QL, Zhou YY, Cheng F, Cai J, Jiang XG*
- 136** Age, alcohol, sex, and metabolic factors as risk factors for colonic diverticulosis  
*Yan Y, Wu JS, Pan S*
- 143** Evaluation of right-to-left shunt on contrast-enhanced transcranial Doppler in patent foramen ovale-related cryptogenic stroke: Research based on imaging  
*Xiao L, Yan YH, Ding YF, Liu M, Kong LJ, Hu CH, Hui PJ*
- 155** Characterization of focal hypermetabolic thyroid incidentaloma: An analysis with F-18 fluorodeoxyglucose positron emission tomography/computed tomography parameters  
*Lee H, Chung YS, Lee JH, Lee KY, Hwang KH*

### Clinical Trials Study

- 166** Low-dose intralesional injection of 5-fluorouracil and triamcinolone reduces tissue resident memory T cells in chronic eczema  
*Wu Y, Wang GJ, He HQ, Qin HH, Shen WT, Yu Y, Zhang X, Zhou ML, Fei JB*

### Observational Study

- 177** Alterations in blink and masseter reflex latencies in older adults with neurocognitive disorder and/or diabetes mellitus  
*Bricio-Barrios JA, Rios-Bracamontes E, Rios-Silva M, Huerta M, Serrano-Moreno W, Barrios-Navarro JE, Ortiz GG, Huerta-Trujillo M, Guzmán-Esquivel J, Trujillo X*
- 189** Predicting adolescent perfectionism: The role of socio-demographic traits, personal relationships, and media  
*Livazović G, Kuzmanović K*
- 205** Novel m.4268T>C mutation in the mitochondrial tRNA<sup>Leu</sup> gene is associated with hearing loss in two Chinese families  
*Zhao LJ, Zhang ZL, Fu Y*
- 217** Superior mesenteric venous thrombosis: Endovascular management and outcomes  
*Alnahhal K, Toskich BB, Nussbaum S, Li Z, Erben Y, Hakaim AG, Farres H*

### Randomized Controlled Trial

- 227** Zinc carnosine-based modified bismuth quadruple therapy *vs* standard triple therapy for *Helicobacter pylori* eradication: A randomized controlled study  
*Ibrahim N, El Said H, Choukair A*

## CASE REPORT

- 236** Acquired coagulation dysfunction resulting from vitamin K-dependent coagulation factor deficiency associated with rheumatoid arthritis: A case report  
*Huang YJ, Han L, Li J, Chen C*
- 242** Intraoperative thromboelastography-guided transfusion in a patient with factor XI deficiency: A case report  
*Guo WJ, Chen WY, Yu XR, Shen L, Huang YG*
- 249** Positron emission tomography and magnetic resonance imaging combined with computed tomography in tumor volume delineation: A case report  
*Zhou QP, Zhao YH, Gao L*
- 254** Successful response to camrelizumab in metastatic bladder cancer: A case report  
*Xie C, Yuan X, Chen SH, Liu ZY, Lu DL, Xu F, Chen ZQ, Zhong XM*
- 260** HER2 changes to positive after neoadjuvant chemotherapy in breast cancer: A case report and literature review  
*Wang L, Jiang Q, He MY, Shen P*
- 268** Hyper-accuracy three-dimensional reconstruction as a tool for better planning of retroperitoneal liposarcoma resection: A case report  
*Ye MS, Wu HK, Qin XZ, Luo F, Li Z*
- 275** Recurrent postmenopausal bleeding - just endometrial disease or ovarian sex cord-stromal tumor? A case report  
*Wang J, Yang Q, Zhang NN, Wang DD*
- 283** Complex proximal femoral fracture in a young patient followed up for 3 years: A case report  
*Li ZY, Cheng WD, Qi L, Yu SS, Jing JH*
- 289** Bilateral Hypertrophic Olivary Degeneration after Pontine Hemorrhage: A Case Report  
*Zheng B, Wang J, Huang XQ, Chen Z, Gu GF, Luo XJ*
- 296** Clinical characteristics and outcomes of primary intracranial alveolar soft-part sarcoma: A case report  
*Chen JY, Cen B, Hu F, Qiu Y, Xiao GM, Zhou JG, Zhang FC*
- 304** Removal of laparoscopic cerclage stitches *via* laparotomy and rivanol-induced labour: A case report and literature review  
*Na XN, Cai BS*
- 309** Cerebral venous sinus thrombosis in pregnancy: A case report  
*Zhou B, Huang SS, Huang C, Liu SY*
- 316** Eustachian tube teratoma: A case report  
*Li JY, Sun LX, Hu N, Song GS, Dou WQ, Gong RZ, Li CT*

- 323** Protein-losing enteropathy caused by a jejunal ulcer after an internal hernia in Petersen's space: A case report  
*Yasuda T, Sakurazawa N, Kuge K, Omori J, Arai H, Kakinuma D, Watanabe M, Suzuki H, Iwakiri K, Yoshida H*
- 331** Lunate dislocation with avulsed triquetral fracture: A case report  
*Li LY, Lin CJ, Ko CY*
- 338** Clinical manifestations and prenatal diagnosis of Ullrich congenital muscular dystrophy: A case report  
*Hu J, Chen YH, Fang X, Zhou Y, Chen F*
- 345** Diagnosis and guidance of treatment of breast cancer cutaneous metastases by multiple needle biopsy: A case report  
*Li ZH, Wang F, Zhang P, Xue P, Zhu SJ*
- 353** Test of incremental respiratory endurance as home-based, stand-alone therapy in chronic obstructive pulmonary disease: A case report  
*Dosbaba F, Hartman M, Batalik L, Brat K, Plutinsky M, Hnatiak J, Formiga MF, Cahalin LP*
- 361** Diagnostic and surgical challenges of progressive neck and upper back painless masses in Madelung's disease: A case report and review of literature  
*Yan YJ, Zhou SQ, Li CQ, Ruan Y*
- 371** Suspected cerebrovascular air embolism during endoscopic esophageal varices ligation under sedation with fatal outcome: A case report  
*Zhang CMJ, Wang X*
- 381** An atypical primary malignant melanoma arising from the cervical nerve root: A case report and review of literature  
*Shi YF, Chen YQ, Chen HF, Hu X*
- 388** Epidural blood patch for spontaneous intracranial hypotension with subdural hematoma: A case report and review of literature  
*Choi SH, Lee YY, Kim WJ*

**ABOUT COVER**

Editorial Board Member of *World Journal of Clinical Cases*, Ravi Kant, MD, Associate Professor, Division of Endocrinology, Diabetes and Metabolism, Medical University of South Carolina/Anmed Campus, Anderson, SC 29621, United States. rkant82@hotmail.com

**AIMS AND SCOPE**

The primary aim of *World Journal of Clinical Cases* (WJCC, *World J Clin Cases*) is to provide scholars and readers from various fields of clinical medicine with a platform to publish high-quality clinical research articles and communicate their research findings online.

WJCC mainly publishes articles reporting research results and findings obtained in the field of clinical medicine and covering a wide range of topics, including case control studies, retrospective cohort studies, retrospective studies, clinical trials studies, observational studies, prospective studies, randomized controlled trials, randomized clinical trials, systematic reviews, meta-analysis, and case reports.

**INDEXING/ABSTRACTING**

The WJCC is now indexed in Science Citation Index Expanded (also known as SciSearch®), Journal Citation Reports/Science Edition, Scopus, PubMed, and PubMed Central. The 2021 Edition of Journal Citation Reports® cites the 2020 impact factor (IF) for WJCC as 1.337; IF without journal self cites: 1.301; 5-year IF: 1.742; Journal Citation Indicator: 0.33; Ranking: 119 among 169 journals in medicine, general and internal; and Quartile category: Q3. The WJCC's CiteScore for 2020 is 0.8 and Scopus CiteScore rank 2020: General Medicine is 493/793.

**RESPONSIBLE EDITORS FOR THIS ISSUE**

Production Editor: Lin-YuTong Wang; Production Department Director: Xiang Li; Editorial Office Director: Jin-Lei Wang.

**NAME OF JOURNAL**

*World Journal of Clinical Cases*

**ISSN**

ISSN 2307-8960 (online)

**LAUNCH DATE**

April 16, 2013

**FREQUENCY**

Weekly

**EDITORS-IN-CHIEF**

Bao-Gan Peng

**EDITORIAL BOARD MEMBERS**

<https://www.wjgnet.com/2307-8960/editorialboard.htm>

**PUBLICATION DATE**

January 7, 2022

**COPYRIGHT**

© 2022 Baishideng Publishing Group Inc

**INSTRUCTIONS TO AUTHORS**

<https://www.wjgnet.com/bpg/gerinfo/204>

**GUIDELINES FOR ETHICS DOCUMENTS**

<https://www.wjgnet.com/bpg/GerInfo/287>

**GUIDELINES FOR NON-NATIVE SPEAKERS OF ENGLISH**

<https://www.wjgnet.com/bpg/gerinfo/240>

**PUBLICATION ETHICS**

<https://www.wjgnet.com/bpg/GerInfo/288>

**PUBLICATION MISCONDUCT**

<https://www.wjgnet.com/bpg/gerinfo/208>

**ARTICLE PROCESSING CHARGE**

<https://www.wjgnet.com/bpg/gerinfo/242>

**STEPS FOR SUBMITTING MANUSCRIPTS**

<https://www.wjgnet.com/bpg/GerInfo/239>

**ONLINE SUBMISSION**

<https://www.f6publishing.com>



Retrospective Study

# Surgical resection of intradural extramedullary tumors in the atlantoaxial spine *via* a posterior approach

Di-Hua Meng, Jia-Qi Wang, Kun-Xue Yang, Wei-You Chen, Cheng Pan, Hua Jiang

**ORCID number:** Di-Hua Meng 0000-0002-2487-7638; Jia-Qi Wang 0000-0002-3158-3056; Kun-Xue Yang 0000-0002-2933-515X; Wei-You Chen 0000-0001-8316-7997; Cheng Pan 0000-0003-1223-5336; Hua Jiang 0000-0001-9347-5782.

**Author contributions:** Jiang H conceived, supervised the study and performed critical revision of the manuscript; Meng DH and Wang JQ were involved in the data search and selection of data; Yang KX, Pan C and Chen WY analyzed and interpreted the data and drafted the manuscript; All authors read and approved the final manuscript.

**Institutional review board**

**statement:** The histological study of surgical samples was approved by the Ethics Committee of the First Affiliated Hospital of Guangxi Medical University (No. 2020-KY-NSFC-025).

**Informed consent statement:**

Written consent was obtained from each participant.

**Conflict-of-interest statement:** The authors declare that they have no competing interests.

**Data sharing statement:** No additional data are available.

**Di-Hua Meng, Jia-Qi Wang, Kun-Xue Yang, Wei-You Chen, Cheng Pan, Hua Jiang,** Department of Spine Surgery, the First Affiliated Hospital of Guangxi Medical University, Nanning 530021, Guangxi Province, China

**Corresponding author:** Hua Jiang, MD, PhD, Professor, Department of Spine Surgery, the First Affiliated Hospital of Guangxi Medical University, No. 6 Shuangyong Road, Nanning 530021, Guangxi Province, China. [drjianghua@163.com](mailto:drjianghua@163.com)

## Abstract

### BACKGROUND

The anatomical features of the atlantoaxial spine increase the difficulty of complete and safe removal of atlantoaxial intradural extramedullary (IDEM) tumors. Studies concerning surgical interventions *via* a posterior approach are limited.

### AIM

To investigate the safety and efficacy of atlantoaxial IDEM tumor resection using a one-stage posterior approach.

### METHODS

We retrospectively analyzed clinical databases for one-stage atlantoaxial IDEM tumor resection *via* a posterior approach between January 2008 and January 2018. The analyzed data included tumor position, histopathological type, pre- and post-operative Japanese Orthopedic Association (JOA) scores and Nurick grades, postoperative complication and recurrence status.

### RESULTS

A total of 13 patients who underwent C1-C2 Laminectomy and/or unilateral facetectomy *via* the posterior approach were enrolled in the study. In all cases reviewed, total tumor resection and concomitant C1-C2 fusion were achieved. The average follow-up was  $35.3 \pm 6.9$  mo (range, 26-49 mo). A statistically significant difference was noted between the preoperative JOA score ( $11.2 \pm 1.1$ ) and the score at the last final follow-up ( $15.6 \pm 1.0$ ) ( $P < 0.05$ ). A statistically significant difference was noted between the preoperative Nurick grade ( $2.3 \pm 0.9$ ) and that at the last follow-up ( $1.2 \pm 0.4$ ) ( $P < 0.05$ ). However, no statistically significant difference was noted between the preoperative and last follow-up C1-2 Cobb angle and C2-7 Cobb angle ( $P > 0.05$ ). No mortalities, severe complications or tumor recurrence were observed during the follow-up period.



**Supported by** the National Natural Science Foundation of China, No. 81860406; Guangxi Natural Science Foundation, No. 2018GXNSFAA281127; and Medical Excellence Award Funded by the Creative Research Development Grant from The First Affiliated Hospital of Guangxi Medical University.

**Country/Territory of origin:** China

**Specialty type:** Surgery

**Provenance and peer review:**

Unsolicited article; Externally peer reviewed.

**Peer-review model:** Single blind

**Peer-review report's scientific quality classification**

Grade A (Excellent): 0

Grade B (Very good): 0

Grade C (Good): C

Grade D (Fair): 0

Grade E (Poor): 0

**Open-Access:** This article is an open-access article that was selected by an in-house editor and fully peer-reviewed by external reviewers. It is distributed in accordance with the Creative Commons Attribution NonCommercial (CC BY-NC 4.0) license, which permits others to distribute, remix, adapt, build upon this work non-commercially, and license their derivative works on different terms, provided the original work is properly cited and the use is non-commercial. See: <https://creativecommons.org/licenses/by-nc/4.0/>

**Received:** May 3, 2021

**Peer-review started:** May 3, 2021

**First decision:** October 16, 2021

**Revised:** October 30, 2021

**Accepted:** November 19, 2021

**Article in press:** November 19, 2021

**Published online:** January 7, 2022

**P-Reviewer:** Koumantakis GA

**S-Editor:** Wang JL

**L-Editor:** A

**P-Editor:** Wang JL

## CONCLUSION

Total resection of atlantoaxial IDEM tumors is feasible and effective *via* a posterior approach. Surgical reconstruction should be considered to avoid iatrogenic kyphosis and improve spinal stability and overall clinical outcomes.

**Key Words:** Atlantoaxial spine; Cervical spine; Extramedullary tumors; Intardural tumor; Posterior approach; Surgical resection

©The Author(s) 2022. Published by Baishideng Publishing Group Inc. All rights reserved.

**Core Tip:** This retrospective study investigated the safety and efficacy of atlantoaxial intradural extramedullary (IDEM) tumor resection using a one-stage posterior approach. Statistically significant differences were noted between the preoperative Japanese Orthopedic Association (JOA) score and Nurick grade and those at the last follow-up (JOA:  $11.2 \pm 1.1$  vs  $15.6 \pm 1.0$ ; Nurick grade:  $2.3 \pm 0.9$  vs  $1.2 \pm 0.4$ ; all  $P < 0.05$ ). No mortalities, severe complications or tumor recurrence were observed during the follow-up period. Total resection of atlantoaxial IDEM tumors is feasible and effective *via* a posterior approach.

**Citation:** Meng DH, Wang JQ, Yang KX, Chen WY, Pan C, Jiang H. Surgical resection of intradural extramedullary tumors in the atlantoaxial spine *via* a posterior approach. *World J Clin Cases* 2022; 10(1): 62-70

**URL:** <https://www.wjgnet.com/2307-8960/full/v10/i1/62.htm>

**DOI:** <https://dx.doi.org/10.12998/wjcc.v10.i1.62>

## INTRODUCTION

Intradural extramedullary (IDEM) tumors have an incidence rate of approximately 5 to 10 per 100,000 people[1]. IDEM tumors in the atlantoaxial spine are uncommon and present with progressive pain and neurological deficits. With advances in surgical technology, the management of these tumors has shifted toward radical resection with decompression of surrounding neural structures[2]. The odontoid process and lack of bony foramen make the anatomical characteristics of the atlantoaxial spine uniquely complex, thus making surgical approach for the treatment of an atlantoaxial IDEM tumor both difficult and controversial. Commonly used surgical strategies include the anterior or anterolateral approach, posterior approach, or combined anterior-posterior approach. The anterior or anterolateral approach has been reported to facilitate easy access to lesions located anterior to the atlantoaxial spine[3]. However, the operation fields of these approaches are deep and narrow and require the resection of vital components of the atlantoaxial spine. The prolonged surgical time of the combined anterior-posterior approach has been linked to iatrogenic traumatism[4]. The posterior approach is the most widely used. However, there is no general consensus regarding the surgical outcome. The objective of this study was to evaluate the safety and efficacy of atlantoaxial IDEM tumor resection *via* a one-stage posterior approach.

## MATERIALS AND METHODS

We retrospectively searched the clinical databases of the First Affiliated Hospital of Guangxi Medical University over a period of ten years (January 2008 to January 2018) for patients who underwent atlantoaxial IDEM tumor resection *via* a one-stage posterior approach. The study was approved by the Ethics Committee of the First Affiliated Hospital of Guangxi Medical University (No. 2020-KY-NSFC-025), and all participants provided written informed consent. Patients were included in the study if (1) age > 18 years; (2) atlantoaxial IDEM tumor was confirmed by magnetic resonance imaging; (3) underwent standard open IDEM tumor resection *via* a one-stage posterior approach; and (4) postoperative histopathological studies of surgical samples confirmed IDEM tumor diagnosis. The exclusion criteria were as follows: (1) preoperative, intraoperative or postoperative diagnosis of non-IDEM tumor; (2)





patient with history of cervical spine surgery; (3) patient with congenital atlantoaxial anomalies; and (4) patients with incomplete pre- and postoperative data.

### **Surgical techniques**

Following the induction of general anesthesia, a patient was placed in a prone position, and a longitudinal midline incision was made. Paravertebral soft tissues were then dissected to expose the occiput, posterior arch of C1, and spinous process and lamina of C2. The inferior part of the C1 posterior arch and the superior part of the C2 Lamina were then drilled off according to the location of the lesion. In some cases, the facet joint may be unilaterally removed to expose the tumor and protect the spinal cord. In the case of dumbbell tumors, the extradural components were first removed, and the intradural procedure was performed following the exposure of the dura mater. All tumor resections were performed using standard microsurgical techniques, and the dura mater was closed using running sutures with 4-0 Nurolon. This procedure is followed by spinal instrumentation and fusion. Under fluoroscopic guidance, C1 Lateral mass screws and C2 pedicle screws were fixed followed by grafting with cancellous bone granules between the C1 and C2 vertebrae.

### **Assessment of the surgical outcome**

Nurick grade and Japanese Orthopaedic Association (JOA) score were used to evaluate preoperative and follow-up symptoms[5,6]. The intra- and postoperative reviewed data included lesion level, operation time, surgery-related complications, histopathological type and tumor recurrence.

### **Assessment of the spinal alignment**

The following preoperative, postoperative and last follow-up parameters were measured on radiographs: (1) C1-2 Cobb angle: the angle between the line connecting the superior margins of the anterior and posterior arches of C1 and another line along the inferior endplate of C2[7], and (2) C2-7 angle: the angle between the lines along the inferior endplate of C2 and C7 vertebrae[8]. The C1-C2 and C2-C7 cervical lordosis were expressed as positive values.

### **Statistical analysis**

Data collected for the assessment of pre- and postoperative spinal alignment and surgical outcomes, including the Nurick grade, JOA score, C1-2 angle and C2-7 angle, were analyzed using paired *t* tests for statistical significance. All statistical analyses were performed using SPSS version 13.0 (SPSS, Inc., Chicago, IL, United States), with a *P* value < 0.05 considered statistically significant.

## **RESULTS**

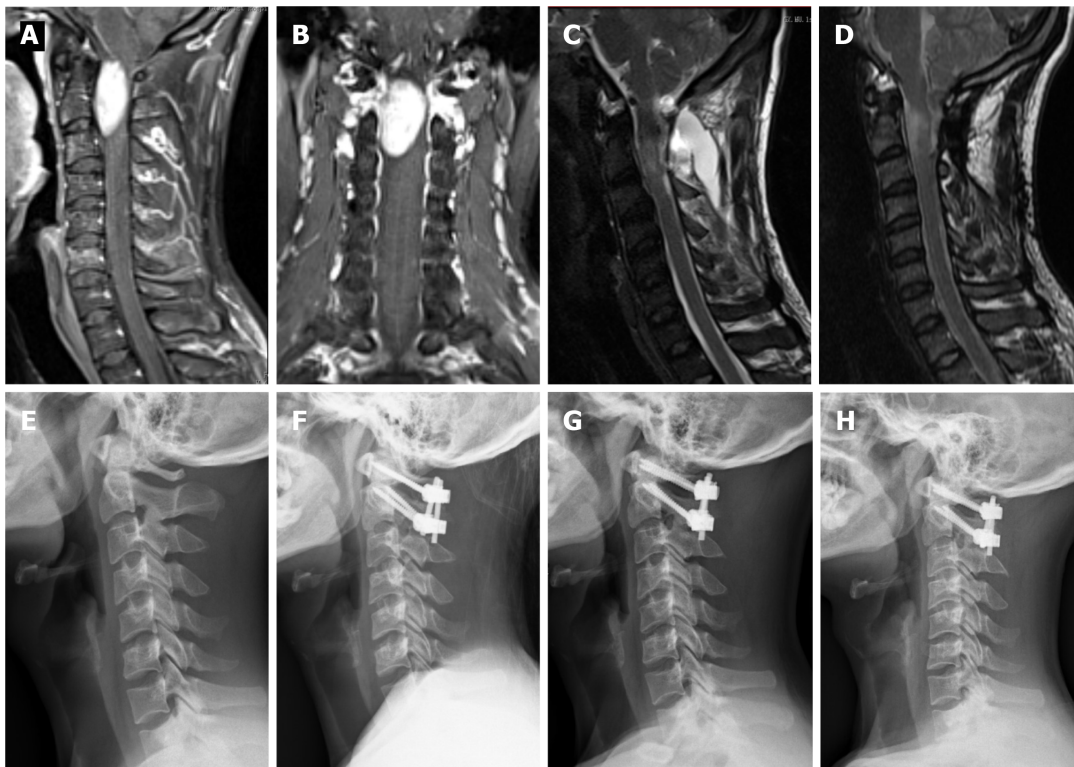
A total of 13 patients (6 males and 7 females) with an average age of 49.3 years (range 29-66 years) were enrolled for this study (Table 1). The mean follow-up period was 35.3 mo and ranged between 26 and 49 mo. The tumor location was at the C1-C2 Level in 8 patients, the occiput-C1 Level in 3 patients, and the occiput-C2 Level in 2 patients. The maximum tumor diameter within the spinal canal ranged between 5 and 11 mm with a mean of 8.7 mm. All patients reviewed were symptomatic: 2 patients presented with occipital neuralgia, 7 patients presented with extremity pain and/or numbness, and 4 patients presented with clumsiness of the upper extremities. The average duration from onset of initial symptoms to surgery was 10 mo (range 2-18 mo). The histopathological studies confirmed 5 cases as meningiomas, 6 as schwannomas, and 2 as neurofibromas.

In all cases, the atlantoaxial IDEM tumors were successfully removed *via* a one-stage posterior approach (Figures 1 and 2). The surgical time ranged from 121-368 min with an average of  $205 \pm 85$  min and an average intraoperative blood loss of  $263 \pm 155$  mL (range 150-650 mL). Total resection and C1-C2 fusion were successfully performed in all the reviewed cases, among which 8 were treated with C1-C2 Laminectomy and 5 with C1-C2 Laminectomy and unilateral facetectomy. With the exception of 2 patients who developed cerebrospinal fluid (CSF) leakage, no major surgery-related complications or deaths were observed. CSF leakage was successfully treated using neck wrapping and strict bed rest. No tumor recurrence or surgical revision was observed during the follow-up period. Significant improvements in the JOA score and Nurick grade were noted (Figures 3 and 4). The JOA score increased from  $11.2 \pm 1.1$  to  $15.6 \pm 1.0$ , while the Nurick grade improved from  $2.3 \pm 0.9$  to  $1.2 \pm 0.4$ . There were statist-

**Table 1** The clinical data of the patients with intradural extramedullary tumor in the atlantoaxial spine

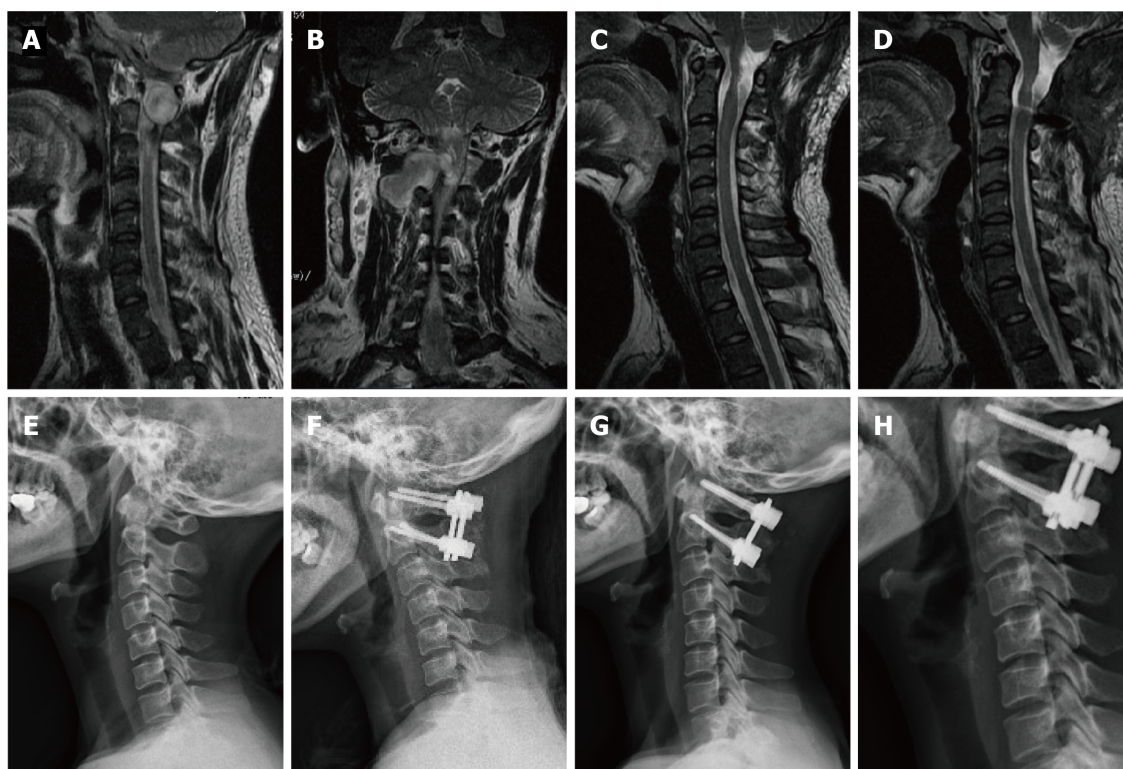
Patient	Gender	Age (yrs)	Affected level	Location	Tumor type	Tumor size (mm)	Complication	Follow up (mo)
1	F	54	Occiput-C1	Ventral	Meningioma	7		41
2	M	29	Occiput-C2	Ventrolateral	Schwannoma	11	CSF leaks	31
3	M	57	C1-C2	Ventral	Meningioma	8		28
4	F	37	C1-C2	Ventral	Schwannoma	7		34
5	F	51	C1-C2	Ventrolateral	Schwannoma	7		42
6	M	39	Occiput-C1	Ventral	Meningioma	6		32
7	M	61	C1-C2	Ventrolateral	Neurofibroma	8		26
8	F	48	Occiput-C2	Ventrolateral	Schwannoma	10		38
9	F	45	C1-C2	Ventral	Neurofibroma	6		42
10	M	59	Occiput-C1	Ventral	Meningioma	7	CSF leaks	36
11	F	43	C1-C2	Ventrolateral	Schwannoma	5		49
12	M	66	C1-C2	Ventrolateral	Schwannoma	6		26
13	M	52	C1-C2	Ventral	Meningioma	5		34

Pre: preoperative; post: postoperative; tumor size; maximum diameter within the spinal canal; CSF: cerebrospinal fluid.

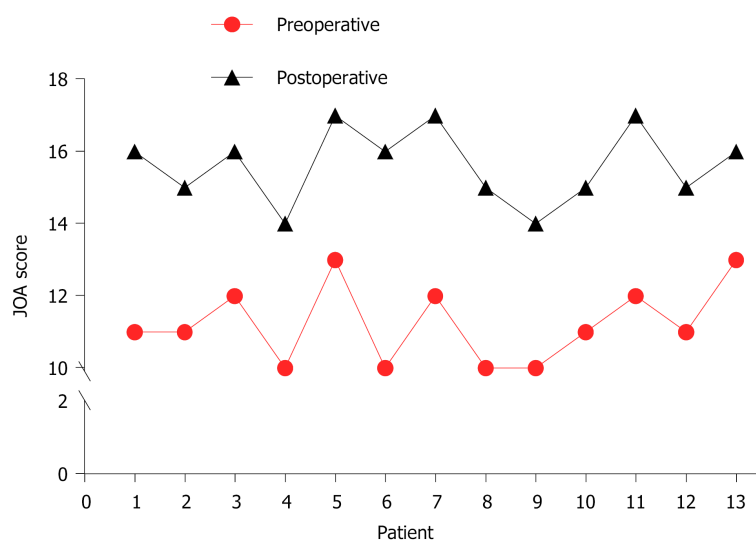


**Figure 1** This 29-year-old male patient experienced a significant deterioration in his neurological condition and was unable to walk after 3 mo (Case 2). A: Preoperative sagittal enhanced magnetic resonance imaging (MRI): an intradural extramedullary tumor located anterior to the atlantoaxial spinal cord; B: Preoperative coronal enhanced MRI: an intradural extramedullary tumor extending into the spinal canal at C1-C2 Levels; C, D: 3 mo and 31 mo postoperative sagittal T2-weighted MRI showing complete tumor resection; E: Preoperative X-ray: cervical sagittal alignment shows a loss of cervical lordosis; F, G, H: 3 mo, 18 mo and 31 mo postoperative X-ray: C1-C2 fixation with cervical pedicle screws and titanium plates.

ically significant differences between the preoperative and postoperative JOA scores and Nurick grade ( $P < 0.05$ ). This suggests significant postoperative benefits of the one-stage posterior approach resection of IDEM tumors. The mean preoperative C1-2 Cobb angle and C2-7 Cobb angle were  $25.7 \pm 8.1^\circ$  and  $14.8 \pm 15.3^\circ$ , respectively. At the



**Figure 2** This 48-year-old female patient experienced a significant deterioration in her neurological condition (Case 8). A: Preoperative sagittal enhanced magnetic resonance imaging (MRI): an intradural extramedullary tumor located anterior to the atlantoaxial spinal cord; B: Preoperative coronal enhanced MRI: an intradural extramedullary tumor extending into the spinal canal at C1-C2 Levels; C, D: 3 mo and 38 mo postoperative sagittal T2-weighted MRI showing complete tumor resection; E: Preoperative X-ray: cervical sagittal alignment shows a loss of cervical lordosis; F, G, H: 3 mo, 24 mo and 38 mo postoperative X-ray: C1-C2 fixation with cervical pedicle screws and titanium plates.



**Figure 3** The Japanese Orthopedic Association score before and after surgery in all cases. JOA: Japanese Orthopedic Association.

last follow-up, the mean C1-2 Cobb angle increased to  $27.2 \pm 6.8^\circ$ , whereas the C2-7 Cobb angle decreased to  $16.5 \pm 12.7^\circ$ . However, the difference was not statistically significant ( $P > 0.05$ ).

## DISCUSSION

Although the atlantoaxial spine accounts for approximately 14% of all spinal cord tumors[9], there are still limited published reports about its clinical features and

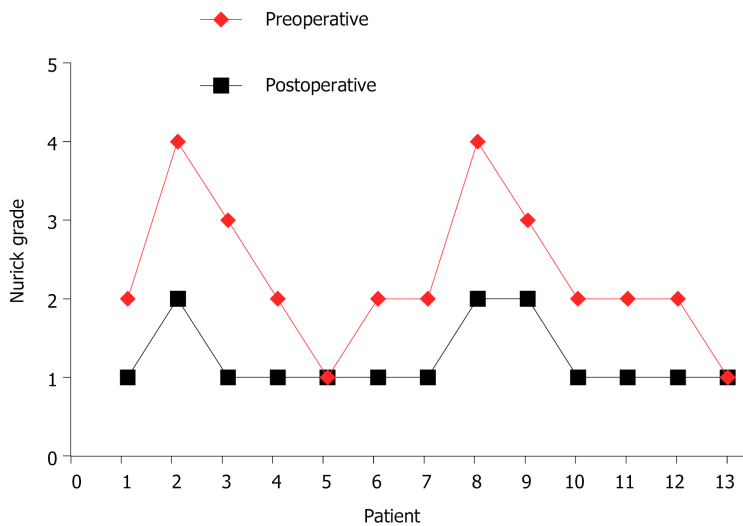


Figure 4 The Nurick grade before and after surgery in all cases.

overall postoperative outcome. The atlantoaxial spine has specific anatomical complexities not found at the other spinal levels. Thus, a detailed understanding of this condition is paramount for safe and efficient surgical intervention of tumors located at this level. In this study, all patients underwent a one-stage posterior approach, and our results demonstrate that this approach provided the adequate exposure required for safe and complete tumor resection. The results also revealed an improved overall postoperative neurological function at the last follow-up.

Currently, the various surgical approaches employed for the resection of atlantoaxial IDEM tumors include anterior, anterolateral, posterior and combined anterior and posterior approaches. The anterior approach provides the most direct access to intradural lesions ventral to the craniocervical junction. Thus, the procedure is advantageous for the exposure of ventral IDEM tumors without the need for extensive manipulation of the cervical spinal cord. However, the available surgical corridor is narrow and shallow, and access to lateral masses is limited[10]. Therefore, this approach is infrequently used for intradural tumor resections and has been used for the removal of small lesions ventral to the mid-portion of the atlantoaxial spine without spinal cord compression[11,12]. However, there is an increased difficulty in achieving watertight closure of the dura mater. Posterior approach atlantoaxial IDEM tumor resection is a familiar, low-risk procedure used by spine surgeons. In most instances, adequate exposure can be attained using the standard posterior approach with laminectomy. In addition, the standard posterior approach allows for direct ventral canal access *via* the removal of lateral bone structures, such as facet joints, or part of the pedicle. The cervical spinal cord is more susceptible to intraoperative damage; therefore, there is the need to secure a wide operative field to allow for gentle maneuvering of the spinal cord. Successful cervical tumor resection includes successful gross total tumor resection, and gentle manipulation of the spinal cord can help minimize postoperative neurological deficits and maximize postoperative neurological symptom recovery[13]. In this study, the surgical technique used in all patients included C1-C2 Laminectomy, which was occasionally combined with unilateral facetectomy on the tumor side. This process provides sufficient extraspinal and intraspinal access for tumor excision and produces satisfactory postoperative outcomes. Our results showed that atlantoaxial IDEM tumors smaller than 10 mm, even those located ventral to the spinal canal, can be safely and completely removed *via* posterior approach laminectomy and/or unilateral facetectomy.

The development of postlaminectomy kyphosis following cervical IDEM tumors resection is a relatively common problem with a reported incidence rate between 24% and 75%[14,15]. However, the incidence of craniocervical instability or deformity in relation to C1-C2 Laminectomy has not been reported[16-19]. Increased risk of postoperative deformity have been reported to correlate with C2 Laminectomy[15], facet joint damage[20], and preoperative loss of cervical lordosis[21]. Additionally, there are reported cases of intraspinal tumors causing preoperative spinal deformities [22]. Thus, an inevitable risk of postoperative atlantoaxial instability and/or deformity is noted following C1-C2 Laminectomy.



Several studies have reported postoperative atlantoaxial instability and postlaminectomy kyphosis following posterior decompression of atlantoaxial spinal pathologies [23-25]. Currently available studies of cadavers of animals and humans point to the C2 Lamina and facet joints being of prominent importance in the maintenance of cervical stability, especially of the atlantoaxial spine [26-28]. However, it remains controversial whether internal fixation and fusion of the atlantoaxial spine should be performed after C2 Laminectomy or facetectomy. McCormick *et al* [29] and Jiang *et al* [30] reported upper cervical instability following resection of greater than 50% of the unilateral facet joint. These researchers suggested spinal reconstruction following the resection of greater than 50% of the unilateral facet joint. To obtain sufficient space for tumor removal, the posterior arch of C1 and lamina of C2 were resected and occasionally combined with unilateral facet joint resection followed by overturning of the spinal cord in the present study. Adequate stabilization was achieved by posterior fixation and fusion using an autologous bone graft. During the long follow-up periods, no cervical spine deformity was observed in any of the cases. Prevention of postlaminectomy deformity is an important consideration in preoperative surgical planning. Therefore, in cases where C1-C2 Laminectomy was performed or the facet joint was destroyed, we recommend the concomitant application of surgical fusion after resection of atlantoaxial IDEM tumors. It is our understanding that this is an effective surgical option for improving the functional status, quality of life, and preservation of sagittal alignment in postoperative IDEM tumor patients.

There are several limitations in this study. First, this is a single-center study with a relatively small study population. Future studies are warranted to confirm our results. Second, this was a retrospective study, which may introduce the potential for information bias. Finally, the average follow-up period of 35 mo was too short to completely understand postoperative cervical stability and sagittal balance.

## CONCLUSION

Total resection of atlantoaxial IDEM tumors can be safely and effectively resected *via* one-stage posterior approach laminectomy and/or unilateral facetectomy. For longer stability and better clinical outcomes, spinal reconstruction should be considered to prevent iatrogenic kyphosis.

## ARTICLE HIGHLIGHTS

### Research perspectives

The goal of new surgical treatments is to reduce the incidence of cerebrospinal fluid leakage and relieve injury to patients.

### Research conclusions

Total resection of atlantoaxial intradural extramedullary (IDEM) tumors is feasible and effective *via* a posterior approach.

### Research results

A statistically significant difference was noted between the preoperative Japanese Orthopedic Association score ( $11.2 \pm 1.1$ ) and the score at the last final follow-up ( $15.6 \pm 1.0$ ) ( $P < 0.05$ ). A statistically significant difference was also noted between the preoperative Nurick grade ( $2.3 \pm 0.9$ ) and that at the last follow-up ( $1.2 \pm 0.4$ ) ( $P < 0.05$ ). However, no statistically significant difference was noted between the preoperative and last follow-up C1-2 Cobb angle and C2-7 Cobb angle ( $P > 0.05$ ). No mortalities, severe complications or tumor recurrence were observed during the follow-up period.

### Research methods

This was a retrospective study of 13 patients who underwent atlantoaxial IDEM tumor resection *via* a posterior approach.

### Research objectives

To investigate the efficacy of surgical resection for atlantoaxial IDEM tumors and its influencing factors.

**Research motivation**

To explore the safety and feasibility of atlantoaxial IDEM tumor resection.

**Research background**

IDEM tumors in the atlantoaxial spine are uncommon and present with progressive pain and neurological deficits.

**ACKNOWLEDGEMENTS**

The authors thank all the participants in this study.

**REFERENCES**

- 1 **Traul DE**, Shaffrey ME, Schiff D. Part I: spinal-cord neoplasms-intradural neoplasms. *Lancet Oncol* 2007; **8**: 35-45 [PMID: [17196509](#) DOI: [10.1016/S1470-2045\(06\)71009-9](#)]
- 2 **Jiang H**, He J, Zhan X, He M, Zong S, Xiao Z. Occipito-cervical fusion following gross total resection for the treatment of spinal extramedullary tumors in craniocervical junction: a retrospective case series. *World J Surg Oncol* 2015; **13**: 279 [PMID: [26384486](#) DOI: [10.1186/s12957-015-0689-0](#)]
- 3 **Ohnishi Y**, Iwatsuki K, Taketsuna S, Ninomiya K, Yoshimine T. Retro-odontoid synovial cyst resected via an anterolateral approach without fusion. *Eur Spine J* 2015; **24**: S508-S513 [PMID: [25212453](#) DOI: [10.1007/s00586-014-3578-2](#)]
- 4 **Chotai S**, Zuckerman SL, Parker SL, Wick JB, Stonko DP, Hale AT, McGirt MJ, Cheng JS, Devin CJ. Healthcare Resource Utilization and Patient-Reported Outcomes Following Elective Surgery for Intradural Extramedullary Spinal Tumors. *Neurosurgery* 2017; **81**: 613-619 [PMID: [28498938](#) DOI: [10.1093/neuros/nyw126](#)]
- 5 **Nurick S**. The pathogenesis of the spinal cord disorder associated with cervical spondylosis. *Brain* 1972; **95**: 87-100 [PMID: [5023093](#) DOI: [10.1093/brain/95.1.87](#)]
- 6 **Yonenobu K**, Abumi K, Nagata K, Taketomi E, Ueyama K. Interobserver and intraobserver reliability of the Japanese orthopaedic association scoring system for evaluation of cervical compression myelopathy. *Spine (Phila Pa 1976)* 2001; **26**: 1890-1894 [PMID: [11568701](#) DOI: [10.1097/00007632-200109010-00014](#)]
- 7 **Kato Y**, Itoh T, Kanaya K, Kubota M, Ito S. Relation between atlantoaxial (C1/2) and cervical alignment (C2-C7) angles with Magerl and Brooks techniques for atlantoaxial subluxation in rheumatoid arthritis. *J Orthop Sci* 2006; **11**: 347-352 [PMID: [16897197](#) DOI: [10.1007/s00776-006-1033-x](#)]
- 8 **Tang X**, Dong L, Tan M, Yi P, Yang F, Hao Q. Long-Term Influence of C1-C2 Pedicle Screw Fixation on Occipitotantal Angle and Subaxial Cervical Spine in the Pediatric Population. *Pediatr Neurosurg* 2018; **53**: 143-148 [PMID: [29514167](#) DOI: [10.1159/000481784](#)]
- 9 **Zozulya YP**, Slynko YI, Al-Qashqish II. Surgical treatment of ventral and ventrolateral intradural extramedullary tumors of craniovertebral and upper cervical localization. *Asian J Neurosurg* 2011; **6**: 18-25 [PMID: [22059100](#) DOI: [10.4103/1793-5482.85629](#)]
- 10 **Angevine PD**, Kellner C, Haque RM, McCormick PC. Surgical management of ventral intradural spinal lesions. *J Neurosurg Spine* 2011; **15**: 28-37 [PMID: [21495815](#) DOI: [10.3171/2011.3.SPINE1095](#)]
- 11 **Slin'ko EI**, Al-Qashqish II. Intradural ventral and ventrolateral tumors of the spinal cord: surgical treatment and results. *Neurosurg Focus* 2004; **17**: ECP2 [PMID: [15264778](#) DOI: [10.3171/foc.2004.17.1.9](#)]
- 12 **Naito K**, Yamagata T, Kawahara S, Ohata K, Takami T. High Cervical Lateral Approach to Safely Remove the Cystic Retro-odontoid Pseudotumor: Technical Note. *Neurol Med Chir (Tokyo)* 2019; **59**: 392-397 [PMID: [31406052](#) DOI: [10.2176/nmc.tn.2019-0060](#)]
- 13 **Altas M**, Cerci A, Silav G, Sari R, Coskun K, Balak N, Isik N, Elmali I. Microsurgical management of non-neurofibromatosis spinal schwannoma. *Neurocirugia (Astur)* 2013; **24**: 244-249 [PMID: [23102980](#) DOI: [10.1016/j.neucir.2012.01.002](#)]
- 14 **Tatter C**, Fletcher-Sandersjö A, Persson O, Burström G, Grane P, Edström E, Elmi-Terander A. Incidence and predictors of kyphotic deformity following resection of cervical intradural tumors in adults: a population-based cohort study. *Acta Neurochir (Wien)* 2020; **162**: 2905-2913 [PMID: [32556521](#) DOI: [10.1007/s00701-020-04416-4](#)]
- 15 **Abduljabbar FH**, Teles AR, Bokhari R, Weber M, Santaguida C. Laminectomy with or Without Fusion to Manage Degenerative Cervical Myelopathy. *Neurosurg Clin N Am* 2018; **29**: 91-105 [PMID: [29173440](#) DOI: [10.1016/j.nec.2017.09.017](#)]
- 16 **Fassett DR**, Clark R, Brockmeyer DL, Schmidt MH. Cervical spine deformity associated with resection of spinal cord tumors. *Neurosurg Focus* 2006; **20**: E2 [PMID: [16512653](#)]
- 17 **McGirt MJ**, Chaichana KL, Atiba A, Bydon A, Witham TF, Yao KC, Jallo GI. Incidence of spinal deformity after resection of intramedullary spinal cord tumors in children who underwent laminectomy compared with laminoplasty. *J Neurosurg Pediatr* 2008; **1**: 57-62 [PMID: [18352804](#)]

- DOI: [10.3171/PED-08/01/057](https://doi.org/10.3171/PED-08/01/057)
- 18 **Nakamura M**, Iwanami A, Tsuji O, Hosogane N, Watanabe K, Tsuji T, Ishii K, Toyama Y, Chiba K, Matsumoto M. Long-term surgical outcomes of cervical dumbbell neurinomas. *J Orthop Sci* 2013; **18**: 8-13 [PMID: [22948961](https://pubmed.ncbi.nlm.nih.gov/22948961/) DOI: [10.1007/s00776-012-0300-2](https://doi.org/10.1007/s00776-012-0300-2)]
  - 19 **Yu Y**, Hu F, Zhang X, Gu Y, Xie T, Ge J. Application of the hemi-semi-laminectomy approach in the microsurgical treatment of C2 schwannomas. *J Spinal Disord Tech* 2014; **27**: E199-E204 [PMID: [23732182](https://pubmed.ncbi.nlm.nih.gov/23732182/) DOI: [10.1097/BSD.0b013e318299f606](https://doi.org/10.1097/BSD.0b013e318299f606)]
  - 20 **Ahmed R**, Menezes AH, Awe OO, Mahaney KB, Torner JC, Weinstein SL. Long-term incidence and risk factors for development of spinal deformity following resection of pediatric intramedullary spinal cord tumors. *J Neurosurg Pediatr* 2014; **13**: 613-621 [PMID: [24702614](https://pubmed.ncbi.nlm.nih.gov/24702614/) DOI: [10.3171/2014.1.PEDS13317](https://doi.org/10.3171/2014.1.PEDS13317)]
  - 21 **Kaptain GJ**, Simmons NE, Replogle RE, Pobereskin L. Incidence and outcome of kyphotic deformity following laminectomy for cervical spondylotic myelopathy. *J Neurosurg* 2000; **93**: 199-204 [PMID: [11012049](https://pubmed.ncbi.nlm.nih.gov/11012049/) DOI: [10.3171/spi.2000.93.2.0199](https://doi.org/10.3171/spi.2000.93.2.0199)]
  - 22 **Bansal S**, Suri A, Borkar SA, Kale SS, Singh M, Mahapatra AK. Management of intramedullary tumors in children: analysis of 82 operated cases. *Childs Nerv Syst* 2012; **28**: 2063-2069 [PMID: [22772484](https://pubmed.ncbi.nlm.nih.gov/22772484/) DOI: [10.1007/s00381-012-1835-4](https://doi.org/10.1007/s00381-012-1835-4)]
  - 23 **Mukai Y**, Hosono N, Sakaura H, Fujii R, Iwasaki M, Fuchiya T, Fujiwara K, Fuji T, Yoshikawa H. Sagittal alignment of the subaxial cervical spine after C1-C2 transarticular screw fixation in rheumatoid arthritis. *J Spinal Disord Tech* 2007; **20**: 436-441 [PMID: [17970184](https://pubmed.ncbi.nlm.nih.gov/17970184/) DOI: [10.1097/bsd.0b013e318030ca3b](https://doi.org/10.1097/bsd.0b013e318030ca3b)]
  - 24 **Guo Q**, Ni B, Yang J, Liu K, Sun Z, Zhou F, Zhang J. Relation between alignments of upper and subaxial cervical spine: a radiological study. *Arch Orthop Trauma Surg* 2011; **131**: 857-862 [PMID: [21274548](https://pubmed.ncbi.nlm.nih.gov/21274548/) DOI: [10.1007/s00402-011-1265-x](https://doi.org/10.1007/s00402-011-1265-x)]
  - 25 **Huang JC**, Qian BP, Qiu Y, Yu Y, Ni HB. Surgical overreduction and hyperlordotic fusion of C1-C2 joint are associated with cervical sagittal malalignment. *Arch Orthop Trauma Surg* 2017; **137**: 1631-1639 [PMID: [28986674](https://pubmed.ncbi.nlm.nih.gov/28986674/) DOI: [10.1007/s00402-017-2814-8](https://doi.org/10.1007/s00402-017-2814-8)]
  - 26 **Claybrooks R**, Kayanja M, Milks R, Benzel E. Atlantoaxial fusion: a biomechanical analysis of two C1-C2 fusion techniques. *Spine J* 2007; **7**: 682-688 [PMID: [17434809](https://pubmed.ncbi.nlm.nih.gov/17434809/) DOI: [10.1016/j.spinee.2006.08.010](https://doi.org/10.1016/j.spinee.2006.08.010)]
  - 27 **Cadena G**, Duong HT, Liu JJ, Kim KD. Atlantoaxial fixation using C1 posterior arch screws: feasibility study, morphometric data, and biomechanical analysis. *J Neurosurg Spine* 2018; **30**: 314-322 [PMID: [30554179](https://pubmed.ncbi.nlm.nih.gov/30554179/) DOI: [10.3171/2018.8.SPINE18160](https://doi.org/10.3171/2018.8.SPINE18160)]
  - 28 **Liu S**, Song Z, Liu L, Yin X, Hu X, Yang M, Wu Q, Song Y, Hao D. Biomechanical evaluation of C1 lateral mass and C2 translaminar bicortical screws in atlantoaxial fixation: an *in vitro* human cadaveric study. *Spine J* 2018; **18**: 674-681 [PMID: [29269311](https://pubmed.ncbi.nlm.nih.gov/29269311/) DOI: [10.1016/j.spinee.2017.12.011](https://doi.org/10.1016/j.spinee.2017.12.011)]
  - 29 **McCormick PC**. Surgical management of dumbbell tumors of the cervical spine. *Neurosurgery* 1996; **38**: 294-300 [PMID: [8869056](https://pubmed.ncbi.nlm.nih.gov/8869056/) DOI: [10.1097/00006123-199602000-00012](https://doi.org/10.1097/00006123-199602000-00012)]
  - 30 **Jiang L**, Lv Y, Liu XG, Ma QJ, Wei F, Dang GT, Liu ZJ. Results of surgical treatment of cervical dumbbell tumors: surgical approach and development of an anatomic classification system. *Spine (Phila Pa 1976)* 2009; **34**: 1307-1314 [PMID: [19455006](https://pubmed.ncbi.nlm.nih.gov/19455006/) DOI: [10.1097/BRS.0b013e3181a27a32](https://doi.org/10.1097/BRS.0b013e3181a27a32)]





Published by **Baishideng Publishing Group Inc**  
7041 Koll Center Parkway, Suite 160, Pleasanton, CA 94566, USA

**Telephone:** +1-925-3991568

**E-mail:** [bpgoffice@wjgnet.com](mailto:bpgoffice@wjgnet.com)

**Help Desk:** <https://www.f6publishing.com/helpdesk>

<https://www.wjgnet.com>

