

# World Journal of *Clinical Cases*

*World J Clin Cases* 2021 July 6; 9(19): 4881-5351



## Contents

Thrice Monthly Volume 9 Number 19 July 6, 2021

## OPINION REVIEW

- 4881** Fear of missing out: A brief overview of origin, theoretical underpinnings and relationship with mental health

*Gupta M, Sharma A*

## REVIEW

- 4890** Molecular pathways in viral hepatitis-associated liver carcinogenesis: An update

*Elpek GO*

- 4918** Gastroenterology and liver disease during COVID-19 and in anticipation of post-COVID-19 era: Current practice and future directions

*Oikonomou KG, Papamichalis P, Zafeiridis T, Xanthoudaki M, Papapostolou E, Valsamaki A, Bouliaris K, Papamichalis M, Karvouniaris M, Vlachostergios PJ, Skoura AL, Komnos A*

- 4939** Enhancing oxygenation of patients with coronavirus disease 2019: Effects on immunity and other health-related conditions

*Mohamed A, Alawna M*

## MINIREVIEWS

- 4959** Clinical potentials of ginseng polysaccharide for treating gestational diabetes mellitus

*Zhao XY, Zhang F, Pan W, Yang YF, Jiang XY*

- 4969** Remarkable gastrointestinal and liver manifestations of COVID-19: A clinical and radiologic overview

*Fang LG, Zhou Q*

- 4980** Liver injury in COVID-19: Known and unknown

*Zhou F, Xia J, Yuan HX, Sun Y, Zhang Y*

- 4990** COVID-19 and gastroenteric manifestations

*Chen ZR, Liu J, Liao ZG, Zhou J, Peng HW, Gong F, Hu JF, Zhou Y*

- 4998** Role of epithelial-mesenchymal transition in chemoresistance in pancreatic ductal adenocarcinoma

*Hu X, Chen W*

- 5007** Insights into the virologic and immunologic features of SARS-COV-2

*Polat C, Ergunay K*

## ORIGINAL ARTICLE

## Basic Study

- 5019 SMAC exhibits anti-tumor effects in ECA109 cells by regulating expression of inhibitor of apoptosis protein family

Jiang N, Zhang WQ, Dong H, Hao YT, Zhang LM, Shan L, Yang XD, Peng CL

## Case Control Study

- 5028 Efficacy of Solitaire AB stent-release angioplasty in acute middle cerebral artery atherosclerosis obliterative cerebral infarction

Wang XF, Wang M, Li G, Xu XY, Shen W, Liu J, Xiao SS, Zhou JH

## Retrospective Study

- 5037 Diagnostic value of different color ultrasound diagnostic method in endometrial lesions

Lin XL, Zhang DS, Ju ZY, Li XM, Zhang YZ

- 5046 Clinical and pathological features and risk factors for primary breast cancer patients

Lei YY, Bai S, Chen QQ, Luo XJ, Li DM

- 5054 Outcomes of high-grade aneurysmal subarachnoid hemorrhage patients treated with coiling and ventricular intracranial pressure monitoring

Wen LL, Zhou XM, Lv SY, Shao J, Wang HD, Zhang X

- 5064 Microwave ablation combined with hepatectomy for treatment of neuroendocrine tumor liver metastases

Zhang JZ, Li S, Zhu WH, Zhang DF

- 5073 Clinical application of individualized total arterial coronary artery bypass grafting in coronary artery surgery

Chen WG, Wang BC, Jiang YR, Wang YY, Lou Y

## Observational Study

- 5082 Early diagnosis, treatment, and outcomes of five patients with acute thallium poisoning

Wang TT, Wen B, Yu XN, Ji ZG, Sun YY, Li Y, Zhu SL, Cao YL, Wang M, Jian XD, Wang T

- 5092 Sarcopenia in geriatric patients from the plateau region of Qinghai-Tibet: A cross-sectional study

Pan SQ, Li YM, Li XF, Xiong R

- 5102 Medium-term efficacy of arthroscopic debridement vs conservative treatment for knee osteoarthritis of Kellgren-Lawrence grades I-III

Lv B, Huang K, Chen J, Wu ZY, Wang H

## Prospective Study

- 5112 Impact of continuous positive airway pressure therapy for nonalcoholic fatty liver disease in patients with obstructive sleep apnea

Hirono H, Watanabe K, Hasegawa K, Kohno M, Terai S, Ohkoshi S

**Randomized Controlled Trial**

- 5126** Erector spinae plane block at lower thoracic level for analgesia in lumbar spine surgery: A randomized controlled trial  
*Zhang JJ, Zhang TJ, Qu ZY, Qiu Y, Hua Z*

**SYSTEMATIC REVIEWS**

- 5135** Controversies' clarification regarding ribavirin efficacy in measles and coronaviruses: Comprehensive therapeutic approach strictly tailored to COVID-19 disease stages  
*Liatsos GD*
- 5179** Systematic review and meta-analysis of trans-jugular intrahepatic portosystemic shunt for cirrhotic patients with portal vein thrombosis  
*Zhang JB, Chen J, Zhou J, Wang XM, Chen S, Chu JG, Liu P, Ye ZD*

**CASE REPORT**

- 5191** Myelodysplastic syndrome transformed into B-lineage acute lymphoblastic leukemia: A case report  
*Zhu YJ, Ma XY, Hao YL, Guan Y*
- 5197** Imaging presentation and postoperative recurrence of peliosis hepatis: A case report  
*Ren SX, Li PP, Shi HP, Chen JH, Deng ZP, Zhang XE*
- 5203** Delayed retroperitoneal hemorrhage during extracorporeal membrane oxygenation in COVID-19 patients: A case report and literature review  
*Zhang JC, Li T*
- 5211** Autologous tenon capsule packing to treat posterior exit wound of penetrating injury: A case report  
*Yi QY, Wang SS, Gui Q, Chen LS, Li WD*
- 5217** Treatment of leiomyomatosis peritonealis disseminata with goserelin acetate: A case report and review of the literature  
*Yang JW, Hua Y, Xu H, He L, Huo HZ, Zhu CF*
- 5226** Homozygous deletion, c. 1114-1116del, in exon 8 of the *CRPPA* gene causes congenital muscular dystrophy in Chinese family: A case report  
*Yang M, Xing RX*
- 5232** Successful diagnosis and treatment of jejunal diverticular haemorrhage by full-thickness enterotomy: A case report  
*Ma HC, Xiao H, Qu H, Wang ZJ*
- 5238** Liver metastasis as the initial clinical manifestation of sublingual gland adenoid cystic carcinoma: A case report  
*Li XH, Zhang YT, Feng H*
- 5245** Severe hyperbilirubinemia in a neonate with hereditary spherocytosis due to a *de novo* ankyrin mutation: A case report  
*Wang JF, Ma L, Gong XH, Cai C, Sun JJ*



- 5252** Long-term outcome of indwelling colon observed seven years after radical resection for rectosigmoid cancer: A case report  
*Zhuang ZX, Wei MT, Yang XY, Zhang Y, Zhuang W, Wang ZQ*
- 5259** Diffuse xanthoma in early esophageal cancer: A case report  
*Yang XY, Fu KI, Chen YP, Chen ZW, Ding J*
- 5266** COVID-19 or treatment associated immunosuppression may trigger hepatitis B virus reactivation: A case report  
*Wu YF, Yu WJ, Jiang YH, Chen Y, Zhang B, Zhen RB, Zhang JT, Wang YP, Li Q, Xu F, Shi YJ, Li XP*
- 5270** Maintenance treatment with infliximab for ulcerative ileitis after intestinal transplantation: A case report  
*Fujimura T, Yamada Y, Umeyama T, Kudo Y, Kanamori H, Mori T, Shimizu T, Kato M, Kawaida M, Hosoe N, Hasegawa Y, Matsubara K, Shimojima N, Shinoda M, Obara H, Naganuma M, Kitagawa Y, Hoshino K, Kuroda T*
- 5280** Infliximab treatment of glycogenosis Ib with Crohn's-like enterocolitis: A case report  
*Gong YZ, Zhong XM, Zou JZ*
- 5287** Hemichorea due to ipsilateral thalamic infarction: A case report  
*Li ZS, Fang JJ, Xiang XH, Zhao GH*
- 5294** Intestinal gangrene secondary to congenital transmesenteric hernia in a child misdiagnosed with gastrointestinal bleeding: A case report  
*Zheng XX, Wang KP, Xiang CM, Jin C, Zhu PF, Jiang T, Li SH, Lin YZ*
- 5302** Collagen VI-related myopathy with scoliosis alone: A case report and literature review  
*Li JY, Liu SZ, Zheng DF, Zhang YS, Yu M*
- 5313** Neuromuscular electrical stimulation for a dysphagic stroke patient with cardiac pacemaker using magnet mode change: A case report  
*Kim M, Park JK, Lee JY, Kim MJ*
- 5319** Four-year-old anti-N-methyl-D-aspartate receptor encephalitis patient with ovarian teratoma: A case report  
*Xue CY, Dong H, Yang HX, Jiang YW, Yin L*
- 5325** Glutamic acid decarboxylase 65-positive autoimmune encephalitis presenting with gelastic seizure, responsive to steroid: A case report  
*Yang CY, Tsai ST*
- 5332** Ectopic opening of the common bile duct into the duodenal bulb with recurrent choledocholithiasis: A case report  
*Xu H, Li X, Zhu KX, Zhou WC*
- 5339** Small bowel obstruction caused by secondary jejunal tumor from renal cell carcinoma: A case report  
*Bai GC, Mi Y, Song Y, Hao JR, He ZS, Jin J*
- 5345** Brugada syndrome associated with out-of-hospital cardiac arrest: A case report  
*Ni GH, Jiang H, Men L, Wei YY, A D, Ma X*

**ABOUT COVER**

Editorial Board Member of *World Journal of Clinical Cases*, Fan-Bo Meng, MD, PhD, Chief Doctor, Deputy Director, Professor, Department of Cardiology, China-Japan Union Hospital of Jilin University, Changchun 130000, Jilin Province, China. mengfb@jlu.edu.cn

**AIMS AND SCOPE**

The primary aim of *World Journal of Clinical Cases* (WJCC, *World J Clin Cases*) is to provide scholars and readers from various fields of clinical medicine with a platform to publish high-quality clinical research articles and communicate their research findings online.

WJCC mainly publishes articles reporting research results and findings obtained in the field of clinical medicine and covering a wide range of topics, including case control studies, retrospective cohort studies, retrospective studies, clinical trials studies, observational studies, prospective studies, randomized controlled trials, randomized clinical trials, systematic reviews, meta-analysis, and case reports.

**INDEXING/ABSTRACTING**

The WJCC is now indexed in Science Citation Index Expanded (also known as SciSearch®), Journal Citation Reports/Science Edition, Scopus, PubMed, and PubMed Central. The 2020 Edition of Journal Citation Reports® cites the 2019 impact factor (IF) for WJCC as 1.013; IF without journal self cites: 0.991; Ranking: 120 among 165 journals in medicine, general and internal; and Quartile category: Q3. The WJCC's CiteScore for 2019 is 0.3 and Scopus CiteScore rank 2019: General Medicine is 394/529.

**RESPONSIBLE EDITORS FOR THIS ISSUE**

Production Editor: Yan-Xia Xing, Production Department Director: Yun-Xiaoqian Wu, Editorial Office Director: Jin-Lai Wang.

**NAME OF JOURNAL**

*World Journal of Clinical Cases*

**ISSN**

ISSN 2307-8960 (online)

**LAUNCH DATE**

April 16, 2013

**FREQUENCY**

Thrice Monthly

**EDITORS-IN-CHIEF**

Dennis A Bloomfield, Sandro Vento, Bao-Gan Peng

**EDITORIAL BOARD MEMBERS**

<https://www.wjgnet.com/2307-8960/editorialboard.htm>

**PUBLICATION DATE**

July 6, 2021

**COPYRIGHT**

© 2021 Baishideng Publishing Group Inc

**INSTRUCTIONS TO AUTHORS**

<https://www.wjgnet.com/bpg/gerinfo/204>

**GUIDELINES FOR ETHICS DOCUMENTS**

<https://www.wjgnet.com/bpg/gerinfo/287>

**GUIDELINES FOR NON-NATIVE SPEAKERS OF ENGLISH**

<https://www.wjgnet.com/bpg/gerinfo/240>

**PUBLICATION ETHICS**

<https://www.wjgnet.com/bpg/gerinfo/288>

**PUBLICATION MISCONDUCT**

<https://www.wjgnet.com/bpg/gerinfo/208>

**ARTICLE PROCESSING CHARGE**

<https://www.wjgnet.com/bpg/gerinfo/242>

**STEPS FOR SUBMITTING MANUSCRIPTS**

<https://www.wjgnet.com/bpg/gerinfo/239>

**ONLINE SUBMISSION**

<https://www.f6publishing.com>

## Retrospective Study

## Clinical application of individualized total arterial coronary artery bypass grafting in coronary artery surgery

Wei-Guang Chen, Bai-Chun Wang, Yong-Ri Jiang, Ye-Yang Wang, Yang Lou

**ORCID number:** Wei-Guang Chen 0000-0001-9155-1905; Bai-Chun Wang 0000-0002-2697-276X; Yong-Ri Jiang 0000-0002-5976-1897; Ye-Yang Wang 0000-0002-8574-517X; Yang Lou 0000-0001-8390-5291.

**Author contributions:** Chen WG, Wang BC, Jiang YR, Wang YY, and Lou Y constructed the study, collected and recorded data, and wrote the manuscript; Wang BC critically read the manuscript and proposed comments; All authors approved the final version of the manuscript.

**Institutional review board**

**statement:** The study was reviewed and approved by the Fourth Affiliated Hospital of Harbin Medical University Institutional Review Board.

**Informed consent statement:** All study participants provided informed written consent.

**Conflict-of-interest statement:** There is no conflict of interest.

**Data sharing statement:** No additional data are available.

**Open-Access:** This article is an open-access article that was selected by an in-house editor and fully peer-reviewed by external reviewers. It is distributed in

Wei-Guang Chen, Bai-Chun Wang, Yong-Ri Jiang, Ye-Yang Wang, Yang Lou, Second Ward, Department of Heart and Great Arteries Surgery, Fourth Affiliated Hospital of Harbin Medical University, Harbin 150001, Heilongjiang Province, China

**Corresponding author:** Bai-Chun Wang, MD, Chief Physician, Second Ward, Department of Heart and Great Arteries Surgery, Fourth Affiliated Hospital of Harbin Medical University, No. 37 Palace Street, Nangang District, Harbin 150001, Heilongjiang Province, China. [baichun705@163.com](mailto:baichun705@163.com)

## Abstract

**BACKGROUND**

Total arterial revascularization is associated with increased patency and long-term efficacy and decreased perioperative morbidity and mortality and incidence of cardiac-related events and sternal wound infection compared with conventional coronary artery bypass surgery (CABG), in which the left internal mammary artery (LIMA) is typically grafted to the left anterior descending artery with additional saphenous vein grafts often used. This study determined whether these favorable clinical results could be realized at the authors' institute.

**AIM**

To summarize the early efficacy and clinical experience of individualized total arterial coronary artery bypass grafting surgery.

**METHODS**

CABG was performed on 35 patients with non-single-vessel coronary artery disease by adopting total arterial grafts at Fourth Affiliated Hospital of Harbin Medical University between April 2016 and December 2019. LIMA was used in 35 patients, radial artery (RA) was used in 35 patients, and right gastroepiploic artery (RGEA) was used in 9 patients. Perioperative complications were observed, short-term graft patency rate was followed-up, and quality of life was assessed.

**RESULTS**

All patients underwent off-pump coronary artery bypass and the surgeries were successful. All of them were discharged without any complications or deaths. During the follow-up, it was found that patients' angina symptoms were relieved and New York Heart Association classification for cardiac function was class I to class II. A total of 90 vessels were grafted with no occlusion for internal mammary artery, three occlusions for RA, and one occlusion for RGEA.

accordance with the Creative Commons Attribution NonCommercial (CC BY-NC 4.0) license, which permits others to distribute, remix, adapt, build upon this work non-commercially, and license their derivative works on different terms, provided the original work is properly cited and the use is non-commercial. See: <http://creativecommons.org/licenses/by-nc/4.0/>

**Manuscript source:** Unsolicited manuscript

**Specialty type:** Cardiac and cardiovascular systems

**Country/Territory of origin:** China

**Peer-review report's scientific quality classification**

Grade A (Excellent): 0  
Grade B (Very good): 0  
Grade C (Good): 0  
Grade D (Fair): 0  
Grade E (Poor): 0

**Received:** February 25, 2021

**Peer-review started:** February 25, 2021

**First decision:** April 4, 2021

**Revised:** April 19, 2021

**Accepted:** April 26, 2021

**Article in press:** April 26, 2021

**Published online:** July 6, 2021

**P-Reviewer:** Snyder J

**S-Editor:** Wang JL

**L-Editor:** Filipodia

**P-Editor:** Yuan YY



## CONCLUSION

The individualized total arterial strategy based on the vessels targeting individual anatomic characteristics can achieve complete revascularization with satisfactory short-term grafting patency rate.

**Key Words:** Total arterial revascularization; Coronary artery bypass grafting; Radial artery; Right gastroepiploic artery

©The Author(s) 2021. Published by Baishideng Publishing Group Inc. All rights reserved.

**Core Tip:** To determine whether total arterial revascularization is superior to conventional coronary artery bypass surgery (CABG), we observed the efficacy and clinical outcomes in patients receiving three major arterial grafts during arterial revascularization surgery. All patients were discharged without occurrence of death. Over a follow-up of 3 mo to 1 year, the number of anastomoses was high, the graft occlusion rate was low, and no severe complications occurred. The use of arterial conduits generally provides significantly better late survival especially in patients with multi-vessel coronary disease, cardiac event-free survival and improved health-related quality of life compared to conventional CABG.

**Citation:** Chen WG, Wang BC, Jiang YR, Wang YY, Lou Y. Clinical application of individualized total arterial coronary artery bypass grafting in coronary artery surgery. *World J Clin Cases* 2021; 9(19): 5073-5081

**URL:** <https://www.wjgnet.com/2307-8960/full/v9/i19/5073.htm>

**DOI:** <https://dx.doi.org/10.12998/wjcc.v9.i19.5073>

## INTRODUCTION

Coronary heart disease (CHD), a common clinical heart disease, is one of the diseases with the highest mortality rate worldwide[1]. Despite the continuous development of interventional techniques, coronary artery bypass grafting is still the ideal and standard treatment for multi-vessel coronary artery disease[2]. The long-term patency rate after coronary artery bypass surgery (CABG) is an important factor influencing the prognosis of patients. At present, an internal mammary artery and one or more great saphenous veins grafts (SVGs) are commonly used as conduit for transmyocardial revascularization. However, bypass with SVG is associated with gradual atherosclerosis and occlusion, and its patency rate is much lower than that of arterial bypass. It follows that SVG occlusion is proved to be a stumbling block for CABG. Accordingly, the concept of total arterial revascularization with minimum of SVG is called out. In this study, total arterial CABG was performed in 35 patients with CHD at the authors' department and has archived satisfactory clinical results.

## MATERIALS AND METHODS

### Clinical materials

Thirty-five patients with CHD undergoing total arterial CABG at Fourth Affiliated Hospital of Harbin Medical University (Harbin, China) between April 2016 and December 2019 were selected as the study subjects (Table 1). There were 26 males and 9 females with an average age of  $56 \pm 8.75$  years (range: 33 to 73 years), of whom 2 were over 70-years-old, 12 were diagnosed with diabetes mellitus, 6 underwent left main coronary artery surgery, 29 were diagnosed with multi-vessel disease, and 8 patients were diagnosed with acute myocardial infarction. Specifically, 35 patients received left internal mammary artery (LIMA) grafts and 35 received radial artery (RA) grafts including 12 who received bilateral RA grafts and 9 who received right gastroepiploic artery (RGEA) grafts during the CABG surgery.

**Table 1 Patient information in this study (n = 35)**

Clinical data	n (%)
Age (yr)	56.5 ± 6.5
Gender	
Male	26 (74.3)
Female	9 (25.7)
Hypertension	22 (62.9)
Hyperlipemia	7 (20.0)
Diabetes	11 (31.4)
Myocardial infarction	6 (17.1)
History of PCI	0 (0)
Cerebrovascular accident	4 (11.4)
Renal insufficiency	2 (5.7)
Family history of coronary heart disease	2 (5.7)
Smoking history	15 (42.9)
Drinking history	6 (17.1)
Cardiac functional grading	
Class II	5 (20.0)
Class III	30 (80.0)
History of atrial fibrillation	1 (2.9)
Ejection fraction	61.1 ± 5.5

PCI: Percutaneous coronary intervention.

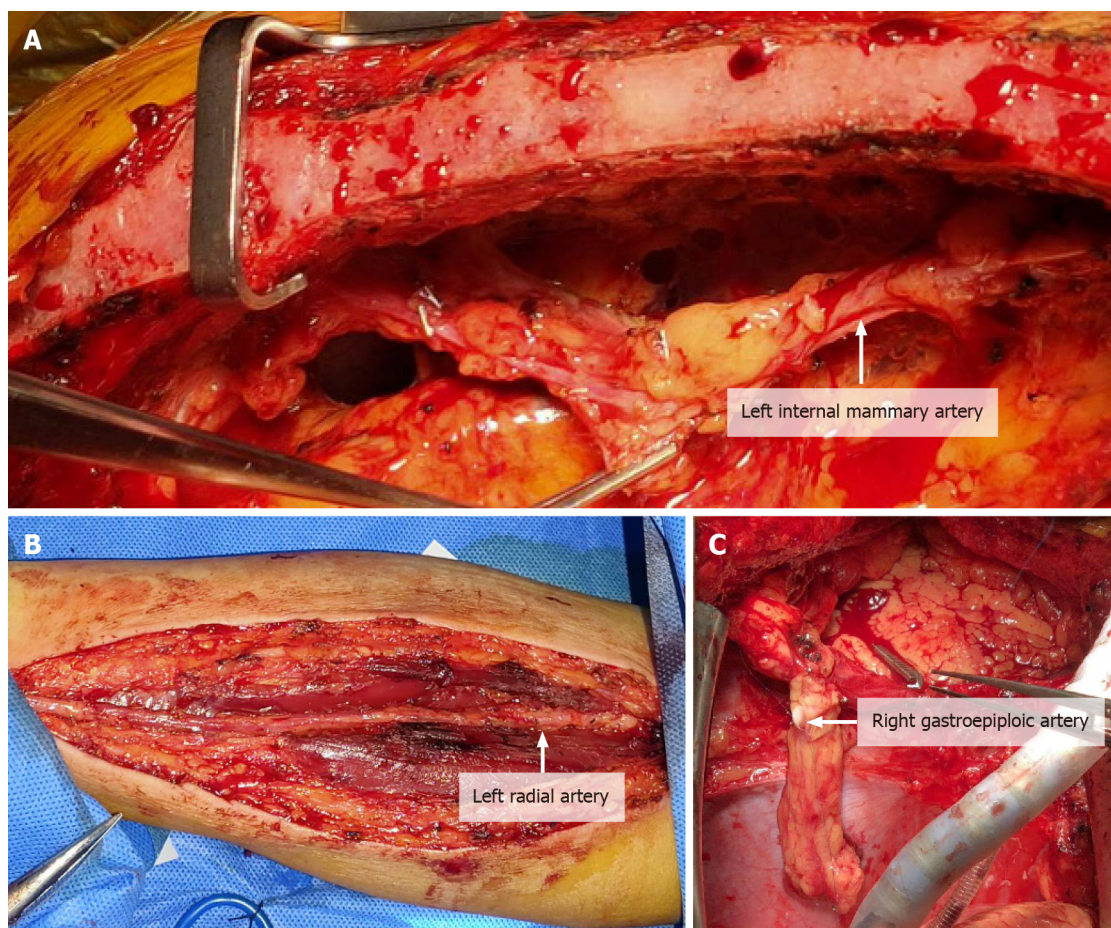
### Preoperative preparation

Routine preoperative testing was carried out *via* coronary angiography, echocardiography, computed tomography (CT) chest scan, CT head scan, arterial blood gas analysis, and blood test to comprehensively assess the basic preoperative situations of patients. For patients with myocardial infarction or complicated with mitral regurgitation, diuretics were routinely administrated to maintain homeostasis and actively improve their cardiopulmonary function. The modified Allen's test for routine preoperative testing was performed in patients who planned to undergo bypass surgery with RA prepared as a conduit. If time to thenar eminence relief was less than or equal to 6 s, it was considered negative. Moreover, if the ultrasound of upper extremity vessels showed no obvious tunica intima injuries or thrombosis, it was suggested that RA should be chosen as an arterial graft[3]. The availability RA was not allowed in patients with a history of forearm trauma, anomalous RA anatomy or Raynaud's disease or in patients whose RA is the dominant artery of forearms. RGEA was prepared for CT scan of the abdomen in routine preoperative testing to see if there were any primary abdominal lesions or calcification in patients requiring bypass surgery. Computed tomography angiography (CTA) test should be further performed in patients with calcification in the abdominal aorta to discover whether celiac artery stenosis occurred. In addition, patients were examined for celiac artery stenosis. For patients with confirmed or suspected celiac artery stenosis, it was not recommended RGEA should be used as the arterial conduits. Doppler ultrasound was also used in routine preoperative testing to check the diameter of internal mammary artery and blood flow in the internal mammary artery.

### Procedures

**LIMA harvest:** Median sternotomy was performed. The LIMA was separated from the branches to the first intercostal artery to the bifurcation of the internal mammary artery and the superior abdominal wall artery while branches along the way were clamped using titanium clips (Figure 1A).





**Figure 1 Procedures.** A: Location and harvest of left internal mammary artery; B: Location and harvest of radial artery; C: Location and harvest of right gastroepiploic artery.

**RA harvest:** RA incision extended from 2 cm to the elbow joint to transverse 2–3 cm incision in the wrist flexor fold. Arc incision was made along the RA pulse and around the medial to the edge of flexor carpi radialis. Always be mindful of preservation of the superficial branches to radial nerve and lateral cutaneous nerve of forearm. RA and its two accompanying satellite veins should be exposed and should be divided together using the “non-touch technique.” The branches should be treated with titanium clips to avoid spasticity. It is also suggested that papaverine saline should be used to spray, soak and wash and preserve branches (Figure 1B).

**RGEA harvest:** To harvest a GEA graft, the median sternotomy incision should be extended to 3–5 cm below the xiphoid process and entered the abdominal cavity. The RGEA was separated along the middle of the greater curvature of the stomach to the margin of pylorus. The branch vessels should be clamped using titanium clips and the branches on the side of the greater curvature of the stomach should be cut off. In addition, papaverine hydrochloride solution should be sprayed locally for standby use (Figure 1C).

Schemes were formulated for individualized total arterial revascularization CABG by comprehensively considering factors such as preoperative coronary angiography, distribution and calcification of target vessels during operation, heart size and the length of grafted vessel. A variety of conduits could be used for the surgery such as Y or T grafting configuration. If the length of LIMA was not long enough to be anastomosed with the anterior descending branch, or the flow rate was slightly poor, its diagonal branch could be selected to realize anastomosis. Actually, RA should be used to be anastomosed with the anterior descending branch. The median sternal incision was adopted and systemic heparin (1.5 mg/kg) was given to main the activated clotting time for more than 300 s. The ascending aorta was clamped with lateral forceps and the proximal end graft anastomoses should be managed firstly. Distal anastomosis and off pump coronary artery bypass (OPCAB) surgery was performed with anterior descending branch, diagonal branch, circumflex branch, right

coronary artery or posterior descending branch and posterior branch of left ventricle selected as graft sequence. When RGEA was used, an incision was made on the diaphragm at the anastomotic position within the coronary artery, and then the artery was fixed on epicardium. At last, neutralization, hemostasis and sternal closure were performed.

### **Perioperative management**

After surgery, stable hemodynamic level and internal environment should be maintained. Myocardial markers were monitored regularly to ensure adequate volume and avoid using large dose of alpha receptor agonists. Considering the characteristics of spasticity for vessel grafts, apart from the no-touch technique used during the operation, continuous intravenous pumping of diltiazem (0.5 to 1 µg/kg per min) should also be administered during the operation and within 48 h after the operation. Moreover, oral diltiazem should be given to patients up to 1 year after surgery. If drainage decreased after the surgery, low molecular weight heparin could be injected subcutaneously on the first postoperative day or in the morning on the next day twice a day for 5 to 7 d. In addition, antiplatelet agents such as Bayaspirin and clopidogrel/ticagrelor should be taken orally timely.

## **RESULTS**

All 35 patients in the study underwent OPCAB. The surgeries were successful and all of them recovered and were discharged with no deaths reported. During the follow-up, all the symptoms of angina were relieved and the cardiac function class was between class I and class II. In general, a total of 90 vessels were grafted with an average of 2.6 vessels per person. LIMA was chosen in 35 patients, RA was chosen in 35 patients including bilateral harvesting of RA in 12 patients and RGEA in 9 patients. During a 3-mo to 1-year follow-up, no occlusion was discovered for LIMA graft and RA graft occlusion occurred in 3 patients with graft occlusion rate of 6.5% and occlusion of RGEA occurred in 1 patient with graft occlusion rate of 11.1%. Graft occlusion rate was 6.2% in patients with diabetics. No graft occlusion was observed in patients over 70 years old. Two patients had mild numbness in left forearm and left thumb and returned to normal at 1 wk after surgeries, with no other complications of forearm and hand and no abdominal complications such as gastrointestinal complications (Figure 2).

## **DISCUSSION**

In 1967, Favaloro and Johnson succeeded in using greater saphenous vein (GSV) as a bypass conduit for the grafting procedure between the aorta and a coronary artery. Since then, the said method has been introduced and popularized rapidly because of its definite curative effect. Subsequently, it has become the main surgical treatment for CHD. However, after years of follow-up and observation, it was found that the GSV was prone to intimal hyperplasia and sclerosis, and the long-term patency rate was low with a 10-year patency rate of merely 50%[4]. As far as conduit materials are concerned, artery graft showed superior long term potency to SVG. In the literature, studies have confirmed that use of more than two artery conduits is associated with decreased mortality or improved long-term survival[5]. Benefits due to the use of conduit was not only limited to its excellent long-term patency but was also involved its protection of coronary circulation[6]. It is the development tendency of CABG to preferably use arterial conduits to take the place of SVG and gradually achieve multi-arterial and even total arterial revascularization.

LIMA, the gold standard choice as an arterial conduit for CABG, has a sound long-term patency rate. As space is limited, the detailed advantages of LIMA will not be elaborated upon here. However, it is impossible to achieve revascularization for all target vessels due to the limited length. The clinical application of other arterial conduits is a good supplement to LIMA such as RIMA, RA, right gastroepiploic artery, inferior epigastric artery, and descending branch of lateral circumflex femoral artery. In view of the fact that the use of bilateral LIMA grafts may aggravate postoperative pain, reduce sternum perfusion, as well as increase the probability of non-healing sternum and incision and the probability of sternal wound infection and deep infection[7], the authors' department has not adopted it extensively. Regarding inferior



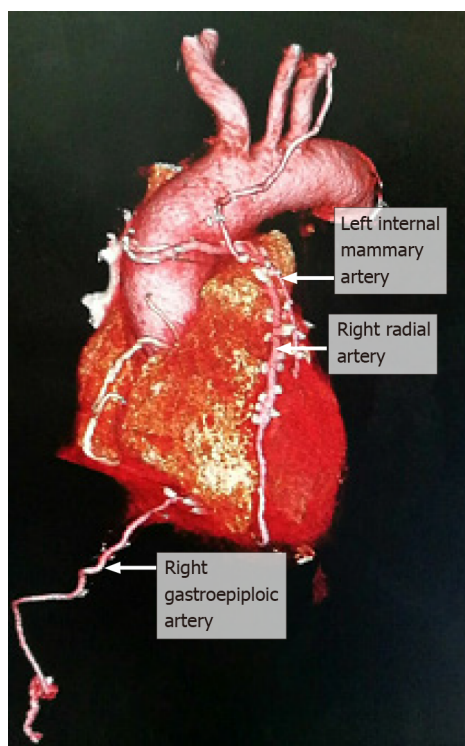


Figure 2 Postoperative reexamination.

epigastric artery and descending branch of lateral circumflex femoral artery, they have been rarely used in clinical practice because of issues such as subsidiary injury and poor long-term patency.

Attention is raised to RA because of the advantages such as easy access to easy to anatomy harvest, suitable caliber, all-round use, manageability, less complications, and less influence on forearm blood flow. A total of 46 RA grafts were used in 35 patients in the authors' department and 3 of them were occluded in short-term period with an occlusion rate of 6.5%. There was no significant difference when compared with the occlusion rate of 6.7% reported by Cao *et al*[8]. Nevertheless, it was slightly lower when compared with the 1-year occlusion rate of 8.2% for coronary angiography reported in a study by Desai *et al*[9]. The author believes that two of the occlusions were associated with the use of right RA which underwent coronary angiography before operation. Besides, time interval between the operation and angiography was only 1 or 2 d. Although preoperative vascular ultrasound confirmed that the blood flow was unobstructed and occlusion 2 cm from the puncture was removed during the operation, the occlusion rate was still high. Zacharias *et al*[10] believe that preoperative angiography of right RA may cause damages to the integrity and function of the endothelium of RA. Moreover, the damages cannot be completely recovered even at 15 d after the operation. Gaudino *et al*[11] even believe that the damages may extend to 30 d. In addition, of the three occluded radial arteries, two were anastomosed with the diagonal branch, which is thought to be associated with the competitive flow after recanalization of LIMA and anterior descending artery. It is worth mentioning that the existence of competitive flow may lead to the decrease of blood flow and accelerate its occlusion. Therefore, in the CABG guidelines jointly formulated by the American College of Cardiology Foundation and the American Heart Association in 2011, RA grafting was recommended (class IIb) in left coronary artery (coronary artery stenosis > 70%) or right coronary artery (coronary artery stenosis  $\geq$  90%) bypass grafting surgeries[12]. In this study, the graft occlusion rate was 6.2% in diabetic patients and no graft occlusion was observed in patients over 70-years-old, which was not significantly different from the reports made by Habib *et al*[13] and Hoffman *et al*[14]. It showed that diabetes and age over 70-years-old were not contraindications to RA harvesting. By contrast, the use of RA graft can be beneficial to their survival. The long-term patency rate of RA grafting is better than that of SVG grafting or even close to LIMA grafting, which will definitely play a key role in total arterial CABG. Although the utilization rate of RA grafting in CABG is not as high as expected, it still has bright prospects in the future.

RGEA grafting will not cause artery ischemia injury when it is used for grafting due to its ideal length and appropriate caliber, the same histological structure as LIMA and being independent of external nutrient vessels for nutrition. Moreover, atherosclerosis rarely occurs in RGEA grafting. Its anatomical position is close to diaphragm surface of the heart, which makes it particularly suitable for the revascularization of right coronary artery and multiple coronary arteries on the diaphragmatic surface of heart [15]. In this study, nine right gastroepiploic arteries were anastomosed with the right coronary artery (posterior descending branch and left ventricular posterior branch). The short-term follow-up CTA examination showed that one vessel was occluded, with an occlusion rate of 11.1%. Its patency rate was slightly lower than the recent patency rate of 92.4% reported by Ali *et al* [16] after an analysis and summary of the literature concerning RGEA grafting vessels published from 2000 to 2007, which may be associated with vasospasm caused during the early stage of operation. Kamohara *et al* [17] thought that RGEA graft could be safely used for CABG if its average diameter was more than 2 mm. Lee *et al* [18] believed that RGEA might not be suitable for CABG if its average diameter was less than 1.4 mm. Considering its characteristics of small diameter tube and being prone to spasm, the operation has been further improved, calcium antagonists have been used, and alpha receptor agonists have been less used in the later stage. To date, no graft occlusion has occurred. In addition, competitive flow is still a factor that shall not be ignored. In the occlusion cases in this study, investigators used RGEA to anastomose with the posterior descending branch with 70% to 90% stenosis. However, Ryu *et al* [19] thought that when a vessel is used as a target vessel for right gastroepiploic artery, its stenosis rate should be over 90% to obtain a better effect. Therefore, the selection of target vessel is very vital in RGEA surgery. No abdominal complications such as gastrointestinal complications occurred during the study period. Therefore, for young patients without gastric diseases who prepared to undergo upper abdominal surgery, especially for patients whose ascending aortas are unsuitable for anastomosis because of calcification, it is a good choice to have their right gastroepiploic arteries anastomosed with severely stenosed right coronary artery.

## CONCLUSION

This study demonstrated that the individualized total arterial CABG does not increase surgical trauma, perioperative complications, and mortality. By contrast, it has sound surgical safety and short-term clinical efficacy. Although artery graft has a tendency to develop spasm, it has high patency rate, which can significantly reduce the adverse cardiovascular events to avoid reoperation and improve quality of life of patients. Therefore, for coronary heart disease patients who have reasonable life expectancy, individualized total arterial CABG is recommended to enhance the potential benefits of patients and society. In this study, the sample size of RA and RGEA grafting is small and the duration of follow-up is not long, which will have a certain impact on the statistical results. It is necessary to further expand the sample size and make a long-term follow-up of the total arterial grafts to observe its long-term clinical effect.

## ARTICLE HIGHLIGHTS

### Research background

Total arterial revascularization is characterized by better long-term patency results and outcomes such as fewer incidence of myocardial infarctions and angina, lower incidence of reintervention, lower associated mortality rates and longer late survival and better quality of life than the traditional coronary artery bypass grafting (CABG).

### Research motivation

Considering the participants were young at enrollment, and most of them were in a good physical state without severe history of diseases, total arterial revascularization was performed to maximize the efficacy of CABG procedures and reduce the adverse effects caused by using one or more great saphenous veins grafts.

### Research objectives

The study reported here the efficacy and outcomes of total arterial coronary artery bypass grafting in 35 patients with non-single-vessel coronary artery diseases.

### Research methods

There are a variety of grafting techniques for arterial revascularization. The study selected three major strategies: left internal mammary artery (LIMA), radial artery (RA) and right gastroepiploic artery (RGEA) grafting. Thirty-five patients with non-single-vessel coronary artery diseases underwent CABG operation receiving the three kinds of grafts based on their physical conditions. Specifically, a total 90 vessels were grafted with an average of 2.6 vessels per person. Thirty-five patients received LIMA grafts, 35 patients received RA grafts and 9 patients received RGEA grafts. Perioperative complications and patency were observed, and quality of life was followed-up.

### Research results

Patients undergoing total arterial revascularization resulted in improved clinical outcomes. All the patients were discharged from hospitals without occurrence of deaths. Over the follow-up, no occlusion was discovered for LIMA graft and occlusion of RA and RGEA grafts was low without severe postoperative complications.

### Research conclusions

In spite of technical difficulty associated with the harvest of LIMA, RA and RGEA, total arterial revascularization provided favorable results especially in the aspect of anastomoses and patency compared with commonly used veins as grafts, which are more likely than artery grafts to develop plaque and become blocked over time.

### Research perspectives

The usage of total arterial revascularization is restricted by several factors such patient age and general health, history of other diseases and conditions. For instance, it should be avoided in patients with insulin-dependent diabetics, or in patients with severe chronic obstructive pulmonary disease because they are at a high risk of developing sternal wound infections and the availability of conduits was constrained. More real-world studies should be conducted to determine the individualized revascularization strategies in this population.

## REFERENCES

- 1 **Song YY**, Xu XH, Lu XH, Wang XW. Clinical application of individualized total arterial coronary artery bypass grafting. *Nanjing Yike Daxue Xuebao* 2019; **39**: 899-902
- 2 **Khan AR**, Golwala H, Tripathi A, Riaz H, Kumar A, Flaherty MP, Bhatt DL. Meta-analysis of Percutaneous Coronary Intervention Versus Coronary Artery Bypass Grafting in Left Main Coronary Artery Disease. *Am J Cardiol* 2017; **119**: 1949-1956 [PMID: [28442067](#) DOI: [10.1016/j.amjcard.2017.03.022](#)]
- 3 **Mohite PN**, Thingnam SK, Saxena AK. Radial artery compression in incomplete palmar arch for radial artery harvesting. *Asian Cardiovasc Thorac Ann* 2014; **22**: 416-420 [PMID: [24771729](#) DOI: [10.1177/0218492313490936](#)]
- 4 **Eagle KA**, Guyton RA, Davidoff R, Ewy GA, Fonger J, Gardner TJ, Gott JP, Herrmann HC, Marlow RA, Nugent WC, O'Connor GT, Orszulak TA, Rieselbach RE, Winters WL, Yusuf S, Gibbons RJ, Alpert JS, Eagle KA, Garson A Jr, Gregoratos G, Russell RO, Smith SC Jr. ACC/AHA Guidelines for Coronary Artery Bypass Graft Surgery: A Report of the American College of Cardiology/American Heart Association Task Force on Practice Guidelines (Committee to Revise the 1991 Guidelines for Coronary Artery Bypass Graft Surgery). American College of Cardiology/American Heart Association. *J Am Coll Cardiol* 1999; **34**: 1262-1347 [PMID: [10520819](#) DOI: [10.1016/s0735-1097\(99\)00389-7](#)]
- 5 **Pick AW**, Orszulak TA, Anderson BJ, Schaff HV. Single vs bilateral internal mammary artery grafts: 10-year outcome analysis. *Ann Thorac Surg* 1997; **64**: 599-605 [PMID: [9307445](#) DOI: [10.1016/s0003-4975\(97\)00620-6](#)]
- 6 **Dimitrova KR**, Hoffman DM, Geller CM, Dincheva G, Ko W, Tranbaugh RF. Arterial grafts protect the native coronary vessels from atherosclerotic disease progression. *Ann Thorac Surg* 2012; **94**: 475-481 [PMID: [22727250](#) DOI: [10.1016/j.athoracsur.2012.04.035](#)]
- 7 **Benedetto U**, Altman DG, Gerry S, Gray A, Lees B, Pawlaczyk R, Flather M, Taggart DP; Arterial Revascularization Trial investigators. Pedicled and skeletonized single and bilateral internal thoracic artery grafts and the incidence of sternal wound complications: Insights from the Arterial Revascularization Trial. *J Thorac Cardiovasc Surg* 2016; **152**: 270-276 [PMID: [27112712](#) DOI: [10.1016/j.jtcvs.2016.03.056](#)]
- 8 **Cao C**, Ang SC, Wolak K, Peeceeyen S, Bannon P, Yan TD. A meta-analysis of randomized controlled trials on mid-term angiographic outcomes for radial artery vs saphenous vein in coronary artery bypass graft surgery. *Ann Cardiothorac Surg* 2013; **2**: 401-407 [PMID: [23977615](#) DOI: [10.3978/j.issn.2225-319X.2013.07.03](#)]

- 9 **Desai ND**, Cohen EA, Naylor CD, Fremes SE; Radial Artery Patency Study Investigators. A randomized comparison of radial-artery and saphenous-vein coronary bypass grafts. *N Engl J Med* 2004; **351**: 2302-2309 [PMID: [15564545](#) DOI: [10.1056/NEJMoa040982](#)]
- 10 **Zacharias A**, Schwann TA, Riordan CJ, Durham SJ, Shah AS, Habib RH. Late results of conventional vs all-arterial revascularization based on internal thoracic and radial artery grafting. *Ann Thorac Surg* 2009; **87**: 19-26.e2 [PMID: [19101262](#) DOI: [10.1016/j.athoracsur.2008.09.050](#)]
- 11 **Gaudino M**, Leone A, Lupascu A, Toesca A, Mazza A, Ponziani FR, Flore R, Tondi P, Massetti M. Morphological and functional consequences of transradial coronary angiography on the radial artery: implications for its use as a bypass conduit. *Eur J Cardiothorac Surg* 2015; **48**: 370-374 [PMID: [25475945](#) DOI: [10.1093/ejcts/ezu456](#)]
- 12 **Hillis LD**, Smith PK, Anderson JL, Bittl JA, Bridges CR, Byrne JG, Cigarroa JE, Disesa VJ, Hiratzka LF, Hutter AM Jr, Jessen ME, Keeley EC, Lahey SJ, Lange RA, London MJ, Mack MJ, Patel MR, Puskas JD, Sabik JF, Selnes O, Shahian DM, Trost JC, Winniford MD. 2011 ACCF/AHA Guideline for Coronary Artery Bypass Graft Surgery: executive summary: a report of the American College of Cardiology Foundation/American Heart Association Task Force on Practice Guidelines. *Circulation* 2011; **124**: 2610-2642 [PMID: [22064600](#) DOI: [10.1161/CIR.0b013e31823b5fee](#)]
- 13 **Habib RH**, Schwann TA, Engoren M. Late effects of radial artery vs saphenous vein grafting in patients aged 70 years or older. *Ann Thorac Surg* 2012; **94**: 1478-1484 [PMID: [22771490](#) DOI: [10.1016/j.athoracsur.2012.05.030](#)]
- 14 **Hoffman DM**, Dimitrova KR, Decastro H, Friedmann P, Geller CM, Ko W, Tranbaugh RF. Improving long term outcome for diabetic patients undergoing surgical revascularization by use of the radial artery conduit: a propensity matched study. *J Cardiothorac Surg* 2013; **8**: 27 [PMID: [23421972](#) DOI: [10.1186/1749-8090-8-27](#)]
- 15 **Huang FJ**, Yang JF, Lai YQ, Xu CL, Wu Q. Right gastroepiploic artery as a coronary bypass graft in coronary artery bypass graft surgery: an experience of 32 cases. *Zhonghua Waikao Zazhi* 2005; **43**: 98-99
- 16 **Ali E**, Saso S, Ashrafian H, Athanasiou T. Does a skeletonized or pedicled right gastro-epiploic artery improve patency when used as a conduit in coronary artery bypass graft surgery? *Interact Cardiovasc Thorac Surg* 2010; **10**: 293-298 [PMID: [19903686](#) DOI: [10.1510/icvts.2009.221226](#)]
- 17 **Kamohara K**, Minato N, Minematsu N, Yunoki J, Hakuba T, Satoh H, Morokuma H, Takao Y. Preoperative evaluation of the right gastroepiploic artery on multidetector computed tomography in coronary artery bypass graft surgery. *Ann Thorac Surg* 2008; **86**: 1444-1449 [PMID: [19049728](#) DOI: [10.1016/j.athoracsur.2008.06.055](#)]
- 18 **Lee DH**, Lee W, Kim KB, Cho KR, Park EA, Chung JW, Park JH. Availability of the right gastroepiploic artery for coronary artery bypass grafting: preoperative multidetector CT evaluation. *Int J Cardiovasc Imaging* 2010; **26**: 303-310 [PMID: [20878251](#) DOI: [10.1007/s10554-010-9713-1](#)]
- 19 **Ryu SW**, Ahn BH, Choo SJ, Na KJ, Ahn YK, Jeong MH, Kim SH. Skeletonized gastroepiploic artery as a composite graft for total arterial revascularization. *Ann Thorac Surg* 2005; **80**: 118-123 [PMID: [15975352](#) DOI: [10.1016/j.athoracsur.2005.02.008](#)]



Published by **Baishideng Publishing Group Inc**  
7041 Koll Center Parkway, Suite 160, Pleasanton, CA 94566, USA

**Telephone:** +1-925-3991568

**E-mail:** [bpgoffice@wjgnet.com](mailto:bpgoffice@wjgnet.com)

**Help Desk:** <https://www.f6publishing.com/helpdesk>

<https://www.wjgnet.com>

