

Intestinal obstruction due to migration of a thermometer from bladder to abdominal cavity: A case report

Jing Nie, Bo Zhang, Yan-Chao Duan, Yue-Hua Hu, Xin-Ying Gao, Jian Gong, Ming Cheng, Yan-Qing Li

Jing Nie, Bo Zhang, Yan-Qing Li, Department of Gastroenterology, Qilu Hospital, Shandong University, Jinan 250012, Shandong Province, China

Yan-Chao Duan, Department of Internal Medicine, Affiliated Hospital of Taishan Medical University, Taian 271000, Shandong Province, China

Jing Nie, Yue-Hua Hu, Xin-Ying Gao, Jian Gong, Department of Gastroenterology, Taian Central Hospital, Taian 271000, Shandong Province, China

Bo Zhang, Department of Infections, Taian Central Hospital, Taian 271000, Shandong Province, China

Ming Cheng, Department of General Surgery, Taian Central Hospital, Taian 271000, Shandong Province, China

Author contributions: Nie J and Zhang B contributed equally to this work; Nie J, Zhang B, Duan YC, Hu YH, Gao XY, Gong J, Cheng M and Li YQ collected the data and managed and reviewed the case; Nie J and Zhang B wrote the paper.

Correspondence to: Yan-Qing Li, Professor, Department of Gastroenterology, Qilu Hospital, Shandong University, 107 West Wenhua Road, Jinan 250012, Shandong Province, China. niejingjing2006@163.com

Telephone: +86-538-6298473 Fax: +86-538-8223227

Received: October 21, 2013 Revised: November 14, 2013

Accepted: January 8, 2014

Published online: March 7, 2014

meter was adhering to the small bowels and mesentery which resulted in intestinal obstruction. Abdominal cramps were eliminated and defecation and flatus recovered soon after removal of the thermometer.

© 2014 Baishideng Publishing Group Co., Limited. All rights reserved.

Key words: Intestinal obstruction; Foreign body; Thermometer; Transmural migration; Bladder

Core tip: Intestinal obstruction due to transmural migration of foreign body is a rare condition. Here we report a case of intestinal obstruction due to transmural migration of a thermometer from the bladder to the abdominal cavity. The patient recovered soon after removal of the thermometer.

Nie J, Zhang B, Duan YC, Hu YH, Gao XY, Gong J, Cheng M, Li YQ. Intestinal obstruction due to migration of a thermometer from bladder to abdominal cavity: A case report. *World J Gastroenterol* 2014; 20(9): 2426-2428 Available from: URL: <http://www.wjgnet.com/1007-9327/full/v20/i9/2426.htm> DOI: <http://dx.doi.org/10.3748/wjg.v20.i9.2426>

Abstract

Intraperitoneal foreign bodies such as retained surgical instruments can cause intestinal obstruction. However, intestinal obstruction due to transmural migration of foreign bodies has rarely been reported. Here, we report a case of intestinal obstruction due to a clinical thermometer which migrated from the bladder into the abdominal cavity. A 45-year-old man was admitted to our hospital with a one-year history of recurrent lower abdominal cramps. Two days before admission, the abdominal cramps aggravated. Intestinal obstruction was confirmed with upright abdominal radiography and computerized tomography scan which showed dilation of the small intestines and a thermometer in the abdominal cavity. Then laparotomy was performed. A scar was observed at the fundus of the bladder and a ther-

INTRODUCTION

Intraperitoneal foreign bodies are common events in children, alcoholics, psychiatric patients and criminals^[1]. They can be categorized as either intraluminal or extraluminal of gastrointestinal tract. Intraluminal ones are usually ingested coins, buttons, pins, batteries and so on^[2]. They can be lodged in narrow areas (*i.e.*, pylorus and ileocecal valve), resulting in obstruction or perforation^[1]. Extraluminal ones, such as retained surgical sponges, are infrequently encountered in patients who have been treated with prior surgery or some other interventional medical procedures. They can lead to intestinal obstruction or abscess formation with or without secondary bacterial

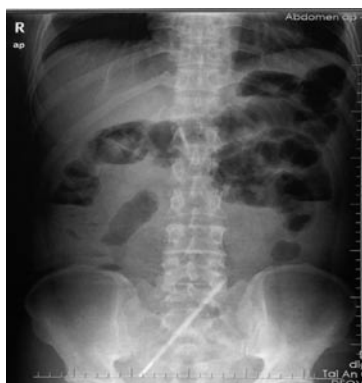

Figure 1 Abdominal X-ray showed dilation of the small intestines, gas-fluid levels and a thermometer-like object in the abdominal cavity.

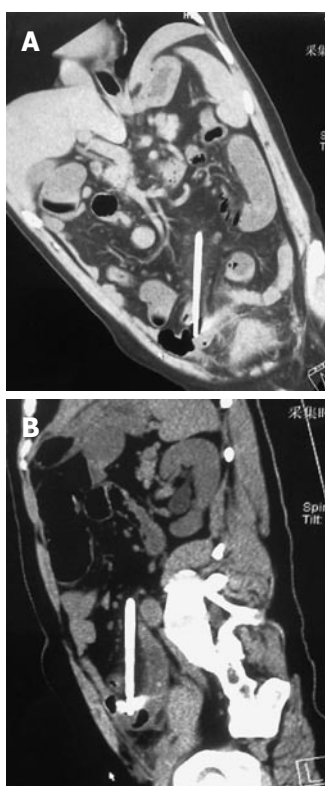


Figure 2 Computerized tomography scan revealed thin walls of intestines and a thermometer-like object in the lower quadrant of the abdomen (A, B).

infection^[3]. Foreign bodies can be detected by abdominal radiography and computerized tomography (CT)^[4]. Here we report a rare case of intestinal obstruction due to transmural migration of a thermometer from the bladder to the abdominal cavity.

CASE REPORT

In April 2013, a 45-year-old man was admitted to our hospital with a one-year history of recurrent lower abdominal cramps. The symptoms could be alleviated with antibiotic treatment. Two days before admission, the abdominal cramps aggravated, and defecation and flatus stopped. On physical examination, he had a regular pulse

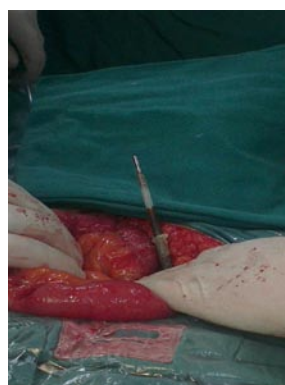

Figure 3 Thermometer coated with pus was seen pressing on the small bowels and mesentery.

of 82 beats/min, a respiratory rate of 20 breaths/min, and a temperature of 37.6 °C. His cardiopulmonary and neurologic examinations were normal. Abdominal examination revealed distension with lower abdomen tenderness and rebound tenderness. Abdominal rumbling sound was weak. Blood routine test revealed a white blood cell count of $8.78 \times 10^9/L$, neutrophil 87.41%, lymphocyte 8.3%, hemoglobin concentration 12.8 g/dL, and platelet count $173 \times 10^9/L$. The serum level of C-reactive protein was 75.1 mg/L. Abdominal radiography showed dilation of the small intestines, gas-fluid levels and a thermometer-like object in the abdominal cavity (Figure 1). CT scan revealed thin walls of the intestines and a thermometer-like object in the lower quadrant of abdominal cavity (Figure 2). He was diagnosed with intestinal obstruction.

The patient was addicted to alcohol. When he was drunk, he would behave strangely. He admitted that he had inserted a thermometer into the urinary passage through the penis two years ago without referring to a doctor. Subsequently, he experienced increased urinary frequency and urgency and enlarged testicles with pain. For this, he would take antibiotics to control the pain.

After the examinations, the patient was sent to the operation room immediately and exploratory laparotomy was performed *via* lower abdominal midline incision. After opening the abdomen, much purulent exudative fluid was sucked out. A scar was observed at the fundus of the bladder and a thermometer was adhering to the small bowels and mesentery, resulting in intestinal obstruction (Figure 3). Three hundred milliliters of normal saline was injected to the bladder through a urinary catheter during the operation and no fluid exuded from around the scar. Abdominal cramps were eliminated and defecation and flatus recovered soon after removal of the thermometer.

DISCUSSION

This is a case report of intraperitoneal foreign body that led to intestinal obstruction. This patient denied ingestion of foreign bodies or prior surgical surgery. We found that the obstruction was due to a thermometer migrating from the bladder to the abdominal cavity. When there is a breakage on the bladder wall, bacteria can travel between

the urinary passage and the abdominal cavity, leading to urinary infection and intra-abdominal inflammation, which can be alleviated with antibiotic therapy as seen in our patient. The scar at the fundus of the bladder is the evidence of perforation. Furthermore, our patient was alcoholic with psychiatric problems. He admitted inserting a thermometer into urinary passage two years before.

Urinary system foreign bodies, especially bladder ones, are frequently encountered. Most of them come from the urinary tract that are inserted by the patients themselves because of being curious about sex and genital organ^[5-7]. But perforation of bladder is rarely reported. It manifests as increased urinary frequency and urgency, hematuria, abdominal pain, *etc.* In our case, fortunately, the thermometer was not broken, otherwise it would cause severe clinical events, such as intestinal perforation and mercury poisoning^[8,9].

To our knowledge, this is the first case report of intestinal obstruction due to transmural migration of a thermometer from the bladder to the abdominal cavity. Based on our experience, a thorough history of patients should be acquired to confirm the ingestion or insertion of any foreign bodies. If patients showed signs of intestinal obstruction, surgery should be performed to avoid further complications.

COMMENTS

Case characteristics

A 45-year-old man presented with recurrent lower abdominal cramps.

Clinical diagnosis

Abdominal distension with lower abdomen tenderness and rebound tenderness.

Differential diagnosis

Intestinal neoplasm, abdominal abscess, and urinary tract infection.

Laboratory diagnosis

WBC $8.78 \times 10^9/L$, Neutrophil 87.41%, and CRP 75.1 mg/L.

Imaging diagnosis

Abdominal radiography and computerized tomography scan showed dilation of the small intestines and a thermometer-like object in the abdominal cavity.

Treatment

Exploratory laparotomy was performed and a thermometer was removed.

Related reports

This is the first case report of intestinal obstruction due to transmural migration

of a thermometer from bladder to abdominal cavity.

Experiences and lessons

Foreign object detained in the bladder can penetrate into the abdominal cavity and cause intestinal obstruction and peritonitis.

Peer review

This case report describes a rare condition that intestinal obstruction occurred due to a clinical thermometer which migrated from the bladder into the abdominal cavity.

REFERENCES

- 1 Samdani T, Singhal T, Balakrishnan S, Hussain A, Grandy-Smith S, El-Hasani S. An apricot story: view through a key-hole. *World J Emerg Surg* 2007; **2**: 20 [PMID: 17697369 DOI: 10.1186/1749-7922-2-20]
- 2 Paltal R, Sahota A, Bemarki A, Salama P, Simpson N, Laine L. Foreign-body ingestion: characteristics and outcomes in a lower socioeconomic population with predominantly intentional ingestion. *Gastrointest Endosc* 2009; **69**: 426-433 [PMID: 19019363 DOI: 10.1016/j.gie.2008.05.072]
- 3 Kato T, Yamaguchi K, Kinoshita K, Sasaki K, Kagaya H, Meguro T, Morita T, Takahashi T, Tamaki N, Horita S. Intestinal Obstruction due to Complete Transmural Migration of a Retained Surgical Sponge into the Intestine. *Case Rep Gastroenterol* 2012; **6**: 754-759 [PMID: 23341797 DOI: 10.1159/000346285]
- 4 Gayer G, Petrovitch I, Jeffrey RB. Foreign objects encountered in the abdominal cavity at CT. *Radiographics* 2011; **31**: 409-428 [PMID: 21415187 DOI: 10.1148/rg.312105123]
- 5 Sukkarieh T, Smaldone M, Shah B. Multiple foreign bodies in the anterior and posterior urethra. *Int Braz J Urol* 2004; **30**: 219-220 [PMID: 15689253 DOI: 10.1590/S1677-55382004000300009]
- 6 Jiménez Parra JD, Cebrián Lostal JL, Alvarez Bandrés S, García García D, Lozano Uruñuela F, Abadía Durán J. Urethral foreign body. *Arch Esp Urol* 2013; **66**: 324-325 [PMID: 23648756]
- 7 Eguíluz Lumbreras P, Palacios Hernández A, Heredero Zorzo O, Grinard De León EA, Martín Parada A, Gómez Zancajo VR, Urrutia Avisrror M. Intravesical thermometer. *Arch Esp Urol* 2012; **65**: 269 [PMID: 22414459]
- 8 Pigatto PD, Guzzi G. Management of subcutaneous implantation of mercury after broken thermometer. *J Am Acad Dermatol* 2010; **63**: e37; author reply e37 [PMID: 20633779 DOI: 10.1016/j.jaad.2009.12.060]
- 9 Aprahamian N, Lee L, Shannon M, Hummel D, Johnston P, Kimia A. Glass thermometer injuries: it is not just about the mercury. *Pediatr Emerg Care* 2009; **25**: 645-647 [PMID: 21465690 DOI: 10.1097/PEC.0b013e3181b920cc]

P- Reviewers: Akbulut S, Coccolini F, Kanno Y
S- Editor: Ma YJ L- Editor: A E- Editor: Wang CH





Published by **Baishideng Publishing Group Co., Limited**

Flat C, 23/F., Lucky Plaza,
315-321 Lockhart Road, Wan Chai, Hong Kong, China

Fax: +852-65557188

Telephone: +852-31779906

E-mail: bpgoffice@wjgnet.com

<http://www.wjgnet.com>



ISSN 1007-9327

