

World Journal of *Clinical Cases*

World J Clin Cases 2021 September 6; 9(25): 7292-7613



Contents

Thrice Monthly Volume 9 Number 25 September 6, 2021

EDITORIAL

- 7292 Radiation oncology practice during COVID-19 pandemic in developing countries

Abuhijla F, Abuhijlih R, Mohamad I

OPINION REVIEW

- 7297 Complete mesocolic excision and central vascular ligation in colorectal cancer in the era of minimally invasive surgery

Franceschilli M, Di Carlo S, Vinci D, Sensi B, Siragusa L, Bellato V, Caronna R, Rossi P, Cavallaro G, Guida A, Sibio S

- 7306 Fecal diversion in complex anal fistulas: Is there a way to avoid it?

Garg P, Yagnik VD, Dawka S

MINIREVIEWS

- 7311 Regulatory roles of extracellular vesicles in immune responses against *Mycobacterium tuberculosis* infection

Yan Z, Wang H, Mu L, Hu ZD, Zheng WQ

- 7319 Aortic stenosis and Heyde's syndrome: A comprehensive review

Lourdusamy D, Mupparaju VK, Sharif NF, Ibebuogu UN

ORIGINAL ARTICLE

Retrospective Study

- 7330 Key determinants of misdiagnosis of tracheobronchial tuberculosis among senile patients in contemporary clinical practice: A retrospective analysis

Tang F, Lin LJ, Guo SL, Ye W, Zha XK, Cheng Y, Wu YF, Wang YM, Lyu XM, Fan XY, Lyu LP

- 7340 Long-term outcome of pancreatic function following oncological surgery in children: Institutional experience and review of the literature

Bolasco G, Capriati T, Grimaldi C, Monti L, De Pasquale MD, Patera IP, Spada M, Maggiore G, Diamanti A

- 7350 Efficacy of arbidol in COVID-19 patients: A retrospective study

Wei S, Xu S, Pan YH

- 7358 Characteristic analysis of clinical coronary heart disease and coronary artery disease concerning young and middle-aged male patients

Peng KG, Yu HL

- 7365 Quantitative analysis of early diabetic retinopathy based on optical coherence tomography angiography biological image

Shi Y, Lin PY, Ruan YM, Lin CF, Hua SS, Li B

- 7372** Mucin 1 and interleukin-11 protein expression and inflammatory reactions in the intestinal mucosa of necrotizing enterocolitis children after surgery

Pan HX, Zhang CS, Lin CH, Chen MM, Zhang XZ, Yu N

Observational Study

- 7381** Research on the prognosis of different types of microvessels in bladder transitional cell carcinoma

Wang HB, Qin Y, Yang JY

- 7391** Is burnout a mediating factor between sharps injury and work-related factors or musculoskeletal pain?

Chen YH, Tsai CF, Yeh CJ, Jong GP

- 7405** Role of international normalized ratio in nonpulmonary sepsis screening: An observational study

Zhang J, Du HM, Cheng MX, He FM, Niu BL

Randomized Controlled Trial

- 7417** Clinical effectiveness of adding probiotics to a low FODMAP diet: Randomized double-blind placebo-controlled study

Turan B, Bengi G, Cehreli R, Akpınar H, Soytürk M

SYSTEMATIC REVIEWS

- 7433** Association between COVID-19 and anxiety during social isolation: A systematic review

Santos ERRD, Silva de Paula JL, Tardieux FM, Costa-e-Silva VN, Lal A, Leite AFB

CASE REPORT

- 7445** Avascular necrosis of the first metatarsal head in a young female adult: A case report and review of literature

Siu RWH, Liu JHP, Man GCW, Ong MTY, Yung PSH

- 7453** Successful treatment of solitary bladder plasmacytoma: A case report

Cao JD, Lin PH, Cai DF, Liang JH

- 7459** Pseudomyxoma peritonei originating from intestinal duplication: A case report and review of the literature

Han XD, Zhou N, Lu YY, Xu HB, Guo J, Liang L

- 7468** Agranulocytosis following injection of inactivated Japanese encephalitis vaccine (Vero cell): A case report

Wang L, Zhang X, Liu YT

- 7472** Importance of clinical suspicion and multidisciplinary management for early diagnosis of a cardiac laminopathy patient: A case report

Santobuono VE, Guaricci AI, Carulli E, Bozza N, Pepe M, Ranauro A, Ranieri C, Carella MC, Loizzi F, Resta N, Favale S, Forleo C

- 7478** First case of forearm crisscross injury in children: A case report

Jiang YK, Wang YB, Peng CG, Qu J, Wu DK

- 7484** Octreotide-induced acute life-threatening gallstones after vicarious contrast medium excretion: A case report
Han ZH, He ZM, Chen WH, Wang CY, Wang Q
- 7490** Acute deep venous thrombosis induced by May-Thurner syndrome after spondylolisthesis surgery: A case report and review of literature
Yue L, Fu HY, Sun HL
- 7498** Successful treatment of refractory lung adenocarcinoma harboring a germline *BRCA2* mutation with olaparib: A case report
Zhang L, Wang J, Cui LZ, Wang K, Yuan MM, Chen RR, Zhang LJ
- 7504** Effective treatment of polyneuropathy, organomegaly, endocrinopathy, M-protein, and skin changes syndrome with congestive heart failure: A case report
Fu LY, Zhang HB
- 7512** Awake craniotomy for auditory brainstem implant in patients with neurofibromatosis type 2: Four case reports
Wang DX, Wang S, Jian MY, Han RQ
- 7520** Coexistence of tuberculosis and squamous cell carcinoma in the right main bronchus: A case report
Jiang H, Li YQ
- 7527** Is simultaneous presence of IgG4-positive plasma cells and giant-cell hepatitis a coincidence in autoimmune hepatitis? A case report
Tan YW, Wang JM, Chen L
- 7535** Surgical treatment of delayed cervical infection and incomplete quadriplegia with fish-bone ingestion: A case report
Li SY, Miao Y, Cheng L, Wang YF, Li ZQ, Liu YB, Zou TM, Shen J
- 7542** Neonatal biliary atresia combined with preduodenal portal vein: A case report
Xiang XL, Cai P, Zhao JG, Zhao HW, Jiang YL, Zhu ML, Wang Q, Zhang RY, Zhu ZW, Chen JL, Gu ZC, Zhu J
- 7551** Hemorrhagic transformation after acute ischemic stroke caused by polycythemia vera: Report of two case
Cao YY, Cao J, Bi ZJ, Xu SB, Liu CC
- 7558** Treatment of lower part of glenoid fractures through a novel axillary approach: A case report
Jia X, Zhou FL, Zhu YH, Jin DJ, Liu WX, Yang ZC, Liu RP
- 7564** Trigger finger at the wrist caused by an intramuscular lipoma within the carpal tunnel: A case report
Huang C, Jin HJ, Song DB, Zhu Z, Tian H, Li ZH, Qu WR, Li R
- 7572** Thrombolysis and embolectomy in treatment of acute stroke as a bridge to open-heart resection of giant cardiac myxoma: A case report
Chang WS, Li N, Liu H, Yin JJ, Zhang HQ
- 7579** Breast adenoid cystic carcinoma arising in microglandular adenosis: A case report and review of literature
An JK, Woo JJ, Kim EK, Kwak HY

- 7588** Diagnosis and management of ophthalmic zoster sine herpete accompanied by cervical spine disc protrusion: A case report
Yun G, Kim E, Baik J, Do W, Jung YH, You CM
- 7593** Hemorrhagic pericardial effusion following treatment with infliximab: A case report and literature review
Li H, Xing H, Hu C, Sun BY, Wang S, Li WY, Qu B
- 7600** Wernicke's encephalopathy in a rectal cancer patient with atypical radiological features: A case report
Nie T, He JL
- 7605** Total hip revision with custom-made spacer and prosthesis: A case report
Liu YB, Pan H, Chen L, Ye HN, Wu CC, Wu P, Chen L

ABOUT COVER

Editorial Board Member of *World Journal of Clinical Cases*, Lan Sun, MD, PhD, Chief Physician, Professor, Department of Oncology, The People's Hospital of Bishan District, Chongqing 402760, China. sunlan6203@163.com

AIMS AND SCOPE

The primary aim of *World Journal of Clinical Cases* (WJCC, *World J Clin Cases*) is to provide scholars and readers from various fields of clinical medicine with a platform to publish high-quality clinical research articles and communicate their research findings online.

WJCC mainly publishes articles reporting research results and findings obtained in the field of clinical medicine and covering a wide range of topics, including case control studies, retrospective cohort studies, retrospective studies, clinical trials studies, observational studies, prospective studies, randomized controlled trials, randomized clinical trials, systematic reviews, meta-analysis, and case reports.

INDEXING/ABSTRACTING

The WJCC is now indexed in Science Citation Index Expanded (also known as SciSearch®), Journal Citation Reports/Science Edition, Scopus, PubMed, and PubMed Central. The 2021 Edition of Journal Citation Reports® cites the 2020 impact factor (IF) for WJCC as 1.337; IF without journal self cites: 1.301; 5-year IF: 1.742; Journal Citation Indicator: 0.33; Ranking: 119 among 169 journals in medicine, general and internal; and Quartile category: Q3. The WJCC's CiteScore for 2020 is 0.8 and Scopus CiteScore rank 2020: General Medicine is 493/793.

RESPONSIBLE EDITORS FOR THIS ISSUE

Production Editor: Yan-Xia Xing; **Production Department Director:** Xiang Li; **Editorial Office Director:** Jin-Lai Wang.

NAME OF JOURNAL

World Journal of Clinical Cases

ISSN

ISSN 2307-8960 (online)

LAUNCH DATE

April 16, 2013

FREQUENCY

Thrice Monthly

EDITORS-IN-CHIEF

Dennis A Bloomfield, Sandro Vento, Bao-Gan Peng

EDITORIAL BOARD MEMBERS

<https://www.wjgnet.com/2307-8960/editorialboard.htm>

PUBLICATION DATE

September 6, 2021

COPYRIGHT

© 2021 Baishideng Publishing Group Inc

INSTRUCTIONS TO AUTHORS

<https://www.wjgnet.com/bpg/gerinfo/204>

GUIDELINES FOR ETHICS DOCUMENTS

<https://www.wjgnet.com/bpg/GerInfo/287>

GUIDELINES FOR NON-NATIVE SPEAKERS OF ENGLISH

<https://www.wjgnet.com/bpg/gerinfo/240>

PUBLICATION ETHICS

<https://www.wjgnet.com/bpg/GerInfo/288>

PUBLICATION MISCONDUCT

<https://www.wjgnet.com/bpg/gerinfo/208>

ARTICLE PROCESSING CHARGE

<https://www.wjgnet.com/bpg/gerinfo/242>

STEPS FOR SUBMITTING MANUSCRIPTS

<https://www.wjgnet.com/bpg/GerInfo/239>

ONLINE SUBMISSION

<https://www.f6publishing.com>



Hemorrhagic transformation after acute ischemic stroke caused by polycythemia vera: Report of two case

Ya-Yun Cao, Jie Cao, Zhua-Jin Bi, Sha-Bei Xu, Chen-Chen Liu

ORCID number: Ya-Yun Cao 0000-0001-5941-5460; Jie Cao 0000-0001-5492-5007; Zhua-Jin Bi 0000-0002-7247-9634; Sha-Bei Xu 0000-0001-5409-2092; Chen-Chen Liu 0000-0001-6589-3178.

Author contributions: Cao YY acquired the data and drafted the manuscript; Cao J acquired and analyzed the data; Bi ZJ analyzed and interpreted the imaging findings; Xu SB helped revise the manuscript; Liu CC designed the study and revised the manuscript; all authors have read and approved the manuscript.

Informed consent statement: Written informed consent was obtained from the patients for publication of this case report.

Conflict-of-interest statement: The authors declare no conflict of interest for this manuscript.

CARE Checklist (2016) statement: The authors have read the CARE Checklist (2016), and the manuscript was prepared and revised according to the CARE Checklist (2016).

Open-Access: This article is an open-access article that was selected by an in-house editor and fully peer-reviewed by external reviewers. It is distributed in accordance with the Creative

Ya-Yun Cao, Jie Cao, Zhua-Jin Bi, Sha-Bei Xu, Chen-Chen Liu, Department of Neurology, Tongji Hospital, Tongji Medical College, Huazhong University of Science and Technology, Wuhan 430000, Hubei Province, China

Ya-Yun Cao, Department of Radiology, Zhongnan Hospital of Wuhan University, Wuhan 430000, Hubei Province, China

Corresponding author: Chen-Chen Liu, MD, Doctor, Lecturer, Department of Neurology, Tongji Hospital, Tongji Medical College, Huazhong University of Science and Technology, No. 1095 Jiefang Avenue, Wuhan 430000, Hubei Province, China. liuchenchen8807@126.com

Abstract

BACKGROUND

Polycythemia vera (PV) is a chronic myeloproliferative disorder characterized by an increase in red blood cells in the peripheral blood. Previous work has reported the occurrence of thrombosis or hemorrhage arising in the cerebral vasculature secondary to PV. However, hemorrhagic transformation after PV-associated acute ischemic stroke has not been previously described.

CASE SUMMARY

We herein present two cases of PV where hemorrhagic transformation occurred after an acute ischemic stroke. Case 1 was a 57-year-old woman with a history of hypertension who was admitted for left-sided weakness. Case 2 was a 68-year-old man who was admitted for a 10-d sudden left arm weakness. Imaging examinations for the two patients revealed hemorrhagic transformation after acute ischemic stroke. Both patients had JAK-2-V617F mutation and received antiplatelet therapy. Both of them had a good prognosis during the follow-up.

CONCLUSION

This report suggested that hemorrhagic transformation may occur in acute ischemic stroke caused by PV. Antiplatelet drugs do not seem to influence the long-term outcomes in such patients. Future research should focus on establishing a standard antiplatelet treatment strategy for this condition.

Key Words: Polycythemia vera; Acute ischemic stroke; Hemorrhagic transformation; Antiplatelet treatment; Thrombosis; Case report

©The Author(s) 2021. Published by Baishideng Publishing Group Inc. All rights reserved.

Commons Attribution

NonCommercial (CC BY-NC 4.0) license, which permits others to distribute, remix, adapt, build upon this work non-commercially, and license their derivative works on different terms, provided the original work is properly cited and the use is non-commercial. See: <http://creativecommons.org/licenses/by-nc/4.0/>

Manuscript source: Unsolicited manuscript

Specialty type: Medicine, research and experimental

Country/Territory of origin: China

Peer-review report's scientific quality classification

Grade A (Excellent): 0
Grade B (Very good): B
Grade C (Good): C
Grade D (Fair): 0
Grade E (Poor): 0

Received: February 28, 2021

Peer-review started: February 28, 2021

First decision: July 5, 2021

Revised: July 12, 2021

Accepted: July 19, 2021

Article in press: July 19, 2021

Published online: September 6, 2021

P-Reviewer: Belen Fernandez A, Eyituooyo HO

S-Editor: Fan JR

L-Editor: Wang TQ

P-Editor: Li JH



Core Tip: Polycythemia vera (PV) is a rare, myeloproliferative disorder. Ischemic stroke is the most frequent neurologic manifestation of PV. However, hemorrhagic transformation after acute ischemic stroke caused by PV has not been previously reported. Here, we present two patients with PV who developed hemorrhagic transformation after sustaining an acute ischemic stroke. Antiplatelet drugs did not lead to poor long-term outcomes in our patients.

Citation: Cao YY, Cao J, Bi ZJ, Xu SB, Liu CC. Hemorrhagic transformation after acute ischemic stroke caused by polycythemia vera: Report of two case. *World J Clin Cases* 2021; 9(25): 7551-7557

URL: <https://www.wjgnet.com/2307-8960/full/v9/i25/7551.htm>

DOI: <https://dx.doi.org/10.12998/wjcc.v9.i25.7551>

INTRODUCTION

Polycythemia vera (PV) is a rare, myeloproliferative disorder characterized by the overproduction of erythrocytes, granulocytes, and megakaryocytes. It has been widely recognized that PV increases the incidence of thrombotic events, especially cerebral infarctions and transient ischemic attacks. Previous studies have revealed that ischemic stroke is the most frequent neurologic manifestation of PV[1]. Although not as common as thrombosis, hemorrhagic stroke has also been associated with PV[2,3]. To our knowledge, hemorrhagic transformation after acute ischemic stroke caused by PV has not been previously reported. Here, we present two patients with PV who developed hemorrhagic transformation after sustaining an acute ischemic stroke.

CASE PRESENTATION

Chief complaints

Case 1: A 57-year-old woman presented with a chief complaint of left-side weakness for 5 d ([Supplementary Figure 1](#)).

Case 2: A 68-year-old man was admitted to our hospital with left arm weakness for 10 d ([Supplementary Figure 2](#)).

History of present illness

Case 1: The patient had hypertension for 3 years.

Case 2: The patient was a smoker with an otherwise unremarkable medical history.

History of past illness

Case 1: The patient had hypertension for 3 years.

Case 2: The patient was a smoker with an otherwise unremarkable medical history.

Personal and family history

Case 1: The patient had hypertension for 3 years.

Case 2: The patient was a smoker with an otherwise unremarkable medical history.

Physical examination

Case 1: On admission, the patient's blood pressure was 154/93 mmHg. Physical examination revealed obvious redness on her face and hands, as well as left hemiplegia with a muscle strength grade of 3/5.

Case 2: Neurological examination showed the patient to be healthy, although he experienced left hemiplegia of 0/5 as assessed by the manual muscle test.

Laboratory examinations

Case 1: Laboratory testing revealed a leukocyte level of $9.3 \times 10^{12}/L$, hemoglobin level of 19.8 g/dL, and hematocrit of 66.7%. Inflammation, coagulation, and autoimmunity markers were all negative. In addition, an ultrasound examination of her lower extremities detected left intermuscular venous thrombosis. Abdominal ultrasound revealed mild splenomegaly (spleen thickness: 43 mm). Bone marrow biopsy and positive JAK-2-V617F mutation tests provided strong evidence for PV.

Case 2: Routine blood testing highlighted that the patient possessed an erythrocyte count of $10.6 \times 10^{12}/L$, hematocrit of 71.7%, hemoglobin 22 g/dL, and platelet count of $794 \times 10^9/L$. Other blood sample tests revealed no obvious abnormalities. Abdominal ultrasound revealed splenomegaly (spleen thickness: 46 mm). A diagnosis of PV was suspected and a subsequent bone marrow biopsy and a positive JAK-2-V617F mutation confirmed this diagnosis.

Imaging examinations

Case 1: Brain computed tomography (CT) showed patchy high-density changes in right parietal low-density lesions (Figure 1A). Magnetic resonance imaging confirmed an acute cerebral infarct in the right parietal and occipital lobes with restricted diffusion (Figure 1B and C). CT-angiography imaging revealed only mild atherosclerosis (Figure 1D). A magnetic resonance venogram (MRV) was unremarkable (Figure 1E).

Case 2: On admission, brain CT revealed infarctions in the right parietal and temporal lobes (Figure 2A). Three days later, a brain CT re-examination revealed an infarct lesion in the right cerebral hemisphere with a right parietal hematoma (Figure 2B). Brain magnetic resonance angiography, MRV, cardiac ultrasonography, and 24-h dynamic electrocardiogram revealed no obvious abnormalities.

FINAL DIAGNOSIS

Case 1: The patient was diagnosed with hemorrhagic infarction in addition to PV.

Case 2: The presence of post-ischemic stroke parenchymal hematomas was concluded to be derived from the patient's PV.

TREATMENT

Case 1: The patient received hydroxyurea and hydration treatment, as well as antiplatelet therapy (aspirin 100 mg daily). CT re-examination after 1 wk demonstrated the resolution of the hemorrhage within the infarction lesions (Figure 1F). Due to the high risk of thrombotic complications, anticoagulation treatment followed by antiplatelet therapy was initiated 1 mo after symptom onset.

Case 2: The patient was consequently given antiplatelet therapeutics, hydration, and cytoreductive therapy. However, 3 d later, the patient suffered a hemiplegia deterioration, accompanied by left-side weakness and drowsiness.

OUTCOME AND FOLLOW-UP

Case 1: At the 6-mo follow-up, the patient retained slight weakness and mild disability (modified Rankin Scale score, 1). She was stable in hematology and neurology outpatient follow-ups without any recurrence of vascular complications.

Case 2: Three months after disease onset, the patient improved to ambulatory care and was provided a brace (modified Rankin Scale score, 3). He was referred for hematology outpatient monitoring with chemotherapy with hydroxyurea follow-ups. To prevent secondary strokes, a regimen of low-dose aspirin (100 mg daily) was reinitiated 6 mo after symptom onset. Currently, he is recovering well with aspirin and hydroxyurea.

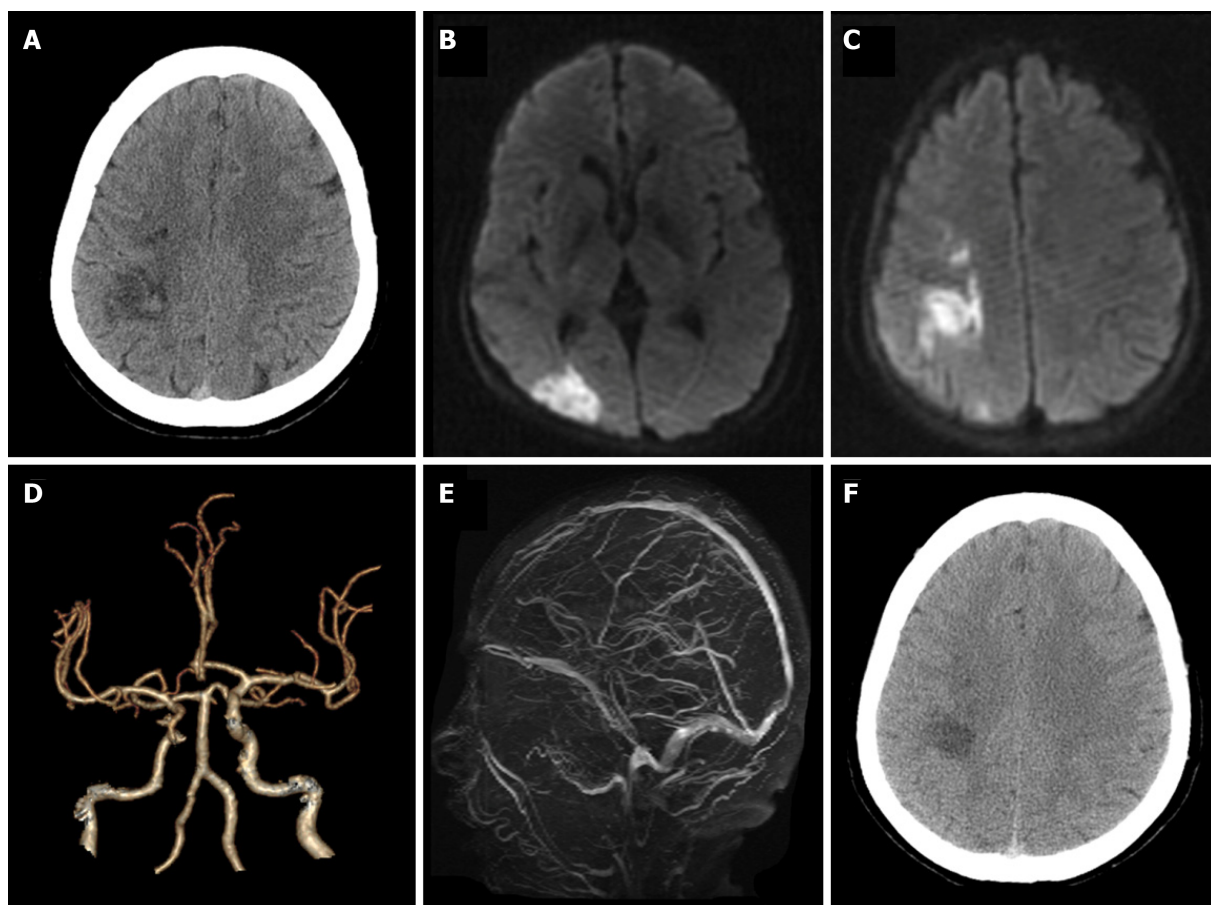


Figure 1 A 57-year-old woman with hemorrhagic infarction due to polycythemia vera. A: Computed tomography (CT) showed patchy high-density changes in right parietal low-density lesions; B and C: Diffusion-weighted imaging showed acute ischemia in the right parietal and occipital lobes; D: CT-angiography showed mild atherosclerosis; E: Magnetic resonance venogram was unremarkable; F: CT re-examination after 1 wk demonstrated the resolution of hemorrhage within the infarction lesion.

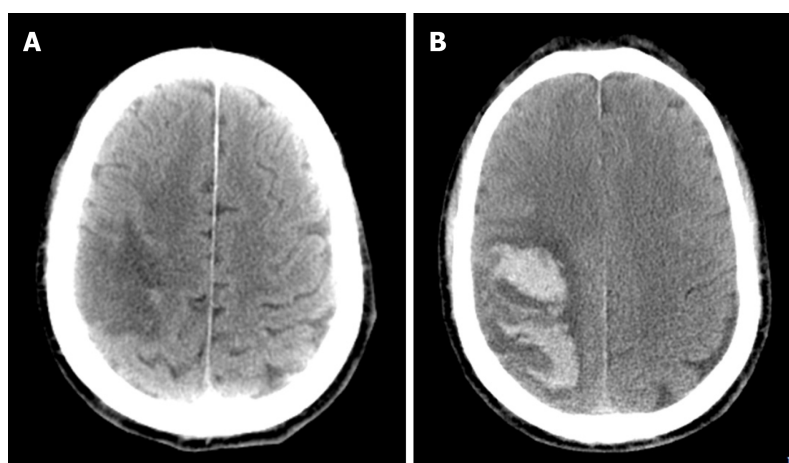


Figure 2 A 68-year-old man with parenchymal hematomas after acute ischemic stroke caused by polycythemia vera. A: Computed tomography (CT) revealed right parietal and temporal lobe infarction; B: CT re-examination after 3 d revealed a hematoma within the infarct lesion of the right cerebral hemisphere.

DISCUSSION

Stroke is a prevalent disorder in neurology clinics. Its common causes include atherosclerosis, cardiogenic embolism, and small vessel disease among others. By contrast, hematological diseases rarely underly a stroke, accounting for less than 1% of cases[4, 5]. PV, as a chronic hematological disorder, is typically associated with an increased

incidence of stroke[1,6]. Our cases further suggest that in PV patients, hemorrhagic transformation can occur after an acute ischemic stroke, a clinical manifestation that has yet to be reported.

Ischemic stroke is considered to be the first presenting symptom in more than 15% of PV patients[4]. The peak incidence of PV occurs between 50–70 years of age, and these ages coincide with a high incidence of stroke[7]. However, the etiology behind increased thrombotic events in PV patients is not fully understood. The mechanisms are likely multifactorial. First, increased hematocrit and blood viscosity may decrease cerebral blood flow and form a prothrombotic state for patients with PV[1]. Second, JAK2 V617F mutations, which occur in 95% of PV cases[8], cause endothelial damage to systemic vessels, and confer a differentiation advantage towards megakaryocytes, thereby increasing intrinsic platelet reactivity[9,10]. Activated platelets will adhere and aggregate on ruptured plaques, resulting in thrombosis formation. Coincidentally, endothelial dysfunction in vessels facilitates leukocyte migration, which in turn triggers an inflammatory cascade in a similar way to atherosclerotic lesions[11]. Moreover, malignant cells can release cytokines and other mediators and provoke an inflammatory response in the vascular endothelial cells. Third, an increase in erythrocytes could obstruct small vessels and form an embolic infarct in the brain[12]. Consistent with this mechanism, microembolic signals on transcranial doppler sonography have been detected in patients with PV, indicative of cardiac embolism [2]. Finally, the hemodynamic infarct is common in PV. Previous work has shown that erythrocytosis decreases plasma volume and leads to a relative thrombocytosis, consequently accelerating thrombogenesis to form a hemodynamic infarct[13].

Hemorrhagic transformation is a frequent complication of acute ischemic stroke, especially after tissue-plasminogen activator intravenous thrombolysis or mechanical thrombectomy[14]. Moreover, massive cerebral infarction and cardioembolic stroke are associated with an increased risk of hemorrhagic transformation[15,16]. The mechanism behind hemorrhage in PV patients, an unusual presentation, has rarely been explored.

Consistent across all causes of ischemic stroke, and present in our first case, infarction is always accompanied by brain edema, which leads to compression of the peripheral vasculature. Increased permeability of the vascular wall caused by vascular compression enhances the risk of hemorrhagic transformation[17]. Furthermore, PV increases blood volume, and this, in turn, brings high pressure to the vessel wall, resulting in vessel overfilling and microaneurysm formation[18]. Once vessel rupture and microaneurysms occur, hemorrhage may follow. Moreover, spontaneous hemorrhages in PV patients may be also associated with platelet dysfunction caused by abnormal proliferation of bone marrow cells[19]. In our second case, we further speculate a role for antiplatelet therapy in causing hemorrhage. However, although neither of our cases developed cerebral venous thrombosis, we cannot exclude that impaired venous drainage, caused by PV, may have also contributed to hemorrhagic infarction[20].

There is a high risk of thrombotic events in PV patients[21]. Antiplatelet therapy can be useful for decreasing the risk of thrombosis and related morbidities. The European Collaboration on Low-Dose Aspirin in PV study confirmed that low-dose aspirin can safely prevent thrombotic complications in PV patients without contraindications[22]. A meta-analysis also suggested that the use of low-dose aspirin in patients with PV is associated with a reduced risk of all-cause mortality, and does not increase the risk of bleeding[23]. For both of our cases, aspirin was also the main preventive treatment for long-term adverse vascular events. For our patients, hemorrhagic transformation as a contraindication existed in the acute phase of stroke. After the resolution of the hemorrhage, reinitiating antiplatelet drug did not overtly cause long-term negative outcomes. Future research should focus on the treatment of this condition.

CONCLUSION

Our case report suggests that hemorrhagic transformation can occur following acute ischemic stroke in PV patients. Antiplatelet drugs do not lead to poor long-term outcomes in such patients.

ACKNOWLEDGEMENTS

We are grateful to the patients for their contributions to the study.

REFERENCES

- 1 Spivak JL. Polycythemia vera: myths, mechanisms, and management. *Blood* 2002; **100**: 4272-4290 [PMID: 12393615 DOI: 10.1182/blood-2001-12-0349]
- 2 Marchioli R, Finazzi G, Landolfi R, Kutti J, Gisslinger H, Patrono C, Marilus R, Villegas A, Tognoni G, Barbui T. Vascular and neoplastic risk in a large cohort of patients with polycythemia vera. *J Clin Oncol* 2005; **23**: 2224-2232 [PMID: 15710945 DOI: 10.1200/JCO.2005.07.062]
- 3 Chen L, Xiao H, Hu Z. Cerebral Hemorrhage of a 50-Year-Old Female Patient with Polycythemia Vera. *J Stroke Cerebrovasc Dis* 2019; **28**: e110-e112 [PMID: 31126786 DOI: 10.1016/j.jstrokecerebrovasdis.2019.04.037]
- 4 Hart RG, Kanter MC. Hematologic disorders and ischemic stroke. A selective review. *Stroke* 1990; **21**: 1111-1121 [PMID: 2202092 DOI: 10.1161/01.str.21.8.1111]
- 5 Ferro JM, Infante J. Cerebrovascular manifestations in hematological diseases: an update. *J Neurol* 2021; **268**: 3480-3492 [PMID: 33586004 DOI: 10.1007/s00415-021-10441-9]
- 6 Frederiksen H, Szépligeti S, Bak M, Ghanima W, Hasselbalch HC, Christiansen CF. Vascular Diseases In Patients With Chronic Myeloproliferative Neoplasms - Impact Of Comorbidity. *Clin Epidemiol* 2019; **11**: 955-967 [PMID: 31807079 DOI: 10.2147/CLEP.S216787]
- 7 Zoraster RM, Rison RA. Acute embolic cerebral ischemia as an initial presentation of polycythemia vera: a case report. *J Med Case Rep* 2013; **7**: 131 [PMID: 23683307 DOI: 10.1186/1752-1947-7-131]
- 8 Kilpivaara O, Levine RL. JAK2 and MPL mutations in myeloproliferative neoplasms: discovery and science. *Leukemia* 2008; **22**: 1813-1817 [PMID: 18754026 DOI: 10.1038/leu.2008.229]
- 9 Falanga A, Marchetti M, Evangelista V, Vignoli A, Licini M, Balicco M, Manarini S, Finazzi G, Cerletti C, Barbui T. Polymorphonuclear leukocyte activation and hemostasis in patients with essential thrombocythemia and polycythemia vera. *Blood* 2000; **96**: 4261-4266 [PMID: 11110700]
- 10 Fleischman AG, Tyner JW. Causal role for JAK2 V617F in thrombosis. *Blood* 2013; **122**: 3705-3706 [PMID: 24288407 DOI: 10.1182/blood-2013-10-531665]
- 11 Hobbs CM, Manning H, Bennett C, Vasquez L, Severin S, Brain L, Mazharian A, Guerrero JA, Li J, Soranzo N, Green AR, Watson SP, Ghevaert C. JAK2V617F leads to intrinsic changes in platelet formation and reactivity in a knock-in mouse model of essential thrombocythemia. *Blood* 2013; **122**: 3787-3797 [PMID: 24085768 DOI: 10.1182/blood-2013-06-501452]
- 12 Fiermonte G, Aloe Spiriti MA, Latagliata R, Petti MC, Giacomini P. Polycythemia vera and cerebral blood flow: a preliminary study with transcranial Doppler. *J Intern Med* 1993; **234**: 599-602 [PMID: 7903108 DOI: 10.1111/j.1365-2796.1993.tb01019.x]
- 13 Harrison MJ. Influence of haematocrit in the cerebral circulation. *Cerebrovasc Brain Metab Rev* 1989; **1**: 55-67 [PMID: 2701370]
- 14 Wang W, Li M, Chen Q, Wang J. Hemorrhagic Transformation after Tissue Plasminogen Activator Reperfusion Therapy for Ischemic Stroke: Mechanisms, Models, and Biomarkers. *Mol Neurobiol* 2015; **52**: 1572-1579 [PMID: 25367883 DOI: 10.1007/s12035-014-8952-x]
- 15 Hornig CR, Bauer T, Simon C, Trittmacher S, Dorndorf W. Hemorrhagic transformation in cardioembolic cerebral infarction. *Stroke* 1993; **24**: 465-468 [PMID: 8446984 DOI: 10.1161/01.str.24.3.465]
- 16 Molina CA, Montaner J, Abilleira S, Ibarra B, Romero F, Arenillas JF, Alvarez-Sabín J. Timing of spontaneous recanalization and risk of hemorrhagic transformation in acute cardioembolic stroke. *Stroke* 2001; **32**: 1079-1084 [PMID: 11340213 DOI: 10.1161/01.str.32.5.1079]
- 17 Michiels JJ, Berneman Z, Schroyens W, Koudstaal PJ, Lindemans J, Neumann HA, van Vliet HH. Platelet-mediated erythromelalgic, cerebral, ocular and coronary microvascular ischemic and thrombotic manifestations in patients with essential thrombocythemia and polycythemia vera: a distinct aspirin-responsive and coumadin-resistant arterial thrombophilia. *Platelets* 2006; **17**: 528-544 [PMID: 17127481 DOI: 10.1080/09537100600758677]
- 18 McMahon B, Stein BL. Thrombotic and bleeding complications in classical myeloproliferative neoplasms. *Semin Thromb Hemost* 2013; **39**: 101-111 [PMID: 23264112 DOI: 10.1055/s-0032-1331153]
- 19 Garaci FG, Gandini R, Romagnoli A, Fasoli F, Varrucchi V, Simonetti G. Hepatic artery pseudoaneurysm in von Willebrand's disease. *Eur Radiol* 2003; **13**: 1913-1915 [PMID: 12942294 DOI: 10.1007/s00330-002-1621-x]
- 20 Martin K. Risk Factors for and Management of MPN-Associated Bleeding and Thrombosis. *Curr Hematol Malig Rep* 2017; **12**: 389-396 [PMID: 28948496 DOI: 10.1007/s11899-017-0400-3]
- 21 Marchioli R, Finazzi G, Specchia G, Cacciola R, Cavazzina R, Cilloni D, De Stefano V, Elli E, Iurlo A, Latagliata R, Lunghi F, Lunghi M, Marfisi RM, Musto P, Masciulli A, Musolino C, Cascavilla N, Quarta G, Randi ML, Rapezzi D, Ruggeri M, Rumi E, Scortechini AR, Santini S, Scarano M, Siragusa S, Spadea A, Tieghi A, Angelucci E, Visani G, Vannucchi AM, Barbui T; CYTO-PV Collaborative Group. Cardiovascular events and intensity of treatment in polycythemia vera. *N Engl J Med* 2013; **368**: 22-33 [PMID: 23216616 DOI: 10.1056/NEJMoa1208500]

- 22 **Landolfi R**, Marchioli R, Kutti J, Gisslinger H, Tognoni G, Patrono C, Barbui T; European Collaboration on Low-Dose Aspirin in Polycythemia Vera Investigators. Efficacy and safety of low-dose aspirin in polycythemia vera. *N Engl J Med* 2004; **350**: 114-124 [PMID: [14711910](#) DOI: [10.1056/NEJMoa035572](#)]
- 23 **Squizzato A**, Romualdi E, Passamonti F, Middeldorp S. Antiplatelet drugs for polycythaemia vera and essential thrombocythaemia. *Cochrane Database Syst Rev* 2013; CD006503 [PMID: [23633335](#) DOI: [10.1002/14651858.CD006503.pub3](#)]



Published by **Baishideng Publishing Group Inc**
7041 Koll Center Parkway, Suite 160, Pleasanton, CA 94566, USA

Telephone: +1-925-3991568

E-mail: bpgoffice@wjgnet.com

Help Desk: <https://www.f6publishing.com/helpdesk>

<https://www.wjgnet.com>

