

## Solid pseudopapillary neoplasm of pancreas

(Definition/Background Information) Solid-Pseudopapillary Neoplasm (SPN) of Pancreas is a type of **exocrine tumor** of the pancreas, with a low potential for malignancy. These pancreatic tumors constitute about 1-2% of all exocrine tumors, and is almost exclusively observed in adolescent girls and women.

### Solid-Pseudopapillary Neoplasm of Pancreas

[www.dovemed.com/diseases-conditions/solid-pseudopapillary-neoplasm-pancr...](http://www.dovemed.com/diseases-conditions/solid-pseudopapillary-neoplasm-pancr...)

Was this helpful?

#### PEOPLE ALSO ASK

What is a "solid pseudopapillary" neoplasm? ▾

What is pancreatic pseudopapillary tumor? ▾

What are the different names for pancreas neoplasms? ▾

What is the prognosis of pseudopapillary neoplasm of pancreas? ▾

Feedback

### Solid pseudopapillary neoplasm of the pancreas: ...

<https://pubmed.ncbi.nlm.nih.gov/28238521>

Background: Solid pseudopapillary neoplasm (SPN) of pancreas is a rare pancreatic neoplasm with a low metastatic potential. Our aim was to study the clinical-pathological characteristics, and long-term outcome of this tumor. Materials: Retrospective single center study of patients operated for SPN of pancreas. Clinical and pathological data were collected.

Cited by: 53

Author: N. Lubezky, M. Papoulas, Y. Lessing, G. ...

Publish Year: 2017

### The solid-pseudopapillary tumor of pancreas: the clinical ...

Microsoft Bing

国内版 国际版

Chat with Bing

Sign in

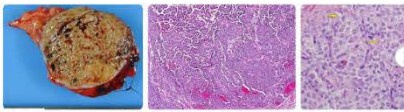
Solid pseudopapillary neoplasm of the pancreas

ALL IMAGES VIDEOS

Add the Bing with Bing extension

Solid pseudopapillary tumour

Symptoms Diagnosis Causes Treatments Risk factors Clinical trials Prevalence Complications



### Solid pseudopapillary neoplasm of pancreas

(Definition/Background Information) Solid-Pseudopapillary Neoplasm (SPN) of Pancreas is a type of **exocrine tumor** of the pancreas, with a low potential for malignancy. These pancreatic tumors constitute about 1-2% of all exocrine tumors, and is almost exclusively observed in adolescent girls and women.

**Solid-Pseudopapillary Neoplasm of Pancreas**  
www.dovemed.com/diseases-conditions/solid-pseudopapillary-neoplasm-pancr...

Was this helpful?

PEOPLE ALSO ASK

What does pancreatic neoplasms mean?

What are neoplasia, tumors and cancer?

What is neoplasia cancer?

Feedback

### Solid pseudopapillary neoplasm of the pancreas: Management ...

https://pubmed.ncbi.nlm.nih.gov/28238521

Background: Solid pseudopapillary neoplasm (SPN) of pancreas is a rare pancreatic neoplasm with a low metastatic potential. Our aim was to study the clinical-pathological characteristics, and long-term outcome of this tumor. Materials: Retrospective single center study of patients operated for SPN of pancreas. Clinical and pathological data were collected.

Cited by: 59 Author: N. Lubezky, M. Papoulas, Y. Lessing, G. Gits...  
Publish Year: 2017

EXPLORE FURTHER

Diagnosis and treatment of solid pseudopapillary tumor of ...

wjso.biomedcentral.com

Solid pseudopapillary tumor of the pancreas | Radiology ...

radiopaedia.org

Pathology Outlines - Solid pseudopapillary neoplasm

www.pathologyoutlines.com

Recommended to you based on what's popular • Feedback

### Pathology Outlines - Solid pseudopapillary neoplasm

https://www.pathologyoutlines.com/topic/pancreassolidpseud.html

Jul 12, 2021 - Solid nests of poorly cohesive cells forming a cuff surrounding blood vessels, resulting in a pseudopapillary architecture. Stroma usually shows various degrees of hyalinization or evidence of degeneration such as hemorrhage, foamy macrophages, calcification and cholesterol debris. Tumor cells usually have a moderate amount of eosinophilic cytoplasm with large intracytoplasmic hyaline ...

Pathology Outlines - WHO classification

Dec 10, 2020

Pathology Outlines - Staging-exocrine

Dec 10, 2020

Pathology Outlines - Solid papillary carcinoma

Nov 25, 2020

See more results

### Solid-pseudopapillary neoplasm of the pancreas ...

https://www.ncbi.nlm.nih.gov/pubmed/26275248

BACKGROUND: Solid pseudopapillary neoplasm (SPFN) of the pancreas is a distinctive tumor of low malignant potential with a predilection for female patients in the second and third decades of life. We studied nine cases of SPFN of the pancreas and reviewed the literature concerning these uncommon tumors.

Cited by: 2 Author: Banu Yilmaz Ozyuven, Deniz Tuncel, Nedim...  
Publish Year: 2015

### The solid-pseudopapillary tumor of pancreas: the clinical ...

https://pubmed.ncbi.nlm.nih.gov/16457845

Background and objective: Since being named and reclassified by WHO in 1996, solid-pseudopapillary tumor (SPT) of pancreas has been recognized as a special entitative disease that is different from pancreatic cancer and should be recognized and treated more accurately in the surgical process. The clinic characteristics and surgical strategy on 25 cases of SPT of pancreas from the authors' center ...

Cited by: 58 Author: Cheng-hong Peng, Dong-jeng Chen, Guang...  
Publish Year: 2006

### Solid-pseudopapillary tumor of the pancreas: a typically ...

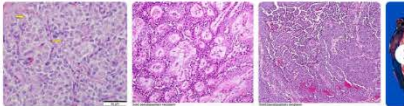
https://www.ncbi.nlm.nih.gov/pubmed/10721808

Solid-pseudopapillary tumor of the pancreas: a typically cystic carcinoma of low malignant potential. Klimstra DS (1), Wenig BM, Hefless CS. Solid-pseudopapillary tumors are uncommon neoplasms of low malignant potential generally occurring in young women.

Cited by: 520 Author: D S Klimstra, B M Wenig, C S Hefless  
Publish Year: 2000

### Images of Solid pseudopapillary neoplasm of the Pancreas

bing.com/images



See all images

### Diagnosis and treatment of solid pseudopapillary tumor of ...

https://wjso.biomedcentral.com/articles/10.1186/1477-7819-11-308

Dec 01, 2013 - Solid pseudopapillary neoplasia (SPN) of the pancreas is an extremely rare epithelial tumor of low malignant potential. SPN accounts for less than 1% to 2% of exocrine pancreatic tumors. The aim of this study is to report our experience with SPN of the pancreas.

Estimated Reading Time: 9 mins

Related searches for Solid pseudopapillary neoplasm of the pancr...

solid pseudopapillary neoplasm pathology

spen pancreas

pancreatic neck lesion

pseudopapillary tumor of the pancreas

pseudopapillary neoplasm pancreas led 10

solid pseudopapillary neoplasm

solid pseudopapillary tumor pancreas pathology

24-Jul-2021 09:13AM
2184 words • 70 matches • 31 sources
FAO

iThenticate®
65262\_Auto\_EditedC.docx
Quotes Included: 28%  
Bibliography Included: 0%

**Name of Journal:** World Journal of Hepatology

**Manuscript NO:** 65262

**Manuscript Type:** MINIREVIEWS

**2** Solid pseudopapillary neoplasm of the pancreas

Omiyale AO **2** *et al.* Solid pseudopapillary neoplasm of the pancreas

Ayo O Omiyale

**Abstract**

Solid pseudopapillary neoplasms are rare. This article reviews the clinical and pathologic features of solid pseudopapillary neoplasm of the pancreas, including the epidemiology, cytology, molecular pathology, differential diagnosis, treatment, and prognosis. Solid pseudopapillary neoplasms are low-grade malignant tumours of the pancreas characterized by poorly cohesive epithelial cells with solid and pseudopapillary patterns. Solid pseudopapillary neoplasms occur predominantly in

**Match Overview**

1	Crossref 62 words Essentials of Anatomic Pathology, 2016.	3%
2	Internet 55 words servat.unl.ch	2%
3	Crossref 39 words Minhee Park, Jong-Sun Lim, Hydaung-Joo Lee, Keun Na, Min Jung Lee, Chang Moo Kang, Young-Ki Park, Hogueun	2%
4	Crossref 37 words Cystic Tumors of the Pancreas, 2016.	2%
5	Crossref 30 words Ivo Junić, Zenon Pogorelec, Jasminka Giljević, Stepan, Iva na Prusac Kuzmić, "Extremely rare presentation of Piar...	1%
6	Crossref 29 words "Adrenocortical Carcinoma", Springer Science and Business Media LLC, 2011	1%
7	Crossref 28 words Michelle D. Reid, Pein Bagci, N. Volkan Adiguzel, "Histopathologic assessment of pancreatic cancer: Does one size fit	1%
8	Crossref 27 words Arbaz Samad, Akshisha A. Shah, Edward B. Steiner, Manam Altharfi, Stuart E. H. Cameron, Stefan E. Pambuccia	1%

PAGE: 1 OF 10
Text-Only Report

国内版

国际版

Solid pseudopapillary neoplasm of the pancreas



ALL

IMAGES

VIDEOS

Solid pseudopapillary  
tumour

Symptoms

Diagnosis

Causes

Treatments

Risk factors

## Solid pseudopapillary neoplasm of pancreas

(Definition/Background Information) Solid-Pseudopapillary Neoplasm (SPN) of Pancreas is a type of **exocrine tumor** of the pancreas, with a low potential for malignancy. These pancreatic tumors constitute about 1-2% of all exocrine tumors, and is almost exclusively observed in adolescent girls and women.

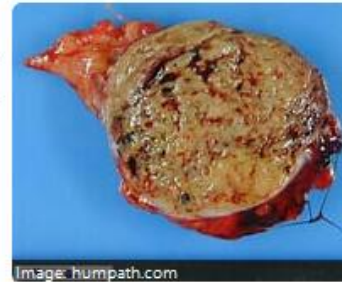

Image: humpath.com

### Solid-Pseudopapillary Neoplasm of Pancreas

[www.dovemed.com/diseases-conditions/solid-pseudopapillary-neoplasm-pancr...](http://www.dovemed.com/diseases-conditions/solid-pseudopapillary-neoplasm-pancr...)

Was this helpful?

#### PEOPLE ALSO ASK

What does pancreatic neoplasms mean?



What are neoplasia, tumors and cancer?



What is neoplasia cancer?



Feedback

### Pancreatic Solid Pseudopapillary Neoplasm: Key Pathologic ...

<https://pubmed.ncbi.nlm.nih.gov/31958381>

Solid pseudopapillary neoplasm of the pancreas is a low-grade malignant tumor generally associated with a good prognosis. Solid pseudopapillary neoplasms show peculiar morphologic features, but sometimes the differential diagnosis with other pancreatic neoplasms (ie, pancreatic neuroendocrine tumors) can be a challenging task, especially in cytologic or biopsy specimens.

Cited by: 8

Author: Stefano La Rosa, Massimo Bongiovanni

Publish Year: 2020