

World Journal of *Clinical Cases*

World J Clin Cases 2021 July 26; 9(21): 5754-6177



Contents

Thrice Monthly Volume 9 Number 21 July 26, 2021

REVIEW

- 5754 Treatment strategies for hepatocellular carcinoma with extrahepatic metastasis
Long HY, Huang TY, Xie XY, Long JT, Liu BX

MINIREVIEWS

- 5769 Prevention of hepatitis B reactivation in patients requiring chemotherapy and immunosuppressive therapy
Shih CA, Chen WC
- 5782 Research status on immunotherapy trials of gastric cancer
Liang C, Wu HM, Yu WM, Chen W
- 5794 Therapeutic plasma exchange for hyperlipidemic pancreatitis: Current evidence and unmet needs
Zheng CB, Zheng ZH, Zheng YP
- 5804 Essentials of thoracic outlet syndrome: A narrative review
Chang MC, Kim DH

ORIGINAL ARTICLE

Case Control Study

- 5812 Soluble programmed death-1 is predictive of hepatitis B surface antigen loss in chronic hepatitis B patients after antiviral treatment
Tan N, Luo H, Kang Q, Pan JL, Cheng R, Xi HL, Chen HY, Han YF, Yang YP, Xu XY

Retrospective Cohort Study

- 5822 Tunneled biopsy is an underutilised, simple, safe and efficient method for tissue acquisition from subepithelial tumours
Koutsoumpas A, Perera R, Melton A, Kuker J, Ghosh T, Braden B

Retrospective Study

- 5830 Macular ganglion cell complex injury in different stages of anterior ischemic optic neuropathy
Zhang W, Sun XQ, Peng XY
- 5840 Value of refined care in patients with acute exacerbation of chronic obstructive pulmonary disease
Na N, Guo SL, Zhang YY, Ye M, Zhang N, Wu GX, Ma LW
- 5850 Facilitators and barriers to colorectal cancer screening in an outpatient setting
Samuel G, Kratzer M, Asagbra O, Kinderwater J, Poola S, Udom J, Lambert K, Mian M, Ali E
- 5860 Development and validation of a prognostic nomogram for colorectal cancer after surgery
Li BW, Ma XY, Lai S, Sun X, Sun MJ, Chang B

Observational Study

- 5873** Potential protein-phenotype correlation in three lipopolysaccharide-responsive beige-like anchor protein-deficient patients

Tang WJ, Hu WH, Huang Y, Wu BB, Peng XM, Zhai XW, Qian XW, Ye ZQ, Xia HJ, Wu J, Shi JR

- 5889** Quantification analysis of pleural line movement for the diagnosis of pneumothorax

Xiao R, Shao Q, Zhao N, Liu F, Qian KJ

Prospective Study

- 5900** Preprocedure ultrasound imaging combined with palpation technique in epidural labor analgesia

Wu JP, Tang YZ, He LL, Zhao WX, An JX, Ni JX

Randomized Controlled Trial

- 5909** Effects of perioperative rosuvastatin on postoperative delirium in elderly patients: A randomized, double-blind, and placebo-controlled trial

Xu XQ, Luo JZ, Li XY, Tang HQ, Lu WH

SYSTEMATIC REVIEWS

- 5921** Pain assessment and management in the newborn: A systematized review

Garcia-Rodriguez MT, Bujan-Bravo S, Seijo-Bestilleiro R, Gonzalez-Martin C

META-ANALYSIS

- 5932** Fatigue prevalence in men treated for prostate cancer: A systematic review and meta-analysis

Luo YH, Yang YW, Wu CF, Wang C, Li WJ, Zhang HC

CASE REPORT

- 5943** Diagnostic discrepancy between colposcopy and vaginoscopy: A case report

Li Q, Zhang HW, Sui L, Hua KQ

- 5948** Contrast enhanced ultrasound in diagnosing liver lesion that spontaneously disappeared: A case report

Wang ZD, Haitham S, Gong JP, Pen ZL

- 5955** COVID-19 patient with an incubation period of 27 d: A case report

Du X, Gao Y, Kang K, Chong Y, Zhang ML, Yang W, Wang CS, Meng XL, Fei DS, Dai QQ, Zhao MY

- 5963** Awake extracorporeal membrane oxygenation support for a critically ill COVID-19 patient: A case report

Zhang JC, Li T

- 5972** Meigs syndrome with pleural effusion as initial manifestation: A case report

Hou YY, Peng L, Zhou M

- 5980** Giant hemangioma of the caudate lobe of the liver with surgical treatment: A case report

Wang XX, Dong BL, Wu B, Chen SY, He Y, Yang XJ

- 5988** Anti-programmed cell death ligand 1-based immunotherapy in recurrent hepatocellular carcinoma with inferior vena cava tumor thrombus and metastasis: Three case reports
Liu SR, Yan Q, Lin HM, Shi GZ, Cao Y, Zeng H, Liu C, Zhang R
- 5999** Minimal deviation adenocarcinoma with elevated CA19-9: A case report
Dong Y, Lv Y, Guo J, Sun L
- 6005** Isolated fungus ball in a single cell of the left ethmoid roof: A case report
Zhou LQ, Li M, Li YQ, Wang YJ
- 6009** Rare case of brucellosis misdiagnosed as prostate carcinoma with lumbar vertebra metastasis: A case report
Yan JF, Zhou HY, Luo SF, Wang X, Yu JD
- 6017** Myeloid sarcoma of the colon as initial presentation in acute promyelocytic leukemia: A case report and review of the literature
Wang L, Cai DL, Lin N
- 6026** Primary follicular lymphoma in the renal pelvis: A rare case report
Shen XZ, Lin C, Liu F
- 6032** Rosai-Dorfman disease in the spleen of a pediatric patient: A case report
Ryu H, Hwang JY, Kim YW, Kim TU, Jang JY, Park SE, Yang EJ, Shin DH
- 6041** Relapsed/refractory classical Hodgkin lymphoma effectively treated with low-dose decitabine plus tislelizumab: A case report
Ding XS, Mi L, Song YQ, Liu WP, Yu H, Lin NJ, Zhu J
- 6049** Disseminated *Fusarium* bloodstream infection in a child with acute myeloid leukemia: A case report
Ning JJ, Li XM, Li SQ
- 6056** Familial hemophagocytic lymphohistiocytosis type 2 in a female Chinese neonate: A case report and review of the literature
Bi SH, Jiang LL, Dai LY, Wang LL, Liu GH, Teng RJ
- 6067** Usefulness of metagenomic next-generation sequencing in adenovirus 7-induced acute respiratory distress syndrome: A case report
Zhang XJ, Zheng JY, Li X, Liang YJ, Zhang ZD
- 6073** Neurogenic orthostatic hypotension with Parkinson's disease as a cause of syncope: A case report
Li Y, Wang M, Liu XL, Ren YF, Zhang WB
- 6081** SATB2-associated syndrome caused by a novel SATB2 mutation in a Chinese boy: A case report and literature review
Zhu YY, Sun GL, Yang ZL
- 6091** Diagnosis and treatment discussion of congenital factor VII deficiency in pregnancy: A case report
Yang Y, Zeng YC, Rumende P, Wang CG, Chen Y

- 6102** Unusual immunohistochemical “null” pattern of four mismatch repair proteins in gastric cancer: A case report
Yue M, Liu JY, Liu YP
- 6110** Generalized periodontitis treated with periodontal, orthodontic, and prosthodontic therapy: A case report
Kaku M, Matsuda S, Kubo T, Shimoe S, Tsuga K, Kurihara H, Tanimoto K
- 6125** Ligamentum flavum hematoma following a traffic accident: A case report
Yu D, Lee W, Chang MC
- 6130** Oral cyclophosphamide-induced posterior reversible encephalopathy syndrome in a patient with ANCA-associated vasculitis: A case report
Kim Y, Kwak J, Jung S, Lee S, Jang HN, Cho HS, Chang SH, Kim HJ
- 6138** Encapsulating peritoneal sclerosis in an AMA-M2 positive patient: A case report
Yin MY, Qian LJ, Xi LT, Yu YX, Shi YQ, Liu L, Xu CF
- 6145** Multidisciplinary diagnostic dilemma in differentiating Madelung’s disease – the value of superb microvascular imaging technique: A case report
Seskute G, Dapkute A, Kausaite D, Strainiene S, Talijunas A, Butrimiene I
- 6155** Complicated course of biliary inflammatory myofibroblastic tumor mimicking hilar cholangiocarcinoma: A case report and literature review
Strainiene S, Sedleckaite K, Jarasunas J, Savlan I, Stanaitis J, Stundiene I, Strainys T, Liakina V, Valantinas J
- 6170** Fruquintinib beneficial in elderly patient with neoplastic pericardial effusion from rectal cancer: A case report
Zhang Y, Zou JY, Xu YY, He JN

ABOUT COVER

Editorial Board Member of *World Journal of Clinical Cases*, Jae Gil Lee, MD, PhD, Professor, Surgeon, Department of Surgery, Yonsei University College of Medicine, Seoul 03722, South Korea. jakii@yuhs.ac

AIMS AND SCOPE

The primary aim of *World Journal of Clinical Cases* (WJCC, *World J Clin Cases*) is to provide scholars and readers from various fields of clinical medicine with a platform to publish high-quality clinical research articles and communicate their research findings online.

WJCC mainly publishes articles reporting research results and findings obtained in the field of clinical medicine and covering a wide range of topics, including case control studies, retrospective cohort studies, retrospective studies, clinical trials studies, observational studies, prospective studies, randomized controlled trials, randomized clinical trials, systematic reviews, meta-analysis, and case reports.

INDEXING/ABSTRACTING

The WJCC is now indexed in Science Citation Index Expanded (also known as SciSearch®), Journal Citation Reports/Science Edition, Scopus, PubMed, and PubMed Central. The 2021 Edition of Journal Citation Reports® cites the 2020 impact factor (IF) for WJCC as 1.337; IF without journal self cites: 1.301; 5-year IF: 1.742; Journal Citation Indicator: 0.33; Ranking: 119 among 169 journals in medicine, general and internal; and Quartile category: Q3. The WJCC's CiteScore for 2020 is 0.8 and Scopus CiteScore rank 2020: General Medicine is 493/793.

RESPONSIBLE EDITORS FOR THIS ISSUE

Production Editor: Ji-Hong Lin; Production Department Director: Xiang Li; Editorial Office Director: Jin-Lai Wang.

NAME OF JOURNAL

World Journal of Clinical Cases

ISSN

ISSN 2307-8960 (online)

LAUNCH DATE

April 16, 2013

FREQUENCY

Thrice Monthly

EDITORS-IN-CHIEF

Dennis A Bloomfield, Sandro Vento, Bao-Gan Peng

EDITORIAL BOARD MEMBERS

<https://www.wjgnet.com/2307-8960/editorialboard.htm>

PUBLICATION DATE

July 26, 2021

COPYRIGHT

© 2021 Baishideng Publishing Group Inc

INSTRUCTIONS TO AUTHORS

<https://www.wjgnet.com/bpg/gerinfo/204>

GUIDELINES FOR ETHICS DOCUMENTS

<https://www.wjgnet.com/bpg/GerInfo/287>

GUIDELINES FOR NON-NATIVE SPEAKERS OF ENGLISH

<https://www.wjgnet.com/bpg/gerinfo/240>

PUBLICATION ETHICS

<https://www.wjgnet.com/bpg/GerInfo/288>

PUBLICATION MISCONDUCT

<https://www.wjgnet.com/bpg/gerinfo/208>

ARTICLE PROCESSING CHARGE

<https://www.wjgnet.com/bpg/gerinfo/242>

STEPS FOR SUBMITTING MANUSCRIPTS

<https://www.wjgnet.com/bpg/GerInfo/239>

ONLINE SUBMISSION

<https://www.f6publishing.com>



Generalized periodontitis treated with periodontal, orthodontic, and prosthodontic therapy: A case report

Masato Kaku, Shinji Matsuda, Takayasu Kubo, Saiji Shimoe, Kazuhiro Tsuga, Hidemi Kurihara, Kotaro Tanimoto

ORCID number: Masato Kaku 0000-0002-3878-749X; Shinji Matsuda 0000-0002-4281-3216; Takayasu Kubo 0000-0003-0853-2987; Saiji Shimoe 0000-0003-2274-8354; Kazuhiro Tsuga 0000-0002-3678-7015; Hidemi Kurihara 0000-0002-3446-6904; Kotaro Tanimoto 0000-0003-4439-1579.

Author contributions: Kaku M and Tanimoto K performed orthodontic treatment and drafted the manuscript; Shimoe S reviewed the literature; Matsuda S and Kurihara H performed periodontal treatment and contributed to the drafting the manuscript; Kubo T and Tsuga K performed prosthodontic treatment and reviewed the literature; all authors issued final approval for the version to be submitted.

Informed consent statement:

Informed written consent was obtained from the patient for publication of this report and any accompanying images.

Conflict-of-interest statement: The authors declare that they have no conflict of interest.

CARE Checklist (2016) statement:

The authors have read the CARE Checklist (2016), and the manuscript was prepared and revised according to the CARE

Masato Kaku, Saiji Shimoe, Department of Anatomy and Functional Restorations, Hiroshima University Graduate School of Biomedical Sciences, Hiroshima 734-8553, Japan

Shinji Matsuda, Hidemi Kurihara, Department of Periodontal Medicine, Hiroshima University Graduate School of Biomedical Sciences, Hiroshima 734-8553, Japan

Takayasu Kubo, Kazuhiro Tsuga, Department of Advanced Prosthodontics, Hiroshima University Graduate School of Biomedical Sciences, Hiroshima 734-8553, Japan

Kotaro Tanimoto, Department of Orthodontics and Craniofacial Developmental Biology, Hiroshima University Graduate School of Biomedical Sciences, Hiroshima 734-8553, Japan

Corresponding author: Masato Kaku, DDS, PhD, Professor, Department of Anatomy and Functional Restorations, Hiroshima University Graduate School of Biomedical Sciences, 1-2-3 Kasumi, Minami-ku, Hiroshima 734-8553, Japan. mkaku@hiroshima-u.ac.jp

Abstract

BACKGROUND

Generalized periodontitis is a severe periodontal disease characterized by rapid periodontal destruction in healthy persons. This case report describes the treatment of a severe crowding, large overjet, and occlusal collapse due to the loss of anterior guidance with generalized periodontitis.

CASE SUMMARY

A 35-year-old female patient with a chief complaint of crowding and maxillary protrusion was diagnosed with generalized periodontitis by clinical and radiographic examinations. To improve crowding and overjet, orthodontic treatment was performed after basic periodontal therapy. Severely damaged upper right lateral incisor and left canine were extracted, and lower right first premolar and left second premolar were also removed to treat severe crowding. After orthodontic treatment, periodontal flap surgery for upper left molars and guided tissue regeneration for the lower left second molar was performed. Then, a dental implant was inserted in the upper left canine region. The esthetics of the maxillary anterior tooth was improved by prosthetic restorations. The treatment result showed a well-improved occlusion with proper anterior guidance and healthy periodontal tissue after a retention period of 10 years.

CONCLUSION

Checklist (2016).

Open-Access: This article is an open-access article that was selected by an in-house editor and fully peer-reviewed by external reviewers. It is distributed in accordance with the Creative Commons Attribution NonCommercial (CC BY-NC 4.0) license, which permits others to distribute, remix, adapt, build upon this work non-commercially, and license their derivative works on different terms, provided the original work is properly cited and the use is non-commercial. See: <http://creativecommons.org/licenses/by-nc/4.0/>

Manuscript source: Unsolicited manuscript

Specialty type: Medicine, research and experimental

Country/Territory of origin: Japan

Peer-review report's scientific quality classification

Grade A (Excellent): 0
Grade B (Very good): B
Grade C (Good): C
Grade D (Fair): 0
Grade E (Poor): 0

Received: March 25, 2021

Peer-review started: March 25, 2021

First decision: May 11, 2021

Revised: May 20, 2021

Accepted: June 1, 2021

Article in press: June 1, 2021

Published online: July 26, 2021

P-Reviewer: Bhatsange A, Dharmarajan G

S-Editor: Gao CC

L-Editor: A

P-Editor: Zhang YL



Periodontal, orthodontic, and prosthodontic treatments are extremely useful to improve function and stable periodontal tissue for generalized periodontitis.

Key Words: Generalized periodontitis; Orthodontic treatment; Periodontal regenerative therapy; Prosthodontic treatment; Comprehensive dental treatment; Long-term case study; Case report

©The Author(s) 2021. Published by Baishideng Publishing Group Inc. All rights reserved.

Core Tip: Generalized periodontitis causes malocclusion by severe periodontal destruction. Little information is available on the long-term occlusal stability for generalized periodontitis. In this case report, we demonstrated that periodontal, orthodontic and prosthodontics are useful to improve long-term stability of occlusal function and healthy periodontal tissue for generalized periodontitis.

Citation: Kaku M, Matsuda S, Kubo T, Shimoe S, Tsuga K, Kurihara H, Tanimoto K. Generalized periodontitis treated with periodontal, orthodontic, and prosthodontic therapy: A case report. *World J Clin Cases* 2021; 9(21): 6110-6124

URL: <https://www.wjgnet.com/2307-8960/full/v9/i21/6110.htm>

DOI: <https://dx.doi.org/10.12998/wjcc.v9.i21.6110>

INTRODUCTION

Generalized periodontitis was first introduced as diffuse atrophy of the alveolar bone in 1923 by Gottlieb[1] and finally named as aggressive periodontitis in 1999 [2,3]. It is a rare and severe periodontal disease characterized by rapid periodontal destruction with loss of attachment in healthy persons[4]. Therefore, initial periodontal treatment and additional periodontal surgery should be performed if required for generalized periodontitis. Although it is considered that generalized periodontitis is a multifactorial disease including genetic and immunologic factors, pathogenic oral bacteria of *Aggregatibacter actinomycetemcomitans* and *Porphyromonas gingivalis* are strongly related to severity of this disease[5,6].

Treatment planning in patients with generalized periodontitis are almost same as those in chronic periodontitis patients. The treatment phases are divided into general examination, initial treatment, re-evaluation, surgical treatment and maintenance for both types of periodontitis. The treatment goal of generalized periodontitis is to generate a health periodontal condition that can retain many teeth as long as possible [7]. Orthodontic treatment is essential for patients with generalized periodontitis to inhibit progression of periodontitis, because generalized periodontitis causes some pathologic tooth migration such as labial inclination, severe crowding and pathologic extrusion of anterior teeth as well as posterior occlusal collapse. B. Schacher, F. Baron, M. Roßberg, M. Wohlfeil, R. Arndt, and P. Eickholz, "Aggregatibacter actinomycetemcomitans as indicator for aggressive periodontitis by two analysing strategies," *Journal of Clinical Periodontology*, vol. 34, no. 7, pp. 566-573, 2007. View at: Publisher SiteGoogle ScholarSee in References Generalized periodontitis sometimes induces posterior occlusal trauma caused by occlusal interference due to unfavorable anterior guidance. It is reported that an important factor for long-term occlusal stability is proper anterior guidance, and overjet and overbite is considered to control anterior guidance[8]. Hence, orthodontic treatment is necessary for these patients to improve overjet and overbite and restore posterior bite collapse along with esthetic problems. Although an orthodontic tooth movement for generalized periodontitis is challenging because of the possibility of deteriorating the periodontal condition, there are some case reports of this disease treated by orthodontic therapy[9,10]. However, little information is available on the long-term occlusal stability for generalized periodontitis by comprehensive dental treatment. In this case report, we demonstrated that periodontal, orthodontic, and prosthodontics treatments are useful to improve the long-term stability of occlusal function and healthy periodontal tissue for generalized periodontitis.

CASE PRESENTATION

Chief complaints

A 35-year and 6-mo-old female patient came to our hospital with a chief complaint, “My teeth are wobbly, and I have crooked and protruding teeth”.

History of present illness

The patient complained teeth mobility in the upper anterior teeth region from the past 3 years. Although she was treated at a private practice, teeth mobility was not improved. So, the patient was referred to Hiroshima University Hospital by a general dentist for a full mouth periodontal evaluation and treatment. The pre-treatment facial photographs showed an average angle type and a convex profile with a retrognathic mandible (Figure 1). The intraoral photographs revealed a 9.5 mm overjet and 6.0 mm overbite. Both the right and left molar relationships were Class II. The upper incisors displaced labially and severe crowding was observed in the lower arch.

History of past illness

She did not have any history of systemic illness. Temporary splinting was applied from the upper right canine to the left first premolar to immobilize the loose tooth (Figure 2).

Personal and family history

The patient did not have any history of smoking and her oral hygiene was poor. The patient's father wore removable partial dentures.

Physical examination

A panoramic radiograph and full-mouth set of dental radiographs showed severe alveolar bone loss; especially, the upper right lateral incisor and left canine were severely damaged without any alveolar bone support (Figure 3 and 4). Posterior occlusal interference on both sides was observed in the anterior and lateral guidance due to unfavorable anterior guidance. Redness and swelling were observed on upper gingiva. Initial periodontal examination showed dental plaque index; 50.9%, mean probing pocket depth; 4.3 mm, 4-6 mm; 40.5%, more than 7 mm; 14.3%, bleeding on probing; 61.9%, periodontal inflamed surface area[11]; 1725.7 mm², tooth mobility of Miller classification (class 0; 2 teeth, class 1; 18 teeth, class 2; 7 teeth, class 3; 1 tooth) (Table 1).

Imaging examinations

As shown in the cephalometric measurements, a skeletal Class II relationship (ANB angle, 10.0°) with a retrognathic mandible was observed. The labial inclination of the lower incisors (IMPA, 101.1°) was also evident (Table 2 and Figure 5).

FINAL DIAGNOSIS

Based on the information, the patient was diagnosed with a generalized Stage III Grade C periodontitis[12] with skeletal Class II maxillary protrusion and severe crowding. First, we recommended initial periodontal therapy to reduce periodontal inflammation before orthodontic treatment. The treatment objectives essentially consisted of inflammation management and restoration of occlusal function. The treatment plan was as follows: (1) Initial periodontal treatment (full-mouth scaling and root planing, tooth brushing instruction); (2) Reexamination of periodontal condition; (3) Orthodontic treatment: (a) Extraction of the hopeless upper right lateral incisor and left canine; (b) Extraction of the lower right first premolar and left second premolar for orthodontic reasons; (c) Insertion of miniscrews into the mid-palatal area with a transpalatal arch; and (d) Lingual movement of the upper incisors and alignment of the lower arch; (4) Periodontal surgery; (5) Insert dental implant in the upper left canine region; (6) Prosthodontic treatment; and (7) Supportive periodontal therapy.

Table 1 Pre-treatment periodontal examinations

Maxilla	17	16	15	14	13	12	11	21	22	23	24	25	26	27
Pocket depth (buccal)	323	857	754	646	654	758	322	346	576	325	653	423	458	833
Bleeding on probing	++	+++	+++	+++	+++	+++	+	+++	+++	++	++	++	++	+
Pocket depth (palatal)	834	448	324	466	664	579	433	438	586	888	663	333	368	633
Bleeding on probing	++	+++	++	+++	+++	+++	+	++	+++	+++	++		++	++
Tooth mobility	1	1	1	2	2	3	1	2	2	2	2	1	1	0
Mandible	17	16	15	14	13	12	11	21	22	23	24	25	26	27
Pocket depth (lingual)	337	838	334	534	435	533	335	622	222	223	553	355	633	733
Bleeding on probing	+++	++	+	+++	+++	++	+	+			++	+	+	+
Pocket depth (buccal)	434	934	333	556	554	423	324	463	323	323	423	323	423	834
Bleeding on probing	+	++	+	+++	+	+	+	+++	+		+		+	+++
Tooth mobility	1	1	1	1	2	1	1	1	1	0	1	1	1	1

Plaque index: 50.9%; Periodontal inflamed surface area: 1725.7 mm²; +: Bleeding on probing.

TREATMENT

Initial periodontal treatment

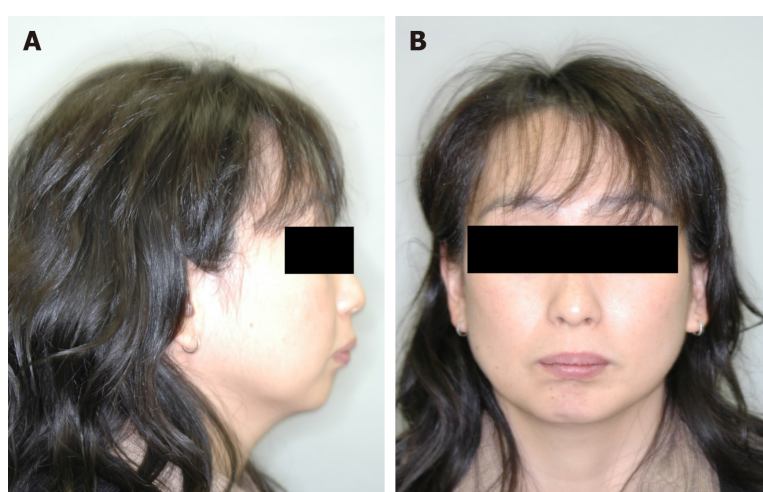Before the orthodontic treatment, an initial periodontal treatment including full-mouth scaling, root planing, and tooth brushing instruction was performed. One year after initiating the initial periodontal treatment, the patient showed significant improvement in the periodontal condition compared to that at the first examination; dental plaque index; 11.6%, mean probing pocket depth; 4.3 mm, 4-6 mm; 13.1%, more than 7 mm; 2.4%, bleeding on probing; 12.5%, periodontal inflamed surface area; 309.3 mm², tooth mobility of Miller classification (class 0; 14 teeth, class 1; 13 teeth, class 2; 1 tooth, class 3; 0) (Table 3). Based on this reexamination, we decided to start orthodontic treatment (6 mo after the end of initial periodontal treatment).

Orthodontic treatment

The patient frequently received periodontal maintenance program during orthodontic treatment. The upper right lateral incisor, left canine, lower right first premolar and left second premolar were extracted. A 0.018-inch standard edgewise bracket was bonded on the upper and lower teeth. Under local anesthesia, two self-drilling titanium alloy miniscrews (2.0 mm in diameter and 6 mm in length, Dual Top Auto

Table 2 Summary of cephalometric measurements

Measurements	Pre-treatment	Post-treatment	After 10 yr of retention
SNA (°)	81.9	81.1	81.2
SNB (°)	71.9	72.0	72.0
ANB (°)	10.0	9.1	9.2
FMA (°)	32.0	32.1	32.1
FMIA (°)	46.9	54.4	54.2
IMPA (°)	101.1	93.5	93.6
U1-FH (°)	109.9	98.6	98.8
Over jet (mm)	9.5	5.0	5.2
Over bite (mm)	6.0	4.0	4.3

**Figure 1 Pre-treatment facial photographs. A: Lateral view; B: Front view.**

Screw; Jeil Medical Corp., South Korea) were inserted into the mid-palatal area. A transpalatal arch was placed and combined with miniscrews to prevent the mesial movement of the maxillary molars. After 2 years, the overjet and overbite decreased to 3.0 mm and 3.5 mm, respectively. The teeth were well aligned and proper anterior guidance was achieved. The edgewise bracket was removed and provisional restorations were set on the upper anterior tooth. After orthodontic treatment, the patient's periodontal condition improved significantly: dental plaque index; 9.0%, mean probing pocket depth; 2.8 mm, 1-3 mm; 88.2%, 4-6 mm; 11.8%, more than 7 mm; 0%, bleeding on probing; 16.0%, periodontal inflamed surface area; 270.1 mm², tooth mobility of Miller classification (class 0; 24 teeth, class 1; 0, class 2; 0, class 3; 0) (Table 4).

Periodontal surgery

More than 5 mm of probing pocket depth area alveolar bone defect remained at both upper and lower left molars (Figure 6). Thus, periodontal flap surgery for the upper left first and second molars was performed. The surgery area was anesthetized by 2% lidocaine. The sulcular incision was made from mesial end of upper left first molar to distal end of upper left second molar. Next, a vertical incision was made and a periosteal flap was raised both on buccal and lingual part. Then, this area was completely debrided by curettes, and debris of calculus on the root surface was removed by scaling and root planning. Guided tissue regeneration for the lower left second molar was then performed. The 2% lidocaine was injected to buccal and lingual part of lower molars. The sulcular incision was performed both on the buccal and lingual sides of lower left first and second molars. Full-thickness elevations were made past the mucogingival junction both on the buccal and lingual side. The bony defect area and root surface were completely debrided. A bioresorbable poly lactic-co-

Table 3 Periodontal examinations one year after beginning of initial periodontal treatment

Maxilla	17	16	15	14	13	12	11	21	22	23	24	25	26	27
Pocket depth (buccal)	133	635	433	535	323	338	323	233	334	223	532	222	335	333
Bleeding on probing	+	++	+		+	+							+	+
Pocket depth (palatal)	333	335	333	335	533	338	333	333	335	345	332	323	233	323
Bleeding on probing		+	+		++	+					+		+	
Tooth mobility	0	0	0	1	0	0	0	0	0	2	1	0	0	0
Mandible	17	16	15	14	13	12	11	21	22	23	24	25	26	27
Pocket depth (lingual)	336	333	323	533	333	222	222	222	222	223	333	336	533	633
Bleeding on probing	+	+		+									+	+
Pocket depth (buccal)	638	336	333	335	333	322	212	212	212	222	333	322	333	733
Bleeding on probing	+													
Tooth mobility	1	1	0	1	2	1	1	1	1	0	1	1	0	1

Plaque index: 11.6%; Periodontal inflamed surface area: 309.3 mm²; +: Bleeding on probing.

glycolic acid membrane (GC MEMBRANE, GC Corp., Tokyo, Japan) was shaped appropriately and set on the bone defect area.

Prosthodontic treatment

A dental implant (3.3 mm in diameter and 13 mm in length, Brånemark System Mk III, Nobel Biocare, Sweden) was inserted in the upper left canine legion and the final prosthetic restorations were set on the maxillary anterior tooth. The tooth remained stable, and healthy periodontal tissue was observed 10 years from the beginning of the retention by supportive periodontal therapy.

OUTCOME AND FOLLOW-UP

The facial profile significantly changed and the strain of the mentalis muscle became more relaxed than before (Figure 7). The overjet and overbite improved and proper anterior guidance was achieved (Figure 8). The post-treatment panoramic radiograph showed that all the roots were almost parallel (Figure 9). The cephalometric analysis showed that IMPA changed from 101.1° to 93.5° and the ANB angle changed from 10.0° to 9.1° (Table 2 and Figure 10 and 11). The dental radiograph on the upper and

Table 4 Periodontal examinations after orthodontic treatment

Maxilla	17	16	15	14	13	12	11	21	22	23	24	25	26	27
Pocket depth (buccal)	323	434	323	323	322	-	322	323	323	-	533	323	335	533
Bleeding on probing	+										+		+	+
Pocket depth (palatal)	323	333	433	332	333	-	323	323	323	-	433	323	336	623
Bleeding on probing	+	++		+			+	+			+		+	++
Tooth mobility	0	0	0	0	0		0	0	0		0	0	0	0
Mandible	17	16	15	14	13	12	11	21	22	23	24	25	26	27
Pocket depth (lingual)	334	333	323	-	212	212	212	212	212	212	-	323	533	533
Bleeding on probing	+	+											+	+
Pocket depth (buccal)	334	434	323	-	323	412	222	323	312	212	-	323	333	623
Bleeding on probing		+				+	+	+						+
Tooth mobility	0	0	0		0	0	0	0	0	0		0	0	0

Plaque index: 9.0%; Periodontal inflamed surface area: 270.1 mm²; +: Bleeding on probing.

lower left molars showed alveolar bone regeneration by periodontal surgery (Figure 12). The patient's periodontal examination at the beginning of supportive periodontal therapy showed dental plaque index; 8.0%, mean probing pocket depth; 2.5 mm (1-3 mm; 98.6%, 4-6 mm; 1.4%, more than 7 mm; 0%), bleeding on probing; 9.7%, periodontal inflamed surface area; 107.2 mm², tooth mobility of Miller classification (class 0; 22 teeth, class 1; 2, class 2; 0, class 3; 0) (Table 5). No clinical changes were found after 10 years of retention when compared to the beginning of the retention (Table 2 and 6 and Figure 13).

DISCUSSION

In the present case, the patient was middle-aged with no systemic disorders with a familial history of periodontal issues. Moreover, because attachment loss affecting at least three permanent teeth characterizing generalized periodontitis[13] was observed, we diagnosed this patient with a generalized periodontitis. For the treatment of generalized periodontitis, which shows a wide-ranging decrease in the surrounding alveolar bone and pathologic migration of the tooth, control of the periodontal inflammation and restoration of occlusal function are important[10]. Especially, in this

Table 5 Periodontal examinations at beginning of supportive periodontal therapy

Maxilla	17	16	15	14	13	12	11	21	22	23	24	25	26	27
Pocket depth (buccal)	333	323	212	213	322	-	212	212	212	-	222	323	333	333
Bleeding on probing				+										+
Pocket depth (palatal)	333	323	323	222	313	-	323	323	312	-	323	323	323	323
Bleeding on probing		+	+						++				+	
Tooth mobility	0	0	1	1	0		0	0	0		0	0	0	0
Mandible	17	16	15	14	13	12	11	21	22	23	24	25	26	27
Pocket depth (lingual)	323	333	323	-	323	212	323	323	323	323	-	323	323	333
Bleeding on probing	+	+						++		+				+
Pocket depth (buccal)	322	333	323	-	523	323	323	323	212	212	-	323	433	323
Bleeding on probing					+									
Tooth mobility	0	0	0		0	0	0	0	0	0		0	0	0

Plaque index: 8.0%; Periodontal inflamed surface area: 107.2 mm²; +: Bleeding on probing.

patient, posterior occlusal interference was observed in the anterior and lateral guidance. Therefore, we planned occlusal reconstruction by orthodontic treatment after periodontal therapy. Usually, to reduce microorganisms, non-surgical and surgical treatment is provided[14], and this is divided into two periodontal treatment times. One is to perform the periodontal treatment before the beginning of orthodontic treatment, and the other is to provide periodontal treatment simultaneously with the orthodontic treatment. In patients with active periodontal disease, it is possible that orthodontic treatment may cause further progressive periodontal destruction[15]. On the other hand, tooth movement can improve attachment levels in reduced periodontium, suggesting that orthodontic treatment should be performed at an early stage. Zasčiurinskienė *et al*[16] compared the effect of orthodontic treatment on the periodontal status between control patients who received periodontal treatment before the beginning of orthodontic treatment and a test group that received periodontal treatment simultaneously with orthodontic treatment. Their results showed that both groups exhibited an increase in the clinical attachment level and reduction in the probing depth. No difference in gingival recession development was observed between the two groups. However, total periodontal-orthodontic treatment time was significantly longer for the control group. Accordingly, they recommended that orthodontic treatment and periodontal treatment should be performed simultaneously. Therefore, we provided orthodontic treatment immediately after the initial

Table 6 Periodontal examinations after 10 yr of retention

Maxilla	17	16	15	14	13	12	11	21	22	23	24	25	26	27
Pocket depth (buccal)	333	323	212	212	322	-	212	212	212	-	323	212	223	223
Bleeding on probing									+					
Pocket depth (palatal)	323	323	212	222	212	-	212	222	212	-	212	323	323	323
Bleeding on probing											+			
Tooth mobility	0	0	0	1	0		0	1	0		0	0	0	0
Mandible	17	16	15	14	13	12	11	21	22	23	24	25	26	27
Pocket depth (lingual)	323	323	323	-	323	322	212	212	212	212	-	212	323	323
Bleeding on probing		+												
Pocket depth (buccal)	322	323	212	-	323	212	212	212	212	212	-	212	323	323
Bleeding on probing					+									
Tooth mobility	0	0	1		0	0	0	0	0	0		0	0	0

Plaque index: 9.0%; Periodontal inflamed surface area: 26.1 mm²; +: Bleeding on probing.

periodontal treatment, and not after surgical periodontal therapy.

In this patient, 1-year of initial periodontal treatment with full-mouth scaling, root planing and tooth brushing instruction were effective for the periodontal condition. Thus, we initiated orthodontic treatment for proper anterior guidance and to improve crowding. In cases of severe periodontitis in adults, a skeletal anchorage system is useful for the retraction of incisors, because it is difficult to obtain suitable molar anchorage in patients with periodontitis without proper periodontal support. Fukunaga *et al*[17] reported that skeletal anchorage is useful for the retraction and intrusion of upper incisors in cases of maxillary protrusion with severe adult periodontitis. Miniplates[18-20] and miniscrews[21-23] are now frequently used to establish absolute anchorage for adult orthodontic patients. However, miniscrews have been frequently used because surgical invasion is minimal compared to miniplates. Thus, we chose miniscrews in this patient with loss of alveolar bone to gain proper anchorage. As a result of the orthodontic treatment, the overjet improved and proper anterior guidance was achieved. The patient's periodontal condition improved overall, except in both the upper and lower left molars. These results suggested that reconstruction of proper anterior guidance by orthodontic treatment is very important to disclude the balancing side, which resulting in the improvement of overall clinical attachment level especially in patients with generalized periodontitis. However, because the improvement in flap surgery and guided tissue regeneration was better at

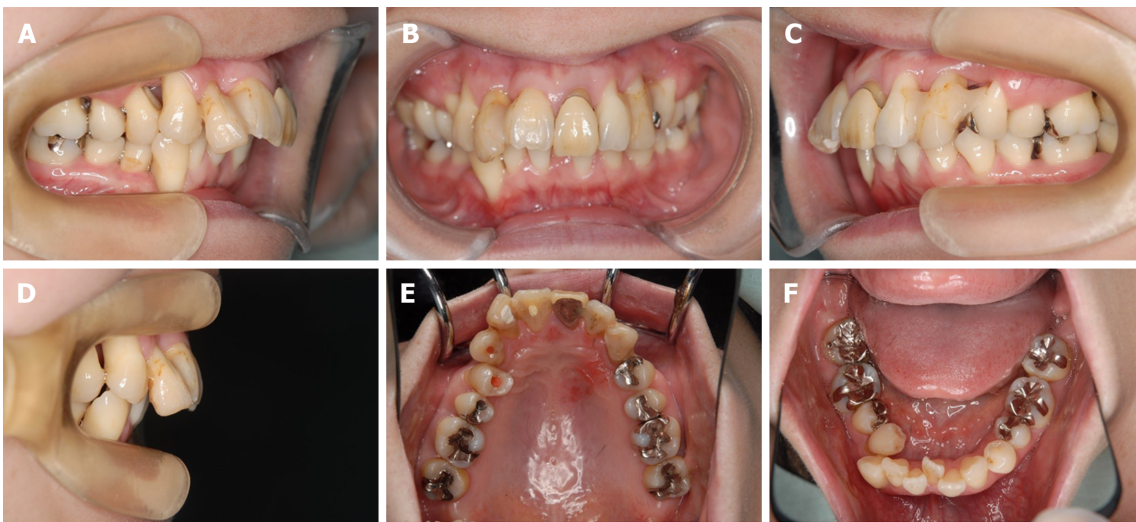


Figure 2 Pre-treatment intraoral photographs. A: Right side view; B: Front view; C: Left side view; D: Incisal view; E: Upper occlusal view; F: Lower occlusal view.

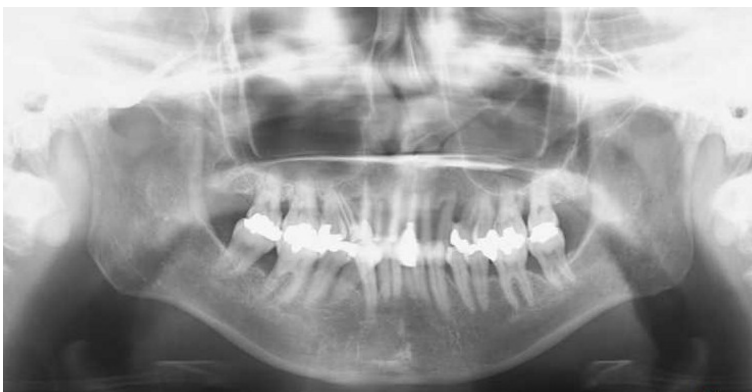

Figure 3 Pre-treatment panoramic radiograph.

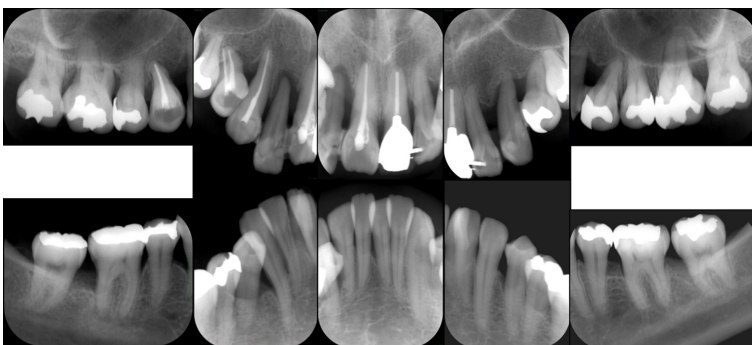


Figure 4 Pre-treatment full-mouth set of dental radiographs.

the upper and lower left molar sections of this patient, it is clear that periodontal surgery is necessary for cases of severe generalized periodontitis.

Recently, dental implants have been widely used to treat patients who lost their teeth, and long-term prognosis for implant therapy have been provided[24,25]. Although implant restoration is challenging in patients with generalized periodontitis [26], it is reported that implant loss and surrounding bone loss in patients with generalized periodontitis were not significantly larger than that in periodontally healthy patients or patients with chronic periodontitis[27]. For patients with generalized periodontitis, implant treatment should be recommended in patients who

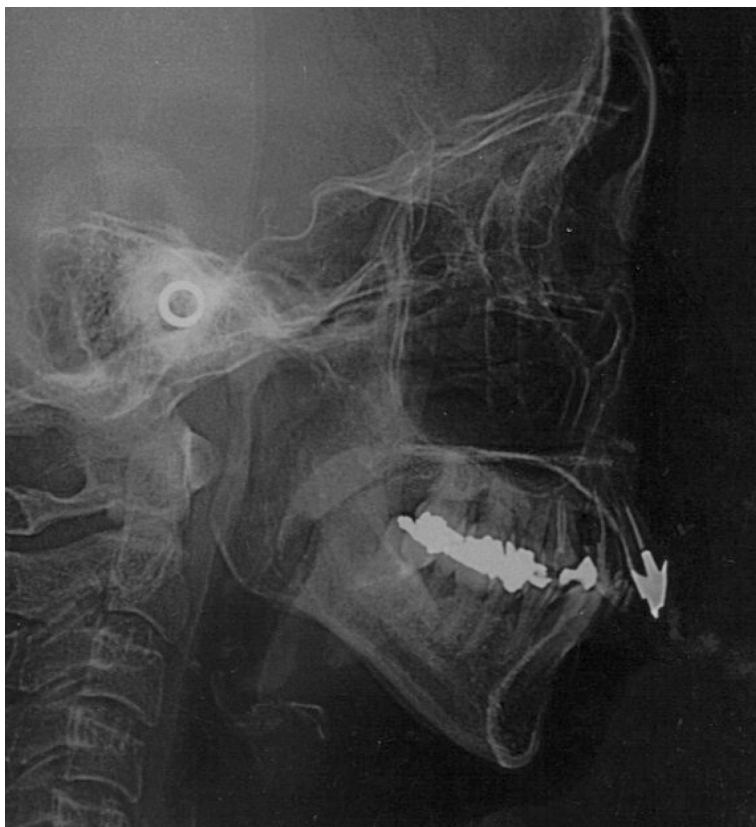

Figure 5 Pre-treatment cephalometric radiograph.

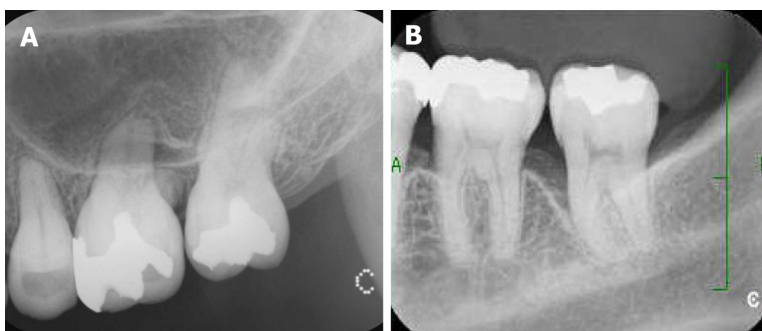


Figure 6 Dental radiographs of the upper and lower left molars after orthodontic treatment. A: Upper left molars; B: Lower left molars.

can receive continuous periodontal therapy. Additionally, in the present case, a dental implant in the upper left canine region survived without any clinical symptoms such as peri-implantitis by continuous supportive periodontal therapy. Thus, healthy periodontal tissue and occlusal reconstruction for patients with generalized periodontitis can be achieved by periodontal, orthodontic, and prosthodontic treatment.

CONCLUSION

This case report showed that a comprehensive treatment including periodontal, orthodontic, and prosthodontic treatments can be useful in improving occlusal function and achieving long-term stability in periodontal tissue for generalized periodontitis.

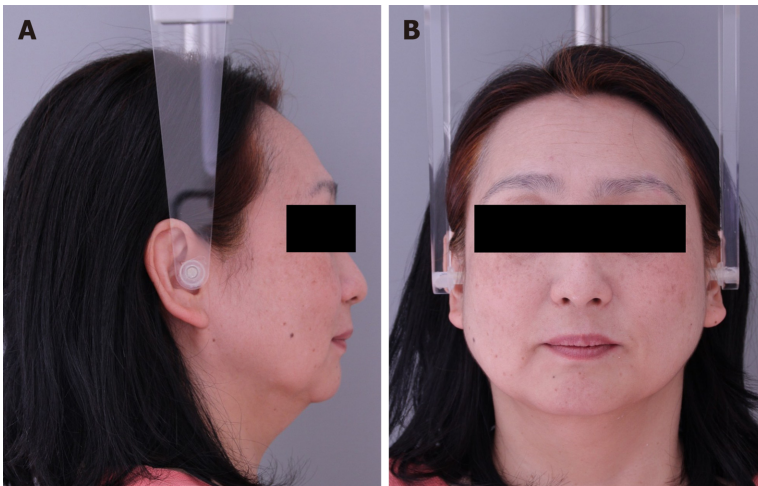

Figure 7 Post-treatment facial photographs. A: Lateral view; B: Front view.

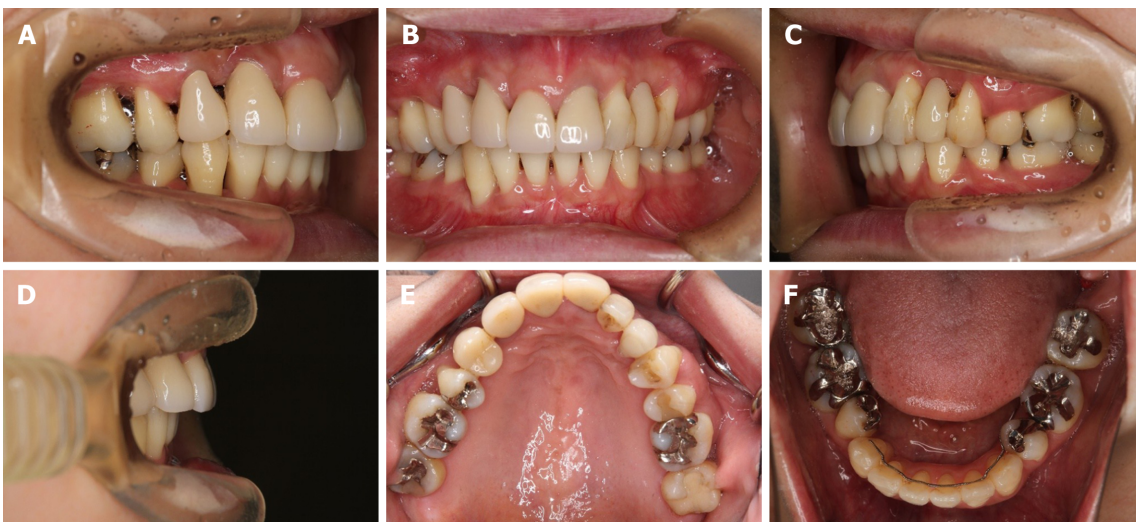


Figure 8 Post-treatment intraoral photographs. A: Right side view; B: Front view; C: Left side view; D: Incisal view; E: Upper occlusal view; F: Lower occlusal view.

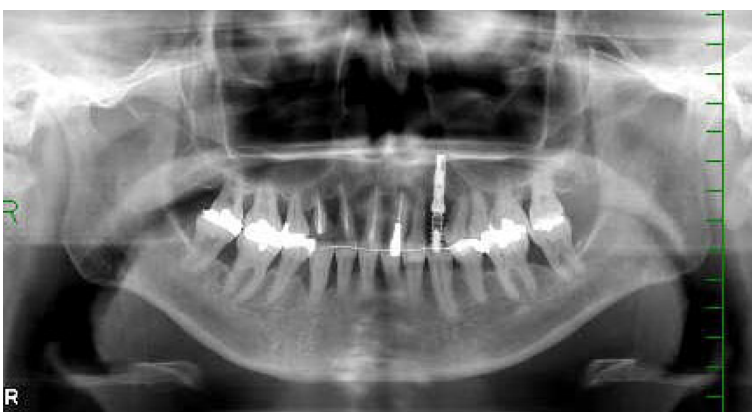

Figure 9 Post-treatment panoramic radiograph.

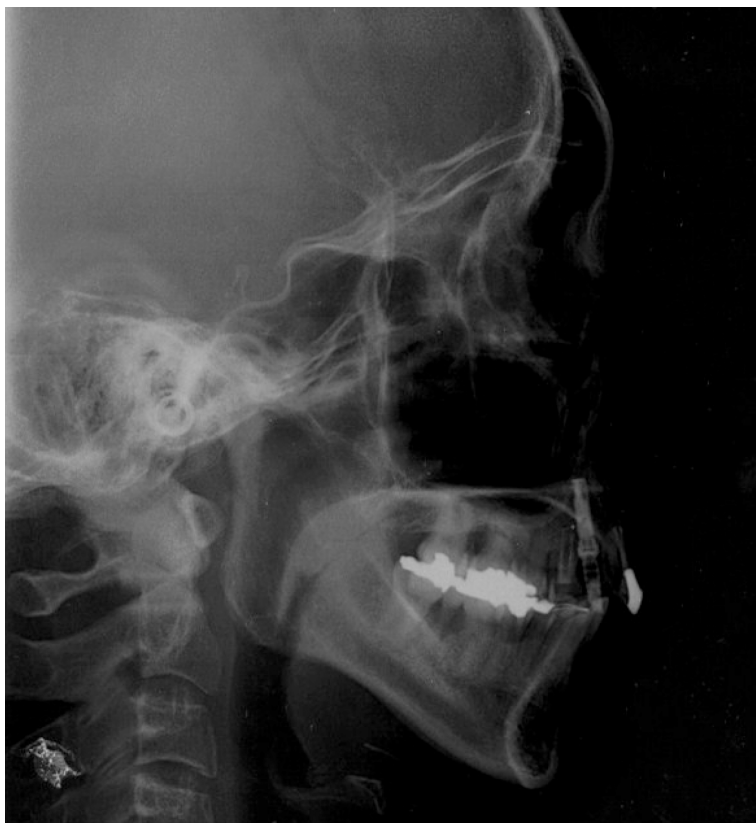

Figure 10 Post-treatment cephalometric radiograph.

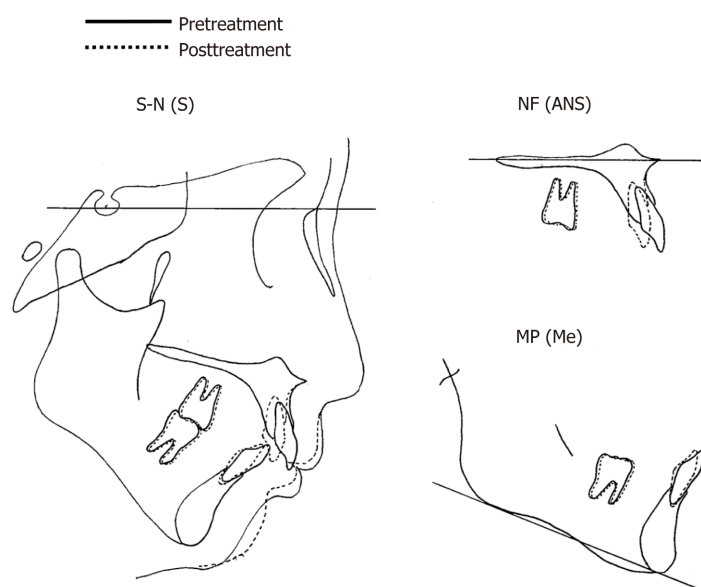


Figure 11 Cephalometric superimposition (pre-treatment and post-treatment). S-N(S): Superimposition for sella-nasion at sella; NF(ANS): Superimposition for nasal floor at anterior nasal spine; MP(Me): Superimposition for mandibular plane at menton.

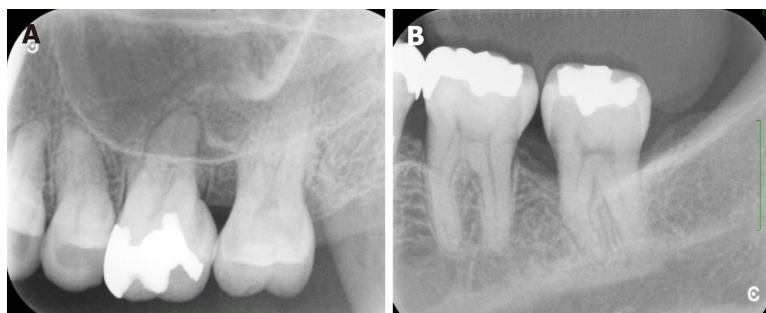

Figure 12 Dental radiographs of the upper and lower left molars after periodontal surgery. A: Upper left molars; B: Lower left molars.

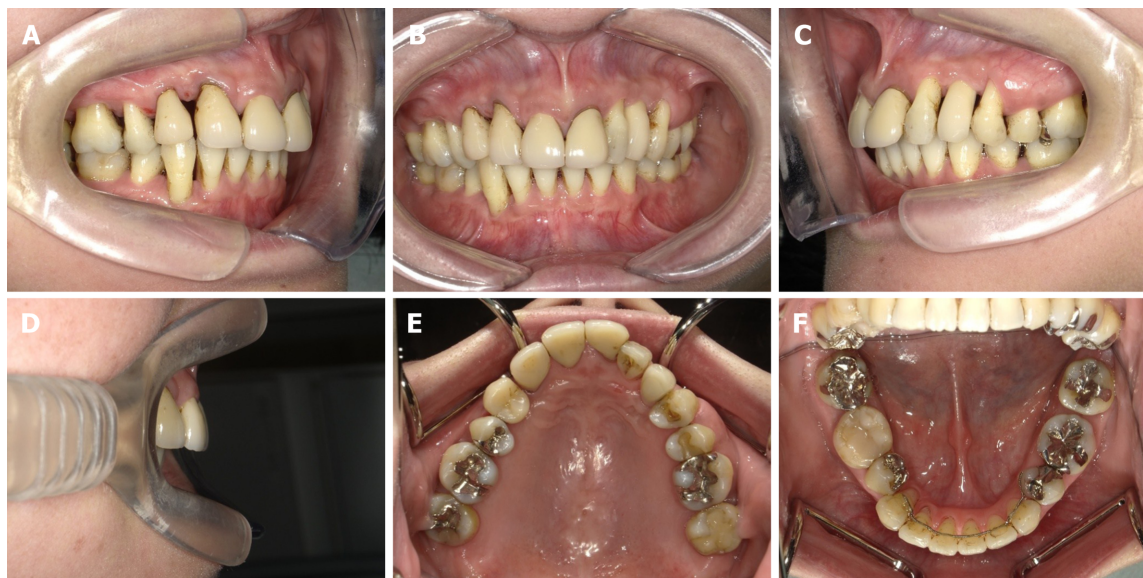


Figure 13 Intraoral photographs after 10 yr of retention. A: Right side view; B: Front view; C: Left side view; D: Incisal view; E: Upper occlusal view; F: Lower occlusal view.

REFERENCES

- 1 **Gottlieb B.** Die diffuse atrophy des alveolarknochens. *Z Stomatol* 1923; **21**: 195
- 2 **Armitage GC.** Development of a classification system for periodontal diseases and conditions. *Ann Periodontol* 1999; **4**: 1-6 [PMID: 10863370 DOI: 10.1902/annals.1999.4.1.1]
- 3 **Guzeldemir E, Toygar HU.** From alveolar diffuse atrophy to aggressive periodontitis: a brief history. *J Hist Dent* 2006; **54**: 96-99 [PMID: 17354672]
- 4 **on aggressive periodontitis.** American Academy of Periodontology. *J Periodontol* 2000; **71**: 867-869 [PMID: 10875695 DOI: 10.1902/jop.2000.71.5-S.867]
- 5 **Schacher B, Baron F, Rossberg M, Wohlfeil M, Arndt R, Eickholz P.** Aggregatibacter actinomycetemcomitans as indicator for aggressive periodontitis by two analysing strategies. *J Clin Periodontol* 2007; **34**: 566-573 [PMID: 17433043 DOI: 10.1111/j.1600-051X.2007.01080.x]
- 6 **Armitage GC.** Comparison of the microbiological features of chronic and aggressive periodontitis. *Periodontol* 2000 2010; **53**: 70-88 [PMID: 20403106 DOI: 10.1111/j.1600-0757.2010.00357.x]
- 7 **Teughels W, Dhondt R, Dekeyser C, Quirynen M.** Treatment of aggressive periodontitis. *Periodontol* 2000 2014; **65**: 107-133 [PMID: 24738589 DOI: 10.1111/prd.12020]
- 8 **Schuyler CH.** The function and importance of incisal guidance in oral rehabilitation. 1963. *J Prosthet Dent* 2001; **86**: 219-232 [PMID: 11552159 DOI: 10.1067/mpr.2001.118493]
- 9 **Maeda S, Maeda Y, Ono Y, Nakamura K, Sasaki T.** Interdisciplinary treatment of a patient with severe pathologic tooth migration caused by localized aggressive periodontitis. *Am J Orthod Dentofacial Orthop* 2005; **127**: 374-384 [PMID: 15775955 DOI: 10.1016/j.ajodo.2004.01.019]
- 10 **Ishihara Y, Tomikawa K, Deguchi T, Honjo T, Suzuki K, Kono T, Kuboki T, Kamioka H, Takashiba S, Yamashiro T.** Interdisciplinary orthodontic treatment for a patient with generalized aggressive periodontitis: Assessment of IgG antibodies to identify type of periodontitis and correct timing of treatment. *Am J Orthod Dentofacial Orthop* 2015; **147**: 766-780 [PMID: 26038081 DOI: 10.1016/j.ajodo.2014.09.022]
- 11 **Tonetti MS, Greenwell H, Kornman KS.** Staging and grading of periodontitis: Framework and

- proposal of a new classification and case definition. *J Periodontol* 2018; **89** Suppl 1: S159-S172 [PMID: 29926952 DOI: 10.1002/JPER.18-0006]
- 12 **Nesse W**, Abbas F, van der Ploeg I, Spijkervet FK, Dijkstra PU, Vissink A. Periodontal inflamed surface area: quantifying inflammatory burden. *J Clin Periodontol* 2008; **35**: 668-673 [PMID: 18564145 DOI: 10.1111/j.1600-051X.2008.01249.x]
- 13 **Armitage GC**. Periodontal diagnoses and classification of periodontal diseases. *Periodontol 2000* 2004; **34**: 9-21 [PMID: 14717852 DOI: 10.1046/j.0906-6713.2002.003421.x]
- 14 **Deas DE**, Moritz AJ, Sagun RS Jr, Gruwell SF, Powell CA. Scaling and root planing vs. conservative surgery in the treatment of chronic periodontitis. *Periodontol 2000* 2016; **71**: 128-139 [PMID: 27045434 DOI: 10.1111/prd.12114]
- 15 **Melsen B**. Tissue reaction to orthodontic tooth movement--a new paradigm. *Eur J Orthod* 2001; **23**: 671-681 [PMID: 11890063 DOI: 10.1093/ejo/23.6.671]
- 16 **Zasčiurinskienė E**, Basevičienė N, Lindsten R, Slotte C, Jansson H, Bjerklin K. Orthodontic treatment simultaneous to or after periodontal cause-related treatment in periodontitis susceptible patients. Part I: Clinical outcome. A randomized clinical trial. *J Clin Periodontol* 2018; **45**: 213-224 [PMID: 29106749 DOI: 10.1111/jcpe.12835]
- 17 **Fukunaga T**, Kuroda S, Kurosaka H, Takano-Yamamoto T. Skeletal anchorage for orthodontic correction of maxillary protrusion with adult periodontitis. *Angle Orthod* 2006; **76**: 148-155 [PMID: 16448285]
- 18 **Costa A**, Raffaini M, Melsen B. Miniscrews as orthodontic anchorage: a preliminary report. *Int J Adult Orthodon Orthognath Surg* 1998; **13**: 201-209 [PMID: 9835819]
- 19 **Sugawara J**, Daimaruya T, Umemori M, Nagasaka H, Takahashi I, Kawamura H, Mitani H. Distal movement of mandibular molars in adult patients with the skeletal anchorage system. *Am J Orthod Dentofacial Orthop* 2004; **125**: 130-138 [PMID: 14765050 DOI: 10.1016/j.ajodo.2003.02.003]
- 20 **Erverdi N**, Keles A, Nanda R. The use of skeletal anchorage in open bite treatment: a cephalometric evaluation. *Angle Orthod* 2004; **74**: 381-390 [PMID: 15264651]
- 21 **Kanomi R**. Mini-implant for orthodontic anchorage. *J Clin Orthod* 1997; **31**: 763-767 [PMID: 9511584]
- 22 **Paik CH**, Woo YJ, Boyd RL. Treatment of an adult patient with vertical maxillary excess using miniscrew fixation. *J Clin Orthod* 2003; **37**: 423-428 [PMID: 14519904]
- 23 **Kaku M**, Kojima S, Sumi H, Koseki H, Abedini S, Motokawa M, Fujita T, Ohtani J, Kawata T, Tanne K. Gummy smile and facial profile correction using miniscrew anchorage. *Angle Orthod* 2012; **82**: 170-177 [PMID: 22220843 DOI: 10.2319/020711-86.1]
- 24 **Jung RE**, Zembic A, Pjetursson BE, Zwahlen M, Thoma DS. Systematic review of the survival rate and the incidence of biological, technical, and aesthetic complications of single crowns on implants reported in longitudinal studies with a mean follow-up of 5 years. *Clin Oral Implants Res* 2012; **23** Suppl 6: 2-21 [PMID: 23062124 DOI: 10.1111/j.1600-0501.2012.02547.x]
- 25 **Donos N**, Laurell L, Mardas N. Hierarchical decisions on teeth vs. implants in the periodontitis-susceptible patient: the modern dilemma. *Periodontol 2000* 2012; **59**: 89-110 [PMID: 22507062 DOI: 10.1111/j.1600-0757.2011.00433.x]
- 26 **Al-Zahrani MS**. Implant therapy in aggressive periodontitis patients: a systematic review and clinical implications. *Quintessence Int* 2008; **39**: 211-215 [PMID: 18618035]
- 27 **Karoussis IK**, Kotsovilis S, Fourmousis I. A comprehensive and critical review of dental implant prognosis in periodontally compromised partially edentulous patients. *Clin Oral Implants Res* 2007; **18**: 669-679 [PMID: 17868376 DOI: 10.1111/j.1600-0501.2007.01406.x]



Published by **Baishideng Publishing Group Inc**
7041 Koll Center Parkway, Suite 160, Pleasanton, CA 94566, USA

Telephone: +1-925-3991568

E-mail: bpgoffice@wjgnet.com

Help Desk: <https://www.f6publishing.com/helpdesk>

<https://www.wjgnet.com>

