

World Journal of *Clinical Cases*

World J Clin Cases 2021 September 16; 9(26): 7614-7962



Contents

Thrice Monthly Volume 9 Number 26 September 16, 2021

EDITORIAL

- 7614 Advances in deep learning for computed tomography denoising
Park SB

REVIEW

- 7620 Spirituality, religiousness, and mental health: A review of the current scientific evidence
Lucchetti G, Koenig HG, Lucchetti ALG
- 7632 Role of hospitalization for inflammatory bowel disease in the post-biologic era
Soriano CR, Powell CR, Chiorean MV, Simianu VV

MINIREVIEWS

- 7643 Combined targeted therapy and immunotherapy for cancer treatment
Guo CX, Huang X, Xu J, Zhang XZ, Shen YN, Liang TB, Bai XL

ORIGINAL ARTICLE

Basic Study

- 7653 Mechanism of Jianpi Qingchang Huashi Recipe in treating ulcerative colitis: A study based on network pharmacology and molecular docking
Zheng L, Wen XL, Dai YC

Case Control Study

- 7671 Common bile duct morphology is associated with recurrence of common bile duct stones in Billroth II anatomy patients
Ji X, Jia W, Zhao Q, Wang Y, Ma SR, Xu L, Kan Y, Cao Y, Fan BJ, Yang Z

Retrospective Cohort Study

- 7682 Efficacy of roxadustat in treatment of peritoneal dialysis patients with renal anaemia
Zhu XW, Zhang CX, Xu TH, Jiang GN, Yao L

Retrospective Study

- 7693 Clinical metagenomic sequencing for rapid diagnosis of pneumonia and meningitis caused by *Chlamydia psittaci*
Yin XW, Mao ZD, Zhang Q, Ou QX, Liu J, Shao Y, Liu ZG
- 7704 Evaluation of the etiology and risk factors for maternal sepsis: A single center study in Guangzhou, China
Lin L, Ren LW, Li XY, Sun W, Chen YH, Chen JS, Chen DJ

- 7717 Influencing factors for hepatic fat accumulation in patients with type 2 diabetes mellitus

Wu MJ, Fang QL, Zou SY, Zhu Y, Lu W, Du X, Shi BM

- 7729 Clinical effect of peripheral capsule preservation in eyes with silicone oil tamponade

Jiang B, Dong S, Sun MH, Zhang ZY, Sun DW

- 7738 Potential effects of the nursing work environment on the work-family conflict in operating room nurses

Fu CM, Ou J, Chen XM, Wang MY

Observational Study

- 7750 Effect and satisfaction of outpatient services by precision valuation reservation registration

Jin HJ, Cheng AL, Qian JY, Lin LM, Tang HM

Randomized Controlled Trial

- 7762 Impact of intravenous dexmedetomidine on postoperative bowel movement recovery after laparoscopic nephrectomy: A consort-prospective, randomized, controlled trial

Huang SS, Song FX, Yang SZ, Hu S, Zhao LY, Wang SQ, Wu Q, Liu X, Qi F

META-ANALYSIS

- 7772 Comparison of different methods of nasogastric tube insertion in anesthetized and intubated patients: A meta-analysis

Ou GW, Li H, Shao B, Huang LM, Chen GM, Li WC

CASE REPORT

- 7786 Secondary injuries caused by ill-suited rehabilitation treatments: Five case reports

Zhou L, Zhou YQ, Yang L, Ma SY

- 7798 Gastric syphilis mimicking gastric cancer: A case report

Lan YM, Yang SW, Dai MG, Ye B, He FY

- 7805 Low-grade chondrosarcoma of the larynx: A case report

Vučković L, Klisic A, Filipović A, Popović M, Čulafić T

- 7811 Pediatric temporal fistula: Report of three cases

Gu MZ, Xu HM, Chen F, Xia WW, Li XY

- 7818 Treatment for CD57-negative $\gamma\delta$ T-cell large granular lymphocytic leukemia with pure red cell aplasia: A case report

Xiao PP, Chen XY, Dong ZG, Huang JM, Wang QQ, Chen YQ, Zhang Y

- 7825 Rare neonatal malignant primary orbital tumors: Three case reports

Zhang Y, Li YY, Yu HY, Xie XL, Zhang HM, He F, Li HY

- 7833 Carbon ion radiotherapy for bladder cancer: A case report

Zhang YS, Li XJ, Zhang YH, Hu TC, Chen WZ, Pan X, Chai HY, Wang X, Yang YL

- 7840** Extravasation of chemotherapeutic drug from an implantable intravenous infusion port in a child: A case report
Ly DN, Xu HZ, Zheng LL, Chen LL, Ling Y, Ye AQ
- 7845** Chronic active Epstein-Barr virus infection treated with PEG-asparaginase: A case report
Song DL, Wang JS, Chen LL, Wang Z
- 7850** Omental mass combined with indirect inguinal hernia leads to a scrotal mass: A case report
Liu JY, Li SQ, Yao SJ, Liu Q
- 7857** Critical lower extremity ischemia after snakebite: A case report
Lu ZY, Wang XD, Yan J, Ni XL, Hu SP
- 7863** Migration of the localization wire to the back in patient with nonpalpable breast carcinoma: A case report
Choi YJ
- 7870** Uniportal video-assisted thoracoscopic surgery for complex mediastinal mature teratoma: A case report
Hu XL, Zhang D, Zhu WY
- 7876** Congenital disorder of glycosylation caused by mutation of *ATP6AP1* gene (c.1036G>A) in a Chinese infant: A case report
Yang X, Lv ZL, Tang Q, Chen XQ, Huang L, Yang MX, Lan LC, Shan QW
- 7886** Rare monolocular intrahepatic biliary cystadenoma: A case report
Che CH, Zhao ZH, Song HM, Zheng YY
- 7893** Hepatocellular carcinoma with inferior vena cava and right atrium thrombus: A case report
Liu J, Zhang RX, Dong B, Guo K, Gao ZM, Wang LM
- 7901** Delayed diagnosis of ascending colon mucinous adenocarcinoma with local abscess as primary manifestation: Report of three cases
Han SZ, Wang R, Wen KM
- 7909** Gastrointestinal bleeding caused by syphilis: A case report
Sun DJ, Li HT, Ye Z, Xu BB, Li DZ, Wang W
- 7917** Transient involuntary movement disorder after spinal anesthesia: A case report
Yun G, Kim E, Do W, Jung YH, Lee HJ, Kim Y
- 7923** Diagnosis and treatment of an inborn error of bile acid synthesis type 4: A case report
Wang SH, Hui TC, Zhou ZW, Xu CA, Wu WH, Wu QQ, Zheng W, Yin QQ, Pan HY
- 7930** Malignant fibrous histiocytoma of the bone in a traumatic amputation stump: A case report and review of the literature
Zhao KY, Yan X, Yao PF, Mei J

- 7937** Rare complication of acute adrenocortical dysfunction in adrenocortical carcinoma after transcatheter arterial chemoembolization: A case report
Wang ZL, Sun X, Zhang FL, Wang T, Li P
- 7944** Peripherally inserted central catheter placement in neonates with persistent left superior vena cava: Report of eight cases
Chen Q, Hu YL, Li YX, Huang X
- 7954** Subcutaneous angiolipoma in the scrotum: A case report
Li SL, Zhang JW, Wu YQ, Lu KS, Zhu P, Wang XW

LETTER TO THE EDITOR

- 7959** Should people with chronic liver diseases be vaccinated against COVID-19?
Chen LP, Zeng QH, Gong YF, Liang FL

ABOUT COVER

Editorial Board Member of *World Journal of Clinical Cases*, Alessandro Leite Cavalcanti, DDS, MSc, PhD, Associate Professor, Department of Dentistry, State University of Paraiba, Campina Grande 58429500, Paraiba, Brazil. alessandrouepb@gmail.com

AIMS AND SCOPE

The primary aim of *World Journal of Clinical Cases* (WJCC, *World J Clin Cases*) is to provide scholars and readers from various fields of clinical medicine with a platform to publish high-quality clinical research articles and communicate their research findings online.

WJCC mainly publishes articles reporting research results and findings obtained in the field of clinical medicine and covering a wide range of topics, including case control studies, retrospective cohort studies, retrospective studies, clinical trials studies, observational studies, prospective studies, randomized controlled trials, randomized clinical trials, systematic reviews, meta-analysis, and case reports.

INDEXING/ABSTRACTING

The WJCC is now indexed in Science Citation Index Expanded (also known as SciSearch®), Journal Citation Reports/Science Edition, Scopus, PubMed, and PubMed Central. The 2021 Edition of Journal Citation Reports® cites the 2020 impact factor (IF) for WJCC as 1.337; IF without journal self cites: 1.301; 5-year IF: 1.742; Journal Citation Indicator: 0.33; Ranking: 119 among 169 journals in medicine, general and internal; and Quartile category: Q3. The WJCC's CiteScore for 2020 is 0.8 and Scopus CiteScore rank 2020: General Medicine is 493/793.

RESPONSIBLE EDITORS FOR THIS ISSUE

Production Editor: Jia-Hui Li; Production Department Director: Yun-Jie Ma; Editorial Office Director: Jin-Lei Wang.

NAME OF JOURNAL

World Journal of Clinical Cases

ISSN

ISSN 2307-8960 (online)

LAUNCH DATE

April 16, 2013

FREQUENCY

Thrice Monthly

EDITORS-IN-CHIEF

Dennis A Bloomfield, Sandro Vento, Bao-Gan Peng

EDITORIAL BOARD MEMBERS

<https://www.wjgnet.com/2307-8960/editorialboard.htm>

PUBLICATION DATE

September 16, 2021

COPYRIGHT

© 2021 Baishideng Publishing Group Inc

INSTRUCTIONS TO AUTHORS

<https://www.wjgnet.com/bpg/gerinfo/204>

GUIDELINES FOR ETHICS DOCUMENTS

<https://www.wjgnet.com/bpg/GerInfo/287>

GUIDELINES FOR NON-NATIVE SPEAKERS OF ENGLISH

<https://www.wjgnet.com/bpg/gerinfo/240>

PUBLICATION ETHICS

<https://www.wjgnet.com/bpg/GerInfo/288>

PUBLICATION MISCONDUCT

<https://www.wjgnet.com/bpg/gerinfo/208>

ARTICLE PROCESSING CHARGE

<https://www.wjgnet.com/bpg/gerinfo/242>

STEPS FOR SUBMITTING MANUSCRIPTS

<https://www.wjgnet.com/bpg/GerInfo/239>

ONLINE SUBMISSION

<https://www.f6publishing.com>



Omental mass combined with indirect inguinal hernia leads to a scrotal mass: A case report

Jia-Yi Liu, Shuai-Qi Li, Shi-Jie Yao, Qian Liu

ORCID number: Jia-Yi Liu 0000-0002-4973-0077; Shuai-Qi Li 0000-0003-2338-3748; Shi-Jie Yao 0000-0002-2624-2134; Qian Liu 0000-0002-8211-9990.

Author contributions: Liu JY, Li SQ, and Yao SJ were the patient's surgeons, reviewed the literature, and contributed to manuscript drafting; Liu Q reviewed the literature and contributed to manuscript drafting.

Supported by Science and Technology Fund of Tianjin Health and Family Planning Commission, No. 16KG103; and Tianjin Health Science and Technology Project, No. ZC20162.

Informed consent statement: Informed written consent was obtained from the patient for publication of this report and any accompanying images.

Conflict-of-interest statement: The authors declare that they have no conflict of interest to report.

CARE Checklist (2016) statement: The authors have read the CARE Checklist (2016), and the manuscript was prepared and revised according to the CARE Checklist (2016).

Open-Access: This article is an open-access article that was

Jia-Yi Liu, Shi-Jie Yao, Qian Liu, Department of Urology, Tianjin First Central Hospital, School of Medicine, Nankai University, Tianjin 300192, China

Shuai-Qi Li, School of Medicine, Nankai University, Tianjin 300192, China

Corresponding author: Qian Liu, MD, Doctor, Surgeon, Department of Urology, Tianjin First Central Hospital, School of Medicine, Nankai University, No. 24 Fukang Road, Tianjin 300192, China. simonlq@163.com

Abstract

BACKGROUND

Primary omental tumors are uncommon, and omental fibromas account for 2% of these tumors. Due to the low incidence of omental fibromas and the limited relevant literature, it is challenging for clinicians to make an accurate diagnosis of this condition, especially before surgery.

CASE SUMMARY

A 30-year-old man was admitted to the hospital because of a left epididymal mass with vague discomfort for more than 1 mo. A physical examination was performed, and the findings showed that the epididymal mass may have entered the abdominal cavity. Pelvic computed tomography was performed in our hospital and revealed a left inguinal hernia with a mass in the hernial contents, and no masses were found in the left epididymis. A traditional inguinal hernia incision was made. Intraoperative hernia contents were found to be of the greater omentum, and a 2.5 cm-diameter mass was found at the distal end of the greater omentum. The scrotum and epididymis did not exhibit other masses. Then, the mass of the greater omentum was excised. Intraoperative frozen pathological examination suggested a spindle cell tumor. The postoperative pathological examination suggested that the mass was an omental angiofibroma. Postoperatively, the patient recovered well and was discharged. Outpatient re-examinations were performed at 1 mo and half a year after the operation and showed no obvious abnormalities.

CONCLUSION

Due to the low morbidity rate associated with and latent nature of omental tumors, these tumors are difficult to diagnose preoperatively; thorough medical history taking, detailed physical examinations, and necessary imaging auxiliary examinations can help clinicians diagnose and treat these cases.

selected by an in-house editor and fully peer-reviewed by external reviewers. It is distributed in accordance with the Creative Commons Attribution NonCommercial (CC BY-NC 4.0) license, which permits others to distribute, remix, adapt, build upon this work non-commercially, and license their derivative works on different terms, provided the original work is properly cited and the use is non-commercial. See: <http://creativecommons.org/licenses/by-nc/4.0/>

Manuscript source: Unsolicited manuscript

Specialty type: Urology and nephrology

Country/Territory of origin: China

Peer-review report's scientific quality classification

Grade A (Excellent): 0
Grade B (Very good): B
Grade C (Good): 0
Grade D (Fair): 0
Grade E (Poor): 0

Received: March 30, 2021

Peer-review started: March 30, 2021

First decision: April 28, 2021

Revised: May 6, 2021

Accepted: August 4, 2021

Article in press: August 4, 2021

Published online: September 16, 2021

P-Reviewer: Ferreira GSA

S-Editor: Liu M

L-Editor: Wang TQ

P-Editor: Ma YJ



Key Words: Diagnosis; Epididymal mass; Omental mass; Inguinal hernia; Angiofibroma; Case report

©The Author(s) 2021. Published by Baishideng Publishing Group Inc. All rights reserved.

Core Tip: Primary omental tumors are not common, and omental fibromas account for 2% of these tumors. No previous studies have reported an omental fibroma combined with indirect hernia showing an epididymal mass. This case reminds us of the importance of detailed medical history, strict physical examination, and necessary imaging examinations when clinicians dealing with similar cases.

Citation: Liu JY, Li SQ, Yao SJ, Liu Q. Omental mass combined with indirect inguinal hernia leads to a scrotal mass: A case report. *World J Clin Cases* 2021; 9(26): 7850-7856

URL: <https://www.wjgnet.com/2307-8960/full/v9/i26/7850.htm>

DOI: <https://dx.doi.org/10.12998/wjcc.v9.i26.7850>

INTRODUCTION

Primary omental tumors are not common, and omental fibromas account for 2% of these tumors[1-4]. Due to the low incidence of omental fibromas and the limited relevant literature, it is challenging for clinicians to make an accurate diagnosis of this condition[1,2,5]. No previous studies have reported an omental fibroma combined with indirect hernia showing an epididymal mass. Herein, we report a case of omental angiofibroma combined with an indirect inguinal hernia, as well as important information regarding the diagnosis and treatment of omental masses.

CASE PRESENTATION

Chief complaints

A 30-year-old man was admitted to the Urological Department of Tianjin First Central Hospital because of a left epididymal mass with vague discomfort for more than 1 mo.

History of present illness

One month before the patient visited the hospital, he underwent a scrotal ultrasonographic (US) examination at another hospital for scrotal vague discomfort, which illustrated that there was a mass within the left epididymis.

History of past illness

The patient did not have any previous history of chronic disease, surgery, blood transfusion, or trauma.

Personal and family history

The patient was not a smoker and drank little liquor occasionally. No family history of malignancy was identified.

Physical examination

A physical examination was performed, and the findings showed that the epididymal mass may have entered the abdominal cavity after the patient was admitted to the hospital. Small movement of the mass was felt when the patient coughed or performed a Valsalva maneuver.

Laboratory examinations

Routine blood tests, biochemical examinations, and alpha-fetoprotein, carcinoembryonic antigen, carbohydrate antigen-19-9, carbohydrate antigen-72-4, and neuron-specific enolase tests were performed, and all of the resulting values were within the normal ranges. The patient denied experiencing weight loss, decreased appetite,

fatigue, or malaise.

Imaging examinations

The scrotal US examination performed at another hospital illustrated that there was a mass within the left epididymis. Pelvic computed tomography (CT) was performed in Tianjin First Central Hospital and showed intraperitoneal fat herniation in the left scrotum through the widened left inguinal canal, and the mass appeared as dense soft tissue within a hernia with a size of approximately 2.5 cm × 1.3 cm × 3.0 cm. The CT value was approximately 24 Hu (Figure 1). CT revealed a left inguinal hernia with a mass in the hernial contents, and no masses were found in the left epididymis.

FINAL DIAGNOSIS

Intraoperative frozen pathological examination suggested a spindle cell tumor. Subsequently, inguinal hernia repair was performed. Postoperative pathological examination suggested that the mass was an omental angiofibroma (Figure 2), and the immunohistochemical examination showed Vimentin (+), CK (-), CD43 (+), SMA (-), S100 (-), CD31 (+), F8 (-), and Ki-67 sporadic positivity.

TREATMENT

A traditional inguinal hernia incision was made and served as the projection point from the outer upper part of the pubic tubercle to the internal ring orifice. Intraoperative hernia contents were found to be of the greater omentum, and a 2.5 cm-diameter mass was found at the distal end of the greater omentum. The scrotum and epididymis did not exhibit other masses. Then, a surgical mesh was placed in the inguinal canal and the mass at the distal end of the greater omentum was excised.

OUTCOME AND FOLLOW-UP

Postoperatively, the patient recovered well and was discharged. Outpatient re-examinations were performed at 1 mo and half a year after the operation and showed no obvious abnormalities.

DISCUSSION

The primary diagnosis for the patient was an epididymal mass. Clinically, diseases for which epididymal masses are the main manifestations include epididymal tuberculosis, seminal cysts, epididymal cysts, epididymal benign tumors, epididymal malignant tumors, *etc.* It is difficult to diagnose epididymal masses solely based on the patient's medical history and clinical manifestations, and misdiagnoses easily occur. Epididymal masses are mainly identified on the basis of clinical manifestations such as the location, texture, and tenderness of the mass, combined with imaging modalities such as US, plain CT, and magnetic resonance imaging (MRI)[5-9].

The results of the physical examination and CT led us to diagnose the patient with left inguinal hernia. Inguinal hernias most commonly involve the small intestine, followed by the greater omentum. Preoperative imaging examinations alone, such as US and CT examinations, to determine hernia contents are prone to misdiagnosis. Michele *et al*[10] reported a patient who was diagnosed with an inguinal hernia and whose preoperative CT examination findings showed that the hernia content was of the small intestine, but the postoperative pathological examination demonstrated that the hernia content included Hodgkin's lymphoma. Tajti *et al*[11] also reported a patient who was diagnosed with an inguinal hernia and whose preoperative US examination findings showed that the hernia content was of an edematous intestinal loop with no circulation detected, but the hernia content was found to be of the gallbladder that was incarcerated during the operation. Taskovska and Janez[12] reported a patient who was diagnosed with an inguinal hernia and whose preoperative US examination findings showed that the hernia contents were of aperistaltic small intestine loops without dilatation, but the hernia content was found to be of the urinary bladder. In

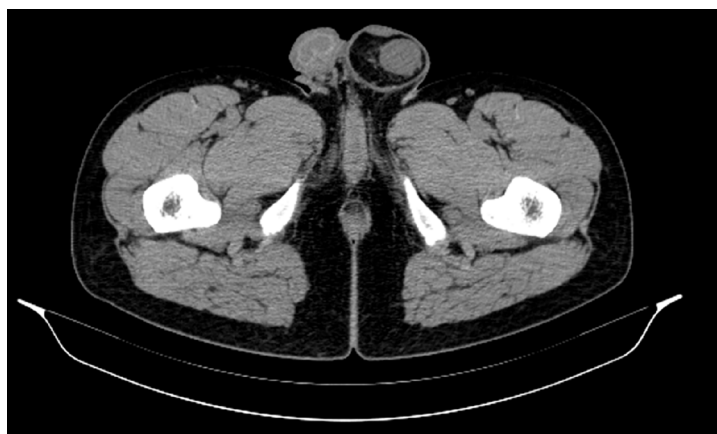


Figure 1 Pelvic computed tomography findings. Pelvic computed tomography showed that intraperitoneal fat herniate in the left scrotum through widened left inguinal canal, and there is a mass appearing as soft tissue density in hernia contents with a size of approximately 2.5 cm × 1.3 cm × 3.0 cm.

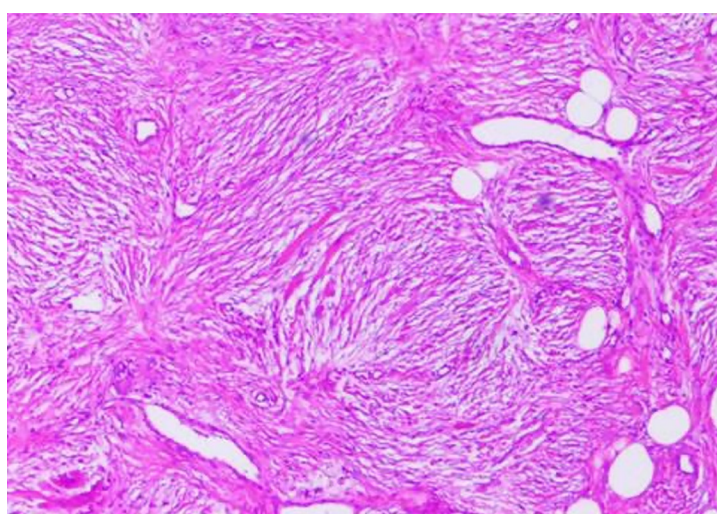


Figure 2 Histological findings revealed by hematoxylin and eosin staining of paraffin-embedded sections from the surgical specimen. Postoperative pathological examination suggested that the mass is omental angiofibroma (magnification × 100).

our study, the preoperative CT examination demonstrated that the hernia contents contained a mass that could not be diagnosed by imaging tests alone.

The vast majority of omental tumors are metastatic tumors. In contrast, tumors originating from the greater omentum are extremely rare, and the pathogenesis is still not clear. The most common clinical symptoms of omental tumors include abdominal pain, abdominal masses, and bloating. In most patients, abdominal pain is aggravated in the supine position and relieved in the upright position. Some patients also experience nausea and weight loss. In addition, the local symptoms of benign and malignant omental lesions are the same. In the initial stage when the tumor is small, as in the patient in this study, omental tumors are usually asymptomatic. Although imaging examinations are becoming increasingly popular and Chinese people are paying increasing attention to physical examination findings, primary omental tumors are still extremely rare[2,4].

The most common primary malignant omental tumors include leiomyosarcoma, hemangiopericytoma, and fibrosarcoma, and liposarcoma has also been reported[13-20]. The most common benign omental tumors include gastrointestinal stromal tumors, leiomyomas, lipomas, and fibroids. Only a few studies have reported cases of omental angiofibroma, and all of these cases were considered to be intra-abdominal[2,4]. No previous studies have reported an omental mass combined with indirect inguinal hernia showing an epididymal mass. In this study, a primary omental tumor herniated into the scrotum and formed an indirect inguinal hernia. The tumor was located near the epididymis. Therefore, US at another hospital showed an epididymal tumor.

In addition to regular preoperative examinations, US, CT, MRI, positron emission tomography (PET), and angiography can be used to detect omental tumors[2]. Abdominal US examinations are considered the first-line screening imaging examinations for most patients, as US can detect abdominal masses and distinguish cystic tumors from solid tumors. However, US usually cannot provide additional information about the tumor. For this reason, abdominal CT is the primary choice for the diagnosis of omental tumors. CT can provide more anatomical details, which can assist in determining the location of the primary tumor and indicate whether adjacent organs and tissues are significantly dislocated or compressed. MRI is another imaging modality that can help distinguish cystic tumors from solid tumors. MRI findings are not affected by the examiner, and contrast agents do not need to be prepared. However, MRI is time-consuming and expensive compared to other imaging methods. PET scans can also be used to help distinguish between benign and malignant tissues, necrotic scars, and active tumors when omental gastrointestinal stromal tumors are suspected. Angiography may also be helpful for patients suspected of having omental tumors. If angiography shows a tumor with rich blood supply in the greater omentum accompanied by neovascularization, it is likely to be malignant. At this time, angiography can also determine the distribution of supplying arteries and peripheral blood vessels of the tumor. At present, there is still considerable controversy about whether fine-needle aspiration biopsy should be performed for omental tumors. Although needle biopsy helps determine the pathological diagnosis preoperatively, it also increases the risk of tumor intra-abdominal implantation. However, these imaging examinations cannot help clinicians make an accurate preoperative diagnosis[2]. Usually, the definitive diagnosis still depends on postoperative pathological examination findings.

Total omentectomy is performed to treat primary omental tumors, as it seems to significantly improve the survival time of patients postoperatively, even with peritoneal implantation metastasis. The first symptoms of omental tumors can also be rupture-related bleeding and intestinal obstruction, requiring emergency surgery. The inability to safely remove the tumor due to local invasion is an absolute contraindication for surgical resection[21,22].

Owing to the rarity of primary omental tumors, the role of other adjuvant therapies, such as chemotherapy and radiotherapy, in the treatment of omental malignant tumors is currently unclear. In this study, because the intraoperative frozen pathological test results suggested a benign spindle cell tumor, only omental tumor resection and inguinal hernia repair were performed instead of total omental resection.

The pathology of this case was considered to be angiofibroma, which is mainly composed of proliferating blood vessels and fibrous tissue[23]. It mostly takes place in the nasopharynx of male adolescents, rarely occurs outside the nasopharyngeal area, and even more rarely occurs in the genitourinary system[24,25]. Studies have suggested that angiofibroma may originate from the periosteum of the skull base, but its exact pathogenesis is still not clear[1-3].

The median survival time of patients with primary malignant tumors of the greater omentum is only 6 mo. Two years after surgery, only approximately 10%-20% of patients are alive. The reasons for this poor prognosis are still unclear, potentially due to the small sample sizes of studies and the fact that some patients have had distant metastases at the time of admission. The prognosis of benign tumors of the greater omentum is significantly better than that of malignant tumors. Studies have reported that the 5-year survival rate for benign tumors of the greater omentum is approximately 75% and that this rate varies by the specific pathological type[1,2,4]. Due to the limited number of clinical studies on patients with omental tumors, there is no consensus on the postoperative management of patients with omental tumors. Some omental tumors, such as sarcoma, may recur and metastasize 20 years after surgery. Therefore, it is recommended that patients with omental tumors undergo long-term follow-ups after surgery[26]. In this study, although the postoperative pathology of this case was benign angiofibroma, we still recommended that the patient undergo active reexamination and follow-ups.

CONCLUSION

Due to the low morbidity rate associated with and latent nature of omental tumors, these tumors are difficult to diagnose preoperatively; thorough medical history taking, detailed physical examinations, and necessary imaging auxiliary examinations can help clinicians diagnose and treat these cases.

REFERENCES

- 1 **Ono M**, Tanaka K, Ikezawa N, Kobayashi Y, Inoue Y, Yokota M, Matsumura S, Uehara I, Hattori Y, Kurahashi T, Shimada T, Nakagawa H. Fibroma of the omentum resembling an ovarian tumor in the pelvis. *Keio J Med* 2009; **58**: 234-236 [PMID: [20037288](#) DOI: [10.2302/kjm.58.234](#)]
- 2 **Iusco D**, Donadei E, Sgobba G, Sarli L. Giant fibroma of the lesser omentum: report of a rare case. *Acta Biomed* 2005; **76**: 42-44 [PMID: [16116825](#)]
- 3 **Paksoy Y**, Sahin M, Açikgözoğlu S, Odev K, Omeroğlu E. Omental fibroma: CT and US findings. *Eur Radiol* 1998; **8**: 1422-1424 [PMID: [9853228](#) DOI: [10.1007/s003300050566](#)]
- 4 **Ishida H**, Ishida J. Primary tumours of the greater omentum. *Eur Radiol* 1998; **8**: 1598-1601 [PMID: [9866769](#) DOI: [10.1007/s003300050594](#)]
- 5 **Gao L**, Song H, Mu K, Wang J, Guo B, Shi B, Li G. Primary epididymis malignant triton tumor: case report and review of the literature. *Eur J Med Res* 2015; **20**: 79 [PMID: [26392076](#) DOI: [10.1186/s40001-015-0172-y](#)]
- 6 **Bedir R**, Şehitoğlu İ, Uzun H, Yurdakul C. Inflammatory pseudotumor of the epididymis: a case report and review of the literature. *Turk J Urol* 2013; **39**: 281-284 [PMID: [26328125](#) DOI: [10.5152/tud.2013.068](#)]
- 7 **Borges WM**, Bechara GR, de Miranda MML, de Figueiredo GB, Venturini BA, Laghi CR. Epididymis tuberculosis: Case report and brief review of the literature. *Urol Case Rep* 2019; **26**: 100969 [PMID: [31367526](#) DOI: [10.1016/j.eucr.2019.100969](#)]
- 8 **Huang Y**, Song J, Xu M, Zan Q. Primary Leydig cell tumour of epididymis: a rare case report with review of literature. *Andrologia* 2013; **45**: 430-433 [PMID: [23194277](#) DOI: [10.1111/and.12049](#)]
- 9 **Marcou M**, Perst V, Cacchi C, Lehnhardt M, Vögeli TA. Epididymal leiomyoma: a benign intrascrotal tumour. *Andrologia* 2017; **49** [PMID: [27709651](#) DOI: [10.1111/and.12689](#)]
- 10 **Teodoro M**, Mannino M, Vitale M, Mattone E, Palumbo V, Fraggetta F, Toro A, Di Carlo I. Small bowel lymphoma presenting as inguinal hernia: case report and literature review. *World J Surg Oncol* 2018; **16**: 91 [PMID: [29764448](#) DOI: [10.1186/s12957-018-1396-4](#)]
- 11 **Tajti J Jr**, Pieler J, Ábrahám S, Simonka Z, Paszt A, Lázár G. Incarcerated gallbladder in inguinal hernia: a case report and literature review. *BMC Gastroenterol* 2020; **20**: 425 [PMID: [33317478](#) DOI: [10.1186/s12876-020-01569-5](#)]
- 12 **Taskovska M**, Janež J. Inguinal hernia containing urinary bladder-A case report. *Int J Surg Case Rep* 2017; **40**: 36-38 [PMID: [28923679](#) DOI: [10.1016/j.ijscr.2017.08.046](#)]
- 13 **Becker JHR**, Koto MZ, Matsevych OY, Bida NM. Haemangiopericytoma/solitary fibrous tumour of the greater omentum. *S Afr J Surg* 2014; **52**: 111-113 [PMID: [28876701](#) DOI: [10.7196/sajs.2274](#)]
- 14 **Brañes A**, Bustamante C, Valbuena J, Pimentel F, Quezada N. Primary leiomyosarcoma of the greater omentum: a case report. *Int J Surg Case Rep* 2016; **28**: 317-320 [PMID: [27771602](#) DOI: [10.1016/j.ijscr.2016.10.025](#)]
- 15 **Okamoto K**, Okada Y, Ohno K, Yagi T, Tsukamoto M, Akahane T, Shimada R, Hayama T, Tsuchiya T, Nozawa K, Matsuda K, Ishida T, Kondo F, Hashiguchi Y. A rare case of perivascular epithelioid cell tumor (PEComa) of the greater omentum. *World J Surg Oncol* 2018; **16**: 113 [PMID: [29921303](#) DOI: [10.1186/s12957-018-1407-5](#)]
- 16 **Llenas-García J**, Guerra-Vales JM, Moreno A, Ibarrola C, Castelbon FJ, Fernández-Ruiz M, Meneu JC, Ballestin C, Moreno E. Primary extragastrointestinal stromal tumors in the omentum and mesentery: a clinicopathological and immunohistochemical study. *Hepatogastroenterology* 2008; **55**: 1002-1005 [PMID: [18705316](#)]
- 17 **Schwartz RW**, Reames M, McGrath PC, Letton RW, Appleby G, Kenady DE. Primary solid neoplasms of the greater omentum. *Surgery* 1991; **109**: 543-549 [PMID: [2008659](#)]
- 18 **Todoroki T**, Sano T, Sakurai S, Segawa A, Saitoh T, Fujikawa K, Yamada S, Hirahara N, Tsushima Y, Motojima R, Motojima T. Primary omental gastrointestinal stromal tumor (GIST). *World J Surg Oncol* 2007; **5**: 66 [PMID: [17565683](#) DOI: [10.1186/1477-7819-5-66](#)]
- 19 **Chauhan U**, Udiya AK, Prabhu SM, Shetty GS. Malignant nerve sheath tumour of omentum and the "omental vascular pedicle sign". *BJR Case Rep* 2016; **2**: 20150037 [PMID: [30363546](#) DOI: [10.1259/bjrcr.20150037](#)]
- 20 **Urabe M**, Yamagata Y, Aikou S, Mori K, Yamashita H, Nomura S, Shibahara J, Fukayama M, Seto Y. Solitary fibrous tumor of the greater omentum, mimicking gastrointestinal stromal tumor of the small intestine: a case report. *Int Surg* 2015; **100**: 836-840 [PMID: [26011203](#) DOI: [10.9738/INTSURG-D-14-00141.1](#)]
- 21 **Alves M**. Primary omental gastrointestinal stromal tumor- what we know based on case series and literature review. *Eur J Surg Oncol* 2020; **46**: E135-E136 [DOI: [10.1016/j.ejso.2019.11.355](#)]
- 22 **Hashimoto S**, Arai J, Nishimuta M, Matsumoto H, Fukuoka H, Muraoka M, Nakashima M, Yamaguchi H. Resection of liposarcoma of the greater omentum: A case report and literature review. *Int J Surg Case Rep* 2019; **61**: 20-25 [PMID: [31306901](#) DOI: [10.1016/j.ijscr.2019.06.067](#)]
- 23 **López F**, Triantafyllou A, Snyderman CH, Hunt JL, Suárez C, Lund VJ, Strojjan P, Saba NF, Nixon IJ, Devaney KO, Albid I, Bernal-Sprekelsen M, Hanna EY, Rinaldo A, Ferlito A. Nasal juvenile angiofibroma: Current perspectives with emphasis on management. *Head Neck* 2017; **39**: 1033-1045 [PMID: [28199045](#) DOI: [10.1002/hed.24696](#)]
- 24 **Pérez-Navarro JV**, Flores-Cardoza A, Anaya-Prado R, González-Izquierdo Jde J, Ramírez-Barba EJ. Angiofibrolipoma of the greater omentum: case report and literature review. *Cir Cir* 2009; **77**: 229-232 [PMID: [19671276](#)]

- 25 **Windfuhr JP**, Vent J. Extranasopharyngeal angiofibroma revisited. *Clin Otolaryngol* 2018; **43**: 199-222 [PMID: [28714226](#) DOI: [10.1111/coa.12939](#)]
- 26 **Vasdeki D**, Bompou E, Diamantis A, Anagnostou A, Tepetes K, Efthimiou M. Haemangiopericytoma of the greater omentum: a rare tumour requiring long-term follow-up. *J Surg Case Rep* 2018; **2018**: rjy087 [PMID: [29977504](#) DOI: [10.1093/jscr/rjy087](#)]



Published by **Baishideng Publishing Group Inc**
7041 Koll Center Parkway, Suite 160, Pleasanton, CA 94566, USA

Telephone: +1-925-3991568

E-mail: bpgoffice@wjgnet.com

Help Desk: <https://www.f6publishing.com/helpdesk>

<https://www.wjgnet.com>

