

ALL IMAGES VIDEOS

63,500 Results Any time

Critical limb ischemia in a patient with systemic lupus ...<https://pubmed.ncbi.nlm.nih.gov/31018871>

The second follow-up was done 2 months after the first follow-up and discoloration was improved. The third follow-up, 5 months after the second follow-up, showed improvement. Conclusion: Critical limb ischemia is a rare complication of systemic lupus erythematosus that requires immediate treatment. Due to our limited resources, we improvised a strategy to achieve the best possible outcome in our patient ...

Author: Vito Damay, Wendy Wiharja, Raymon... Publish Year: 2019

Adductor Canal Compression Syndrome in a 46-Year-Old ...<https://pubmed.ncbi.nlm.nih.gov/27554690>

We report the case of a 46-year-old athletic woman, who suffered from activity-related paresthesia and sharp pain in the left upper and lower leg for 2 years. Imaging and neurological investigations of the spine remained without pathological findings that would explain the patient's complaints. Actually, the patient presented with symptoms of critical lower limb ischemia. Magnetic resonance angiography revealed ...

Search Tools

Turn off Hover Translation (关闭取词)

Critical limb ischemia in a patient with systemic lupus ...

<https://pubmed.ncbi.nlm.nih.gov/31018871>

Critical limb ischemia is a rare complication of systemic lupus erythematosus that requires immediate treatment. Due to our limited resources, we improvised a strategy to achieve the best possible outcome in our patient by using a combination of invasive treatment and medication.

Author: Vito Damay, Wendy Wiharja, Raymond P... **Publish Year:** 2019

Critical Limb Ischemia Secondary to Antiphospholipid ...

<https://pubmed.ncbi.nlm.nih.gov/28390911>

APS affecting primarily the arteries is less common when compared to venous complications. We present a case of arterial occlusion resulting in **critical limb ischemia** (CLI) in a pediatric patient. Methods: A 14-year old boy presented with worsening right **lower extremity** pain and ulcerative lesions of his foot. Laboratory analysis revealed a ...

Author: Andrew J. Soo Hoo, Joseph M. White, P... **Publish Year:** 2017

Snake Bite Management: A Scoping Review of the Literature

<https://www.ncbi.nlm.nih.gov/pmc/articles/PMC8084039>

Apr 29, 2021 · 51 were upper **extremity**, 38 **lower extremity**. 31 patients had complications and 20 needed surgery. 88 patients received a median of 10 vials antivenom. ... **Case report:** 1: Evaluate post **snake bite** cellulitis leading to infected open dislocation of first MCP joint: ... **Critical** to receive **critical** care and antivenom administration if envenomation ...

Author: Jeffrey J. Russell, Anna Schoenbrunner,... **Publish Year:** 2021

Adder bite: an uncommon cause of compartment syndrome in ...

<https://www.ncbi.nlm.nih.gov/pmc/articles/PMC2949668>

Sep 20, 2010 · The **critical** period for a victim is usually the first 12 hours **after** being bitten but may last for several days. Compartment syndrome **after** an adder bite is extremely rare, but has been reported in the palm and forearm following envenomation [9-11]. Other more common reasons for compartment syndrome of the upper **extremity** include forearm fractures, ischemic-reperfusion following injury, hemorrhage, vascular puncture, intravenous drug injection, casts, prolonged **limb** ...

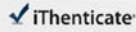
Cited by: 15

Author: Lars H Evers, Tanja Bartscher, Thomas Lan...

26-Jul-2021 04:02PM


1273 words • 0 matches • 3 sources

FAQ

 iThenticate®

66186_Auto_Edited - IT check.docx

Quotient Excluded
Bibliography Excluded
4%
0.000001



Name of Journal: *World Journal of Clinical Cases*

Manuscript NO: 66186

Manuscript Type: CASE REPORT

Critical lower extremity ischemia after snakebite: A case report

Critical Lower Extremity Ischemia After Snakebite

Ziying Lu, Xiaodong Wang, Jin Yan, Xiaolong Ni, Sipin Hu

Match Overview

1

Internet: 13 words
Crawled on 26-May-2021
www.viggo.com

1%

2

Internet: 12 words
Crawled on 26-Oct-2019
itpublishing.bkz.com/windows.net

1%

3

Internet: 12 words
www.mpi.sen.gov

1%

66186 revised

PRUE: 1 OF 7

Text-Only Report

国内版

国际版

Critical lower extremity ischemia after snakebite: A case report



ALL

IMAGES

VIDEOS

20,700 Results

Any time ▾

Snake Bite Management: A Scoping Review of the Literature

<https://www.ncbi.nlm.nih.gov/pmc/articles/PMC8084039>

Apr 29, 2021 · 51 were upper extremity, 38 lower extremity. 31 patients had complications and 20 needed surgery. 88 patients received a median of 10 vials antivenom. ... **Case report:** 1: Evaluate post snake bite cellulitis leading to infected open dislocation of first MCP joint: ... **Critical** to receive critical care and antivenom administration if envenomation ...

Author: Jeffrey J. Russell, Anna Schoenbrunn... Publish Year: 2021

Critical limb ischemia in a patient with systemic lupus ...

<https://pubmed.ncbi.nlm.nih.gov/31018871>

Critical limb ischemia is a rare complication of systemic lupus erythematosus that requires immediate treatment. Due to our limited resources, we improvised a strategy to achieve the best possible outcome in our patient by using a combination of invasive treatment and medication.

Author: Vito Damay, Wendy Wiharja, Raymon... Publish Year: 2019

Critical Limb Ischemia Secondary to Antiphospholipid ...

<https://pubmed.ncbi.nlm.nih.gov/28390911>

APS affecting primarily the arteries is less common when compared to venous complications. We present a case of arterial occlusion resulting in critical limb ischemia (CLI) in a pediatric patient. Methods: A 14-year old boy presented with worsening right lower extremity pain and ulcerative lesions of his foot. Laboratory analysis revealed a ...

Author: Andrew J. Soo Hoo, Joseph M. White,... Publish Year: 2017

Cureus | Complex Regional Pain Syndrome Developing After ...

<https://www.cureus.com/articles/37766-complex...> ▾

Aug 16, 2020 · Complex regional pain syndrome (CRPS) usually occurs after an inciting injury. Poor understanding of pathophysiology, management, and disease awareness has led to misdiagnosis of this condition. We report a rare case of a 69-year-old male who developed CRPS following a Florida Coral snake bite on his right foot. Initially, it was misdiagnosed as recurrent cellulitis; however, he ...

Author: Elis M Cruz Salcedo, Anamarys Blan... Publish Year: 2020

Adder bite: an uncommon cause of compartment syndrome ...

<https://www.ncbi.nlm.nih.gov/pmc/articles/PMC2949668>